

STUDIES ON MEASLES.

I. SUSCEPTIBILITY OF MONKEYS TO THE VIRUS OF MEASLES.

By FRANCIS G. BLAKE, M.D., AND JAMES D. TRASK, JR., M.D.

(From the Hospital of The Rockefeller Institute for Medical Research.)

PLATE 36.

(Received for publication, November 5, 1920.)

INTRODUCTION.

Measles occupies a prominent position among the acute infectious diseases that lead to severe and not infrequently fatal secondary infections of the respiratory tract. Efforts to control this serious effect of measles are at present directed almost wholly toward the prevention of the secondary infections by means of isolation and careful treatment of the patient, and while they have met with a certain degree of success, the results obtained are still far from satisfactory. A more hopeful solution of the problem would appear to lie in the prevention of measles itself.

Long experience has shown that the prevention of measles by strict quarantine is largely inadequate because of the contagiousness of the disease during the prodromal period. There would appear to be, however, more than a theoretical possibility that prevention may be accomplished by protective inoculation. This will obviously require isolation of the virus of measles, or at least the development of a method of handling the virus in pure form, whether it is actually identified under the microscope and in the culture tube or not. Much work has already been done in this direction, both by culture study and by attempted transmission of the virus to animals. The former method has not yet yielded positive results. Whether the transmission of the virus to animals has been successfully accomplished has remained an open question because of the conflicting results obtained by different investigators and because of the somewhat indefinite and limited criteria that have been relied upon as evidence

of a positive transmission. In undertaking a study of measles it has seemed desirable, therefore, to determine at the outset whether more conclusive evidence concerning the susceptibility of animals to the virus of the disease might not be obtained.

This paper presents the results of experiments so far conducted on the transmission of measles from man to monkeys and the passage of the infection from monkey to monkey. The symptomatology and pathology of the reaction produced will be presented in greater detail in a subsequent paper.¹

LITERATURE.

The more recent experiments upon the transmission of measles to monkeys date from the work of Anderson and Goldberger² and are largely based upon Hektoen's³ earlier report of having successfully transmitted measles from man to man by the subcutaneous injection of ascites broth blood cultures from patients in the early eruptive stage of the disease. The former authors claim to have transmitted the virus of measles to monkeys in a considerable number of instances by the use of whole defibrinated blood, blood serum, and washed corpuscles from cases of measles in the preruptive or early eruptive stages of the disease. Intra-peritoneal, intracerebral, intravenous, and subcutaneous routes of inoculation were employed with apparently equal success. Transmission was also accomplished by subcutaneous injection of nasopharyngeal secretions collected in the prodromal and early eruptive stages, and further transmission from monkey to monkey was carried through six passages. The evidence of a positive transmission consisted in a moderate febrile reaction of inconstant character coming on after an incubation period varying from 6 to 21 days, accompanied in some instances by an erythematous or maculopapular rash of variable character with or without symptoms of rhinitis. No mention is made of Koplik spots, of blood counts, or of histological examination of the skin or mucous membranes. It seems probable that Anderson and Goldberger succeeded in transmitting the virus of measles to monkeys in certain of their experiments, but the evidence which they present is not entirely conclusive.

Nicolle and Conseil⁴ using similar methods have also reported the successful transmission of the virus of measles from man to monkey and its further passage

¹ Blake, F. G., and Trask, J. D., Jr., *J. Exp. Med.*, 1921, xxxiii, 413.

² Anderson, J. F., and Goldberger, J., *Pub. Health Rep., U. S. P. H.*, 1911, xxvi, 847, 887; *J. Am. Med. Assn.*, 1911, lvii, 113. Goldberger, J., and Anderson, J. F., *J. Am. Med. Assn.*, 1911, lvii, 476. Anderson, J. F., and Goldberger, J., *J. Am. Med. Assn.*, 1911, lvii, 1612.

³ Hektoen, L., *J. Infect. Dis.*, 1905, ii, 238.

⁴ Nicolle, C., and Conseil, E., *Compt. rend. Acad.*, 1911, cliii, 1522; *Compt. rend. Soc. biol.*, 1920, lxxxiii, 56.

from monkey to monkey. Except for an elevation of temperature after an incubation period of 8 to 11 days no symptoms of measles are mentioned as having been observed in the inoculated monkeys.

Hektoen and Eggers,⁵ Tunnichiff,⁶ and Lucas and Prizer⁷ have studied the leucocyte reaction in monkeys inoculated with blood from measles patients and have shown that a fall in the total leucocyte count takes place. These authors, however, present little definite evidence that the monkeys were infected with the virus of measles.

Jurgelunas⁸ inoculated three monkeys with defibrinated blood and five monkeys with secretions of the respiratory tract from cases of measles. He also exposed two monkeys for 5 days to active cases of measles in a hospital ward. None of the animals showed any evidence of infection with the virus of measles.

Sellards and Wentworth⁹ and Sellards¹⁰ have recently carried out a series of inoculation experiments in both monkeys and man. Five monkeys were intensively inoculated with large amounts of blood from preeruptive and early eruptive cases of measles. The results were negative. Eight susceptible human volunteers were inoculated with blood from cases of measles in the prodromal or early eruptive stages. None of the men showed any evidence of measles.

Although according to the literature, as Sellards has pointed out, most of the important symptoms of measles have been described in inoculated monkeys, it is striking that no single investigator has obtained all the features in any one animal or even in a series of animals, and that no single symptom has appeared with constancy. The periods of incubation vary widely, the temperature reactions are inconstant, Koplik spots have been noted only by Lucas and Prizer, the rashes described are variable in character and frequently lacking, and there is disagreement in regard to the character of the leucocyte reaction.

EXPERIMENTAL.

In attempting to determine the susceptibility of monkeys to the virus of measles it seemed desirable at the outset to utilize a method that presumably would afford the optimum opportunity for successful transmission; namely, the use of a comparatively large amount of material believed to contain the virus of measles and the inoculation

⁵ Hektoen, L., and Eggers, H. E., *J. Am. Med. Assn.*, 1911, lvii, 1833.

⁶ Tunnichiff, R., *J. Infect. Dis.*, 1912, xi, 474.

⁷ Lucas, W. P., and Prizer, E. L., *J. Med. Research*, 1912-13, xxvi, 181.

⁸ Jurgelunas, A., *Centr. Bakt., 1te Abl., Orig.*, 1914, lxxii, 483.

⁹ Sellards, A. W., and Wentworth, J. A., *Bull. Johns Hopkins Hosp.*, 1919, xxx, 57.

¹⁰ Sellards, A. W., *Bull. Johns Hopkins Hosp.*, 1919, xxx, 257, 311.

of this material by the natural path of infection. This method might be expected to afford not only the best opportunity for successful transmission, but also a greater probability that the reaction of the animal to the virus would more closely conform to the course of measles as it occurs in man. Clinical observation has indicated beyond reasonable doubt that the virus of measles is abundantly present in the secretions of the respiratory tract during the pre-eruptive and early eruptive stages of the disease and that the respiratory mucous membrane is the natural path of entry of the virus. The method used in the preliminary experiments, therefore, consisted in inoculation of the mucous membranes of the respiratory tract with unfiltered nasopharyngeal secretions of patients in the early stages of measles. The secretions were collected by irrigation of the nasopharynx with 20 to 40 cc. of sterile 0.85 per cent salt solution. Monkeys were inoculated with 5 to 10 cc. of the nasopharyngeal washings by intratracheal injection in order to facilitate retention by the animal of as much of the material as possible. When as much as 5 to 10 cc. was injected a small amount was commonly regurgitated and spread itself over the mucous membranes of the buccal and nasal cavities.

It is appreciated that this method is open to criticism on the ground that many other organisms beside the virus of measles were inevitably introduced into the trachea. It was felt, however, that in most instances these organisms, being largely saprophytic, would be promptly disposed of by the normal respiratory mucous membrane and would not interfere with the ultimate result of the experiment. It furthermore seemed probable that other methods free from the foregoing objection could more satisfactorily be carried out after the susceptibility of the monkey to the supposed virus of measles had been demonstrated and the criteria necessary to establish a positive transmission had been learned. This objection has been met in subsequent experiments by the use of filtered nasopharyngeal washings and of blood shown to be free from ordinary bacteria by culture tests.

The methods of study after inoculation consisted in daily observation of symptoms and inspection of the skin, conjunctivæ, and mucous membranes of the mouth, in the recording of morning and evening temperature (rectal), and daily counts of the white blood corpuscles.

Blood cultures were made at irregular intervals in a variety of media (aerobic and anaerobic) both during the incubation period and during the disease in order to exclude as far as possible the presence of possible intercurrent infections resulting from the introduction of extraneous organisms into the trachea, or occurring independently from other sources. Finally, small sections of skin were excised¹¹ in nearly all animals during the course of the exanthem in order to determine the histological character of the lesion. All animals were observed for a period of at least 3 weeks after inoculation before being discarded as negative. The evidence for a positive transmission has depended, as in the clinical diagnosis of measles, upon the development of the characteristic symptoms and lesions of the disease, the temperature and leucocyte counts having been recorded merely as additional data and not as evidence of a successful inoculation.

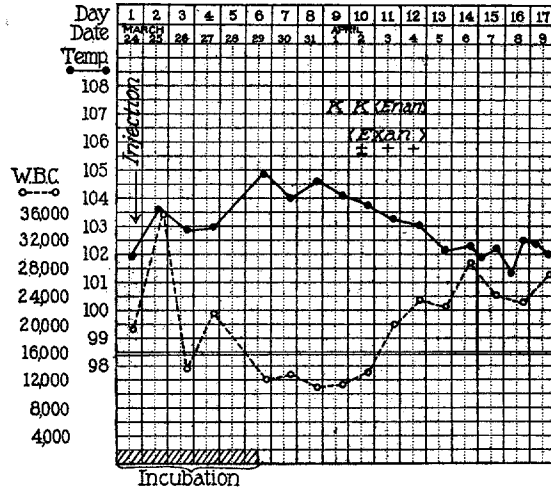
Direct Transmission of the Virus of Measles from Man to Monkeys.

Of ten monkeys inoculated with nasopharyngeal washings from seven patients with measles, eight after an incubation period of 6 to 10 days developed symptoms closely resembling those of measles in man. Of the two monkeys which failed to develop symptoms of measles, one contracted a Pneumococcus Type IV pneumonia with a severe pneumococcus septicemia 24 hours after inoculation and died on the 8th day, while the other failed to show sufficiently definite symptoms to warrant a positive diagnosis and was discarded as negative after 24 days observation. The details of the experiments in which a positive transmission was obtained follow.

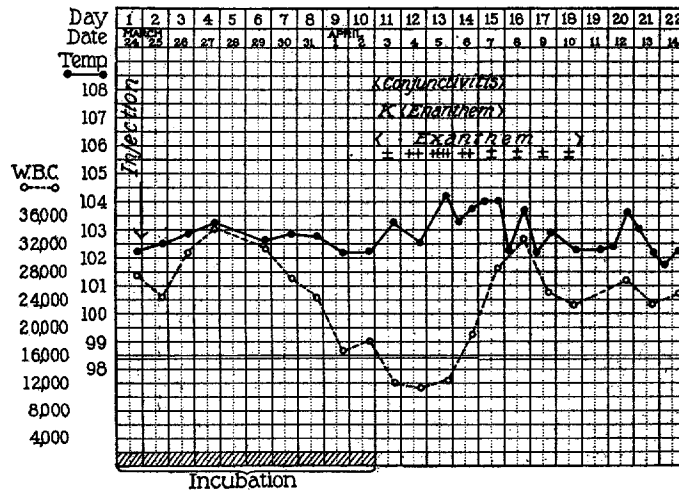
In the first two experiments monkeys were inoculated intratracheally with unfiltered nasopharyngeal washings. In the first instance the secretions were collected from the patient about 1 hour after the first appearance of the exanthem, in the second 6 days before the exanthem appeared.

Experiment 1.—Monkey 2 (Text-fig. 1, a); *Macacus rhesus*. Mar. 24, 1920. Intratracheal injection of 10 cc. of unfiltered nasopharyngeal washings collected from measles patient, Case 1, about 1 hour after the first appearance of the exanthem. Cultures of the washings showed *Micrococcus catarrhalis*, *Streptococcus viridans*, *B. influenzae*, *Staphylococcus pyogenes aureus*, and diphtheroid bacilli.

¹¹ This was always done under anesthesia.



a



b

TEXT-FIG. 1, a and b. Observations on monkeys inoculated with unfiltered nasopharyngeal washings from patients with measles. (a) Monkey 2, Case 1. (b) Monkey 3, Case 2.

The monkey remained well and active until the 6th day when the temperature rose to 104.7° F. and remained elevated for 5 days. The leucocyte count fell on the 6th day and remained low for 5 days. On the 9th day the animal became less active; there was photophobia, and a small, bright red macule appeared on the mucous membrane of the left lower gum. Blood culture showed no growth. On the 10th day drowsiness was quite marked; two more discrete, erythematous spots were present on the labial mucous membrane and a rash consisting of small, discrete, red maculopapules which faded out on pressure appeared on the forehead, cheeks, and neck. On the 11th day the exanthem was more prominent but had not spread to other parts of the skin. The small hyperemic spots on the labial mucous membrane were more numerous but not coalescent. On the 12th day the exanthem was fading and the exanthem was less marked; by the 13th it had disappeared without definite pigmentation or desquamation and the animal again appeared well and active.

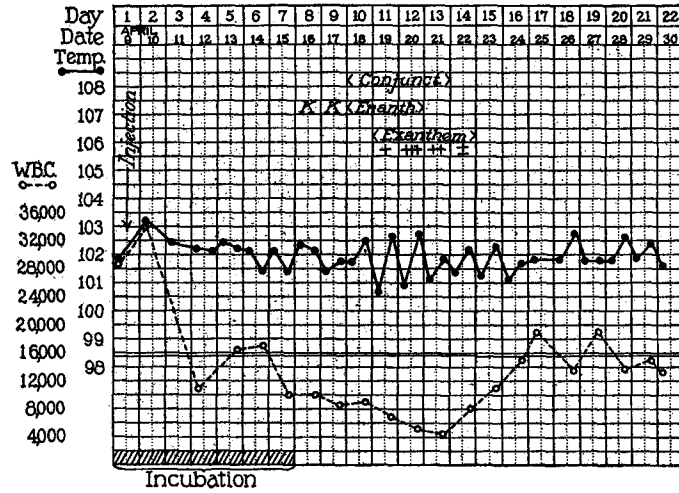
Experiment 2.—Monkey 3 (Text-fig. 1, b); *Macacus rhesus*. Mar. 24, 1920. Intratracheal injection of 10 cc. of unfiltered nasopharyngeal washings collected from measles patient, Case 2, 6 days before the appearance of the exanthem. Cultures of the washings showed *Streptococcus viridans*, *B. influenzae*, *Staphylococcus pyogenes albus*, *Staphylococcus pyogenes aureus*, and diphtheroid bacilli. The animal remained well and active for 10 days. On the 11th day it appeared quiet; the conjunctivæ were markedly congested; a small, bright red macule appeared on the mucous membrane of the upper lip, and in the afternoon a few, small, red, discrete maculopapules appeared on the forehead and cheeks. On the 12th day the conjunctivitis was more marked; there was a moderate, erythematous, granular rash on the mucous membrane of the lips and an abundant, bright red, maculopapular exanthem over the entire face, in places nearly confluent. On the 13th day the animal was weak and drowsy; the exanthem had spread to the flexor surfaces of the arms, forearms, and thighs. On the 14th day the rash had begun to fade. During the 4 following days it gradually disappeared, first from the arms and legs and finally from the face. By the 19th day it had entirely gone, leaving only a yellowish brown pigmentation which lasted for several days and then cleared up. No desquamation was noted. The animal showed a well defined febrile reaction from the 11th to 16th days coincident with the other symptoms. The leucocyte count was low from the 9th to 14th days. On the 3rd day of the exanthem small pieces of skin were excised from the face, left arm, and left thigh. All show the characteristic histology of the measles exanthem, consisting of a proliferative and exudative reaction about the capillaries in the corium. The endothelial cells of the capillary walls are swollen, and numerous endothelial leucocytes are present about the capillaries. A moderate number of these cells are in mitosis, indicating an active multiplication. A few eosinophils, polymorphonuclear leucocytes, and lymphocytes are also present in the pericapillary exudate. There are a few small foci of exudative and degenerative changes in the epidermis. At these points the epithelial cells are swollen and vacuolated, and occasionally show evi-

dence of necrosis. Similar changes are seen in small groups of cells in the hair sheaths and sebaceous glands that lie adjacent to the capillary lesions.

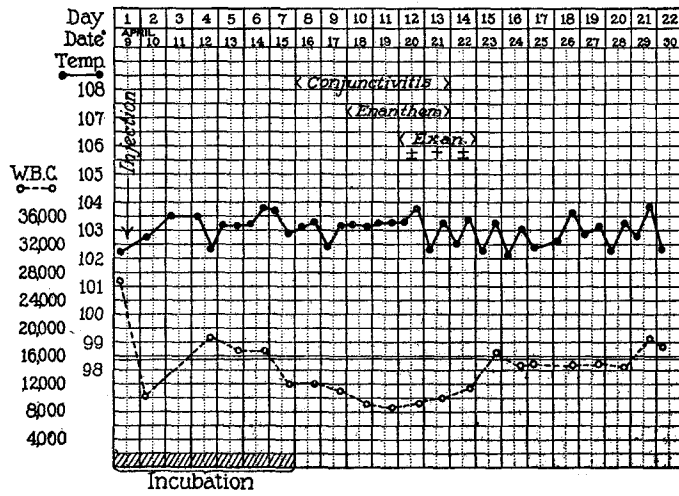
In the next experiment two monkeys were inoculated intratracheally with the pooled nasopharyngeal washings from two patients in the prodromal stage of measles 3 days before the appearance of the exanthem. One monkey received unfiltered washings, the other a portion of the same washings after filtration through a new Berkefeld N filter.

Experiment 3.—Monkey 5 (Text-fig. 2, a); *Macacus rhesus*. Apr. 9, 1920. Intratracheal injection of 10 cc. of pooled unfiltered nasopharyngeal washings collected from measles patients, Cases 3 and 4, 3 days before the appearance of the exanthem. Cultures of the washings showed *Staphylococcus pyogenes albus*, *Micrococcus catarrhalis*, *Streptococcus viridans*, and diphtheroid bacilli. The monkey remained free from symptoms for 6 days. On the afternoon of the 7th day it appeared quiet and drowsy and shivered at times. On the 8th day two small, hyperemic spots appeared on the mucous membrane of the upper lip. On the 10th day the conjunctivæ were slightly congested and a red, punctate, granular rash was present on the labial mucous membrane. On the 11th day a well defined rash consisting of small, discrete, red maculopapules had appeared on the forehead, cheeks, sides of neck, upper chest, lower abdomen, and inside of thighs. The conjunctivitis remained the same; the exanthem was more marked. On the 12th day the exanthem was more abundant; the individual maculopapules were larger, and fresh spots had appeared over the shoulders. The exanthem was fading. The exanthem rapidly faded on the 2 following days. By the 15th day the animal had completely recovered. No pigmentation or desquamation was noted. There was a well defined leucopenia from the 7th to 15th days. Blood cultures made on the 4th and 7th days showed no growth. Sections of skin removed from the face and thigh on the 2nd day of the exanthem show the characteristic histology of measles.

Monkey 6 (Text-fig. 2, b); *Macacus rhesus*. Apr. 9, 1920. Intratracheal injection of 10 cc. of pooled, filtered (Berkefeld N, 20 minutes, 640 mm. vacuum) nasopharyngeal washings collected from measles patients, Cases 3 and 4, 3 days before the appearance of the exanthem. Aerobic and anaerobic cultures of the filtrate showed no growth during 2 weeks incubation except in one of four anaerobic tissue ascites fluid tubes in which a small Gram-negative bacillus, presumably a contaminant, appeared. The monkey remained well and active for 7 days. On the 8th day it showed a moderate conjunctivitis which had increased on the following day. On the 10th day the mucous membranes were congested and showed a moderate, hyperemic, punctate rash on the lips. On the 12th day a few, small, discrete, red maculopapules came out on the forehead, left cheek, and front of the neck. On the 13th day there was a well marked, though sparse,



a



b

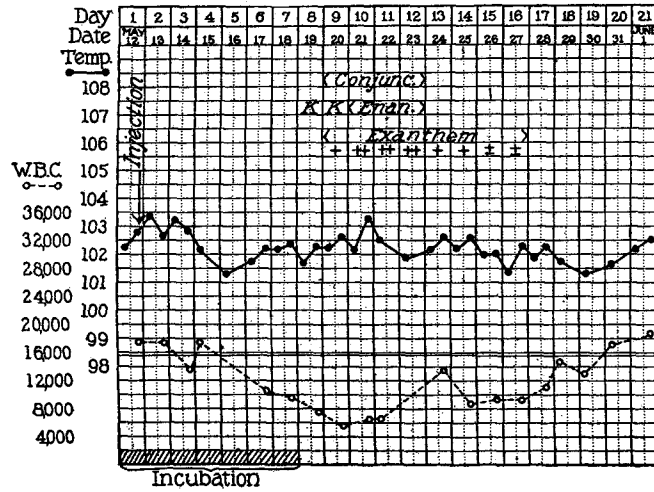
TEXT-FIG. 2, a and b. Observations on monkeys inoculated with pooled nasopharyngeal washings from measles patients, Cases 3 and 4. (a) Monkey 5, unfiltered washings. (b) Monkey 6, filtered washings.

exanthem on the forehead, cheeks, and neck, and fresh maculopapules had appeared on the lower abdomen. On the 14th day the enanthem had disappeared and the exanthem had begun to fade. On the 15th day it had disappeared without desquamation; the animal appeared well and active. There was no febrile reaction. The leucocyte count was low from the 7th to 14th days. Blood cultures on the 2nd, 4th, and 7th days showed no growth. A piece of skin excised from the forehead on the 2nd day of the exanthem shows the typical histological picture of measles. This animal was subsequently reinoculated on June 8, 1920, with material containing another strain of the virus of measles. It failed to react, the control coming down on the 7th day with characteristic symptoms of measles.

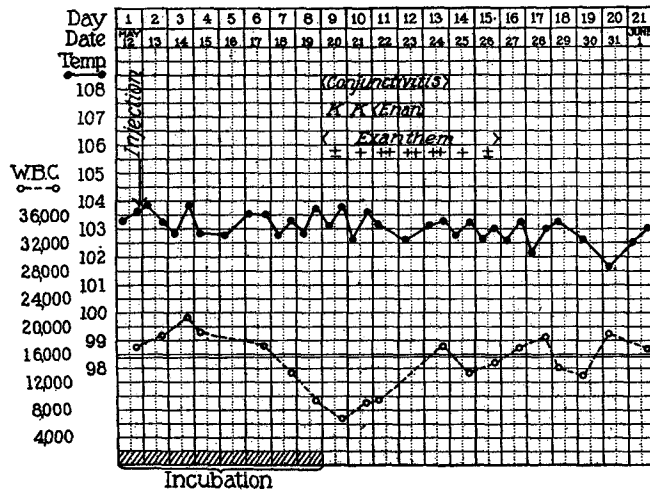
In the following experiment four monkeys were inoculated with different portions of the nasopharyngeal washings collected from a patient with measles about 22 hours after the appearance of the exanthem. One monkey was inoculated on the mucous membranes of the nose and throat with unfiltered washings, one intratracheally with filtered (Berkefeld N) washings, and two intratracheally with unfiltered washings. All developed the characteristic symptoms of measles after the customary incubation period. The protocols follow.

Experiment 4.—Monkey 8 (Text-fig. 3, a); *Macacus rhesus*. May 12, 1920. Inoculated on mucous membranes of nose and throat with 5 cc. of unfiltered nasopharyngeal washings from measles patient, Case 5. Cultures of the washings showed *Staphylococcus pyogenes albus*, *Streptococcus viridans*, and diphtheroid bacilli. The animal remained well for 7 days. On the 8th day it appeared quiet; the tongue was coated and its papillæ were prominent; two small, bright red spots appeared on the mucous membrane of the upper lip. On the 9th day it was quiet and limp; the conjunctivæ were injected; the mucous membranes of the cheeks were congested and a third hyperemic spot was present on the upper lip. A red, maculopapular rash appeared on the inner and posterior sides of the thighs and over the perineum. On the 10th day the exanthem was more intense and had spread to the anterior surfaces of the thighs and lower abdomen. On the 11th day the exanthem on the thighs had begun to fade. Fresh maculopapules were present on the abdomen and on the left cheek. The conjunctivitis and enanthem were less marked. By the 14th day the animal appeared well and the exanthem had nearly faded, leaving a yellowish brown pigmentation. There was a well marked leucopenia coincident with the foregoing symptoms but no definite febrile reaction. A section of skin removed from the thigh on the 2nd day of the exanthem shows the characteristic histological picture of measles.

Monkey 9 (Text-fig. 3, b); *Macacus rhesus*. May 12, 1920. Intratracheal injection of 4.5 cc. of filtered (Berkefeld N, 5 minutes, 600 mm. vacuum) nasopharyngeal washings from measles patient, Case 5. Aerobic and anaerobic cul-



a



b

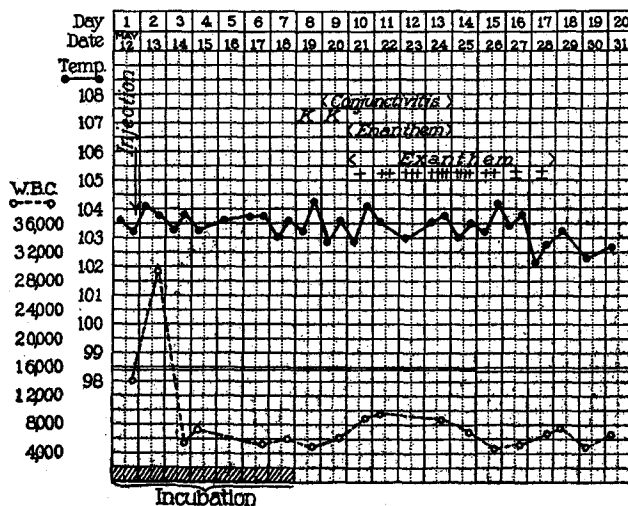
TEXT-FIG. 3, a and b. Observations on monkeys inoculated with nasopharyngeal washings from measles patient, Case 5. (a) Monkey 8, unfiltered washings. (b) Monkey 9, filtered washings.

tures of the filtrate showed no growth after 2 weeks incubation. The animal remained well and active for 8 days. On the 9th day it appeared quiet; the conjunctivæ were moderately injected. On the mucous membrane of the upper lip there was a small, red, granular spot and on that of the left cheek there were three slightly elevated, hyperemic spots with bluish white centers presenting the typical appearance of Koplik spots. A few red maculopapules developed on the skin about the left corner of the mouth. On the 10th day the condition was the same, except for an additional spot on the mucous membrane of the lower lip and fresh maculopapules on the left cheek. On the 11th day there was a well developed, red, punctate, granular exanthem on the mucous membrane of the lips; the exanthem had spread to the forehead, cheeks, and nose. On the 13th day the exanthem had cleared up; the conjunctivitis was less marked; the exanthem on the face was fading. A red, maculopapular rash had appeared on the thighs. During the 2 following days the exanthem faded with a fine, branny desquamation, and the animal again became lively. There was no significant febrile reaction, but a well defined leucopenia occurred from the 8th to 11th days. This animal was reinoculated on June 8, 1920, with material containing the same strain of measles virus after it had been passed through three monkeys. It failed to react, while the control after 6 days incubation period developed the characteristic symptoms of measles.

Monkey 10 (Text-fig. 4); *Macacus rhesus*. May 12, 1920. Intratracheal injection of 5 cc. of unfiltered nasopharyngeal washings collected from measles patient, Case 5. The monkey remained well for 7 days. On the 8th day it was listless and drowsy, shivering slightly; a small hyperemic spot was present on the mucous membrane of the lower lip. The tongue was coated and its papillæ were prominent. On the 9th day the conjunctivæ were inflamed; there was a faint erythematous blush over the face and two fresh red macules were present on the mucous membrane of the upper lip. On the 10th day there was a well developed, red, granular exanthem on the labial mucous membrane; a few, small, discrete, red maculopapules appeared on the left cheek and on the upper arms. By the 13th day the exanthem had reached its height. It consisted of numerous, red maculopapules, 2 to 5 mm. in diameter, irregularly scattered over the face, neck, chest, upper arms, abdomen, and thighs (Fig. 1). On the 14th day the conjunctivæ and mucous membranes appeared normal again; the exanthem on the face and neck was yellowish red and showed a fine desquamation. During the 3 following days the exanthem gradually faded with well marked branny desquamation. By the 18th day the animal again appeared well and active. A section of skin removed from the upper arm on the 1st day of the exanthem shows the typical lesion of measles.

Monkey 11 (Text-fig. 5, a); *Macacus rhesus*. May 12, 1920. Intratracheal injection of 5 cc. of unfiltered nasopharyngeal washings collected from measles patient, Case 5. The animal remained well until the afternoon of the 6th day when its temperature rose from 103.5° to 104.7° F. and it appeared quiet. On the

7th day it appeared listless and drowsy; the temperature remained elevated. Blood culture showed no growth. On the 8th day there was diarrhea; the conjunctivæ were inflamed and there was increased lacrimation; the mucous membrane of the lips was congested and showed two characteristic hyperemic spots; the temperature rose to 105.8° F. On the 9th day a well defined exanthem consisting of small, discrete, red maculopapules appeared about the eyes, on the nose, right cheek, chin, and about the corners of the mouth. The animal was killed for passage of the virus.



TEXT-FIG. 4. Observations on Monkey 10 inoculated with unfiltered nasopharyngeal washings from measles patient, Case 5.

Autopsy.—Grossly negative. Histological sections of the skin, labial mucous membrane, and tongue show the typical lesions of measles. Cultures of the heart's blood showed no growth.

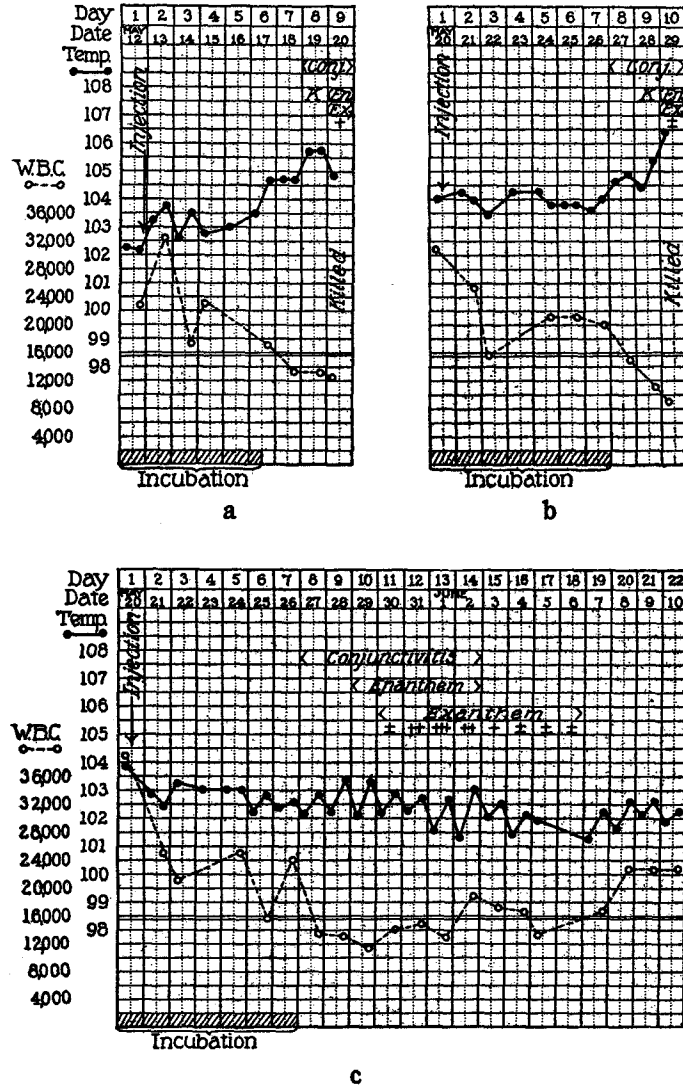
The foregoing experiments have shown that monkeys injected intratracheally with nasopharyngeal washings from cases of measles in the preruleptive and early eruptive stages of the disease react after an incubation period varying from 6 to 10 days with a constant and characteristic group of symptoms closely resembling those of measles in man. These symptoms in brief are as follows: (1) onset with listlessness and drowsiness after a definite incubation period during which the animal appears well; (2) catarrhal conjunctivitis; (3) a well defined and characteristic exanthem usually confined to the labial

mucous membrane; (4) a definite exanthem consisting of discrete, red maculopapules constant in character though somewhat variable in extent and duration and comparable histologically with the exanthem of measles; (5) leucopenia coincident with the foregoing symptoms; (6) prompt and complete recovery after an illness of 7 to 10 days duration. Variations that have occurred in this group of symptoms are ones of degree in the severity of the reaction rather than in character. In only two respects has the reaction shown any significant variation from the symptoms of measles in man; namely, in the inconstant occurrence of a definite elevation of temperature and in the entire absence of symptoms of rhinitis and bronchitis.

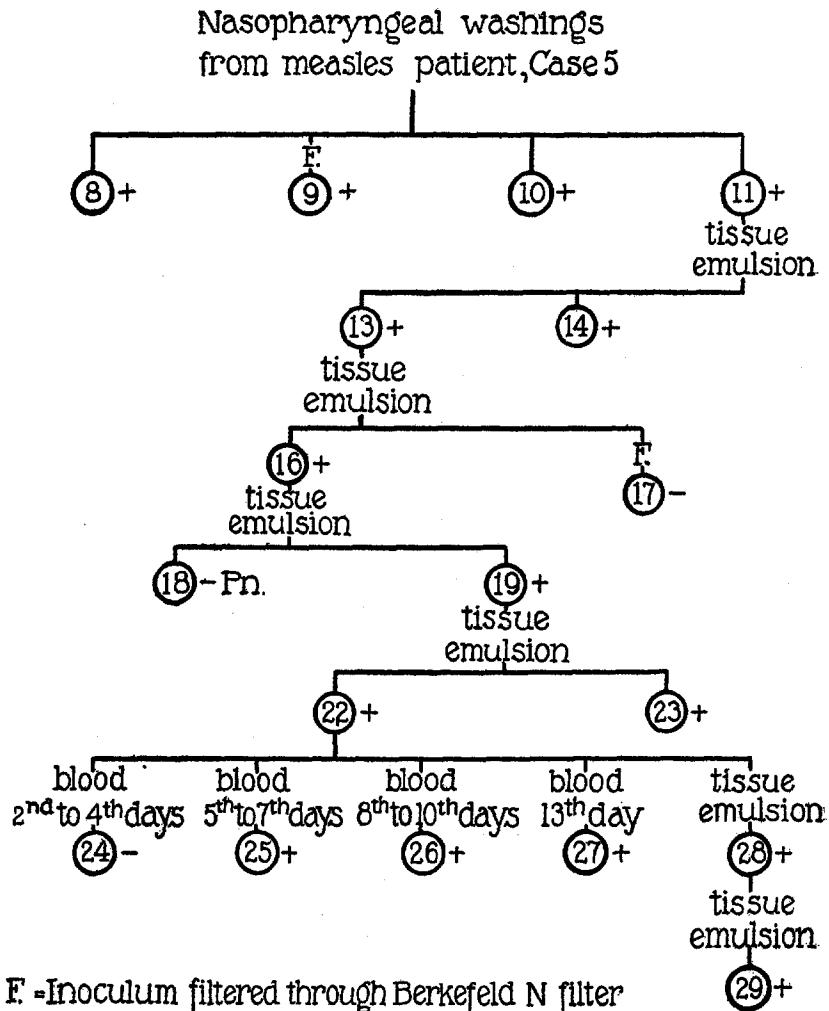
The regularity with which this group of symptoms has developed and the close resemblance of the symptoms to the symptoms of measles are presumptive evidence that the reaction is due to the virus of measles. That the reaction is not due to ordinary organisms of the mouth flora inevitably present in unfiltered nasopharyngeal washings is shown by the occurrence of the same reaction following the inoculation of washings freed from ordinary bacteria by filtration. This, of course, does not exclude the possibility that the reaction might be caused by filterable toxic substances contained in the nasopharyngeal secretions of measles patients rather than by the living virus of measles. This possibility, however, has been excluded by the successful transmission of the infection through a considerable series of monkeys as described below.

Transmission of Measles from Monkey to Monkey by Intratracheal Injection of Tissue Emulsions.

The characteristic reaction which follows the inoculation of monkeys with nasopharyngeal secretions of measles patients has been successfully carried through six passages (Text-fig. 6), by the intratracheal injection of salt solution tissue emulsions prepared from animals killed shortly after the appearance of the exanthem. The principal tissues used were skin and buccal mucous membrane. In some cases bits of spleen, liver, and lung were also employed. In three instances attempted passage failed, presumably due in two to absence of the virus of measles in the material inoculated, in one to the development of a fatal intercurrent infection. The details of the experiment follow.



TEXT-FIG. 5, a to c. Transmission of measles virus, strain from Case 5, from monkey to monkey, by means of tissue emulsions. (a) Monkey 11, inoculated with nasopharyngeal washings from measles patient, Case 5. (b) Monkey 13, first passage. (c) Monkey 14, first passage, duplicate of Monkey 13.



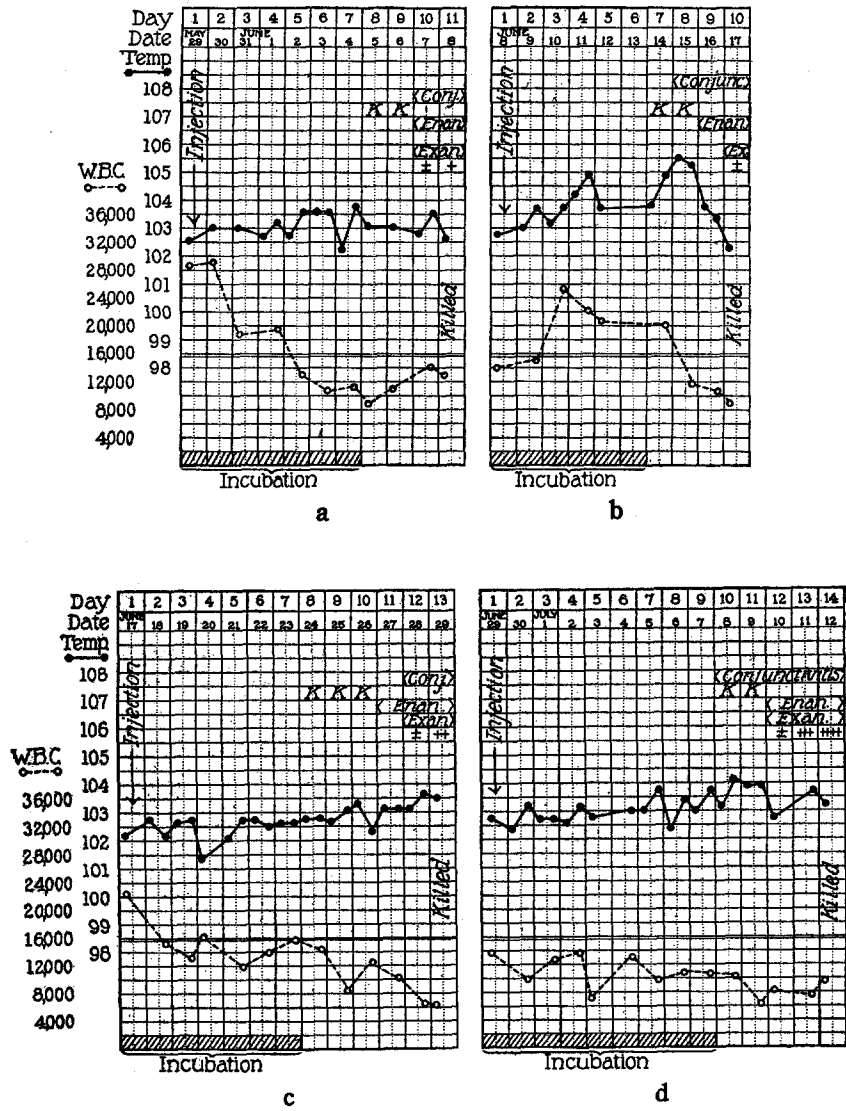
TEXT-FIG. 6. Transmission of measles virus, strain from Case 5, through six animal passages. Monkeys 8 and 23 were inoculated on the nasal and buccal mucous membrane, Monkeys 24 to 27 intravenously, the other monkeys intratracheally. 2nd to 4th days, etc., in Monkeys 24 to 27 indicate the days after inoculation of Monkey 22 on which blood was withdrawn from Monkey 22.

Experiment 5. First Passage.—Monkey 13 (Text-fig. 5, b); *Macacus rhesus*. May 20, 1920. Intratracheal injection of 10 cc. of unfiltered tissue emulsion (skin, spleen, liver, and lung) from Monkey 11. Monkey 11 (Text-fig. 5, a) was killed on the 1st day of the exanthem, the 9th day after inoculation. The hair was shaved from the face, front of chest, abdomen, and thighs, and the skin thoroughly scrubbed with soap and water. The skin was removed from these areas under aseptic precautions, cut into small bits with sterile scissors and ground with small pieces of spleen, liver, and lung in a sterile mortar with sterile sand and 40 cc. of 0.85 per cent salt solution, the whole procedure requiring about 1 hour. The supernatant fluid of this emulsion was pipetted off and used for inoculation without filtration or centrifugation. Cultures of the fluid on blood agar plates showed a few colonies of *Staphylococcus albus*. Monkey 13 remained well and active for 7 days. On the 8th day the temperature rose from 104° to 104.9° F., the conjunctivæ were inflamed, and the leucocyte count was falling. On the 9th day the animal appeared quiet; a few characteristic spots appeared on the mucous membrane of the lips. On the 10th day the temperature had risen to 106.3° F.; there was a well developed, hyperemic, granular, punctate rash on the labial mucous membrane and a few, red maculopapules had appeared on the face. The animal was killed for further transfer of the infection.

Autopsy.—No gross abnormalities. Histological sections of the skin, tongue, and labial mucous membrane show the typical lesions of measles. Aerobic and anaerobic cultures of the heart's blood, spleen, and lung showed no growth.

Monkey 14 (Text-fig. 5, c); *Macacus rhesus*. May 20, 1920. Intratracheal injection of 10 cc. of unfiltered tissue emulsion (skin, spleen, liver, and lung) from Monkey 11 as in the above experiment. The animal remained well for 7 days. On the 8th day it was quiet, showed conjunctivitis and photophobia, and the mucous membranes were congested. No spots were noted. On the 10th day it was drowsy and there was a well developed characteristic enanthem. On the 11th day diarrhea developed; a few small, red maculopapules appeared on the face and thighs. On the 12th day an abundant characteristic exanthem had appeared on the face, neck, chest, shoulders, and thighs. By the 15th day the animal again appeared well; the conjunctivitis and enanthem had cleared up and the exanthem was rapidly fading. Moderate pigmentation persisted for 3 more days and then disappeared. There were a moderate febrile reaction and a well defined leucopenia coincident with the foregoing symptoms. Sections of skin excised from the neck and thigh on the 2nd day of the exanthem show the characteristic histology of measles.

Second Passage.—Monkey 16 (Text-fig. 7, a); *Macacus rhesus*. May 29, 1920. Intratracheal injection of 10 cc. of unfiltered tissue emulsion (skin, spleen, and lung) from Monkey 13 prepared in the same manner as in the preceding experiment. Culture of the supernatant fluid showed a few colonies of *Staphylococcus albus*. After the customary incubation period of 7 days the animal developed the characteristic symptoms of measles, the course of which is indicated on the temper-



TEXT-FIG. 7, a to d. Transmission of measles virus, strain from Case 5, from monkey to monkey by means of tissue emulsions. (a) Monkey 16, second passage. (b) Monkey 19, third passage. (c) Monkey 22, fourth passage. (d) Monkey 28, fifth passage.

ature chart. The enanthem was very abundant, covering the mucous membranes of the lips and cheeks. The exanthem had appeared on the forehead, nose, chin, and left thigh on the 11th day when the animal was killed for further passage.

Autopsy.—Grossly negative except for a few, small, irregular patches of pneumonia about the hilum of the lungs. Culture showed this to be due to a Gram-positive streptococcus of the *viridans* group. Histological sections of the skin and labial mucous membrane show the characteristic lesions of measles.

Monkey 17; *Macacus rhesus*. May 29, 1920. 20 cc. of the tissue emulsion from Monkey 13 were centrifuged at low speed for 10 minutes, the supernatant fluid was diluted with 40 cc. of salt solution and then passed through a Berkefeld N filter (15 minutes, 600 mm. vacuum). Filtration was slow and after about 20 cc. had passed through it was stopped. 10 cc. of the filtrate were inoculated intratracheally. The monkey remained free from definite symptoms and was discarded as negative after 21 days observation.

Third Passage.—Monkey 18; *Macacus rhesus*. June 8, 1920. Intratracheal injection of 10 cc. of unfiltered tissue emulsion (skin, mucous membrane of mouth, spleen, and lung) from Monkey 16. Cultures of the emulsion showed a few colonies of *Streptococcus viridans* and *Staphylococcus albus*. This animal promptly developed a severe pneumonia with *Streptococcus viridans* septicemia followed by multiple arthritis and died on the 21st day without exhibiting any definite evidence of measles.

Monkey 19 (Text-fig. 7, b); *Macacus rhesus*. June 8, 1920. Intratracheal injection of 10 cc. of unfiltered tissue emulsion from Monkey 16 as described above. This animal also developed pneumonia but the disease was mild in character. Blood culture on the 5th day showed no growth and the monkey appeared to have recovered. On the 7th day a few, discrete, hyperemic spots appeared on the mucous membrane of the lips. On the 8th day the animal was quiet; the conjunctivæ were injected; fresh spots had appeared on the mucous membranes of the cheeks. On the 9th day there was an abundant, bright red, granular rash on the mucous membranes of the lips, gums, and cheeks. On the 10th day a few, red maculopapules appeared about the lips, on the chin, and behind the ears. The animal was killed for further passage.

Autopsy.—Grossly negative except for a small patch of pneumonic consolidation in the right lower lobe. Cultures of this area showed *Streptococcus viridans*. Histological sections of the tongue and labial mucous membrane show the typical lesions of measles.

Fourth Passage.—Monkey 22 (Text-fig. 7, c); *Macacus rhesus*. June 17, 1920. Intratracheal injection of 6 cc. of unfiltered tissue emulsion (skin and mucous membranes of lips and cheeks) from Monkey 19. Cultures of the tissue emulsion showed a few colonies of *Staphylococcus albus*, *Streptococcus viridans*, and diphtheroid bacilli. The animal remained well for 7 days. On the 8th day it was quiet; several small, discrete, hyperemic macules with whitish centers appeared on the mucous membrane of the lips. On the 11th day a red, granular rash ap-

peared on the gums. On the 12th day there were moderate conjunctivitis and an abundant enanthem on the mucous membranes of the lips, gums, and cheeks which appeared deeply congested, granular, and covered with minute whitish points. A few, small, red, maculopapules developed about the lips. On the 13th day the exanthem had spread to the arms, abdomen, thighs, and lower legs. The animal was killed for further passage. Blood cultures made daily from the 2nd to 10th days showed no growth.

Autopsy.—Grossly negative. Sections of skin, mucous membrane of the lips, and tongue show the typical histology of measles. Cultures of the heart's blood showed no growth.

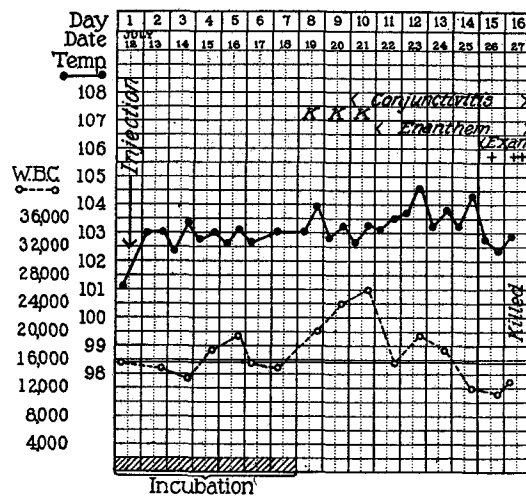
Monkey 23; *Macacus rhesus*. June 17, 1920. Mucous membranes of nose and throat inoculated with 10 cc. of unfiltered tissue emulsion (skin and buccal mucous membrane) from Monkey 19. The animal remained well for 6 days. From the 7th to 14th days it appeared quiet and drowsy. It showed a mild conjunctivitis from the 8th to 14th days with photophobia on the 10th, 11th, and 12th days. A few, discrete, hyperemic macules were present on the mucous membrane of the lips from the 7th to 10th days. No diffuse enanthem and no exanthem appeared at any time. The leucocyte count was low from the 6th to 16th days, varying between 9,460 and 15,740 cells per c.mm., while previous and subsequent counts ranged from 17,460 to 22,800 per c.mm. Although it seemed probable that this animal suffered from a mild infection, the clinical evidence was insufficient to warrant a definite conclusion. Histological sections of the labial mucous membrane, however, show the typical lesion of measles.

Fifth Passage.—Monkey 28 (Text-fig. 7, d); *Macacus rhesus*. June 29, 1920. Intratracheal injection of 6 cc. of unfiltered tissue emulsion (skin and mucous membranes of lips and cheeks) from Monkey 22. Cultures of the emulsion showed a few colonies of *Staphylococcus albus*, diphtheroid bacilli, and a Gram-negative diplococcus. The animal remained well for 9 days. On the 10th day it was listless; the conjunctivæ were injected; a small hyperemic spot appeared on the mucous membrane of the upper lip. On the 11th day several discrete spots of similar character appeared on the mucous membrane of the lower lip. On the 12th day there were a well developed characteristic enanthem and a faint eruption of discrete, red maculopapules over the chin, neck, and inner surfaces of the thighs. On the 13th day there was an abundant, well developed, typical exanthem over the face, neck, shoulders, chest, thighs, and back of lower legs. On the 14th day the condition was the same and the animal was killed for further passage.

Autopsy.—Grossly negative. Cultures of heart's blood showed no growth. Sections of skin, tongue, and labial mucous membrane show the typical histological picture of measles.

Sixth Passage.—Monkey 29 (Text-fig. 8); *Macacus rhesus*. July 12, 1920. Intratracheal injection of 8 cc. of unfiltered tissue emulsion (skin, mucous membranes of lips and cheeks, and piece of tongue) from Monkey 28. Cultures of emulsion showed a few colonies of *Staphylococcus pyogenes aureus*, a non-hemo-

lytic streptococcus, and a Gram-negative bacillus. The animal remained well for 7 days. On the 8th day the temperature rose from 102.9° to 103.8° F.; four discrete hyperemic spots were present on the mucous membrane of the upper lip. On the 10th day diarrhea developed; the conjunctivæ were moderately congested. On the 11th day the conjunctivitis was more marked; a red, granular, punctate rash was present on the mucous membranes. On the 14th day the enanthem was very marked, involving the mucous membranes of lips and cheeks. There were marked conjunctivitis and photophobia. On the 15th day a few, discrete, red maculopapules appeared about the lips. On the 16th day the exanthem was more marked, but had not spread. The enanthem was fading. The temperature had returned to normal. Killed for further passage.



TEXT-FIG. 8. Observations on Monkey 29, sixth passage of measles virus, strain from Case 5.

Autopsy.—Grossly negative. Cultures of heart's blood showed no growth. Histological sections of skin and labial mucous membrane show the typical lesions of measles.

Seventh Passage.—Monkey 30; *Macacus rhesus*. July 27, 1920. Intratracheal injection of 8 cc. of unfiltered tissue emulsion (skin and mucous membrane of lips) from Monkey 29. This monkey showed little evidence of infection. It was killed on the 14th day, however, in an unsuccessful attempt at further passage. It seems probable that Monkey 29 was killed too late for successful transmission.

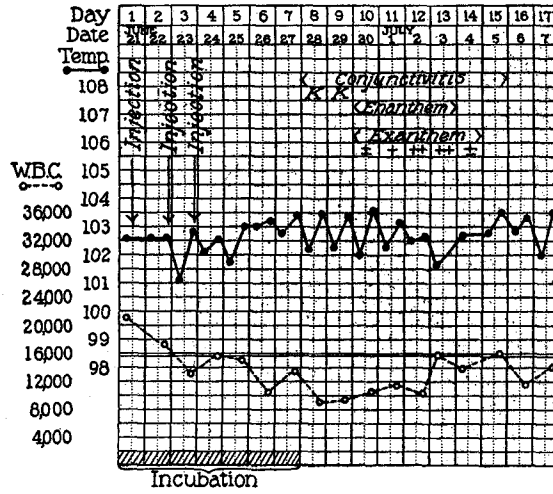
The foregoing experiments have shown that the characteristic group of symptoms which occurs in monkeys following inoculation with nasopharyngeal washings from patients with measles is readily

induced in monkeys by intratracheal injection of salt solution emulsions of the skin and buccal mucous membranes of monkeys killed early in the course of the reaction. The transmission of this group of symptoms through six animal passages makes it highly probable that the reaction is due to the living virus of measles. In the use of unfiltered emulsions of the skin and buccal mucous membranes, as in the use of unfiltered nasopharyngeal washings of patients, other organisms than the virus of measles were unavoidably introduced into the trachea. Although there is no evidence that these bacteria were in any way associated with the characteristic measles reaction, it is obviously desirable to use a method of transmission that will exclude the presence of extraneous organisms as a possible source of error in the interpretation of the results obtained. This was attempted in the case of Monkey 17 by filtration of the tissue emulsion, but without success, since under the conditions of the experiment the virus apparently either failed to pass the filter or was so diluted that it failed to give rise to infection. The desired result has been accomplished, however, by the use of blood.

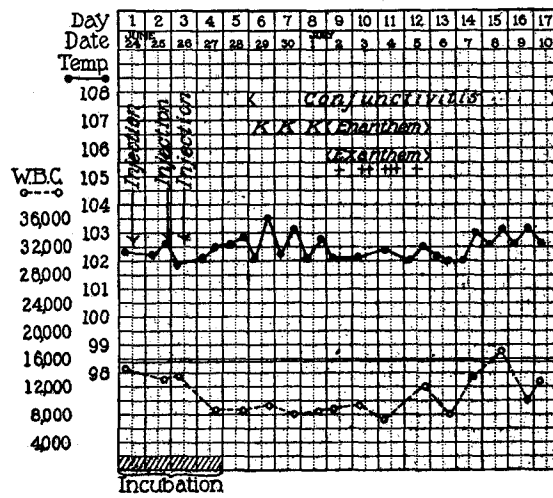
Transmission of Measles from Monkey to Monkey by Intravenous Injection of Citrated Whole Blood.

The clinical course and pathological lesions of measles clearly suggest that the virus is present in the blood stream for at least an appreciable length of time. The experiments of Hektoen, Anderson and Goldberger, and Nicolle and Conseil, if the conclusions of the authors are accepted, support this view. To obtain further knowledge on this subject as well as to eliminate the undesirable features of the method of transmission employed in the passage experiments described above, the following experiment was carried out.

Experiment 6.—Monkey 22 (Text-fig. 7, c), which had been inoculated intratracheally on June 17, 1920, with 6 cc. of unfiltered tissue emulsion from Monkey 19, was bled daily from the 2nd to 10th days after inoculation and again on the 13th day. The blood, which was received into 2 to 3 cc. of sterile 1 per cent sodium citrate solution, after being cultured, was immediately injected intravenously into other monkeys as follows (Text-fig. 6): The 2nd, 3rd, and 4th day bleedings, in amounts of 10, 7.5, and 12 cc. respectively, were injected into Monkey 24. This



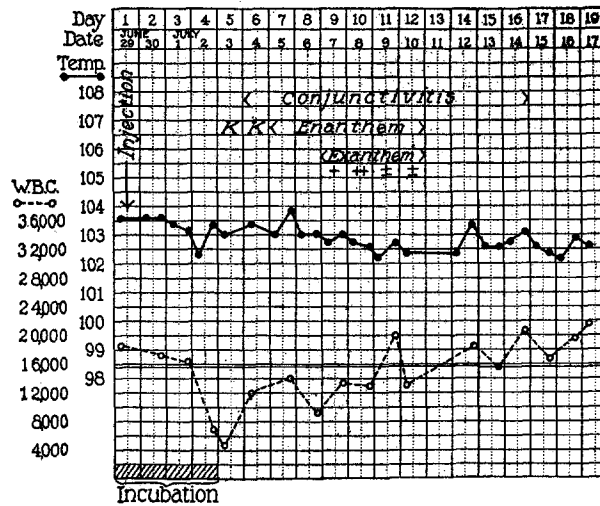
a



b

TEXT-FIG. 9, *a* and *b*. Transmission of measles virus, strain from Case 5, from Monkey 22 by means of whole citrated blood. (*a*) Monkey 25, injected with 5th, 6th, and 7th day bleedings from Monkey 22. (*b*) Monkey 26, injected with 8th, 9th, and 10th day bleedings from Monkey 22.

animal remained free from any symptoms of measles and was discarded as negative after 25 days observation. The 5th, 6th, and 7th day bleedings, in amounts of 9, 8, and 9 cc. respectively, were injected into Monkey 25. This monkey remained well until the 8th day after the first inoculation of blood when it developed the characteristic measles reaction, the course of which is shown in Text-fig. 9, *a*. The 8th, 9th, and 10th day bleedings, in amounts of 12.5, 6, and 13 cc. respectively, were injected into Monkey 26, which fell ill after an incubation period of 4 days with the typical measles symptoms (Text-fig. 9, *b*). The 13th day bleeding, 20 cc., was injected into Monkey 27. This animal likewise showed a typical



TEXT-FIG. 10. Observations on Monkey 27, injected with the 13th day bleeding from Monkey 22. Measles virus, strain from Case 5.

reaction (Text-fig. 10), after an incubation period of 4 days. Cultures of all bleedings from Monkey 22 were made in agar plates. None showed growth. Sections of skin excised from Monkeys 25, 26, and 27, during the period of the exanthem, all show the characteristic histological picture of measles.

The result of the foregoing experiment is important in that it satisfactorily eliminates the objection that can be raised to the preceding passage experiments on the ground that other organisms beside the virus of measles were present in the tissue emulsions employed. It furthermore shows that in monkeys inoculated intratracheally with measles material the virus subsequently enters the blood stream and can be transmitted readily from monkey to monkey

by intravenous injection of whole citrated blood. This observation is of considerable value because it provides a simple method of transmitting the virus from animal to animal in a pure state and affords an opportunity for extensive culture study of a material known to contain the virus of measles and presumably free from other organisms. There are other suggestive points in the experiment which lend support to previous conceptions of the course of measles in man. The failure of Monkey 24 to react suggests that an appreciable period intervenes between the time of infection of the mucous membranes of the respiratory tract and the entrance of the virus into the blood stream. The positive transmission to Monkey 25 shows that the virus had entered the blood of Monkey 22 by at least the 7th day after inoculation, a time which corresponded with the end of the incubation period of the disease and preceded the onset of symptoms by 24 hours. Whether the virus was present in the blood of Monkey 22 on the 5th and 6th days it is impossible to say. It is of interest in this connection that the incubation period in Monkey 25 was 7 days, while in Monkeys 26 and 27 it was but 4 days. This suggests the possibility that the virus was not present in the 5th and 6th day bleedings from Monkey 22. The difference in incubation period, however, may be explained on the assumption that the virus was much more abundant in the blood of Monkey 22 from the 8th to 13th days, which coincided with the active stage of the disease, than from the 5th to 7th days, which coincided with the latter half of the incubation period. The positive results in Monkeys 26 and 27 show that the virus was present in the blood from the onset of the disease until at least the 2nd day of the exanthem. How much longer it may persist in the blood has not as yet been determined. The shortening of the incubation period in Monkeys 26 and 27 from the customary 7 days to 4 days was presumably dependent upon the introduction of the virus directly into the blood stream, since by this method of inoculation the period of several days which probably elapses between the inoculation of the virus on the mucous membranes and its invasion of the blood is eliminated. Although our observations on the infectivity of the blood have so far been made only on the experimental disease in monkeys, it seems probable that similar conditions will be found to obtain in measles in man.

SUMMARY.

By the intratracheal injection into monkeys of unfiltered nasopharyngeal washings from cases of measles in the preruptive and early eruptive stages of the disease a relatively constant group of symptoms was induced which closely resemble those of measles in man. Of seven monkeys inoculated intratracheally with unfiltered nasopharyngeal washings from seven cases of measles, five developed the symptoms. The same group of symptoms was induced in one monkey by inoculation of the mucous membrane of the nose and mouth with unfiltered nasopharyngeal washings from a case of measles. In these experiments a variety of organisms, largely saprophytic inhabitants of the nasopharynx and mouth, were present in the material inoculated. There is sufficient evidence, however, that these organisms were in no way responsible for the reaction, since the same group of symptoms was induced in two monkeys by the intratracheal injection of nasopharyngeal washings from three cases of measles after the washings had been freed from ordinary organisms of the mouth flora by filtration through Berkefeld N filters.

The characteristic group of symptoms which follows the inoculation of monkeys with the nasopharyngeal washings from patients with measles has been successfully carried through six passages by intratracheal injection of saline emulsions of the skin and buccal mucous membranes of monkeys killed from 2 to 6 days after the onset of the reaction. From the fourth passage monkey the reaction was also successfully induced in three monkeys by means of citrated whole blood injected intravenously. This experiment showed the blood to be capable of inciting the reaction from at least the 7th to 13th days after intratracheal inoculation of the donor monkey, but incapable of inducing it from the 2nd to 4th days. Cultures of the blood showed no growth.

The group of symptoms induced has been constant and definite in character. After an incubation period of 6 to 10 days the animal becomes listless and drowsy, the conjunctivæ become injected, and small, discrete, hyperemic macules appear on the labial mucous membrane. These spots increase in number and may eventually coalesce in the course of 2 to 4 days to form a diffuse, red, granular

rash. This rash is usually limited to the labial mucous membrane but may extend to the inside of the cheeks. The individual macules may or may not show the minute bluish white center characteristic of Koplik spots. From one to several days after onset an eruption of small, discrete, red maculopapules appears on the skin, usually coming out first on the face. The rash progressively increases in the number and size of the individual lesions and may in the course of 2 to 3 days extend to the skin of the neck, shoulders, upper arms, chest, abdomen, and thighs. It is constant in character but varies considerably in extent in different animals. By the time the exanthem is fully developed, the rash on the mucous membranes has begun to fade and soon disappears. The exanthem in turn progressively fades, sometimes with a branny desquamation, sometimes without. There may be moderate pigmentation. By the 6th to the 10th day after onset all symptoms have disappeared and the animal again appears well. Coincident with this group of symptoms there is a constant and definite reduction in the total leucocyte count, frequently constituting a true leucopenia. Other symptoms of irregular occurrence are photophobia, diarrhea, and fever. Symptoms of rhinitis and bronchitis have not been noted. Histological sections of the lesions of the skin show an exudative and proliferative lesion about the capillaries of the corium in which endothelial leucocytes are the predominating cells. Mitotic cells are not infrequently present in these areas. The endothelial leucocytes may be seen migrating toward and occasionally invading the epithelial layers of the hair follicles, sebaceous glands, and epidermis. In places the epithelial cells appear edematous and vacuolated, and there is evidence of minute vesicle formation. The lesions of the labial mucous membrane are similar in character. Minute vesicle formation in the epithelium is more frequent and the vesicles occasionally assume a more pustular appearance. Similar lesions are found in histological sections of the tongue. Cultures of the blood made both during the incubation period and during the course of the reaction in a variety of media, aerobic and anaerobic, have consistently shown no growth.

The close similarity of the symptoms and pathological lesions of the reaction to the symptoms and pathological lesions of measles, the successful transmission of the reaction from monkey to monkey,

and the elimination of ordinary bacteria as a possible source of error in the interpretation of the results, warrant the belief that the reaction is caused by the inciting organism of measles.

CONCLUSION.

Monkeys (*Macacus rhesus*) are susceptible to inoculation with the virus of measles.

EXPLANATION OF PLATE 36

FIG. 1. Exanthem in Monkey 10, inoculated with the nasopharyngeal washings from a patient with measles. The drawing illustrates the character and distribution of the lesions on the 3rd day after the first appearance of the exanthem.

