

A USEFUL HEART METHOD.

By CECIL K. DRINKER, M.D.

(From the Laboratory of Applied Physiology of Harvard Medical School, Boston.)

PLATES 83 AND 84.

(Received for publication, February 21, 1921.)

In order to accomplish certain experiments upon the relation of the pulmonary circulation to the air space in the lungs, it became necessary to devise a method in which the heart was exposed and the breathing normal. The procedure described below fulfills these requirements.

Under urethane anesthesia (2 gm. per kilo) and artificial respiration, an elliptical section is cut from the anterior aspect of the thorax of a cat. This piece must be taken out neatly and should leave the uppermost and lowest rib attachments to the sternum and sternal cartilage intact. The heart is then seen beating within the pericardium and the removed section of chest wall should be but slightly larger than the heart itself, so that the organ is framed by the margin of the opening. The anterior aspect of the pericardium is now slit exactly in the midline, and the edges of the pericardial opening attached to the margin of the thoracic window by three strong sutures on either side and one at each extremity. Then, by use of a long continuous suture, the pericardium is sewed to the margins of the window and is thus made to close the opening completely. It will be found to do more than this; that is, there will be a considerable amount of loose pericardial membrane below the heart, a desirable situation since the suturing should not involve serious tension at any point.

The chest wall, which has been closed in this manner anteriorly by the fibrous pericardial membrane, is now stretched laterally by traction on the stay sutures first placed, and superiorly and inferiorly by the stay sutures at the ends of the incision. The retraction so accomplished throws the heart forward where it may be handled with

greater readiness, and takes up the pericardial slack so that a reasonably rigid anterior chest wall is provided. Fortunately, the vessel entering the heart do so posteriorly, and lifting the heart forward in the manner described does not seem to affect its filling. Before discontinuing artificial respiration it is advantageous to withdraw air from the thorax with a syringe in order to assist in the reestablishment of negative intrathoracic pressure.

Fig. 1 shows the preparation as it appears when finished. Obviously one may readily adjust a cardiometer in such a heart technique and manipulate the cardiac vessels, etc., in connection with procedures in which it may be desirable to measure normal respiration at the same time.

Fig. 2 is a record made during the course of an experiment in which a urethanized cat, with heart exposed in the manner described, remained in good physiological condition from 10.35 a.m. to 3.20 p.m., and was then killed with chloroform. The lungs were not edematous at death and the animal would apparently have done well through many more hours.

In this tracing it is noticeable that the blood pressure never reached so high a level after as before operation, and this has invariably been our experience in using the method described. The height attained, however, has always been as great as under artificial respiration, and frequently has exceeded that level. The technique has been employed in the cat alone, but its ease of accomplishment in this animal leaves little doubt of its usefulness in other laboratory animals.

EXPLANATION OF PLATES.

PLATE 83.

FIG. 1. Method of exposing the heart under normal breathing.

PLATE 84.

FIG. 2. Upper tracing, respiration; inspiration written downward; middle tracing, arterial blood pressure; lower tracing, signal magnet $\frac{1}{4}$ minute intervals. Tracing I, normal blood pressure. Tracing II, transition from artificial respiration to normal respiration. Tracing III, condition at 11 a.m. Tracing IV, condition at 12.35 p.m.

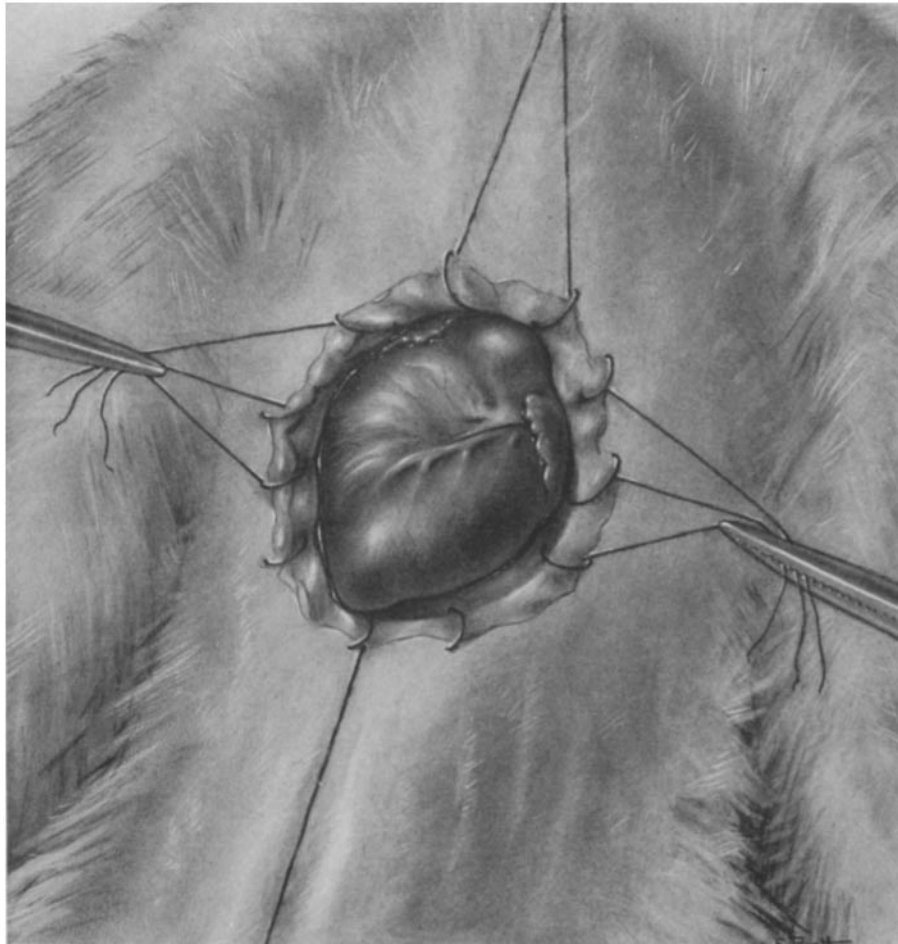


FIG. 1.

(Drinker: Useful heart method.)

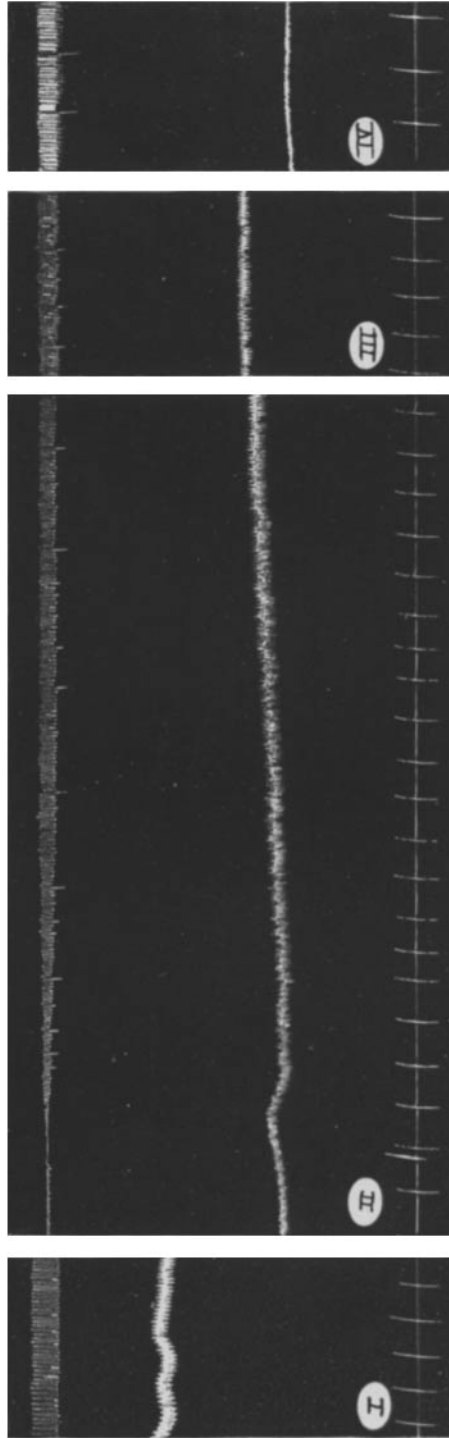


FIG. 2.

(Drinker: Useful heart method.)