

A METHOD FOR THE PERMANENT STERILE DRAINAGE
OF INTRAABDOMINAL DUCTS, AS APPLIED
TO THE COMMON DUCT.

BY PEYTON ROUS, M.D., AND PHILIP D. McMASTER, M.D.

(From the Laboratories of The Rockefeller Institute for Medical Research.)

PLATE 4.

(Received for publication, July 28, 1922.)

There have been many attempts to maintain rubber tubes in connection with the common ducts of animals for the purpose of bile collection over considerable periods of time. They have been so uniformly unsuccessful as to warrant the axiom that such tubes will come away within a few days. This has regularly proved the case in our experience until recently when, happening to leave within the peritoneal cavity a longer portion of the tube than usual, we found it firmly fixed in place although nearly 2 weeks had elapsed. No sign was present of ascending infection along the rubber with destruction of the duct wall next the cannula, which had previously terminated the observations. Instead, the tube was thinly but closely sheathed in omentum which met and joined the common duct, so that the entire collecting apparatus was covered. Elsewhere throughout the peritoneal cavity there were no adhesions. Acting on the suggestion thus presented, we have developed a method whereby the total bile may be collected in a sterile state day after day, during months certainly and probably during years. The method will be described at some length, since it obviously has a wider application than that for which it was devised.

The need for an exact means of bile collection is sufficiently indicated by the fact that major problems in connection with the bile output which were first formulated nearly three generations ago are at this day still unsettled.

Schwann¹ devised in 1841 the fistula method that is still employed in routine studies of the bile. With its aid much has been learnt of the relation of the secretion to body processes. The operation required is nowadays simple, mere severance and ligation of the common duct and cholecystostomy through a separate wound; but the after-care of the animals and the attention required if one is to obtain useful specimens have become no less in the 70 years since Bidder and Schmidt² published their classical observations on fistula bile. Furthermore there are natural limitations to the method which can scarcely be overcome. 24 hour specimens are difficult to obtain unless the animal is suspended in a sling. Dastre,³ it is true, succeeded in keeping a tube in the fistula wound for more than a year in two dogs ("Cholin" and "Cholite"), collecting the bile from day to day into a bag suspended at the neck; but few have attempted to repeat his feat. The fistulous opening in the abdominal wall is often pressed shut by contraction of the abdominal muscles, or that of scar tissue, with a resulting intermittent obstruction and not infrequently reopening of the passage to the intestine, as Schwann himself noted. Usually there is a cholangitis,⁴ and a more or less copious secretion from the ducts mingles with the bile; while if the gall bladder remain normal it cannot but exert a marked influence on the fluid coursing through it.⁵

Of the less used methods of bile collection, that devised by Pawlow⁶ has given highly significant results. It was designed primarily to show the relation of feeding to the delivery of bile into the intestine, and has most value in this connection. A flap of duodenal wall containing the ampulla of Vater is reflected, sewn fast to the skin surface, and the opening in the duodenum is closed. The bile flow may then be directly observed. Pearce and Eisenbrey⁷ have suggested that the bile be diverted into the urine by anastomosis of the common duct with a ureter. And recently Mann⁸ has connected the common duct directly with the body surface by a two stage operation. He reports that the fistula is less likely to close than that of a cholecystostomy.

Method.

The success of our method lies, as already indicated, in the interpolation, with special care for asepsis, of a long drainage tube between

¹ Schwann, T., *Arch. Anat. u. Physiol.*, 1844, No. 2, 127.

² Bidder, F., and Schmidt, C., *Die Verdauungssäfte und der Stoffwechsel*, Milan and Leipsic, 1852.

³ Dastre, A., *Arch. physiol.*, 1890, ii, series 5, 714, 800.

⁴ Pelkan, K. F., and Whipple, G. H., *J. Biol. Chem.*, 1922, 1, 513.

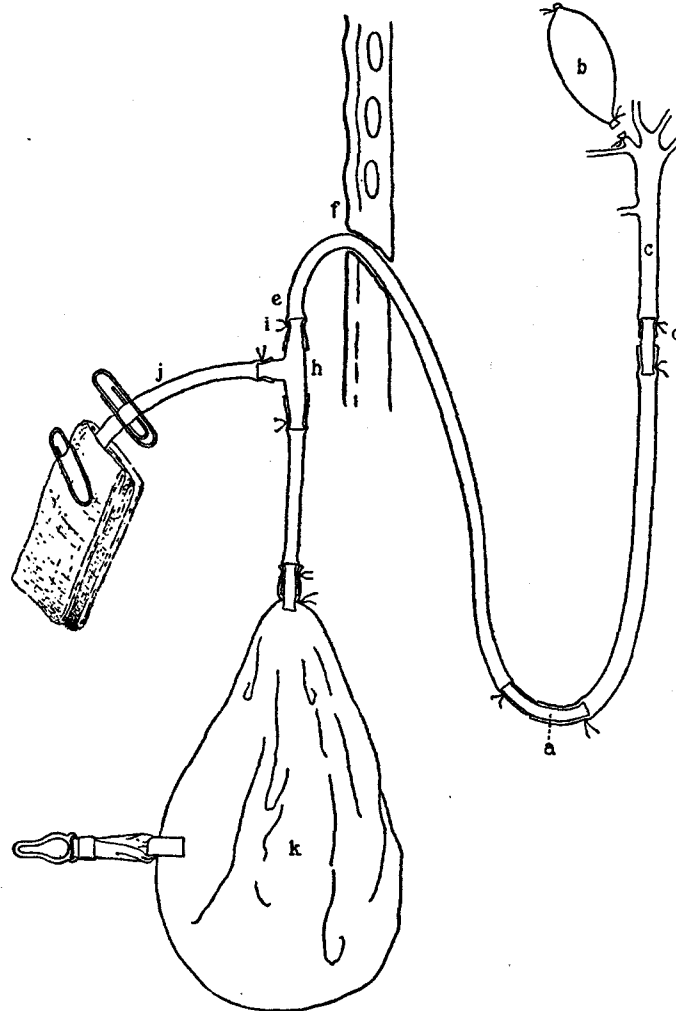
⁵ Rous, P., and McMaster, P. D., *J. Exp. Med.*, 1921, xxxiv, 47.

⁶ Pawlow, J. P., *Arch. Physiol.*, 1887, 452, cited by Langendorff, O., *Ergebn. Physiol.*, 1902, i, pt. 2, 272.

⁷ Pearce, R. M., and Eisenbrey, A. B., *Am. J. Physiol.*, 1913, xxxii, 417.

⁸ Mann, F. C., *J. Lab. and Clin. Med.*, 1921-22, vii, 84.

the common duct and the opening in the abdominal wall. The tube must be pliable near the cannula, else this latter may be pushed askew



TEXT-FIG. 1.

through leverage exerted by the viscera, with obstruction as result; and it must be resistant where it passes the abdominal wall to sustain muscular contraction. To gain these ends a curved glass tube

(Text-fig. 1, *a*) is employed with, on one limb, the soft black rubber tubing that connects with the cannula, and, on the other, a piece of red duodenal tubing that is to pass through the abdominal wall. The entire U of rubber and glass should be as long as the abdominal cavity will readily permit—10 to 12 cm. in a large animal.

With a view to the removal of irritating substances from the surface of the rubber, we have boiled it in a weak solution of sodium bicarbonate, soaked it in weak hydrochloric acid, and washed it well in water prior to autoclaving twice. The cannula (*d*) connecting with the duct (*c*) should be as large as the latter will admit, and blunt ended, with but a slight constriction on the shank.

The skin of the dog is swabbed with iodine followed by alcohol, and, under ether, the common duct and gall bladder are exposed by a right rectus incision. The duct is tied off at once near the intestine to minimize the possibility of infection from this source during the later manipulations; the neck of the gall bladder (*b*) is severed between ligatures placed as far down as possible so as to exclude all bladder mucosa from the duct tract, and the contents of the organ is removed by aspiration, with closure of the needle hole by a purse-string suture. All is now ready for connection of the collecting apparatus. A ligature is laid, but not tied, about the duct just above where it is to be opened. With the aid of long forceps the U-tube with cannula attached is lifted out of the flask of water in which it has been sterilized. In so doing, the black rubber tube should be firmly seized just back of the cannula to close its lumen, else the water within will run out and be replaced by air of dubious sterility. As the tube comes from the flask, its other end is closed with a bulldog clamp; and the whole is at once enveloped in moist, twice sterilized gauze. The duct is cut; the cannula introduced into it without touching the surrounding structures; and the ligature already in place is tied down and supplemented with another. Medium silk is better for the purpose than fine, as having less tendency to cut through. The common duct should now be severed below the cannula and the lower end pulled away from this latter to lessen the danger of a reconstitution of the original channel to the intestine, should obstruction accidentally occur.

To bring the tube out through the abdominal wall, a small stab wound (*f*) is made with a cataract knife obliquely through the tissues just below the rib margin in the mammary line; a sharp-nosed artery forceps is thrust through into the abdominal cavity and the end of the tubing pulled forth. The stab wound should be small enough to hug the tubing closely. The U is now adjusted so that the bend lies well down toward the pelvic basin; the laparotomy opening is closed in three layers; and a dressing wet in 80 per cent alcohol is applied. Over the stab wound there should be only a small dry sponge split to encircle the tubing and dusted with powdered boracic acid.

The free end of the drainage tube is now connected with a rubber bag. This bag (*k*), a rubber balloon of 150 to 300 cc. capacity in the unstretched state, has

been subjected to the same sterilization as the U-tube. During the process it is likely to burst unless kept deflated by a wrapping of gauze. To it there has previously been joined a short length of tubing with a small glass T at the end (*h*), the stem of which bears another piece of tubing (*j*), the eventual outlet tube. The same care is taken to prevent the entrance of air on removal of the apparatus from the sterilization flask as in the case of the drainage tube. Clamps are now placed on the tubing close to the T and this latter is filled with 5 per cent phenol solution. So also is the free end of the drainage tube (*i*) which is then slipped over the open limb of the T and tied on. Prior to removal of the clamp from the drainage tube, the bag should be emptied through the outlet tube of any water it may contain. Afterward the end of the outlet is plugged with cotton wet with phenol solution and covered with a sponge similarly moistened. Ordinary paper clips of wire hold the sponge in place and press the tube shut.

Care is required in the adjustment of the dressings during the first few days to prevent obstruction from a twist or elbow in the tubing. The sponge where this latter emerges from the skin should be changed daily throughout the life of the animal. Given such care the opening will usually remain practically dry even for months, without loosening around the tube or any formation of granulation tissue (Figs. 1 and 2); but lacking it, infection soon ensues, with gaping of the opening and a seepage of thin pus. The laparotomy wound usually heals by first intention. Nevertheless a binder of muslin should be kept on permanently, to which the T-tube is moored with adhesive, as is also a rattan basket to hold the collecting balloon. This basket, oval and shallow, should be large enough to contain all of the drainage apparatus and should be fixed against the side of the animal over the stab wound. The high situation of this latter makes possible the use of male as well as female animals. The end of the outlet tube is brought out between the basket edge and the skin. A many-tailed bandage is put over all, and a snug canvas binder. A saddle of adhesive plaster over the hair of the back prevents slipping of the binders and provides fixed points from which the basket is swung.

Once in each 24 hours the binders are removed, the balloon emptied, the outlet tube plugged again, wrapped in gauze, and the abdominal opening dressed. While the emptying goes on, a clamp should be placed on the drainage tube between *e* and *f* to fend pressure from the duct system when the balloon is squeezed. The whole operation requires only a few minutes.

Lively animals by repeatedly rolling over at a time when the balloon contains bile will sometimes cause it to twist within the basket and thus produce a temporary obstruction. For this reason, balloons of flattened form are preferable to the round. They may be held from turning by a garter clasp attached to one side with adhesive and slipped over a button on the basket rim.

RESULTS.

Thus far we have collected bile by the method from seventeen dogs during periods ranging up to 3 months. When kept on a mixed diet of bread and cooked meat, the animals remain in robust health (Figs. 3 and 4), save for the development of a mild anemia later to be reported upon. In only one case has there been ascending infection along the tube with release of the cannula from the duct; and in this instance the animal had got its bandages off some days previously and pulled much of the tube out, opening it and infecting the bile. Twice the cannula slipped out of the duct end and was displaced 1 to 2 cm., because of loosened ligatures, but the tube of omentum was already so well developed when this occurred that the drainage of bile continued unaffected for some weeks, when cicatricial contraction occluded the short channel in the tissues and caused total obstruction. The general failure of infection to spread upward from the skin surface is the more remarkable because in several of our early experiments the laparotomy and stab wounds became markedly purulent. Sometimes a broad washer of rubber had been placed around the drainage tube just within the peritoneal cavity, to fix it in place, and this washer was at autopsy always found surrounded by pus and encased in massive adhesions. Yet the omental sheath further up along the rubber tube was regularly thin and uninflamed, with a smooth and glistening inner surface. Most interesting was the nature of the connection developed between duct and cannula after the collecting apparatus had been in place for some weeks. It was no longer a union by ligatures but by a thin tube of scar tissue joining with the duct and closely embracing the cannula. Only when it was cut through were the ligatures found, lying free and loose next the glass. So closely did the scar tissue hug this latter that even the pressure from a total biliary obstruction produced by clamping the drainage tube caused no leak or extension of bile along the cannula until several days at least had elapsed. Then in some instances bile penetrated between the tube and omental sheath with an eventual rupture of the latter and bile peritonitis.

Cultures of the bile were made daily in bouillon and on agar plates; and the sediment of centrifugated specimens that appeared sterile

was at intervals stained and searched. Infection of the fluid occurred sooner or later in ten of the seventeen dogs, though always with pure cultures of organisms that behaved as harmless saprophytes. In three of the instances mentioned, the infection resulted from damage to the collecting system by the animal. The circumstances under which it developed in most of the others are suggestive of infection through the blood stream. Once it was terminal in a dog that yielded sterile bile for 3 months before dying of intestinal obstruction; once it appeared in association with the prostration of a severe bronchitis; in another case it developed immediately after hard exercise on a treadmill; and twice it came early in association with a purulent laparotomy wound. We incline to the belief that in the remaining two instances careless handling of the outlet tube was responsible for the contamination. Certainly most dogs in good condition and with well healed abdominal wounds will be found to yield week in and week out a bile that is sterile.

With drainage of the bile carried on as described, there is no danger of a reopening of the pathway to the intestine unless obstruction occurs. And in our experience it has not happened even then. In instances without obstruction, the bile passages remain normal and narrow; while in obstructed ones there are the findings characteristic of stasis without infection by pathogenic organisms. Two causes of eventual obstruction have been encountered—the cicatricial contraction already mentioned that follows upon slipping of the cannula, which interfered twice; and calculus formation in the cannula, which thrice led after some weeks to a complete biliary stasis. In the other twelve instances bile secretion and collection continued over long periods until terminated by accident, or intercurrent disease, or the investigative needs.

Obstruction to the neck of the normal gall bladder is known to be followed by a gradual lessening in size of the organ which after a time contains merely a little pale, semisolid mucus.⁹ This was the regular finding in our animals.

The amount of bile present in the tube system and not evacuated when the balloon is emptied—between 2 and 3 cc. in our experiments—had, of course, to be taken into account in the quantitative work.

⁹ Mignot, cited by Aschoff and Bacmeister, who confirm the observation (Aschoff, L., and Bacmeister, A., *Die Cholelithiasis*, Jena, 1909).

DISCUSSION.

The original bile fistula operation of Schwann¹ was devised by him to determine whether bile is essential to life. And the results of the operation led him to conclude that this was the case. Later observations with animals fed a fat-free diet have made the point debatable. Dastre's³ animals were still vigorous at the end of a year. But, as Hooper and Whipple¹⁰ well point out with regard to similar findings in human beings with bile fistulas, there is no certainty that some bile did not reach the intestine, since autopsy findings are not available. These latter authors hold that the presence of a very little bile in the intestinal tract of dogs suffices for good health; but that total absence of it is not withstood, unless a diet which includes liver is fed, and even then the animals become sparely nourished. Our first dogs did indeed lose weight rapidly, and this despite liver feeding. But in proportion as the method of drainage has been perfected, so has the condition of the animals bettered; and it is now certain that dogs on a mixed diet that is poor in fat and includes no liver remain vigorous and keep their weight during many weeks, though totally deprived of bile (Figs. 3 and 4). Practically always, though, as already stated, a moderate anemia develops early, with gradual and imperfect recovery later on. The cause of the blood changes will be the subject of a later communication.

SUMMARY.

The sheath of omentum that forms about a long rubber tube left within the peritoneal cavity provides so efficient a barrier to ascending infection that such a tube can be employed for the permanent drainage of the common duct, whereas a short tube will regularly come away after a few days. A method is described whereby the total bile of a considerable number of dogs has been obtained in a sterile state during periods up to 3 months. Save for some anemia, the animals remained in good health throughout. The method has obvious uses in connection with the collection of other secretions.

¹⁰ Hooper, C. W., and Whipple, G. H., *Am. J. Physiol.*, 1916, xl, 332.

EXPLANATION OF PLATE 4.

FIG. 1. The exit point of a drainage tube 86 days after intubation, to show the absence of reaction. The white material on and about the tube is powdered boracic acid.

FIG. 2. The characteristic sheath enclosing the portion of the drainage tube within the peritoneal cavity. The picture shows the point at which the tube passes through the parietal peritoneum. From an animal killed 25 days after the intubation.

FIGS. 3 and 4. Dogs with the collecting apparatus in place. The photographs, taken 40 days after operation, show the good general condition of the animals, and the freedom of motion permitted by the apparatus.

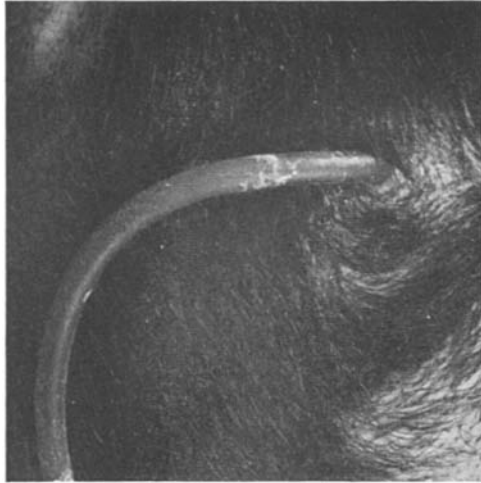


FIG. 1.



FIG. 2.

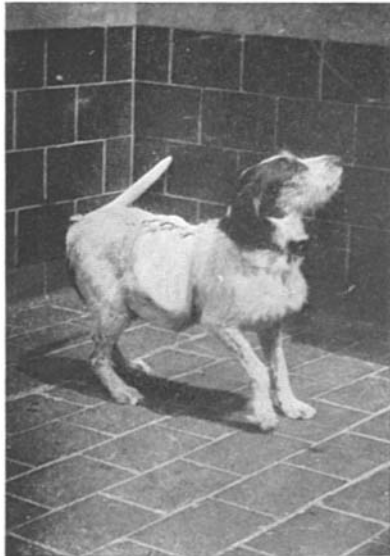

FIG. 3.



FIG. 4.

(Rous and McMaster: Sterile drainage of intraabdominal ducts.)