

BRAIN LESIONS OF THE DOMESTIC RABBIT.

By JAMES E. McCARTNEY, M.D.

(From the Laboratories of The Rockefeller Institute for Medical Research.)

PLATES 4 TO 8.

(Received for publication, June 27, 1923.)

In recent years the domestic or laboratory rabbit has come into increasing use for the study of experimentally induced lesions of the meninges and brain. This has been notably the case in connection with the investigations first of epidemic (lethargic) encephalitis and next of febrile herpes. The conflicting results obtained by different investigators and the divergence, sometimes very wide, of their deductions have brought the experimental animal itself under a measure of suspicion. This particular aspect of the subject has been reviewed by Dr. Flexner to whose paper¹ I refer those wishing to pursue the subject in some detail.

It was at Dr. Flexner's suggestion that, along with certain cultivation studies which were being made with the so called viruses of epidemic encephalitis and febrile herpes,² I undertook the examination of a large number of rabbit brains for the presence of lesions previously described by Bull³ and Oliver⁴ as existing in these animals before experimental inoculations had been made. The rabbits studied were taken from many sources—the laboratory stock regarded as healthy, others dying of snuffles and affections while under observation preparatory to experimental use, as well as animals which were employed for experimental purposes (tumor transplantation, *Treponema pallidum* inoculation, etc.). The total number of brains taken from these animals was 372.⁵ The brains were removed *in*

¹ Flexner, S., *J. Am. Med. Assn.*, 1923, lxxxii, 1688, 1785.

² McCartney, J. E., *J. Exp. Med.* (in press).

³ Bull, C. G., *J. Exp. Med.*, 1917, xxv, 557.

⁴ Oliver, J., *J. Infect. Dis.*, 1922, xxx, 91.

⁵ I am indebted to Dr. Wade H. Brown and Dr. Louise Pearce for sections of a number of rabbit brains.

toto and then dissected so as to provide portions of the forebrain, midbrain, and medulla. Complete transverse sections were made of the midbrain in many instances, but sections of only selected areas, such as the cortex or basal ganglia, in others. These parts were cut in the usual manner after hardening in either Zenker's fluid or in 10 per cent formalin diluted with normal saline solution. Some of the brains were frozen immediately after removal from the rabbit's body and then sectioned. All the sections were stained with hematoxylin and eosin, but some showing lesions were stained in addition by Giemsa's method. In other words, the brains were dealt with in the manner of specimens coming from animals in which definite experiments had been carried out to induce encephalitis.

Possibly it was this extended and rather complete exploration of the brain which accounts for the high percentage of lesions detected.

Results of Examination.

The lesions found in the brains of these rabbits are characterized chiefly by the presence of infiltration with mononuclear cells and less often by peculiar localized necrosis. The infiltrative changes may be classified, depending on the location, into four types: (*a*) perivascular, (*b*) meningeal, (*c*) cerebral, and (*d*) under the ependyma of the lateral ventricles.

This classification does not separate the lesions into hard and fast groups, as, in given cases, infiltrations in all four sites may occur together with localized necrosis. Usually the perivascular, meningeal, and cerebral types of lesions are found in the same case, but in others one of the types may predominate.

Of the class of infiltrative lesions, the histopathology noted in each of the groups is as follows:

(*a*) *Perivascular Lesion*.—This is the commonest and most striking pathological picture observed. The perivascular infiltration may vary from a single layer of mononuclear cells to a thick, dense sheath which, at times, almost obscures the blood vessel. Often the Virchow-Robin spaces surrounding the vessel may be filled with such cells, which are small, round, and deeply staining (Figs. 1 to 6).

(*b*) *Meningeal Lesion*.—Meningeal involvement is not quite so common as the perivascular, and consists of infiltration into the pia-

arachnoid of mononuclear cells. The cellular reaction is often so marked that there is a broad band of cells on the surface of the brain from which proceed finger-like masses of cells dipping into the brain tissue and surrounding the blood vessels. These changes may occasionally be slight, but definite, and appear as a few cells lying apparently between the pia and the brain surface (Figs. 4, 5, 6, and 16).

(c) *Cerebral Lesion*.—Changes in the cerebral substance are more common than those in the meninges, and are only slightly less frequent than the lesions occurring around the vessels. They are usually associated with the latter. There is an infiltration with mononuclear cells which may be diffuse, cells being scattered throughout the tissue. Or, more often, there are focal aggregations of cells distributed irregularly throughout the brain. These foci are sometimes large enough to be seen with the naked eye in the stained specimen. As a rule, the neighboring blood vessels show marked perivascular lesions (Figs. 5, 9, 10, 13, and 16).

(d) *Lesion under the Ependyma of the Lateral Ventricles*.—This picture is seen least often. It may be found only in the forebrain. If care is taken in differentiating the mononuclear cells from nerve cells present in this region, a more or less dense layer of the mononuclear cells is noted immediately underneath the ependyma (Figs. 7 and 8).

Lesions with Necrosis.—In 15 per cent of the total number of brains examined, there appeared, in addition to the infiltrative changes, localized necrotic areas of peculiar structure. The center is definitely necrotic and contains granular débris. Surrounding this is a zone of cells, each having a large, faintly staining nucleus with an open chromatin network in which is a well defined nucleolus. The cells in relation to the necrotic center are phagocytic and are filled with deeply staining granular detritus. Around this cellular zone is a layer of varying thickness of mononuclear cells. The adjacent blood vessels show rings of similar cells. Under higher magnification an increase of glial tissue surrounding the lesion may be seen, simulating a capsule. If the section is not cut through the center of the necrotic focus, the inner, larger, epithelial-like cells and the surrounding ring of mononuclear cells only are manifest.

In some sections, smaller foci are observed, while in others, a process of healing with definite scar tissue occurs. Occasionally groups of four or five of the epithelial-like cells, without any mononuclear infiltration, may be noted as small islands in the brain substance (Figs. 11 to 16).

TABLE I.
Distribution and Incidence of Cerebral Lesions.

Source of rabbits.	Marked.	Slight.	Negative.	Total.
Transplantable tumor.....	63	10	73	146
Per cent.....	43	7	50	
Total per cent positive.....	50			
<i>Treponema pallidum</i> inoculation.....	28	5	49	82
Per cent.....	34	6	60	
Total per cent positive.....	40			
Uninoculated stock.....	23	8	21	52
Per cent.....	44.5	15.5	40	
Total per cent positive.....	60			
Miscellaneous diseases.....	30	5	15	50
Per cent.....	60	10	30	
Total per cent positive.....	70			
Snuffles.....	32	0	10	42
Per cent.....	76		23	
Total per cent positive.....	76			
Total.....	176	28	168	372
“ per cent.....	47.5	7.5	45	
Total per cent positive.....	55			

Table I shows the distribution and incidence of these lesions and the condition of the rabbit in which they were found. The histopathology is recorded as marked and slight. The marked lesions are easily discernible; the slight ones are definite though less frequent but indicate distinct pathological change.

From this table it is apparent that the lesions of meningoencephalitis were present in more than half (55 per cent) of the 372 rabbits examined, of which none was injected intracerebrally. The incidence of cerebral changes in animals inoculated with a transplantable tumor, or with *Treponema pallidum* materials, and normal rabbits was approximately the same (40 to 60 per cent). In the animals suffering from miscellaneous diseases such as pneumonia, septicemia, and subcutaneous abscesses, the percentage was higher, reaching 70 per cent. In rabbits ill with snuffles, 76 per cent were affected. 47.5 per cent of the 372 rabbits showed marked changes.

Inoculation of Cerebral Tissue, Containing Lesions, into Other Rabbits.

Fifteen young rabbits (800 to 900 gm.) were inoculated intracerebrally, after etherization, with 0.25 to 0.35 cc. of suspensions of ground brain tissue obtained from ten rabbits. These latter revealed the cerebral lesions in frozen sections made just prior to use. In none of the fifteen animals were any symptoms noted. They were killed at periods from 14 to 30 days after inoculation and the brains were sectioned and examined. Three exhibited typical changes in the brain, but no conclusions could be drawn, since uninoculated animals of the same size and weight, used as controls, also showed similar pathological conditions.

Cultivation Tests.

Brains were removed from rabbits under aseptic conditions and frozen sections were made. If lesions were present, cultures were made of the brain in a variety of media consisting of ordinary dextrose broth, blood agar in aerobic and anaerobic plates, and Smith-Noguchi medium. In none of these materials was any visible growth obtained.

DISCUSSION.

It appears that approximately one-half of the 372 rabbits examined show particular lesions in the brain. They consist of mononuclear infiltration, either surrounding the blood vessels, under the ventricular wall, throughout the meninges, and in the cortex, or, more frequently, in more than one of these areas. In addition, peculiar necrotic

structures are present in the cortical brain substance. This percentage is maintained not only in animals which are normal by a complete histological examination, but also in rabbits inoculated with a non-infective, transplantable tumor, and in those in the early stages of experimental syphilis. The proportion of animals showing such lesions is increased in the miscellaneous disease group; in the snuffles series more than three-fourths may exhibit evidences of a meningoencephalitis. It has been shown in another paper⁶ that in ordinary stock animals free from nasal discharge, about 25 per cent exhibit chronic sinusitis. On the other hand, snuffles is not the only factor, as animals free from any sinus or mastoid infection and in which no evidence of disease can be found macroscopically may show pronounced cerebral changes. Furthermore, in the disease group, which does not include snuffles but other infections, such as coccidiosis, subcutaneous abscesses, and pneumonia, there is also a higher percentage of brain involvement than in the normal. However, the presence of a transplantable tumor, or early experimental syphilis, does not materially affect the proportion in which these changes are found. Attempts at transmission and cultivation of brain tissue showing these lesions have failed to yield positive results.

The frequent occurrence of accidental lesions of a wide variety in the brain of the laboratory rabbit should have an important bearing on the interpretation of experimental results based on the presence of similar cerebral changes in this animal. This is strongly emphasized by Dr. Flexner,¹ and an examination of the literature supports this view.

For example, Reasoner⁷ noted, in experimental syphilis of the rabbit, meningeal and perivascular infiltration with mononuclear cells, associated with focal necrotic areas in the cortex. Indeed, these changes are described as specific for this experimental disease. In Fig. 6 of Reasoner's paper, a meningitis is shown; in Fig. 7 a focal necrotic lesion; and in Fig. 8 a perivascular infiltration labelled "characteristic syphilitic blood vessel." If a comparison be made between these photographs and Figs. 2 to 7, 11 to 14, and 16 of the present article, it appears that normal rabbits, those inoculated with a transplantable tumor, and those suffering from snuffles or other diseases, reveal practically the same pictures.

⁶ McCartney, J. E., and Olitsky, P. K., *J. Exp. Med.*, 1923, xxxviii, 591.

⁷ Reasoner, M. A., *J. Am. Med. Assn.*, 1916, lxvii, 1799.

Moreover, Bull³ presents photographs (Figs. 12 to 17) of brains from rabbits which succumbed to bacillary infection or were killed during a streptococcus infection, in which the perivascular infiltration, the meningitis, and the focal necrotic lesions are definitely exhibited. So does Oliver,⁴ whose illustrations (Figs. 1 and 2) of meningeal, perivascular, and cerebral necrotic lesions were taken from supposedly healthy rabbits of the laboratory stock. It is therefore apparent that these cerebral changes can hardly be considered as specific manifestations of experimental syphilis in the rabbit.

Recently a number of investigators have reported the experimental production of lesions of the meninges and brain by inoculating rabbits with the so called viruses of epidemic (lethargic) encephalitis and of febrile herpes. Their conflicting results are probably due to a lack of recognition of spontaneous or accidental cerebral lesions in this experimental animal.

For example, Loewe and Strauss⁸⁻¹³ report that the cerebral changes which consist chiefly of a meningeal and perivascular mononuclear infiltration associated with areas of necrosis surrounded by a zone of mononuclear cells indicate the action of the so called virus of encephalitis lethargica. They obtain similar results with their supposed cultures of this material. They point out that in doubtful cases of the disease in man, the intracerebral inoculation of the patient's spinal fluid in the rabbit results in the same lesions, which suffice for a diagnosis of epidemic encephalitis. These observers are supported by Thalhimer.¹⁴ Now, if a comparison is made of Loewe and Strauss' photographs of the meningitis (Fig. 8 of their article¹³), the perivascular infiltration (Figs. 9, 10, 12, 13, 14, and 15 of the same article, Fig. 4 of another of their papers¹¹), the focal infiltration with mononuclear cells (Figs. 11 and 13 of the first article¹³), the focal necrotic areas (Fig. 10 of the same article), together with Figs. 4 to 8 of Thalhimer's series,¹⁴ with Figs. 1 to 16 illustrating the present paper, it will be observed that the same kind of lesions can occur in supposedly healthy animals, or in those employed for a variety of experimental purposes other than for intracerebral inoculation. A further comparison may be made with the photographs of similar conditions in animals free from the so called encephalitic virus presented by Bull³ and by Oliver⁴ and to which reference has already been made.

⁸ Loewe, L., Hirschfeld, S., and Strauss, I., *J. Infect. Dis.*, 1919, xxv, 378.

⁹ Loewe, L., and Strauss, I., *J. Am. Med. Assn.*, 1920, lxxiv, 1373.

¹⁰ Loewe, L., and Strauss, I., *J. Am. Med. Assn.*, 1919, lxxiii, 1056.

¹¹ Loewe, L., and Strauss, I., *J. Infect. Dis.*, 1920, xxvii, 250.

¹² Acute epidemic encephalitis. An investigation by The Association for Research in Nervous and Mental Diseases, New York, 1921.

¹³ Loewe, L., and Strauss, I., *Proc. New York Path. Soc.*, 1920, xx, n.s., 18.

¹⁴ Thalhimer, W., *Arch. Neurol. and Psychiat.*, 1922, viii, 286.

Kling and his coworkers¹⁵⁻²⁰ also emphasize the presence of the cerebral lesions in the rabbit as evidence of the experimental transmission of epidemic encephalitis and of febrile herpes. In describing the histopathology, they state: Epidemic encephalitis is characterized not only by perivascular lesions but also by chronic foci having a necrotic center with epithelial cells and surrounded by lymphocytes.²⁰ Kling¹⁷ reports that from 50 to 60 per cent of the inoculated rabbits reveal these cerebral changes. On the other hand, of the present series of 372 brains from a supposedly normal, laboratory stock of animals and from those not inoculated intracerebrally or with encephalitic or herpetic materials, 55 per cent show a similar histopathologic condition. This can readily be seen by comparing the photographic reproductions of what Kling and his coworkers regard as specific encephalitic changes as shown in their Figs. 1, 3, 4, 5, 8,¹⁸ Figs. 1, 2, and 4,¹⁹ and in others,¹⁵ with Figs. 1 to 7, 13, and 16 of this article. In the figures of the present article can be seen precisely similar meningeal and perivascular infiltrations, and focal mononuclear lesions. The peculiar necrotic area which they consider as pathognomonic of experimental encephalitis (their Fig. 1²⁰), and which consists of a central necrotic area containing epithelial-like cells surrounded by a zone of mononuclear cells, was found in 15 per cent of the rabbits, supposedly normal or not inoculated with encephalitic materials. An identical lesion can be observed in Figs. 11 to 16, presented herewith, and taken from a supposedly normal stock rabbit, from one with snuffles, from three with a transplantable tumor, and from one in the early stages of experimental syphilis.

This study leads to the conclusion that the cerebral lesions found so frequently in the domestic rabbit are preexisting; that is, they are present before any experimental procedure is begun. Many suggestions have been made regarding their origin. Wright and Craighead²¹ in 1922 described a protozoon which they consider to be the cause of infectious motor paralysis of young rabbits. This organism in turn agrees in part with the *Encephalitozoon cuniculi* described

¹⁵ Kling, C., Davide, H., and Liljenquist, F., *Compt. rend. Soc. biol.*, 1921, lxxxiv, 815; lxxxv, 823.

¹⁶ Kling, C., *Hygiea, Stockholm*, 1922, lxxxiv, 894, 913.

¹⁷ Kling, C., *Wien. Arch. inn. Med.*, 1923, vi, 101.

¹⁸ Kling, C., Davide, H., and Liljenquist, F., *Hygiea, Stockholm*, 1921, lxxxiii, 705.

¹⁹ Kling, C., Davide, H., and Liljenquist, F., *Hygiea, Stockholm*, 1921, lxxxiii, 566.

²⁰ Kling, C., Davide, H., and Liljenquist, F., *Compt. rend. Soc. biol.*, 1922, lxxxvii, 1179.

²¹ Wright, J. H., and Craighead, E. M., *J. Exp. Med.*, 1922, xxxvi, 135.

by Levaditi, Nicolau, and Schoen,²² who believe it to be the etiological agent of the particular cerebral lesions under discussion. Before the appearance of the latter papers, however, Dr. Goodpasture kindly lent to The Rockefeller Institute preparations revealing somewhat similar organisms which he also considers as the incitant of the pathological changes.²³ By comparison with these specimens and with the aid of the foregoing published data, Dr. Cowdry²⁴ has been able to observe the protozoon-like structures in some of the brains described in the present paper. The view that some other factors than the so called virus of epidemic encephalitis or of febrile herpes induce the lesions in the brains of rabbits is also in conformity with the observations of Doerr and Zdansky,²⁵ and others.²⁶

CONCLUSIONS.

Lesions of meningoencephalitis were found in 55 per cent of 372 rabbits comprising the laboratory stock regarded as healthy, others with snuffles or dying from different affections while being kept under observation, and still others which were employed for experimental purposes, such as tumor transplantation and *Treponema pallidum* inoculation. None was injected intracerebrally. The lesions consist in the main of infiltration with mononuclear cells occurring around the blood vessels, in the meninges, in the cortex, and under the ependyma of the lateral ventricles, together with particular focal necrotic areas in the cortex. The incidence of these histopathological changes varies in different series of animals; in those supposedly normal and in rabbits inoculated with a transplantable tumor or with *Treponema pallidum* material, the percentage of positives was from 40 to 60; in those suffering from miscellaneous diseases, such as pneumonia, septicemia, etc., the percentage was 70, and in rabbits ill with snuffles,

²² Levaditi, C., Nicolau, S., and Schoen, R., *Compt. rend. Acad.*, 1923, clxxvii, 985; *Compt. rend. Soc. biol.*, 1923, lxxxix, 984. Levaditi, C., and Nicolau, S., *Compt. rend. Soc. biol.*, 1923, lxxxix, 775.

²³ Goodpasture, E. W., personal communication.

²⁴ Cowdry, E. V., personal communication.

²⁵ Doerr, R., and Zdansky, E., *Schweiz. med. Woch.*, 1923, iv, 349.

²⁶ Twort, C. C., and Archer, H. E., *Lancet*, 1923, i, 1102.

as many as 76 per cent were affected. Marked lesions were observed in 47.5 per cent of the total.

The histopathological picture observed in these rabbits corresponds to those offered by a number of investigators as evidence of the transmission of certain nervous diseases of man to this animal. The accidental cerebral lesions in the rabbit, of a wide variety, and of frequent occurrence, are to be regarded as existing before any experimental procedure is begun. Their recognition is of the utmost importance in the interpretation of experimental results based on the presence of similar changes in this animal.

EXPLANATION OF PLATES.

PLATE 4.

FIG. 1. Section of the brain of a rabbit injected intratesticularly with *Treponema pallidum* material, showing perivascular infiltration with mononuclear cells in the Virchow-Robin space. $\times 640$.

FIG. 2. Section of the brain of a supposedly normal stock rabbit. To be noted are the numerous perivascular lesions. $\times 200$.

FIG. 3. The same field as Fig. 2 under higher magnification, illustrating nature of the mononuclear cells. $\times 365$.

PLATE 5.

FIG. 4. Section of rabbit brain from an early case of snuffles, showing slight meningeal infiltration with mononuclear cells. There is some perivascular infiltration around the small blood vessel. $\times 365$.

FIG. 5. Section of the brain of a rabbit inoculated intratesticularly with a transplantable tumor, showing meningeal, cerebral, and perivascular infiltration. $\times 100$.

FIG. 6. Section of the brain of a rabbit with snuffles, containing meningeal and perivascular infiltrations. $\times 250$.

PLATE 6.

FIG. 7. Section of the brain of a rabbit with early snuffles, revealing slight mononuclear infiltration under the ependyma of the lateral ventricle. $\times 210$.

FIG. 8. From a similar rabbit, but with more marked infiltration with mononuclear cells under the ependyma of the lateral ventricle. $\times 250$.

FIG. 9. Section of the brain of a rabbit with a subcutaneous abscess. Diffuse infiltration with mononuclear cells into the cerebral substance is seen. $\times 280$.

FIG. 10. Brain of a rabbit inoculated with a transmissible tumor, showing small groups of mononuclear cells in the brain substance. $\times 250$.

PLATE 7.

FIG. 11. Brain from a similar rabbit with a well marked area of focal necrosis. To be noted are the necrotic center, large, epithelial-like cells, and the surrounding mononuclear infiltration. $\times 190$.

FIG. 12. A similar area of necrosis found in a supposedly normal stock rabbit. $\times 190$.

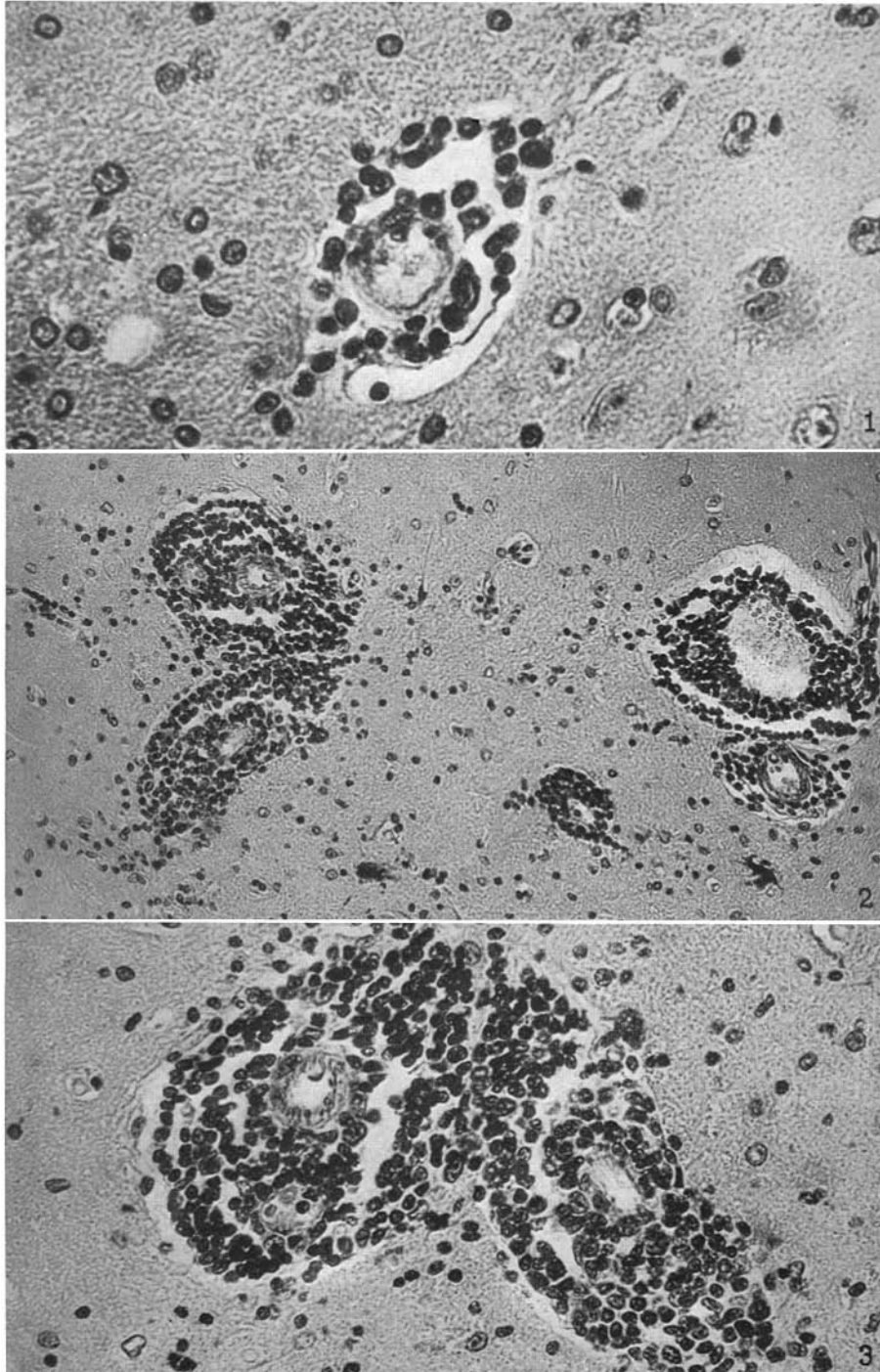
FIG. 13. Section of the brain from a snuffles rabbit, showing a similar area of focal necrosis, but not cut through the center. The blood vessels reveal marked perivascular infiltration. $\times 190$.

PLATE 8.

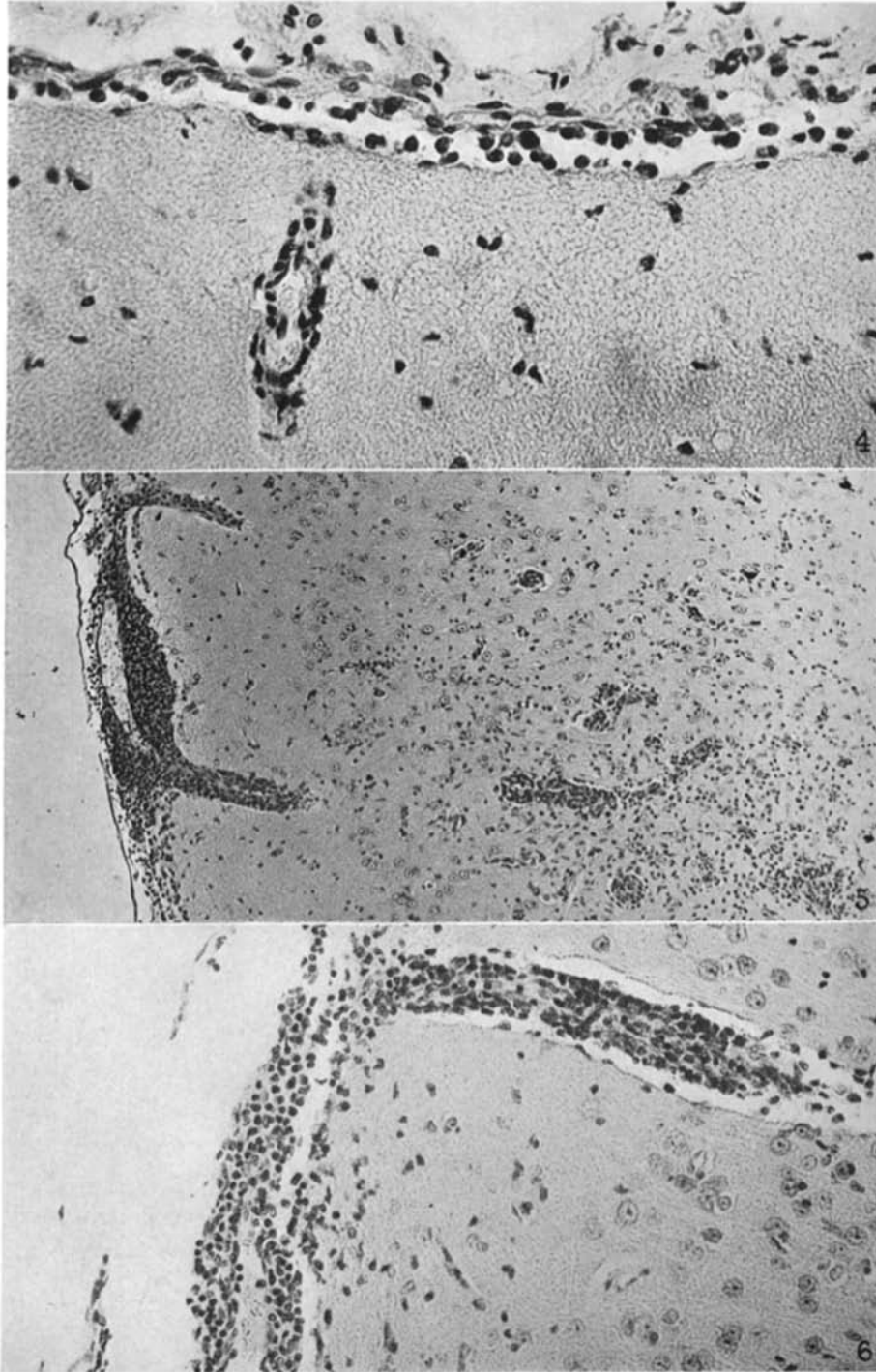
FIG. 14. Brain from a rabbit inoculated intratesticularly with a transmissible tumor. A focal necrotic area with infiltration by mononuclear cells is seen. $\times 270$.

FIG. 15. Section of the brain of a rabbit injected intratesticularly with *Treponema pallidum* material, showing an area of focal necrosis in process of healing. $\times 250$.

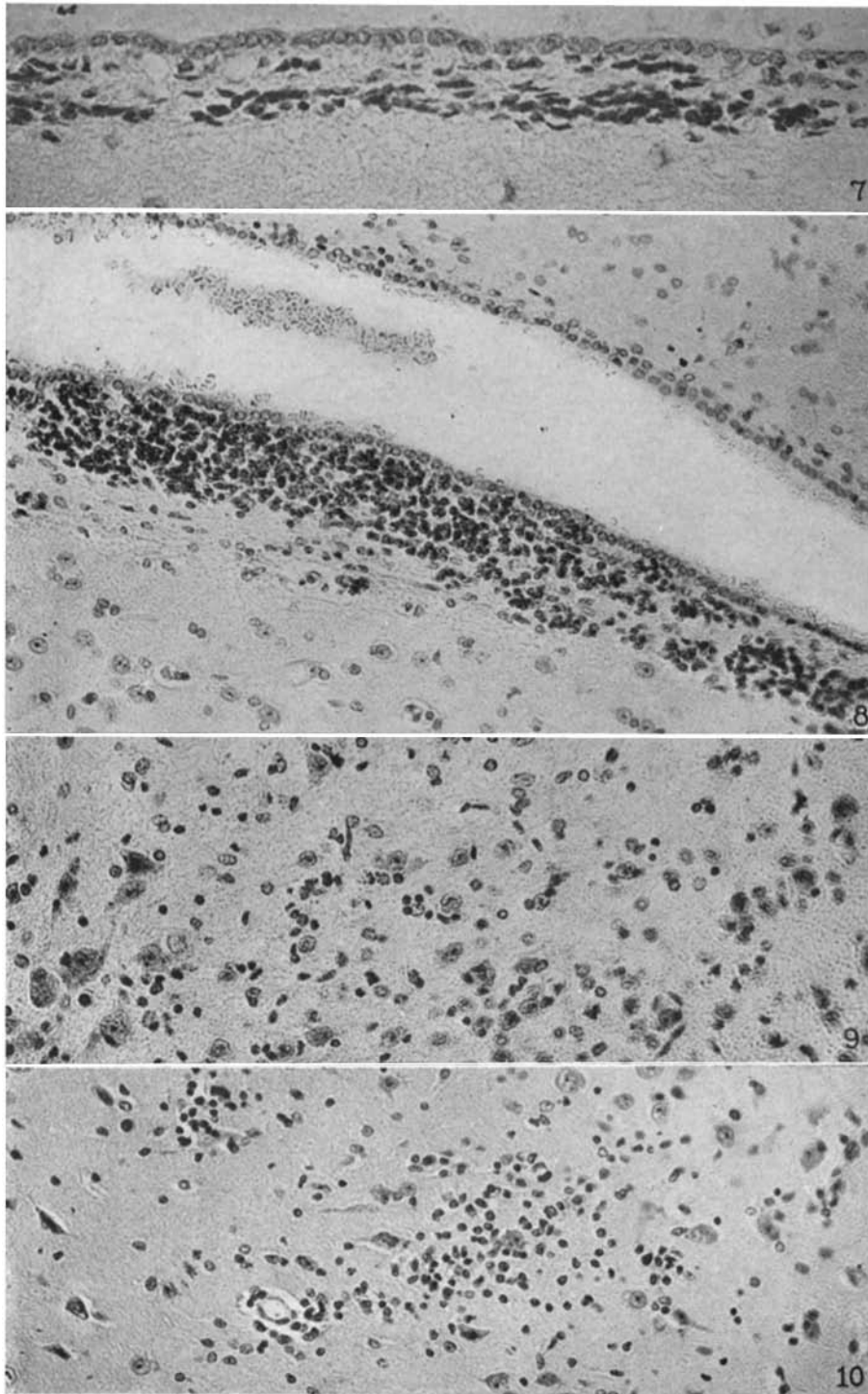
FIG. 16. Section of the brain of a rabbit inoculated intratesticularly with a transmissible tumor. To be noted is an area of necrosis at the surface of the brain with meningeal and perivascular infiltration. $\times 110$.



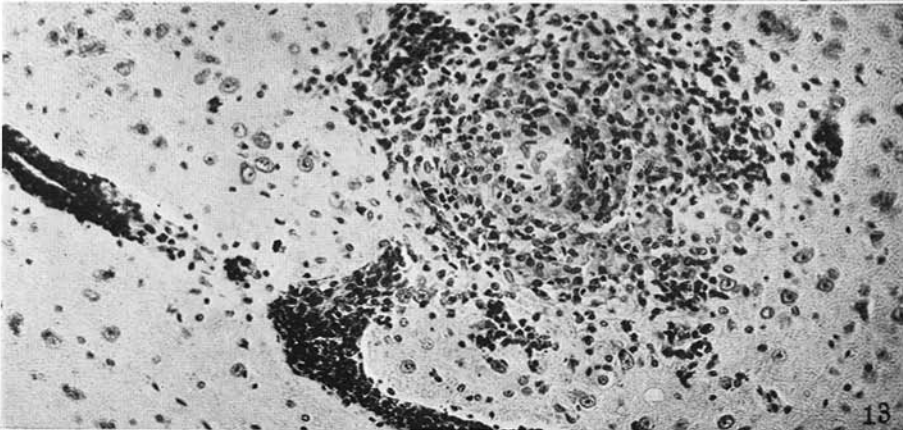
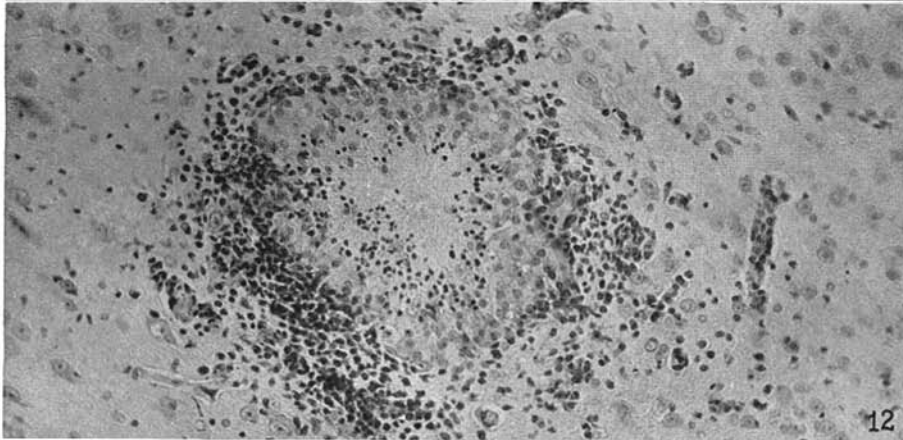
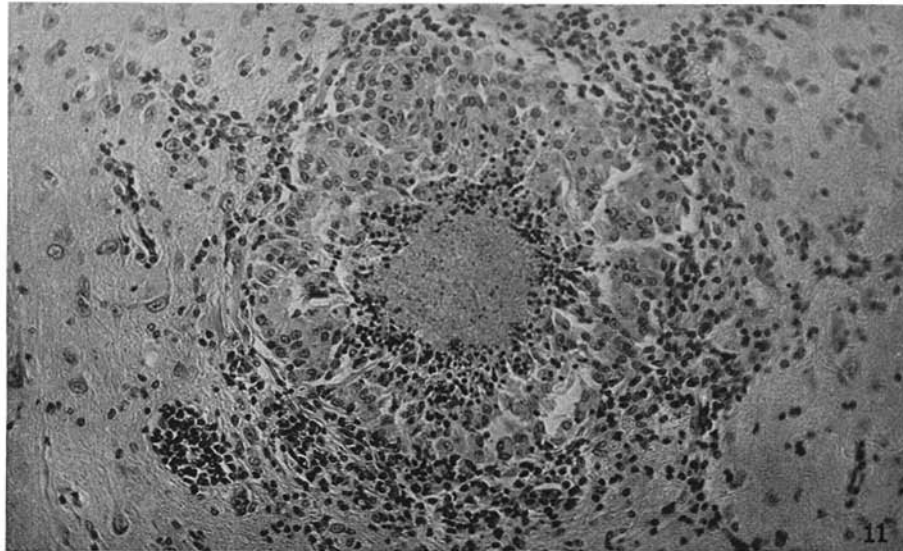
(McCartney: Brain lesions of domestic rabbit.)



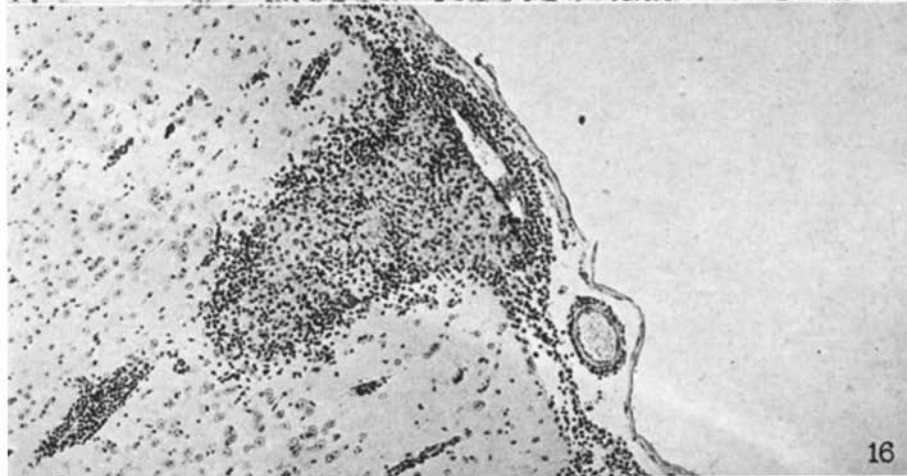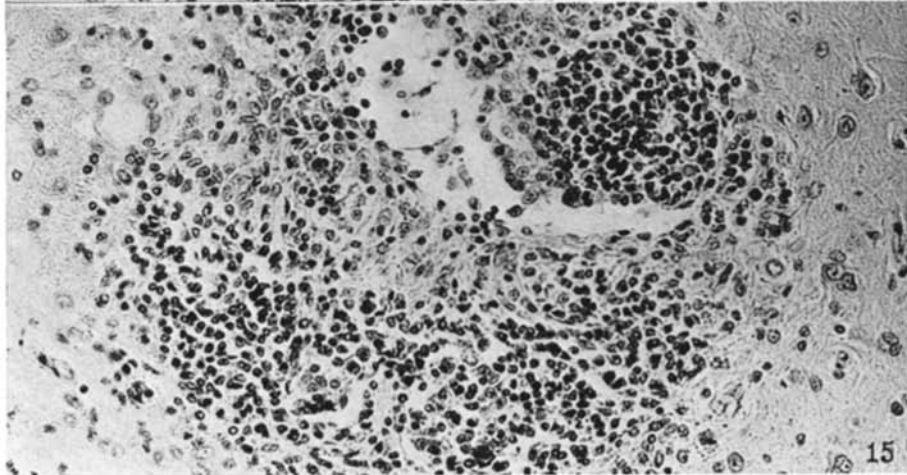
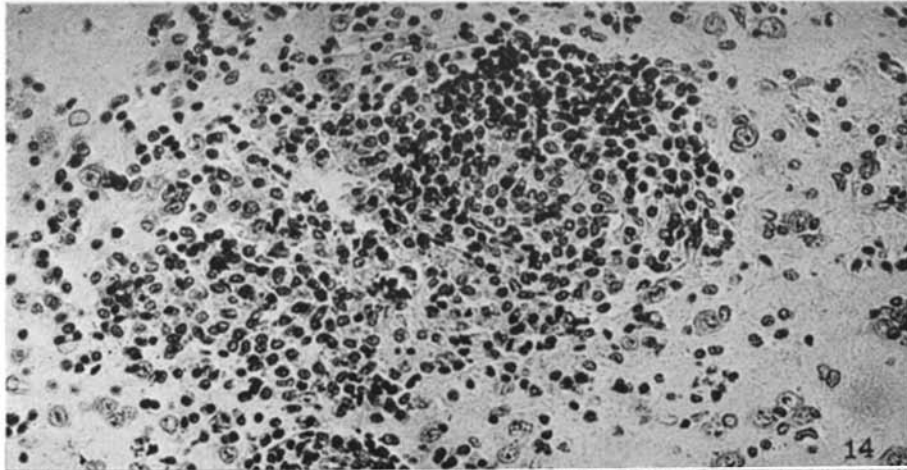
(McCartney: Brain lesions of domestic rabbit.)



(McCartney: Brain lesions of domestic rabbit.)



(McCartney: Brain lesions of domestic rabbit.)



(McCartney: Brain lesions of domestic rabbit.)