

## Serologic evidence of the postoperative persistence of hydatid cysts in man

BY R. M. MATOSSIAN AND G. F. ARAJ

Department of Bacteriology and Virology, American University of Beirut,  
Beirut, Lebanon

(Received 3 February 1975)

BROWN UNIV  
LIBRARY  
DEC 3 1197

### SUMMARY

The sensitivity of the haemagglutination, complement-fixation and indirect fluorescent antibody tests in the diagnosis of primary and recurrent hydatid disease is presented. In the first, diagnostic titres were obtained in 90%, 80% and 96% of 50 patients with hepatic and 64%, 60% and 68% of 25 patients with pulmonary cysts, respectively. In the postoperative study of 62 patients, elevated titres of HA, CF and IFA antibodies in 30 led to the presumptive diagnosis of recurrent disease, confirmed later by radiological and surgical follow-ups. In the 32 others the proportion of positive reactors was 29%, 6% and 28% in HA, CF and IFA tests. These patients had no detectable cysts. This indicates that in post-operative patients a negative CF test may be of a better prognostic value in indicating absence of cysts than the HA and IFA tests.

### INTRODUCTION

The variations in the clinical manifestations of hydatid disease in man have necessitated the introduction of several diagnostic immunological procedures. These include the haemagglutination (HA), complement-fixation (CF), indirect fluorescent antibody (IFA), bentonite flocculation (BF) and other tests. A high degree of accuracy has been obtained in the HA, CF and IFA tests by the selection of the appropriate antigen and the careful standardization of technique (Bradstreet, 1969; Matossian *et al.* 1972).

The postoperative evaluation of the hydatid patient is of great importance because the excision of the visible cyst may not necessarily indicate complete cure (Lass, Laver & Lengy, 1973). In the absence of clinical or radiological signs, the behaviour of circulating antibodies may be the earliest or the only indication of recurrent disease. This was studied by Matossian *et al.* (1972). HA antibodies, associated with IgG immunoglobulins, were present in patients with current and past infections. Complement-fixing antibodies, associated with IgG and IgM globulins, were usually detected during periods of antigenic activity and disappeared soon after the removal of the cyst. Variations in IgG and IgM antibody titres were also detectable by the IFA test. The authors concluded that the combined use of the three tests could help in the diagnosis of hydatid patients with primary infection or recurrent disease.

We present additional data about the value of the HA, CF and IFA tests in the diagnosis of recurrent hydatid disease. Their relative diagnostic merits in primary hydatidosis are also described.

#### MATERIALS AND METHODS

##### *Individuals included in the study*

Serum samples were collected from:

(A) Eighty hydatid patients with primary infection. Included were 50 individuals with hepatic cysts, 25 with pulmonary and 5 with cysts in other organs.

(B) Sixty-two follow-up patients. Many had been operated on for a single cyst and, as far as could be determined, had no additional cysts at the time of study. Other patients, with a history of single or multiple cysts, were referred by their physicians to rule out recurrent illness. The postoperative period varied from 1 to 10 years with a mean of 3.25 years.

(C) One hundred persons with no signs or symptoms suggestive of hydatid disease. Fifty were healthy university students. Fifty other samples were obtained from hospital admissions.

##### *Tests for hydatid disease*

*The haemagglutination (HA) tests.* The tube method used by Garabedian (1971) was adopted after some modifications. The test was considered as positive if the serum titres were 1/1280 or above, doubtful at 1/80 to 1/640, and negative at lower titres.

*The complement-fixation (CF) tests.* The microtitre technique described by Sever (1962) and modified for hydatid serology by Garabedian (1971) was adopted. The test was considered as positive if the titres were 1/8 or above, doubtful at 1/4, and negative at lower dilutions.

*The indirect fluorescent antibody (IFA) test.* This followed the method of Matossian *et al.* (1972). The freeze-dried hydatid antigen and fluorescent conjugates were obtained from Wellcome Reagents Ltd, Beckenham, Kent, England. The test was considered positive if fluorescence was observed at titres of 1/25 and above for IgA and IgM and at titres of 1/100 and above for IgG. After a year, the results obtained by the IFA test necessitated changes of procedure. Thus, in 40 patients with primary infection the percentage of positive reactions was 85, 35 and 10 for IgG, IgM and IgA antibodies, respectively. In 20 patients with recurrent disease it was 95%, 15% and 0%. Consequently, further testing for IgM and IgA was discontinued. Unless otherwise stated, all IFA results represent IgG determinations.

#### RESULTS

The diagnostic sensitivity of HA, CF and IFA tests at the previously specified titres in the preoperative diagnosis of hydatid disease in 50 patients with hepatic and 25 others with pulmonary cysts is presented in Fig. 1A and B, respectively. The proportion of positive reactors in the first group was 90%, 80% and 96% in HA, CF and IFA tests. Doubtful titres were seen in 10%, 12% and 2%. Nega-

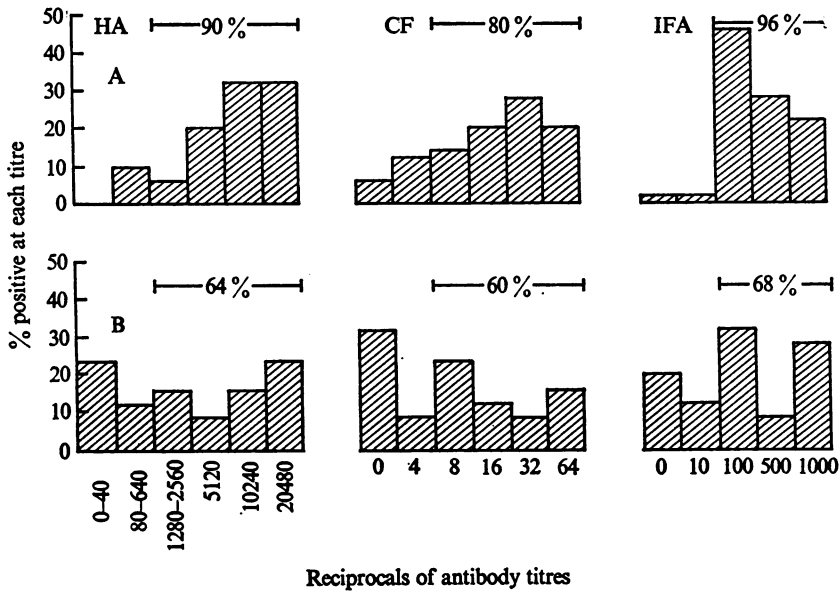


Fig. 1. Preoperative sensitivity of haemagglutination, complement-fixation and indirect fluorescent antibody tests in the diagnosis of primary hydatidosis: (A) in 50 patients with hepatic and (B) in 25 patients with pulmonary cysts.

tive results were obtained in 8% of CF and 2% of IFA tests. In patients with pulmonary cysts the percentage of positive reactors was 64, 60 and 68. Doubtful titres were seen in 12%, 8% and 12%. Negative results were obtained in 24% of HA, 32% of CF and 20% of IFA tests. The five patients with cysts in miscellaneous areas, not included in Fig. 1, were positive in all three tests.

The postoperative behaviour of HA, CF and IFA antibodies in 32 patients having no demonstrable cysts and 30 others with recurrent disease is presented in Fig. 2A and Fig. 2B, respectively. In Fig. 2A the percentage of positive reactors was 29, 6 and 28 in HA, CF and IFA tests, respectively. Doubtful titres were seen in 41%, 22% and 50%. Negative results were obtained in 30% of HA, 72% of CF and 22% of IFA tests. The preoperative site of the cysts in these patients was the liver in 15, the lungs in 11, and miscellaneous other areas in 6. In the 30 patients with recurrent disease, the percentage of positive reactors was 100, 97 and 100 for HA, CF and IFA, respectively. In this group, there were 25 patients with hepatic, 4 with pulmonary and 1 with central nervous system cysts. Recurrence in 24 hepatic cyst patients was in the same organ. One patient had a previous cyst in the lung. In three patients with pulmonary cysts, recurrence was in the same organ. The fourth patient had a previous hepatic cyst. The recurring brain cyst was in the same organ.

Table 1 presents the sensitivity of the different combinations of HA, CF and IFA tests in the diagnosis of hydatid disease in patients at the time of operation, in patients with recurrent disease and in patients with no detectable cysts more than a year after surgery. In patients with primary infection the combined sensitivity of the three tests was not significantly higher than that of individual tests.

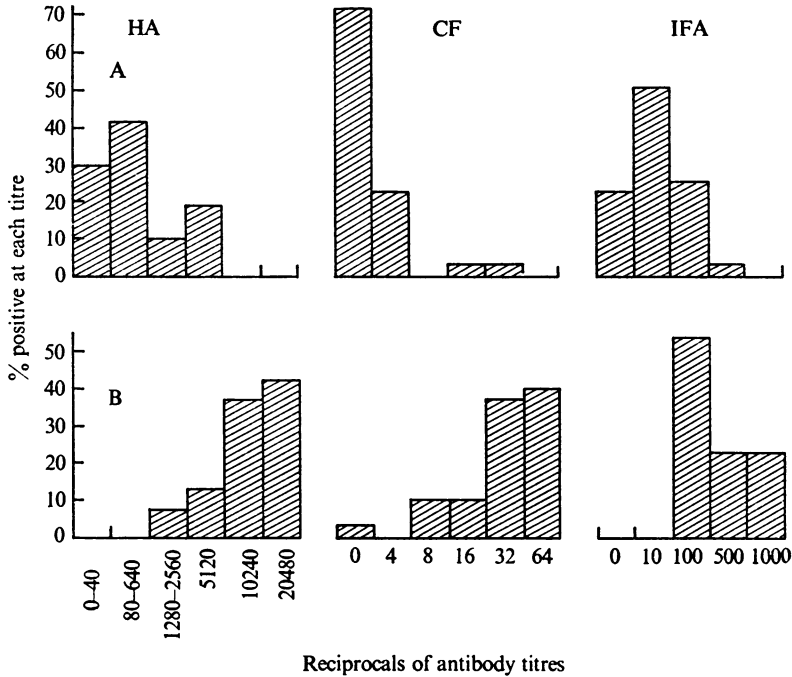


Fig. 2. Postoperative pattern of HA, CF and IFA antibodies in (A) 32 patients with no demonstrable cysts, a year or more after surgery, and (B) 30 patients with recurrent hydatid disease.

Table 1. *The cumulative sensitivity of the HA, CF and IFA tests in the diagnosis of hydatid disease in patients with primary infection, with recurrent disease and others with no detectable cysts, more than a year after surgery*

HA, CF, IFA tests	Cyst site at operation			
	Liver		Lung	
	No.	%	No.	%
<b>A. At operation: primary infection</b>				
All three positive	38	76	14	56
Any two positive	9	18	3	12
Any one positive	2	4	0	0
All three negative	1	2	8	32
	50	100	25	100
<b>B. Postoperative: recurrent disease</b>				
All three positive	24	96	4	100
Any two positive	1	4	0	0
Any one positive	0	0	0	0
All three negative	0	0	0	0
	25	100	4	100
<b>C. Postoperative: no cysts</b>				
All three positive	1	7	0	0
Any two positive	3	20	1	9
Any one positive	5	33	3	27
All three negative	6	40	7	64
	15	100	11	100

In patients with recurrent disease it was 100%. In patients with no detectable cysts, 50% had all three tests negative. In the rest of the patients, having low antibody titres, neither a diagnosis nor a prognosis could be made.

Among the 50 healthy students there were no positive reactors in the HA, CF and IFA tests. However, in the 50 patients with miscellaneous conditions, the percentage of positive reactors was 0, 6 and 12. These included patients with cirrhosis, cancer of the liver, cancer of the colon, collagen disease and undiagnosed illness.

#### DISCUSSION

Human infection with *Echinococcus granulosus* results in the formation of circulating antibodies belonging to IgG, IgM and IgA immunoglobulin classes detectable by HA, CF and IFA tests (Matossian *et al.* 1972). Using a radio-allergosorbent test, Huldt, Johansson & Lantto (1973) showed high-titre specific IgE antibodies in Swedish Lapps with hydatid disease. A significant increase in the mean IgG, IgM and IgA immunoglobulin concentrations of 94 hydatid patients has been noted by Matossian, Alami, Araj & Salti (in preparation). Huldt *et al.* (1973) demonstrated a considerable increase of total IgE concentrations in hydatid disease, by using a radioimmunosorbent test. The time at which antibodies appear in humans after primary infection with hydatid ova is not known. Araj (1973) determined the sequence of antibody formation in laboratory mice infected by the intraperitoneal injection of viable *E. granulosus* protoscoleces. HA and CF antibodies appeared simultaneously around the 14th week after infection, and persisted for over a year.

Knowledge of the antibody globulin pattern at the various stages after *E. granulosus* infection would facilitate the selection of the most appropriate test system for the diagnosis, prognosis and epidemiological studies of the disease. Methods that detect predominantly IgG antibodies do not necessarily indicate current or recent infections, but may be valuable in epidemiological investigations. Those that are largely dependent on IgM antibody may indicate recent antigenic activity and may become negative when stimulus ceases even though a cyst may still be present. A persistent or increasing concentration of IgM antibodies after surgical excision of the cyst would indicate the presence of additional cysts in the host (Matossian *et al.* 1972).

#### *The haemagglutination (HA) test*

Since its introduction by Garabedian, Matossian & Djanian (1957), the HA test has been extensively employed. Kagan (1968) considered HA as the method of choice, having an average sensitivity of 84%. In our 75 patients with primary infection, the incidence of positives was 90% in hepatic and 64% in pulmonary cysts. In patients with recurrent disease the sensitivity of the HA test was 100%. The diagnostic titre of HA antibodies has varied from 1/80 to 1/640 with different investigators. We considered a titre of 1/1280 as positive to avoid errors due to the presence of low-titre hydatid HA antibodies in patients with schistosomiasis (Botros, Moch & Barsoum, 1973). In patients with primary infection a low HA

titre, in the presence of clinical and radiological findings suggesting hydatid disease, was of help towards a final diagnosis. The significance of low-titre residual antibodies after operation was difficult to assess. Lass *et al.* (1973) found HA antibodies in patients up to 21 years after operation. In our 32 cases with no post-operative evidence of additional cysts, 29% had diagnostic and 41% doubtful HA titres. The HA test can be performed with fresh, tanned, human or sheep red blood cells. Erythrocytes, treated with pyruvicaldehyde and subsequently tanned and sensitized are also useful. These cells can be left at  $-40^{\circ}\text{C}$ . and may be freeze-dried (Matossian & Kane, 1971). A new rapid slide test, using a 25% suspension of chromium-chloride-treated erythrocytes, exposed to a formalinized hydatid antigen for sensitization, has given satisfactory results in a comparative study with the tube method (Mamo & Dakroub, 1974).

#### *The complement-fixation (CF) test*

As a satisfactory diagnostic procedure in hydatid disease, the CF test has had a mixed reception. Bradstreet (1969) considered the test as reliable in the diagnosis of primary infection and because the presence of CF antibodies, in general, denoted current or recent infection, it could also be of special help in the diagnosis of recurrent disease. In patients with primary infection, we obtained a CF sensitivity of 80% in hepatic and 60% with pulmonary cysts. In the 30 patients with recurrent disease, the sensitivity of the CF test was 97%. In 32 patients with no detectable cysts, a year or more after operation, the positive, doubtful and negative reactors were 6%, 22% and 72%, respectively.

These findings are in line with the observation that most CF antibodies are associated with IgM immunoglobulins. The reasons why IgM antibodies are continuously produced under the antigenic stimulus of hydatid fluid are not understood. The active antigen being a mosaic of protein and polysaccharide substances it is possible that antibodies produced by the latter react as IgM immunoglobulins in CF tests. Reactive polysaccharide antigens have been demonstrated in hydatid fluid by Hariri, Schwabe & Koussa (1965) and Russi, Siracusano & Vicari (1974). However, their role in CF tests has not been determined.

#### *The indirect fluorescent antibody (IFA) tests*

Using an IFA test, Matossian *et al.* (1972) demonstrated the presence of specific IgG, IgM and IgA antibodies in a number of patients with primary and recurrent hydatid disease. However, in subsequent studies we could detect significant titres of IgM antibodies in 35% of 40 patients with primary infection, and 15% of 20 patients with recurrent disease. IgA antibodies could be detected only in few patients, at titres of 1/10. In contrast, IgG antibodies were present in 96%, 68% and 100% of patients with hepatic, pulmonary and recurrent cysts. High-titre residual IgG antibodies were seen in 28% of patients with no demonstrable cysts. The reasons for the absence of detectable IgM and IgA antibodies are not clear. The monospecific anti-IgM and IgA conjugates were sensitive and had been carefully standardized before use. Appropriate controls were also maintained. Using the IFA test, Huldts *et al.* (1973) studied 8 patients with hydatid disease. IgG antibodies

were present in all patients. In contrast, only traces (1/5 to 1/20) of IgM and IgA were observed in half the patients. Cohen, Norins & Julian (1967) noticed that IgG antibodies inhibited the IgM reactivity in the IFA procedure. The addition of purified 7 S antibodies to purified 19 S antibody fractions decreased the ability of the latter to react with an anti-IgM reagent. Mouton, Stoop, Ballieux & Mul (1970) described a restriction to the possibility of determining the specific immunoglobulin classes of the antibodies reacting by IFA, owing to the masking by excess IgG. Philip, Casper, Gordon & Quan (1974) discussed the possibility that avid IgG antibodies in whole sera interfered with demonstration of IgM antibodies by immunofluorescence. The blocking of specific IgM and IgA antibodies by high concentrations of IgG is a possibility worthy of consideration in hydatid IFA serology.

The high sensitivity of the IFA test in detecting IgG antibodies was handicapped by non-specific reactions observed in 12% of 50 patients with serious systemic illness. These were mostly in patients with liver conditions where the wrong diagnosis could have led to operation. The HA and CF tests were negative in these patients. In 50 healthy students the IFA test was negative. Cross-reactions between *Schistosoma mansoni* and *E. granulosus* antigens have already been described (Matossian *et al.* 1972). Antibodies to *S. mansoni* antigen were observed in 56% of 32 patients with hydatid disease. The same group of patients had no detectable antibodies to *Trichinella spiralis* antigen (Matossian, unpublished data).

Our results indicate that by the simultaneous use of the HA and CF tests it is possible to appraise the antibody globulin pattern of most patients with hydatid disease and thus establish a presumptive diagnosis or prognosis of the condition. On the other hand, IFA tests were less satisfactory than originally expected.

We acknowledge with thanks the free supply of antigens and fluorescent conjugate provided by the Wellcome Research Laboratories, Beckenham, Kent, England.

Thanks are also due to Fisons' Scientific Apparatus Ltd, Loughborough, England, for their supply of a Teflon spray.

#### REFERENCES

- ARAJ, G. F. (1973). Study of humoral antibodies in experimental hydatidosis of mice. MS. thesis, American University of Beirut, Beirut, Lebanon.
- BOTROS, B. A. M., MOCH, R. W. & BARSOUM, I. S. (1973). Echinococcosis in Egypt: Evaluation of the indirect haemagglutination and latex agglutination tests for echinococcal serologic surveys. *Journal of Tropical Medicine and Hygiene* **76**, 243.
- BRADSTREET, C. M. P. (1969). A study of two immunological tests in the diagnosis and prognosis of hydatid disease. *Journal of Medical Microbiology* **2**, 419.
- COHEN, I. R., NORINS, L. C. & JULIAN, A. J. (1967). Competition between, and effectiveness of IgG and IgM antibodies in indirect fluorescent antibody and other tests. *Journal of Immunology* **98**, 143.
- GARABEDIAN, G. A., MATOSSIAN, R. M. & DJANIAN, A. Y. (1957). An indirect hemagglutination test for hydatid disease. *Journal of Immunology* **78**, 269.

- GARABEDIAN, G. A. (1971). Evaluation of the reactivity of hydatid whole scolex antigen in hydatid disease serology. *Annals of Tropical Medicine and Parasitology* **65**, 385.
- HARIRI, M. N., SCHWABE, C. W. & KOUSSA, M. (1965). Host-parasite relationships in echinococcosis. XI. The antigen of the indirect hemagglutination test for hydatid disease. *American Journal of Tropical Medicine and Hygiene* **14**, 592.
- HULDT, G., JOHANSSON, S. G. O. & LANTTO, S. (1973). Echinococcosis in Northern Scandinavia. Immune reactions to *Echinococcus granulosus* in Kautokeino Lapps. *Archives of Environmental Health* **26**, 36.
- KAGAN, I. G. (1968). A review of serological tests for the diagnosis of hydatid disease. *Bulletin of the World Health Organization* **39**, 25.
- LASS, N., LAVER, Z. & LENGY, J. (1973). The immunodiagnosis of hydatid disease: Post-operative evaluation of the skin test and four serological tests. *Annals of Allergy* **31**, 430.
- MAMO, A. J. & DAKROUB, R. (1974). A quick indirect hemagglutination test for the diagnosis of hydatid disease. *Lebanese Medical Journal* **27**, 223.
- MATOSSIAN, R. M. & KANE, G. J. (1971). The use of freeze dried erythrocytes as antigens in hydatid disease. *Lebanese Medical Journal* **24**, 227.
- MATOSSIAN, R. M., KANE, G. J., CHANTLER, S. M., BATTY, I. & SARHADIAN, H. (1972). The specific immunoglobulin in hydatid disease. *Immunology* **22**, 423.
- MOUTON, R. P., STOOP, J. W., BALLIEUX, R. E. & MUL, N. A. J. (1970). Pneumococcal antibodies in IgA of serum and external secretions. *Clinical and Experimental Immunology* **7**, 201.
- PHILIP, R. N., CASPER, E. A., GORDON, F. B. & QUAN, A. L. (1974). Fluorescent antibody responses to chlamydial infection in patients with lymphogranuloma venereum and urethritis. *Journal of Immunology* **112**, 2126.
- RUSSI, S., SIRACUSANO, A. & VICARI, G. (1974). Isolation and characterization of a blood P<sub>1</sub> active carbohydrate antigen of *Echinococcus granulosus* cyst membrane. *Journal of Immunology* **112**, 1061.
- SEVER, L. I. (1962). Application of microtechnique to viral serological investigations. *Journal of Immunology* **88**, 320.