

**The production of pneumonia
with or without pleurisy in gnotobiotic piglets with pure
cultures of strain TR 32 of *Mycoplasma hyorhinitis***

BY J. POLAND, N. EDINGTON, M. GOIS AND A. O. BETTS

*Department of Pathology, The Royal Veterinary College
(University of London), London, N.W. 1*

(Received 20 October 1970)

SUMMARY

Nine gnotobiotic piglets, when 8–9 days old, were exposed to an aerosol of strain TR 32 of *Mycoplasma hyorhinitis* and killed at intervals from 14 to 37 days after infection. The aerosol of *M. hyorhinitis* caused bronchopneumonia in 1 pig, pleurisy alone in 2 pigs, pleuropneumonia in 2 pigs and no lung changes in 4 pigs. *M. hyorhinitis* was re-isolated from the lungs of all infected pigs, irrespective of the presence or absence of lesions, though it was only isolated from the serosa and joints when lesions were present. Four control pigs exposed to aerosols of mycoplasma medium had no lesions.

INTRODUCTION

‘Purified’ cultures of *Mycoplasma hyopneumoniae* (*M. suis*pneumoniae) have been shown to cause pneumonia in gnotobiotic piglets (Hodges, Betts & Jennings, 1969), and the view has been expressed that it is the only recognized mycoplasma causing pneumonia in pigs. Differences of opinion exist as to the role played by *Mycoplasma hyorhinitis* in porcine pneumonia.

Up to 1965, *M. hyorhinitis* was considered to be the cause of a disease of young piglets characterized by polyserositis and arthritis but not by pneumonia (Roberts, Switzer & Ramsey, 1963*a, b*). However, *M. hyorhinitis* is a common inhabitant of the nasal cavities and lungs of both healthy and diseased pigs. Switzer (1955) isolated from 48% and 67% of the nasal cavities of two batches of normal pigs a ‘pleuropneumonia-like organism’ which he named *M. hyorhinitis*, whilst Ross, Switzer & Mare (1963) isolated *M. hyorhinitis* from at least 30% of normal pigs. Hartwich & Niggeschulze (1966) recovered the organism from 75% of normal lungs, and Scheer, Hartwich & Sandersleben (1969) found that 69% of normal pigs harboured the organism in their lungs or nasal cavities.

However, several workers have reported that *M. hyorhinitis* occurs more frequently in the nasal cavities and lungs of pigs with pneumonia than in normal pigs. Thus L’Ecuyer, Switzer & Roberts (1961), in a survey of pulmonary microflora, found that 51% of pneumonic lungs but only 6.6% of normal lungs revealed organisms believed to be *M. hyorhinitis*. Estola & Schulman (1966) found that 14 of 22 lungs and 7 of 22 nasal swabs from pigs in Finland with enzootic pneumonia yielded this organism whilst none of 9 lungs or 9 nasal swabs from normal pigs

did so. Gois, Cerny, Roskosny & Sovadina (1969) found that none of 202 nasal swabs or 107 lungs from a herd free from enzootic pneumonia yielded *M. hyorhinitis*, whereas this organism could be recovered from 56 of 61 nasal swabs and from at least 15 of 33 lungs from a herd with pneumonia.

Nevertheless, in spite of these observations it has been generally considered that *M. hyorhinitis* is either only a secondary invader in porcine pneumonia or merely present in pneumonic lesions (Switzer, 1964; Goodwin, Pomeroy & Whittlestone, 1968). Contrary evidence was produced by Gois and his colleagues working in Czechoslovakia, who induced pneumonia, sometimes without pleurisy, in both conventional and gnotobiotic pigs (Gois, Valicek & Sovadina, 1968; Gois *et al.* 1970). In this country Gois (unpublished observations) found that 20 of 30 lungs and 28 of 30 nasal swabs from a herd with a pneumonia problem yielded *M. hyorhinitis* in circumstances which suggested that it might have played a primary pathogenic role in the pneumonia.

Accordingly, the present work was undertaken to confirm the potentiality of the TR 32 strain of *M. hyorhinitis* to produce pneumonia and to extend the work of Gois *et al.* (1968). Gnotobiotic piglets were used in the experiment so that no potentially pathogenic bacteria or viruses could be incriminated as having a synergistic action with *M. hyorhinitis*, and to avoid the risk of accidental infection with microorganisms of human origin.

MATERIALS AND METHODS

Mycoplasma culture

The *M. hyorhinitis* strain used in this experiment has been designated TR 32 and was isolated originally from the lungs of a pig from a fattening station in Czechoslovakia. It has been classified as *M. hyorhinitis* on the basis of growth inhibition (Gois *et al.* 1969) and of metabolism inhibition and colonial growth (Gois, Cerny & Veznikova, 1970).

Strain TR 32 used in these experiments was 'cloned' three times by culturing from single colonies into liquid medium and inoculating the tenfold dilutions of the resulting 48 hr. culture on agar plates. It was then inoculated into a gnotobiotic piglet which was killed 14 days later. The strain was re-isolated from the pneumonic lungs of this piglet, and further 'purified' by plating out from single colonies three times. It was then grown in liquid medium suitable for inoculation into pigs. The medium comprised 20% pig serum, 70% Difco P.P.L.O. broth, 10% of a 25% yeast extract (D.C.L. Dried Yeast), 0.5% glucose, and 0.002% phenol red. The pH of the inoculum was adjusted to 7.4 and the number of mycoplasmas titrated according to the number of colour changing units (C.C.U.)/ml. After infection of the piglets in the isolators, the remains of the inocula were removed from the isolators, tested for bacteriological sterility and titrated again.

Experimental pigs

The experimental pigs used were two litters (42 and 46) of Large White gnotobiotic piglets produced and reared by the techniques described by Betts & Trexler

(1969). Each plastic isolator contained within it a stainless-steel cage which housed either one or two pigs. The pigs were fed on a sterilized proprietary milk product with added minerals and vitamins. The pigs were maintained under these sterile conditions throughout the course of the experiment. The first litter of three pigs was infected by aerosol when 8 days old, and the second litter of ten pigs was infected by aerosol when 9 days old.

Microbiological tests of pigs before inoculation

Swabs were taken from the anus and mouth of each pig 4 days after birth and tested for bacteria and fungi aerobically and anaerobically by the methods of Betts & Trexler (1969).

Inoculation of pigs

Each group of pigs was exposed to an aerosol of *M. hyorhinis* in culture medium. The aerosol apparatus* was placed inside the animals' cage, which was covered with a plastic canopy that exactly covered the top and four sides. The two pigs in the isolator in the first experiment were exposed for 2 hr. to a total of 12 ml. of a nebulized culture containing 10^8 c.c.u./ml. The pigs in each of the isolators in the second experiment were exposed for $1\frac{1}{4}$ hr. to a total of 8–10 ml. of a nebulized culture containing 10^8 – 10^9 c.c.u./ml., and these pigs also either ingested or insufflated a further 2 ml. of culture (due to the frothing-over of culture from the aerosol apparatus). No anti-foam agent, as described by Wright, Bailey & Hatch (1968), was included in the medium since frothing was not a problem in the first litter. The particle size of the droplets was approximately 5–8 μ . Control pigs were exposed to similar volumes of nebulized uninoculated medium for the same lengths of time.

Necropsy procedure

The pigs were anaesthetized with pentobarbitone sodium B.P. inside the isolators, removed from the isolators, exsanguinated and necropsied. In the first litter the 2 infected pigs were killed 15 and 30 days post inoculation (p.i.) and the control at 30 days. In the second litter 3 pigs (1 control and 2 infected) were killed at 14 days and at 23 days p.i.; 4 pigs (1 control and 3 infected) were killed between 33 and 37 days p.i.

Examination of materials collected at necropsy

Re-isolation of mycoplasmas

Materials were collected from 30 sites. Direct culture to solid media was carried out from the following sites: turbinates, tonsil, trachea, bronchus, pleural fluid, pericardial fluid, peritoneal fluid, cerebrospinal fluid, lumen of the large intestine, and joints (left and right elbow, carpus, stifle and hock).

Pieces of tissue from the lung, heart, liver, spleen, kidney, brain and lymph nodes were stored at -70°C . and later ground up in liquid medium before inoculation into liquid medium and onto solid medium.

Liquid medium was the same as that used for growth of cultures for inoculation,

* The Midhurst Nebuliser, Aerosol Products (Colchester) Ltd.

except that horse serum replaced pig serum, and 10% of pig lung extract, prepared according to the method of Hodges (1969), was added. Solid medium contained 0.85% Oxoid Ion Agar No. 2.

Microbiology

Materials from the same 30 sites were tested for micro-organisms capable of anaerobic growth by direct culture on heated blood agar with additional yeast extract (1%) in the case of the first ten sites listed above, and by culture after grinding up in the mycoplasma liquid medium in the case of the viscera, brain and lymph nodes. Since the solid mycoplasma medium contained neither penicillin nor thallium acetate, it was also used for aerobic growth of micro-organisms.

Serology

All sera were tested by means of the metabolism inhibition test against *M. hyopneumoniae* strain J and *M. hyorhinae* strain TR 32. The medium used for all tests had a pH of 7.8 and comprised 20% fresh horse-serum, 10% of a 25% yeast extract (DCL Dried Yeast), 40% Hanks's solution, 30% Hartley digest broth,* 0.5% glucose, 0.0028% phenol red, 0.05% thallium acetate and 1000 units/ml. of penicillin G. In addition, the medium used for tests against *M. hyorhinae* contained 2% fresh guinea-pig serum. The wells of Lucite† trays were filled with 0.05 ml. of each serum dilution, 0.05 ml. of antigen dilution (1000 c.c.u./ml.) and 0.1 ml. of medium, and then sealed with liquid paraffin. Inhibition of glucose metabolism was considered to have occurred in those wells where the pH remained higher than 7.4 when the pH of antigen control wells had fallen to 6.8 or less.

Histopathology

Pieces of tissue were taken from representative areas of all the 30 sites mentioned above, fixed in 10% formol saline and embedded in paraffin, and 5 μ sections were stained with Mayer's haematoxylin and eosin. In addition, selected sections were stained with methyl green pyronin, by the Picro-Mallory method for fibrin, and the Gordon and Sweet method for reticulin.

RESULTS

Microbiological examination of pigs before inoculation

No micro-organisms were recovered from any of the pigs with the exception of the control pig 42C, which was contaminated with *Staphylococcus epidermidis* and a *Streptococcus* sp. in the turbinates and tonsil.

Clinical signs

Pigs 46P and 46C became clinically ill 6 days after inoculation, especially 46P, which was lethargic, weak on its back legs, and breathing very rapidly on the 8th day p.i. However, it seemed to recover about a week later.

* Oxoid Limited, London, S.E. 1.

† Linbro 1S MRC 96, Cooke Engineering Co., Alexandria, Virginia, U.S.A.

Table 1. *The location of lesions and re-isolation of Mycoplasma hyorhinis from gnotobiotic pigs inoculated with strain TR 32 of M. hyorhinis*

| Fig no. | Inoculum | Time p.i. (days) | Lesions | | | | | | Re-isolations of <i>M. hyorhinis</i> | | | | Bacteriological findings at necropsy | | |
|---------|---------------------|------------------|---------|--------|--------------|-------------|--------|------|--------------------------------------|--------------|-------------|--------|--------------------------------------|---|---|
| | | | Lung | Pleura | Peri-cardium | Peri-toneum | Joints | Lung | Pleura | Peri-cardium | Peri-toneum | Joints | | | |
| 46N | Medium | 14 | - | - | - | - | - | - | - | - | - | - | - | - | - |
| 46B | | 23 | - | - | - | - | - | - | - | - | - | - | - | - | - |
| 42C | | 30 | - | - | - | - | - | - | - | - | - | - | - | - | - |
| 46I | | 34 | - | - | - | - | - | - | - | - | - | - | - | - | - |
| 42D | <i>M. hyorhinis</i> | 14 | - | - | - | - | - | - | - | - | - | - | - | - | - |
| 46P | | 14 | - | + | + | + | + | + | + | + | + | + | + | + | - |
| 46L | | 14 | + | - | - | - | - | + | - | - | - | - | - | - | - |
| 46F | | 23 | - | - | - | - | + | - | - | - | - | - | - | - | - |
| 46H | | 23 | - | - | - | - | - | + | - | - | - | - | - | - | - |
| 42E | | 30 | + | + | + | - | + | + | + | + | + | + | + | + | - |
| 46Q | | 33 | - | - | - | - | + | + | + | - | - | - | - | - | - |
| 46C | | 33 | + | + | + | + | + | + | + | + | + | + | + | + | - |
| 46A | | 37 | - | + | + | + | + | + | + | + | + | + | + | + | - |

+, Microscopic lesion; + +, macroscopic + microscopic lesion.

Staph. epidermidis
+ *Streptococcus* sp.

Clostridium sp.

Clostridium sp.

Lameness was difficult to detect even when gross joint lesions were evident (see Table 1), since movement is restricted in isolators. However, pig 46Q became obviously lame 30 days p.i.

All the pigs in the other five isolators appeared clinically healthy.

Re-isolations of Mycoplasma hyorhinis

Table 1 indicates sites from which organisms were re-isolated. *M. hyorhinis* was re-isolated from the turbinates, tonsil, trachea and bronchi of all the inoculated pigs, although no lesions were observed in these tissues. *M. hyorhinis* was also isolated from the ground-up lungs of all the inoculated pigs, whether the lungs had lesions or not. Otherwise mycoplasmas were only re-isolated from tissues with lesions.

Microbiological examination of pigs after necropsy

No micro-organisms other than *M. hyorhinis* were recovered from any of the pigs, with the exception of pig 42C which was contaminated with the same organisms as were found before inoculation, and pigs 46L and 46Q which were contaminated with a *Clostridium* sp. in the turbinates, tonsil, trachea, bronchus and intestines (this *Clostridium* sp. was presumed to have entered with the plastic canopy just before inoculation).

Serology

No antibodies to *M. hyopneumoniae* were revealed in the metabolism inhibition test, but antibodies to *M. hyorhinis* were detected at titres of at least 1/4 in all the infected pigs except the three killed 14 or 15 days p.i. and pig 46H which was one of the pigs killed 23 days p.i.

Pathology

The incidence of lesions in the tissues typically affected by *M. hyorhinis* (the serosa and joints) and in the lung are recorded in Table 1. The changes seen in the serosa and joints were very similar to those described by Roberts *et al.* (1963*a, b*). They occurred in all ages of pigs.

Macroscopically, affected joints were swollen and hyperaemic. The increased synovial fluid in these joints was cloudy and occasionally contained fibrino-purulent flakes. Histologically there was an extensive cellular infiltration of the tissue underlying the synovial membrane, which showed degenerative changes with desquamating cells being shed into the joint cavity and inflammatory cells lying between and on the inner surface of the serosal cells. The infiltrating cells were predominantly mononuclear, but in the joints in which neutrophils were seen they occurred in foci outnumbering the mononuclear cells. It was not possible to differentiate histologically between the lesions produced 14, 23 and 30 days p.i.

In the abdomen the most characteristic lesion was a creamy yellow, fibrino-purulent exudate on the margin of the liver and spleen. Fibrino-purulent flakes were also seen on the omentum and lying free in the peritoneal cavity. Histological examination confirmed that the lesions did not invade the parenchyma of the liver and spleen, but affected only the mesothelial cells. The exudate which accumulated around these degenerating serosal cells contained mainly lymphocytes and plasma

cells; macrophages and neutrophils were present in smaller numbers. Strands of fibrin lay immediately around the serosal cells while capillary invasion from the parenchyma was evidence of early organization occurring in some of the pigs.

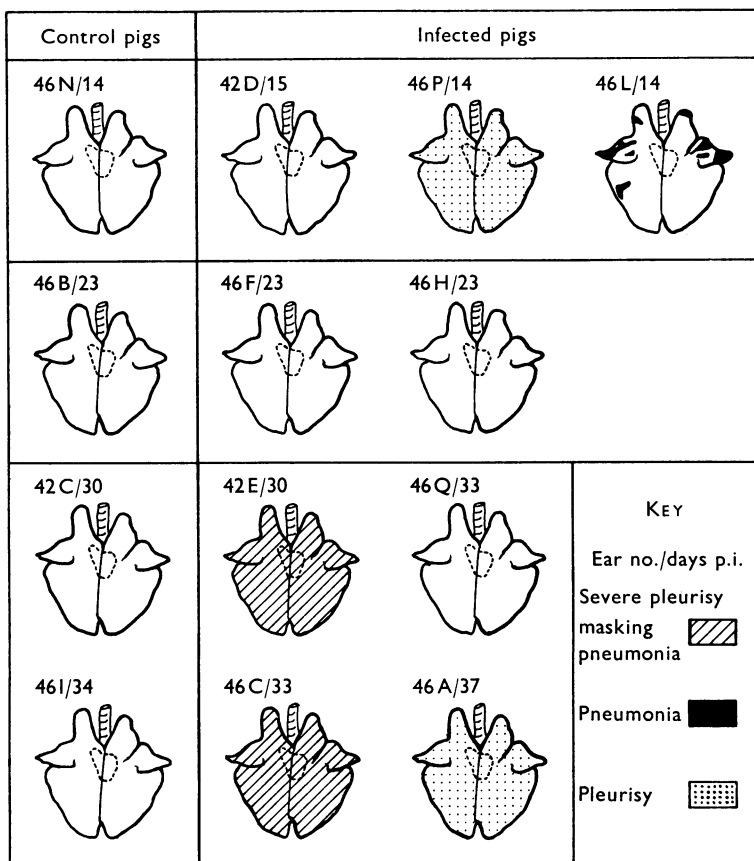


Fig. 1. The incidence of macroscopic lesions in the lungs and pleura of gnotobiotic pigs inoculated with strain TR 32 of *Mycoplasma hyorhinis*.

The incidence and distribution of pneumonia and pleurisy in pigs inoculated with *M. hyorhinis* are summarized in Fig. 1. Of the three pigs killed 14 days p.i., one (46L) had extensive macroscopic lesions in the lungs involving the apical and cardiac lobes of both lungs; one (46P) had developed a diffuse fibrino-purulent pleurisy and pericarditis, and the third pig (42D) did not show any changes macroscopically or microscopically in the lungs or pleura.

The pneumonic lesions in pig 46L were discrete, firm, dark-red areas; microscopically they showed congestion and collapse of the alveolar tissue with considerable exudation of neutrophils and, to a lesser extent, of macrophages. A few mononuclear cells were observed in the lumina of the alveoli and of the bronchioles (Plate 1A). Tissue surrounding the pneumonic areas was emphysematous.

In pig 46P pneumonic lesions were only seen histologically where inflammatory cells spread from the pleurisy into subpleural alveoli. Here some of the alveoli were collapsed and packed with both mononuclear cells and neutrophils (Plate

1 B). The pleurisy varied in its severity. In its mildest forms the mesothelial cells of the visceral pleura were still recognizable, although disrupted and hyperchromatic, and were underlaid by congested capillaries and clumps of neutrophils, while in more severe areas infiltration and proliferation of fibroblasts and mononuclear cells occurred underneath the neutrophils. In the most severe form of the pleurisy the mesothelial cells, where visible, were necrotic and the inflammatory tissue contained a fibrinous exudate which stained positively with Picro-Mallory.

The two pigs killed 23 days after inoculation (46F and 46H) showed no lesions in the lungs or pleura.

Three of the pigs killed between 30 and 37 days after inoculation had severe fibrinopurulent pleurisy and pericarditis. The opacity of the inflamed visceral pleura, with adhesions to pericardium, parietal pleura and diaphragm, made it difficult to assess the extent of the pneumonia macroscopically. However, in two of the pigs sections of lung from apical, cardiac and diaphragmatic lobes all showed engorged capillaries and lymphatics in the inter- and perilobular septa. Mononuclear cells, a few neutrophils and proliferating reticular fibres surrounded these dilated vessels. The material in the lymphatics was eosinophilic and homogeneous but did not stain positively for fibrin. The alveolar tissue round these foci was often collapsed and invaded by mononuclear cells from the interstitial foci (Plate 2A). No cellular exudation was seen in the bronchioles but some peribronchial mononuclear hyperplasia was seen when the surrounding alveolar tissue was totally collapsed and infiltrated with mononuclear cells. The goblet cells of the bronchial epithelium were hyperactive in comparison with control pigs. Perilobular septa connecting the deeper pneumonic foci with the inflamed pleura also had congested capillaries and lymphatics (Plate 2B). The pleurisy in these two pigs showed a considerable degree of organization with capillary invasion, proliferation and orientation of fibroblasts, very few neutrophils and many mononuclear cells.

No lesions were seen macroscopically or histologically in control pigs.

DISCUSSION

The only published work that associates pneumonia with the inoculation of pigs with 'cloned' cultures of *M. hyorhinis* is that of Gois *et al.* (1968). In the present investigation it was felt necessary to avoid gaseous anaesthesia at the time of inoculation because of increased bronchial secretion of mucus, particularly with ether (Lewis's Pharmacology, 1970), and because of the decreased ciliary activity that occurs with some gaseous anaesthetics (Rivera, 1962). The intranasal route was chosen because it simulates 'natural' infection; control pigs were given the same volume of mycoplasma medium as the infected pigs since medium alone has been recorded by Jericho (1968) as causing lymphoid proliferation in the connective tissue of bronchioles in a gnotobiotic pig inoculated 3 weeks earlier both intratracheally and intranasally. Roberts *et al.* (1963*a*), in their extensive investigation, inoculated pigs intraperitoneally and established that *M. hyorhinis* usually attacks mesothelial tissues, causing pleurisy, pericarditis, peritonitis, and synovitis. This classical pattern of response to *M. hyorhinis* was seen in our experiment following the intranasal inoculation of unanaesthetized pigs with TR32 strain of *M. hyo-*

rhinis, but three of the nine pigs also had pneumonic lesions. The pneumonia seen in a single pig killed 14 days after inoculation occurred without pleurisy and was typical of an early bronchopneumonia, although in contrast to the lesions described in 'enzootic pneumonia' (Pattison, 1956) there was little peribronchiolar or perivascular reaction. The pneumonia in two of the four pigs killed between 30 and 37 days after inoculation, however, was quite different in that a severe pleurisy was present in both cases and reaction in the lung occurred around the capillaries and lymphatics in the inter- and perilobular interstitial tissue, spreading from the interstitial tissue into the alveoli without affecting the bronchioles. A similar pattern of change was seen in association with *Haemophilus pleuropneumoniae* infection in pigs (Shope, 1964), although the changes in the pigs due to strain TR 32 of *M. hyorhinae* were not as severe as the changes recorded by Shope.

It thus seems that strain TR 32 of *M. hyorhinae* is sufficiently pathogenic to induce a primary bronchopneumonia as does *M. hyopneumoniae* (Hodges *et al.* 1969), or a pleuropneumonia in which infection spreads from the pleura into the lung via the lymphatics or capillaries of the interlobular septa.

It is interesting that whenever *M. hyorhinae* was re-isolated from pleura, pericardium, peritoneum or joints a lesion had developed at the site of isolation, and if *M. hyorhinae* was not isolated there was no lesion, but in the lungs *M. hyorhinae* was re-isolated from all infected pigs, whilst pneumonic and/or pleural lesions were seen in only five of the nine pairs of lungs. It is suggested that strain TR 32, like other strains of *M. hyorhinae*, usually survives in the trachea and bronchus (therefore in any sample of lung) as well as in the turbinates and tonsil, without stimulating an inflammatory reaction. However, if it survives or localizes in mesothelial tissues it produces there a marked inflammatory reaction, which in the case of the pleura may spread to involve the lung.

This work indicates that at least one strain of *M. hyorhinae* can produce pneumonia in pigs, so that *M. hyopneumoniae* is not the only mycoplasma able to cause pneumonia. This has implications in the diagnosis of enzootic pneumonia. More work is needed, however, to determine the pathogenicity of British strains of *M. hyorhinae* for gnotobiotic and older conventional pigs.

REFERENCES

- BETTS, A. O. & TREXLER, P. C. (1969). Development and possible uses for gnotobiotic farm animals. *Veterinary Record* **84**, 630.
- ESTOLA, T. & SCHULMAN, S. (1966). Isolation of SEP agent from pigs with enzootic pneumonia in Finland. *Acta pathologica et microbiologica scandinavica* **66**, 113.
- GOIS, M., VALICEK, L. & SOVADINA, M. (1968). *Mycoplasma hyorhinae*, a causative agent of pigs' pneumonia. *Zentralblatt für Veterinärmedizin. Reihe B.* **15**, 230.
- GOIS, M., CERNY, M., ROSKOSNY, V. & SOVADINA, M. (1969). Studies on the epizootiological significance of some species of mycoplasma isolated from nasal swabs and lungs of pigs. *Zentralblatt für Veterinärmedizin B* **16**, 253.
- GOIS, M., CERNY, M. & VEZNIKOVA, D. (1970). Relationship between metabolism inhibiting antibodies and colonial growth of *Mycoplasma hyorhinae* and other porcine mycoplasma in the presence of rabbit and pig sera. *Research in Veterinary Science* **11**, 161.
- GOIS, M., POSPISIL, Z., CERNY, M., MRVA, V. & KUKSA, F. (1971). Production of pneumonia after intranasal inoculation of gnotobiotic piglets with three strains of *M. hyorhinae*. *Journal of Comparative Pathology*. (To be published.)

- GOODWIN, R. F. W., POMEROY, A. P. & WHITTLESTONE, P. (1968). Attempts to recover *Mycoplasma suisipneumoniae* from experimental and natural cases of enzootic pneumonia in pigs. *Journal of Hygiene* **66**, 595.
- HARTWICH, J. & NIGGESCHULZE, A. (1966). Zur Frage der ätiologischen Beziehungen von Mykoplasmen zur enzootischen Pneumonie und Rhinitis atrophicans der Ferkel. *Tierärztliche Umschau* **21**, 497.
- HODGES, R. T. (1969). Studies on enzootic pneumonia in pigs. Ph.D. thesis, University of London.
- HODGES, R. T., BETTS, A. O. & JENNINGS, A. R. (1969). Production of pneumonia in gnotobiotic pigs with pure cultures of *M. hyopneumoniae*. *Veterinary Record* **84**, 268.
- JERICHO, K. W. (1968). Studies of the intrapulmonary lymphoid tissue of pigs in health and disease. Ph.D. thesis, University of London.
- L'ECUYER, C., SWITZER, W. P. & ROBERTS, E. D. (1961). Microbiological survey of pneumonic and normal swine lungs. *American Journal of Veterinary Research* **22**, 1020.
- LEWIS'S PHARMACOLOGY (1970). 4th edition, p. 671. Edinburgh and London: E. and S. Livingstone.
- PATTISON, I. H. (1956). A histological study of a transmissible pneumonia of pigs characterised by extensive lymphoid hyperplasia. *Veterinary Record* **68**, 490.
- RIVERA, J. A. (1962). *Cilia, Ciliated Epithelium and Ciliary Activity*. International Series of Monographs on Pure and Applied Biology, vol. 15, London: Pergamon Press.
- ROBERTS, E. D., SWITZER, W. P. & RAMSEY, F. K. (1963a). Pathology of the visceral organs of swine inoculated with *Mycoplasma hyorhinis*. *American Journal of Veterinary Research* **24**, 9.
- ROBERTS, E. D., SWITZER, W. P. & RAMSEY, F. K. (1963b). The pathology of *M. hyorhinis* arthritis produced experimentally in swine. *American Journal of Veterinary Research* **24**, 19.
- ROSS, R., SWITZER, W. P. & MARE, C. J. (1963). Incidence of certain micro-organisms in Iowa swine. *Veterinary Medicine* **58**, 562.
- SCHEER, M., HARTWICH, J. & SANDERSLEBEN, J. v. (1969). Experimental infection of pigs with mycoplasma strains. *Acta veterinaria Academiae scientiarum hungaricae* **19**, 131.
- SHOPE, R. E. (1964). Porcine contagious pleuropneumonia. *Journal of Experimental Medicine* **119**, 357.
- SWITZER, W. P. (1955). Studies on infectious atrophic rhinitis. IV. Characterisation of a pleuropneumonia-like organism isolated from the nasal cavities of swine. *American Journal of Veterinary Research* **16**, 540.
- SWITZER, W. P. (1964). Mycoplasmosis. In *Diseases of Swine*, 2nd ed. (ed. H. W. Dunne), p. 503. Ames, Iowa: Iowa State University Press.
- WRIGHT, D. N., BAILEY, G. D. & HATCH, M. T. (1968). Role of relative humidity in the survival of airborne *Mycoplasma pneumoniae*. *Journal of Bacteriology* **96**, 970.

EXPLANATION OF PLATES

PLATE 1

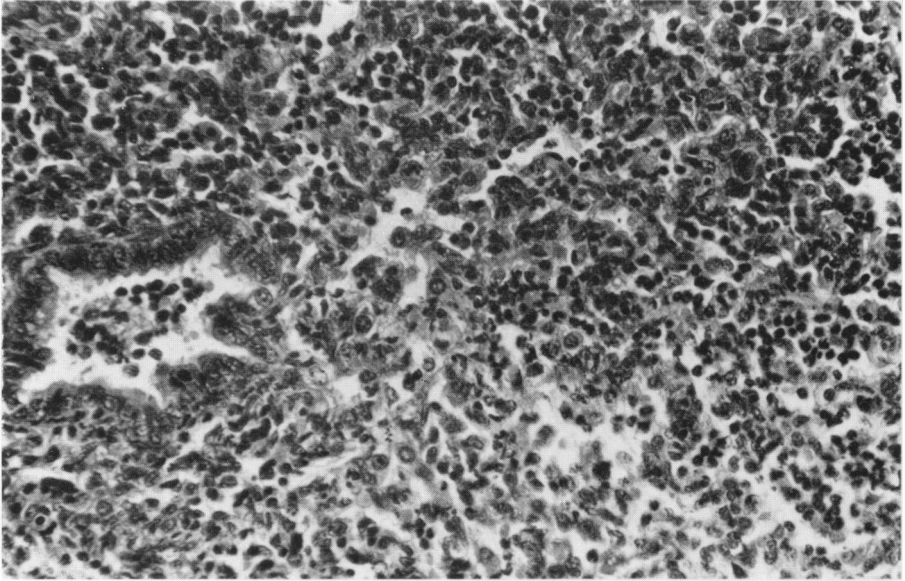
(A) Lung 14 days after inoculation with *Mycoplasma hyorhinis*, showing collapse of the alveoli with exudation of neutrophils and some mononuclear cells. Cells can also be seen in the lumen of the bronchiole. H. and E., × 100.

(B) Pleura 14 days after inoculation with *Mycoplasma hyorhinis* showing fibrino-purulent pleurisy with inflammatory cells from the pleurisy invading the underlying alveolar tissues. H. and E., × 40.

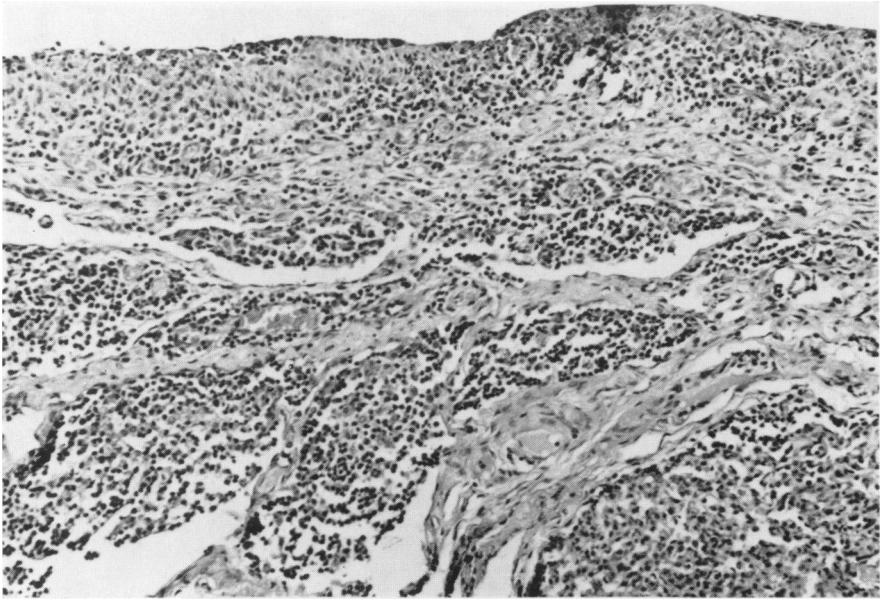PLATE 2

(A) Lung 32 days after inoculation with *Mycoplasma hyorhinis*. The interlobular septa are dilated with mononuclear cells and a few neutrophils while the lymphatics are distended with an eosinophilic homogeneous exudate. The surrounding alveolar tissue is collapsed and on the left inflammatory cells can be seen spreading from the interlobular connective tissue into the alveolar tissue. H. and E., × 40.

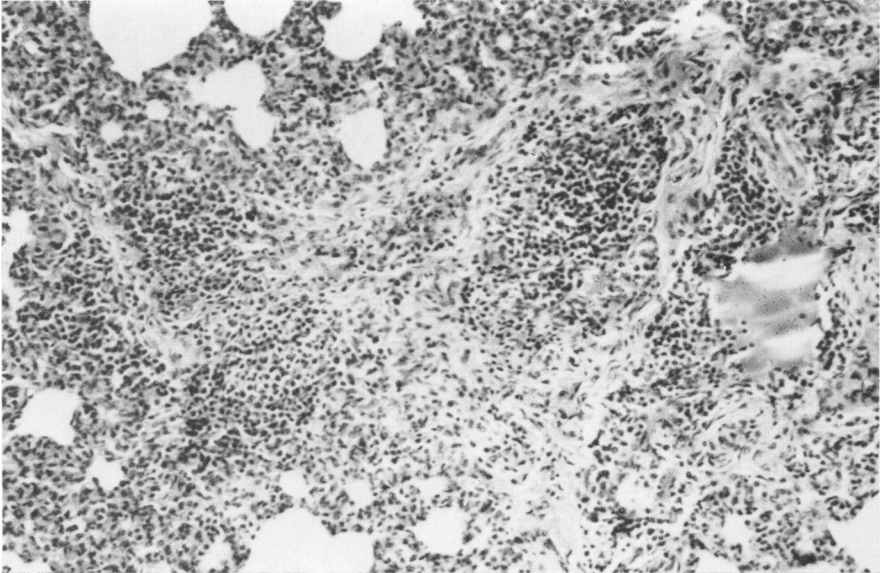
(B) Lung 30 days after inoculation with *Mycoplasma hyorhinis*. The interlobular septum is engorged by inflammatory cells and both capillaries and lymphatics are dilated. There is no involvement of the surrounding alveolar tissue. This inflamed septum ran from the inflamed pleura (as in Plate 1B) to a deeper focus of pneumonia (as in A). H. and E., × 40.



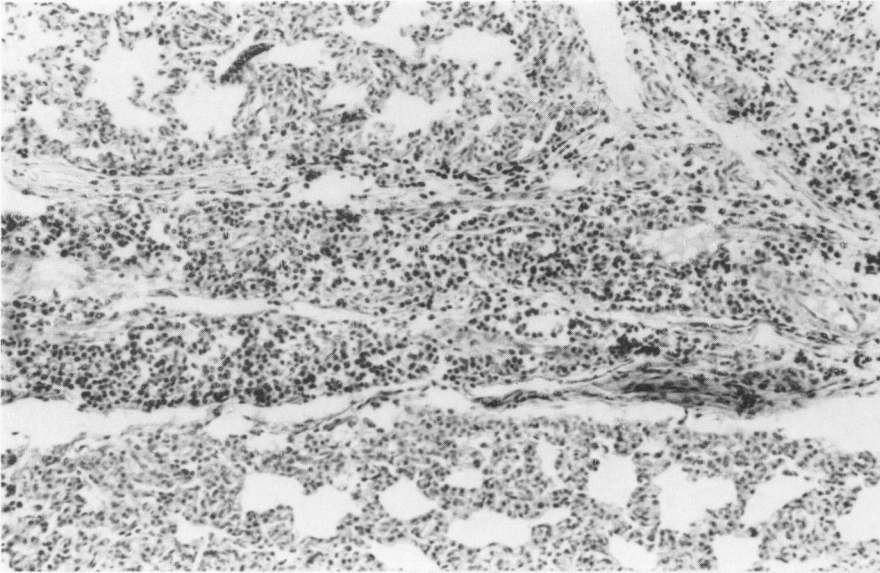
A



B



A



B