

FOCAL INTERSTITIAL NEPHRITIS IN THE CALF FOLLOW-
ING INTERFERENCE WITH THE NORMAL INTAKE
OF COLOSTRUM.

By THEOBALD SMITH, M.D.

(From the Department of Animal Pathology of The Rockefeller Institute for Medical
Research, Princeton, N. J.)

PLATES 15 TO 17.

(Received for publication, January 8, 1925.)

The nephritis to be considered was first seen by the writer in 1917 during an epidemic of pneumonia in calves ultimately traced to an, at that time, undescribed bacillus, *Bacillus actinoides*. It consists in a whitish, patchy discoloration of the kidney surface, seen after the capsule has been removed. The patches vary in size and correspond to similar changes in the cortex which extend through to the medullary border. In a few cases the entire cortex was whitish and the organ enlarged. At the time it was supposed that the lesions were secondary to the pneumonia, but the failure to detect *Bacillus actinoides* did not support this view. The existence of *Bacillus abortus* in the herd and the not infrequent cases of abortion suggested the possible relation of *Bacillus abortus* to the lesions. This supposition was also disposed of by the negative cultures. During the investigations of the relation of colostrum to the early diseases of the newborn calf, it became more and more evident that the nephritis, like the multiple arthritis, was a result of the bacteriemia brought about by incomplete colostrum protection. The almost exclusive presence of *Bacillus coli* in the early septicemias and its presence in small numbers in the organs of incompletely protected calves during the 1st and 2nd weeks of life focused attention upon *Bacillus coli* as the factor concerned in the nephritis.

The white-spotted kidney (*weisse Fleckniere*, *nephritis maculosa alba*) had been known for a number of years to inspectors in German abattoirs as occurring in otherwise normal calves, and a fairly rich literature has accumulated around it.

Up to 1923, the studies dealing with the spotted kidney were almost exclusively of a descriptive nature. Of these the most complete is the article by Sakaguchi.¹ The author very briefly describes the gross and microscopic characters of 68 kidneys obtained from abattoirs and gives a résumé of the earlier descriptions with special reference to the groups or classes into which preceding observers had divided the material. He also summarizes the bacteriological observations of others and shows that the results were chiefly negative. Rarely staphylococci and streptococci appeared in cultures. Sakaguchi himself examined the renal lymph nodes and found in films from seven cases very small Gram-positive rods, and from four other cases staphylococci. Sections of the kidney lesions in twenty cases were as a rule negative for bacteria.

In 1923 Pfenninger and Krupski^{2,3} presented facts with reference to this disease which materially advanced our knowledge of the etiology. They point out the importance of studying early cases and the difficulty of obtaining calves 10 to 14 to 21 days old at the abattoirs. The authors examined 48 cases, of which 28 were cultured. These were from 1 to 6 weeks old. They describe the disease as an embolic, interstitial focal nephritis with a tendency to fibrosis. In cultures the chief species was *B. coli*, more rarely cocci and other bacteria.

This brief review shows that Pfenninger and Krupski and the writer have reached independently the same conclusion—that *Bacillus coli* is the dominating bacteriological factor. To this we may now add another of a very different nature, a deficiency in passive resistance on the part of the calf due to insufficient colostrum protection. Three lines of proof are at hand to associate the nephritis with colostrum deficiency. One is the fatal *Bacillus coli* septicemia following the complete exclusion of colostrum from the diet. The second is the sterility of the kidney tissue in calves fed colostrum early and in sufficient quantity, even when scours terminates in death. The third is the actual production of the spotted kidney in calves which either have had no colostrum and have survived the early septicemia, or else have had the intake of colostrum modified in some way.

Sixteen cases of early nephritis have been autopsied. Of these, six belong to the epidemic of pneumonia in 1917 referred to above (Nos. 9, 11, 12, 13, 14, and 15); one to a later epidemic (No. 508.) One was affected with coccidiosis (No. 102), and one was free from

¹ Sakaguchi, Y., *Frankf. Z. Path.*, 1917, xx, 57.

² Pfenninger, W., and Krupski, A., *Schweiz. Arch. Tierheilk.*, 1923, lxx, 1.

³ Pfenninger, W., *J. Am. Vet. Med. Assn.*, 1924, lxx, 168. See the same authors and Sakaguchi¹ for the literature.

other diseases (No. 469). The history of the rest, seven in all, is known. No. 1052 received at first a substitute globulin and then colostrum on the 2nd day; Nos. 1125, 759, and 495 received only cow's milk at the start; Nos. 935 and 936 received cow's serum and milk in place of colostrum; No. 930, milk during the 1st day and then colostrum. Concerning the early history of the nine spontaneous cases the following may be stated. After the nephritis had been produced by the limitation or elimination of colostrum, this rather large series of diseased kidneys was naturally ascribed to some change in the treatment of calves during the 2 or 3 first days of life. However, no definite information was obtainable. If colostrum was not withheld, it is probable that there was some delay in the first meal in so far as the calves may have been too weak to suckle. In the other group, to which colostrum was not given or else given late, the relationship between the spotted kidney and colostrum deficiency is obvious. Control observations have not been specially made, but there is at present no record of any calf, normally colostrum-fed, with spotted kidneys at autopsy.

To trace the relation between the early infection with *Bacillus coli* and the lesions encountered, at the earliest, 2 weeks later, we may divide the conditions met with into two groups: (1) *Bacillus coli* septicemia; (2) *Bacillus coli* bacteriemia, followed by localizations in some one or more of the following organs or tissues,—joints, kidneys, umbilical stump, and lungs.

1. *Bacillus coli* Septicemia.⁴—This type of disease has been brought about by substituting milk for colostrum. Death may occur on any one of the 4 first days of life. *Bacillus coli* is present in all organs and joints and forms a nearly pure culture in the lower small intestine. The changes in the kidneys are intense congestion of the entire organ which gives the cut surface a uniformly dark red appearance to the tips of the papillæ. All capillaries are distended with red cells in the medulla; in the cortex the injection is more focal. In the injected areas there is evidence of rupture of the capillaries and the presence of red cells in the interstitial tissue and more rarely within convoluted tubules. Groups of *Bacillus coli* may be found in capil-

⁴ Smith, T., and Little, R. B., *J. Exp. Med.*, 1922, xxxvi, 181.

larities of the glomeruli (Fig. 2) and the medulla (Fig. 1). The characteristic condition in this group is the intense congestion and presence of *Bacillus coli* in the capillaries. A reaction on the part of the tissues is rare and then indicated only by a phagocytosis of the invading bacilli by polymorphs. Illustrations of this type of disease have been given elsewhere.⁴

Only one animal (No. 717,^b Fig. 1) has thus far come under observation which survived the feeding of milk in place of colostrum and succumbed on the 11th day to an acute *Bacillus coli* septicemia. Thus of eight other calves deprived of colostrum, four died when 2 days old, two when 3 days old, one when 4, and one when 5 days old, all of *Bacillus coli* septicemia. The delay in the beginnings of the disease in No. 717 suggests that the calf escaped infection with the particular virulent strain of *Bacillus coli* for 9 or 10 days.

2. *Bacillus coli* Bacteriemia.—The partial resistance of the calf's tissues to *Bacillus coli* leads to a limited multiplication of this organism in various tissues, producing either a hemorrhagic and fibrinous exudate in certain joint cavities, or an interstitial nephritis. Both kinds of localizations are usually present. It is this group which furnishes the white-spotted kidney.

Brief Description of Individual Cases.

The evolution of the lesions is best followed by arranging the animals in a series beginning with the youngest showing the spotted condition.

No. 1052 (Fig. 4).—Calf fed with a substitute globulin, prepared by Dr. P. E. Howe, together with some milk in place of normal colostrum. On the 2nd day when diarrhea set in, it was fed colostrum from a bottle until nearly 3 days old; thereafter milk. Diarrhea continued with general weakness until the 6th day when the calf became brighter and more active but with evidences of pain in certain joints. When 13 days old the calf appeared normally active. It was killed and autopsied on this day.

All viscera except kidneys and lungs were normal. The former were involved alike. Scattered over all lobes are white areas from 1 to 5 mm. apart, in some lobes more numerous than in others. A median section shows the surface spots to be the bases of foci of similar color, oval or round or elongated, with longer axis

⁵ Smith, T., and Little, R. B., *J. Exp. Med.*, 1922, xxxvi, 195.

radial, and in general extending through the cortex. The foci represent rather firm tissue, not projecting above the surface and not surrounded by any hyperemic zone. Renal lymph nodes swollen. The caudal half of the ventral lobe of the right lung airless, pinkish to grayish in color, with numerous petechiæ dotting the surface. Both tarsal joints diseased. In the right, about 3 cc. of a turbid, slightly viscid fluid, containing many polymorphs and larger mononuclear elements. The left joint contains a mould of fibrin, permeated with leucocytes.

Cultures made with bits of tissue indicate the presence of a few *B. coli* in spleen and liver. The kidney cultures at this stage were sterile.

The urine was followed from the 1st day. It was clear for 2 days, and contained a trace of protein and some reducing substance. Thereafter it was cloudy when passed and the filtrate contained from 1/8 to 1/40 column of coagulable protein after boiling. Microscopic examination showed the presence of short, straight cylinders, composed probably of necrotic cell masses. These casts, from 0.016 to 0.04 mm. in diameter, caused the cloudiness. Their size brings them within the range of the larger collecting tubules. The reducing substance disappeared after the 2nd day.

Sections of kidney tissue fixed in Zenker's fluid and stained in hematoxylin and eosin and eosin and methylene blue showed, when viewed with the naked eye, the cortical lesions as more deeply stained, irregular lines, isolated or grouped into larger foci. The focal character of the lesions is clearly shown under low powers. The foci vary from a few tubules in diameter to such as are 4 or 5 mm. in diameter. In the smallest lesions, there is cellular infiltration between the convoluted tubules, consisting of mononuclear types, probably lymphocytes, and larger mononuclear elements intermingled. In larger foci there is added a filling up of many of the included tubules with polymorphs. The interstitial infiltration consists of elements with elongated, bent, irregular nuclei, and polymorphs. The epithelium of the tubules when recognizable has very large nuclei. As a rule, in the larger foci the infiltration is dense and the original structures barely distinguishable. In a few foci the cellular elements are enclosed in a fibrin meshwork and the imprisoned cell nuclei breaking up into irregular chromatin fragments. Some of the glomeruli are destroyed, others intact. In the lymph sinuses of the renal nodes, groups of polymorphs.

No. 469.—Guernsey female, obtained when 15 days old in an emaciated condition. Nothing definite known of its history, except that, according to attendant, it had passed through scours. The animal was killed on this day. The autopsy showed more or less congestion and edema of the mucous membrane of the fourth stomach, and slight, patchy congestion of the small intestine. In the large intestine the rectal mucosa is congested. In the lungs scattering lobules in a state of collapse. Both kidneys contain firm, white foci in the cortex, from 1 to 6 mm. in diameter. Some project slightly above the surface. Others are just visible. Some are embedded and disclosed only on section. Cultures from kidneys, spleen, and liver remained sterile.

The sections of the kidney lesions present processes very much like those found in the preceding case (No. 1052). There are, however, absent the localized fibrinous exudates and attendant necrosis of the cell exudate. The largest foci show the same filling up of tubules with casts of polymorphs as in No. 1052. There is also active in parts of the focus the development of fibroblasts, associated with mitotic figures and scattered plasma cells. In these areas the kidney structures, except the glomeruli, are no longer recognizable. The latter show no distinct changes. The small lesions are still wholly cellular.

No. 12.—Received and killed when 23 days old. Both lungs found involved. In the kidneys scattering, white, lardaceous foci, 1 to 2 mm. in diameter were found confined to a single lobe. Cultures negative. Sections showed advancing fibrosis, with some plasma cells and foci of lymphocytes. Polymorphs absent.

No. 13.—This animal also was affected with pneumonia when received, at the age of 23 days. It was killed on this day. The pneumonia involved the smaller lobes of both lungs. In both kidneys the cortex was permeated with whitish, lardaceous foci, occupying about one-third of the entire cortex. Cultures negative.

Sections show numerous discrete foci in the cortex with some normal tissue separating them. Beginning at or near the surface of the organ, the foci at first broad tend to narrow and extend in the columns of Ferrein to the medulla. The process is essentially as in the cases described. The intertubular tissue is broadened by the invasion of endothelial leucocytes and linear and compact groups of plasma cells. Fibrosis is still in the background. Some of the convoluted tubules contain casts of polymorphs.

No. 1125 (Fig. 3).—This animal is of interest in that it was fed on cow's milk from the start. Without going into details at this time, we may simply state that arthritis was quite evident on the 10th day. Samples of urine obtained daily were without the heavy proteinuria quite regularly present in colostrum-fed animals. There was a distinct clouding of the fluid passed after the 8th day. The filtrate presented a faint clouding after the heat test, rising gradually to about 0.1 per cent (Esbach) on the 22nd day. The original clouding after sedimentation appeared as a thick, viscid, dough-like deposit of slight amount, which was made up chiefly of triple phosphate crystals, some mucus, and a few polymorphs.

The calf was killed when 23 days old. The following lesions were found: In both shoulder and hock (tarsal) joints, the synovial fluid is clouded. The joint surfaces are lined with a fibrinous pseudomembrane. The clouding of the fluid is due to polymorphs. In the stump of the right umbilical artery and resting on the urinary bladder is an enlargement about 2 cm. in diameter, embedded in edematous tissue. Within the enlarged vessel is a gray thrombus enclosed in the thickened, discolored walls of the vessel. Both kidneys are somewhat enlarged. The cortex is uniformly pale. When the organ is halved, the entire cut surface of the cortex is of a pale yellowish white color, with slightly more opaque radial lines running through it. These in fresh sections are seen to be casts covered with minute crystals.

Sections show a diffuse lesion of the cortex leaving but little tissue of normal appearance. The usual compact foci are absent. The secreting structures are forced slightly apart by fibroblasts and plasma cells, but on the whole the cellular increase is not conspicuous. There is probably some general slight interstitial edema to emphasize the changes. Some tubules are distended and partly filled with polymorphs and lymphocytes. Others contain faintly tinted hyaline casts. Under high powers the epithelium of many convoluted tubules is normal, possibly slightly hypertrophied as a result of the contracted functioning area.

*No. 936.*⁶—This calf was fed cow serum in milk in place of colostrum. It manifested lameness and swelling of joints from time to time. It was killed at an abattoir when 24 days old and reported normal with exception of the kidneys. These were brought to the laboratory. Both were encased in a rich layer of fat and the capsule readily stripped off. In the cortex, of normal color, are embedded white, subcircular areas, from 2 to 8 mm. in diameter, with a tendency to coalesce into larger patches. There are up to a dozen in each lobe. They project just enough to be felt by the finger passing over them and are slightly firmer than the intervening normal cortex. On median section, they correspond to smooth, white masses, glistening like cartilage, sharply outlined, without inflammatory border. With base near or at surface, they taper to medulla. Medulla entirely free. Cultures negative.

Sections from different regions of the kidneys present essentially the same process. The lesions appear as large and small foci. In general there is in them a diffuse increase of interstitial tissue due chiefly to fibroblastic elements. Polymorphs occur sparsely in the interstitial tissue and more frequently as casts or cylinders in the convoluted tubules. In some foci these casts dominate the picture. More rarely, groups of lymphocytes are within the foci, usually partly enveloping a glomerulus.

No. 935.—This animal and No. 936 were born on the same day and treated alike.⁶ It was slaughtered on the same day with No. 936. The kidneys brought to the laboratory might have passed as normal, but close scrutiny shows in many lobes groups of points a trifle lighter than the enveloping normal cortex. They correspond on the median section to narrowly triangular, paler areas, about 1 mm. at surface of kidney and extending to medulla. In sections of fixed tissue these foci are easily overlooked for they are small and characterized chiefly by a slight broadening of the intertubular tissue with fibroblasts and a slight distortion of the normal arrangement. Polymorphs and other types of inflammatory exudate cells are absent.

No. 759.—This animal was successfully brought to the 26th day of life although it had not received any colostrum. It was killed on this day. The case is briefly sketched elsewhere.⁷ In addition to the arthritis, spotted kidneys were found at

⁶ Smith, T., and Little, R. B., *J. Exp. Med.*, 1922, xxxvi, 460.

⁷ Smith, T., and Little, R. B., *J. Exp. Med.*, 1922, xxxvi, 196.

the autopsy. In sections there were the usual connective tissue hyperplasia, and in addition dense groups of lymphocytes within the areas undergoing fibrosis. These are tentatively associated with bacteria other than *B. coli*, which appeared in very small numbers in the cultures. Among them were streptococci, streptobacilli, and a spore-bearing anaerobe.

No. 9.—Dies when 31 days old. Pneumonic condition of the smaller lobes of both lungs. Both kidneys instead of exhibiting the discrete spots were of a uniformly whitish color and firm consistency. In sections there is very little normal tissue to be seen. A diffuse fibrosis involves the major portion of the tissue in the sections. Some tubules contain moulds of polymorphs, but they are relatively rare. The epithelium of the convoluted tubules is changed to a less differentiated type. Some tubules are compressed and without lumina. The glomeruli, although not noticeably diminished in numbers, are contracted, oval, distorted, the capillary tuft partly lost. Only a few appear normal.

No. 11.—This calf was received and killed when 31 days old and pneumonia diagnosed. At the autopsy pneumonic lesions were found similar to those of No. 9. The cortex of both kidneys was permeated with whitish specks, somewhat star-shaped and several mm. in diameter. Cultures remain sterile. In sections, the foci in the kidneys are fairly numerous, but microscopic, and tend to a linear shape taking a radial direction. In the larger foci visible to the unaided eye, fibrosis is well under way. Besides the nuclei of fibroblasts few other cells are in evidence. There are the usual distortion and forcing apart of the convoluted tubules, the changes in form and staining character of the epithelium, the distortion of the glomeruli, and a general defect of secreting structures. In the minute foci, the fibrosis tends to follow the straight tubules in the columns of Ferrein to the medulla.

No. 508.—Calf received and killed when 31 days old, affected with pneumonia. This case was briefly described elsewhere⁸ with special reference to the pneumonia. In several of the cephalic lobes of both kidneys are circular white areas, 1 to 1.5 mm. in diameter, and about 1 cm. apart. On section these spots correspond to roundish, white, lardaceous masses in the cortex. In each kidney one of these foci is enveloped in intensely congested tissue. Cultures from the cortex contain besides *B. pyogenes*, several putrefactive forms. *B. pyogenes* was probably derived from the lungs, where this organism entered into the bacterial complex there existing. In sections the foci were small as indicated above. They were chiefly triangular with bases at the surface of the organ or else roundish and slightly below the surface. They are due to a diffuse infiltration of plasma cells and to fibroblasts. Polymorphs present in some foci and gathered chiefly in the convoluted tubules.

No. 15.—Received as a sick calf when 35 days old. Pneumonia suspected. Killed and autopsied. Both ventral lobes of lungs were pneumonic. Numerous foci of collapse and consolidation in other lobes. The cortex of both kidneys was spotted with white patches 2 to 5 mm. in diameter and about 3 to 5 mm. apart. They were like the earlier cases in appearance and consistency. In sections the

⁸ Smith, T., *J. Exp. Med.*, 1921, xxxiii, 451.

foci show a decided increase in the intertubular tissue contributed by fibroblasts and plasma cells and emphasized by some edema. Some moulds of polymorphs in tubules. The foci are, however, much poorer in cellular elements than in younger stages. The epithelium of the tubules enclosed in the foci is heaped up in several layers in some tubules, giving the lumen an irregularly contracted outline.

No. 495 (Fig. 5).—Calf born and reared in Department units. It was used when 26 days old in an inoculation experiment with *B. actinoides*. Since its history is given elsewhere,⁹ only certain points bearing on the spotted kidneys found at the autopsy are relevant at this time.

The calf was reared without colostrum. It was killed when 42 days old. There were slight pulmonary lesions produced by the inoculation of *B. actinoides* into the trachea. Both kidneys were spotted with discrete and confluent, white patches, occupying fully one-half of the total area of the kidney surface. Cultures negative. Corresponding with the longer life of the calf, the lesions were further advanced in fibrosis than cases already described. The fibrous tissue between tubules and around glomerular capsules and vessels was conspicuous. Many tubules are irregularly dilated; similarly the capsular spaces of the glomeruli. Some of the tufts are dwarfed. The epithelium of the dilated tubules is very low. In addition to the fibroblasts the intertubular tissue contains small groups of cells of plasma type. Polymorphs within tubules as well as in the interstitial tissue are rarely seen.

No. 14.—Calf received when 2 months old, in poor condition. Skin dry. Temperature 40.2°C., pulse 80, respiration 70. Nasal discharge. Coughs at times. Killed and autopsied. Both lungs are pneumonic. The process involves both cephalic and ventral lobes *in toto* and isolated collapsed lobules throughout the caudal lobes. Both kidneys are symmetrically diseased. The dimensions are one and a half times the normal. When the capsule is removed, the surface appears uniformly opaque, whitish. In the median section only a little of the cortex here and there suggests the normal tissue. All the remainder is of a whitish, waxy appearance, faintly striated radially, and quite firm to the touch. There is some slight bulging of the cut surface. The medulla is not involved. Cultures negative. The sections indicate extensive interstitial fibrosis in foci, both linear and broadly expansive. Within the foci, kidney structures effaced with the exception of some glomeruli whose capsule is thickened and capsular space expanded and irregular. Certain convoluted tubules within the sclerotic foci traceable, because filled with polymorphs.

No. 102.—This animal was 2½ months old when obtained as affected with pneumonia and having had repeated diarrhea. Calf emaciated. Skin dry. Respiration and pulse rapid. Temperature slightly above normal. Killed and autopsied. The only gross lesions were pale red consolidation of both cephalic lobes of the lungs and generally pale whitish color of both kidneys. The heart weighed 490

⁹ Smith, T., *J. Exp. Med.*, 1921, xxxiii, 457.

gm. and was manifestly hypertrophied. Coccidia cysts present in flakes of mucus from the rectum.

In the cortex of the kidneys there is very extensive formation of fibroblasts over larger and smaller areas. The smaller ones tend to be broadly elongated with long axis radial and following the columns of Ferrein. In these foci functioning tubules are mostly absent. Glomeruli are still present, with capsules generally thickened by the apposition of several layers of fibroblasts. Foreign cells other than the latter are no longer in evidence. Throughout the sections are small areas of normal convoluted tubules.

No. 930 (Fig. 6).—This animal received cow's milk until 22 hours after birth, when it was fed colostrum.¹⁰ It passed through an early period of diarrhea. Constipation was noticed when the calf was 35 days old and continued until it was killed at the age of 2½ months. During this latter period it was repeatedly treated with enemas, twice with epsom salts, and once with castor oil. The calf was killed as of no further use when 2½ months old. The only organs manifestly diseased were the kidneys. Both are covered with a layer of glass-clear, edematous tissue, from ½ to 1 cm. thick. The edema extends to the mesenteries of the adjoining small and large intestines. The capsule is easily stripped. The kidneys then appear as pale white organs, peppered with dark red points. Both are larger than normal (15 by 9 by 5 cm.). Their combined weight is 575 gm. The cortex shows the same whitish appearance and dark red points on median section. Urine taken from the bladder is pale, watery, with a specific gravity of 1.010. It is clouded when acetic acid is added. The heat test yields 0.22 per cent coagulable protein (Esbach). No reducing substances present.

The intestines are without noteworthy changes, except the cecum which is within the edematous zone. The mucosa is nearly black with pigmentation, which is arranged in arborescent lines along the blood vessels. The heart is flabby and weighs 450 gm.

The histological picture differs somewhat from the other cases described in that besides the fibrosis and edema there are dense groups of lymphocytes and of plasma cells throughout the cortex. In some areas both cell types are present and in adjoining groups but not intermingled.

DISCUSSION.

The nephritis as encountered in the cases briefly outlined is obviously identical with the spotted kidney of European observers. The fact that in a few instances the entire kidney was white is accounted for by the extent and diffuseness of the process. The enlargement of the white kidney in one instance (No. 930) was associated with an edema of the organ and capsule. Earlier writers have given much

¹⁰ Smith, T., and Little, R. B., *J. Exp. Med.*, 1924, xxxix, 307.

attention to the anatomical groupings of cases of the spotted kidney. Except as a means of analyzing the process and correlating it with the age of the animal, anatomical groups are made unnecessary on account of the etiological unity underlying them.

The process is in all cases focal and interstitial and limited to the cortex. In the earliest cases of the series (13 to 15 days) the lesion is represented largely by cellular exudates, lymphocytes and polymorphs, the latter forming also cylindrical moulds in some of the convoluted tubules. With the increasing age of the calf the exudative cellular elements tend to give way to plasma-like cells and fibroblasts, and in the oldest animal (2½ months) the polymorphs and plasma cells had entirely disappeared. In the one animal with the large, white, edematous kidneys, the new fibrous tissue was associated with dense groups of lymphocytes and larger, plasma-like cells. The two types of cells did not mingle, although they might form contiguous groups.

The secreting structures of the cortex are only secondarily involved. In sections stained according to Van Gieson and with Mallory's aniline blue connective tissue stain, it is possible still to distinguish the epithelium of the convoluted tubules within the dense foci. The tubules in the main are compressed and without visible lumina. In those patent, there may be an irregular increase in the number of epithelial cells, forming small elevations within the tubes. Mitoses in the epithelial layer are not infrequent. The lumen is frequently filled with polymorphs in the early stages and the epithelium low and flattened. Casts of a homogeneous substance are occasionally seen. The capsules of the glomeruli in the foci are thickened by several layers of fibroblasts and in the older cases the size of the capsular space may be doubled and the form distorted. The tufts may be of normal or reduced size.

The medulla is free from focal lesions. Rarely cell casts are found in the collecting tubules and there may be more or less injection of the straight vessels. The urine in the older cases is pale, of low specific gravity, and without formed elements in appreciable numbers. There is usually a trace of clouding after the heat test.

Cultures of relatively large pieces of cortical tissue have remained sterile with few exceptions. This is accounted for by the ages of the animals. *Bacillus coli* is probably more quickly disposed of than are

the more parasitic types of bacteria, such as streptococci and *Bacillus pyogenes* should they gain entrance. On the other hand, it may be hardier than other intestinal forms, such as enterococci, which have access to the body proper when the calf is deprived of colostrum. Slight differences in the reaction of the tissues may be due to the varying character of the invading flora. The overshadowing dominance of certain types of *Bacillus coli* in the early cases before macroscopic lesions are in evidence obscures the presence of other forms and maintains a fair uniformity of the lesions. Other observers (Pfenninger and Krupski;^{2,3} Christiansen¹¹) have obtained a larger number of positive cultures from spotted kidneys because their animals were, as a rule, younger than the ones used in this study.

Next to the predisposition created by a deprivation of colostrum or the delay of the first feeding, the existence in the herd or environment of special, more virulent types of *Bacillus coli* is a necessary antecedent of the nephritis. The lodgment of *Bacillus coli* and temporary multiplication lead to extreme congestion and paralysis of the capillary area followed by hemorrhage. In this favorable nidus *Bacillus coli* may continue multiplication for a time. The larger the original area of congestion and hemorrhage, the larger the resulting inflammatory focus. *Bacillus coli*, which appears to be without the requisite resisting qualities, is soon checked and destroyed and the fibrosis is the end-result.

Nothing definite is known of the fate of the spotted kidneys. Sakaguchi¹ examined a small number of kidneys of older animals, but the lesions found may have been due to other later invasions. The relative infrequency of lesions in older animals lends support to the view that the white foci disappear through absorption and contraction of the fibrous tissue with loss of the enclosed parenchyma. The resulting scars may be inconspicuous and recognizable only when the focal lesion is large at the start. It is of interest to recall the fact that the copious discharge of protein in the urine of colostrum-fed calves has no further pathological significance. On the other hand, in calves not fed colostrum the originally normal urine later shows pathological ingredients (protein, casts, polymorphs) indicative of the inflammatory processes described.

¹¹ Christiansen, quoted by Joest, E., in *Spezielle pathologische Anatomie der Haustiere*, Berlin, 1923, iii, 302.

CONCLUSIONS.

An interstitial focal nephritis found in young calves during the 1st or later months of life, associated with or preceded by the invasion of a special, virulent type of *Bacillus coli*, may be produced by postponing the feeding of colostrum 24 to 36 hours, or by withholding it altogether. In the presence of a virulent type of *Bacillus coli* few calves completely deprived of colostrum survive the 1st week. Among the survivors, the spotted kidney, the result of *Bacillus coli* bacteriemia, is frequently encountered. Calves normally fed have not shown the spotted kidney, and such as have been killed early have had uniformly sterile kidneys.

EXPLANATION OF PLATES.

The figures are photomicrographs of sections of kidney tissue fixed in Zenker's fluid and alcohol and stained in eosin and methylene blue.

PLATE 15.

FIG. 1. Kidney of Calf 717 (see page 416 of text). In center of figure are two joining capillaries filled with *B. coli*. $\times 779$.

FIG. 2. Kidney of calf, dead of scours when about 1 day old. A capillary loop of a glomerulus filled with bacilli. Cultures of kidney tissue indicated presence of large numbers of *B. coli*. $\times 961$.

PLATE 16.

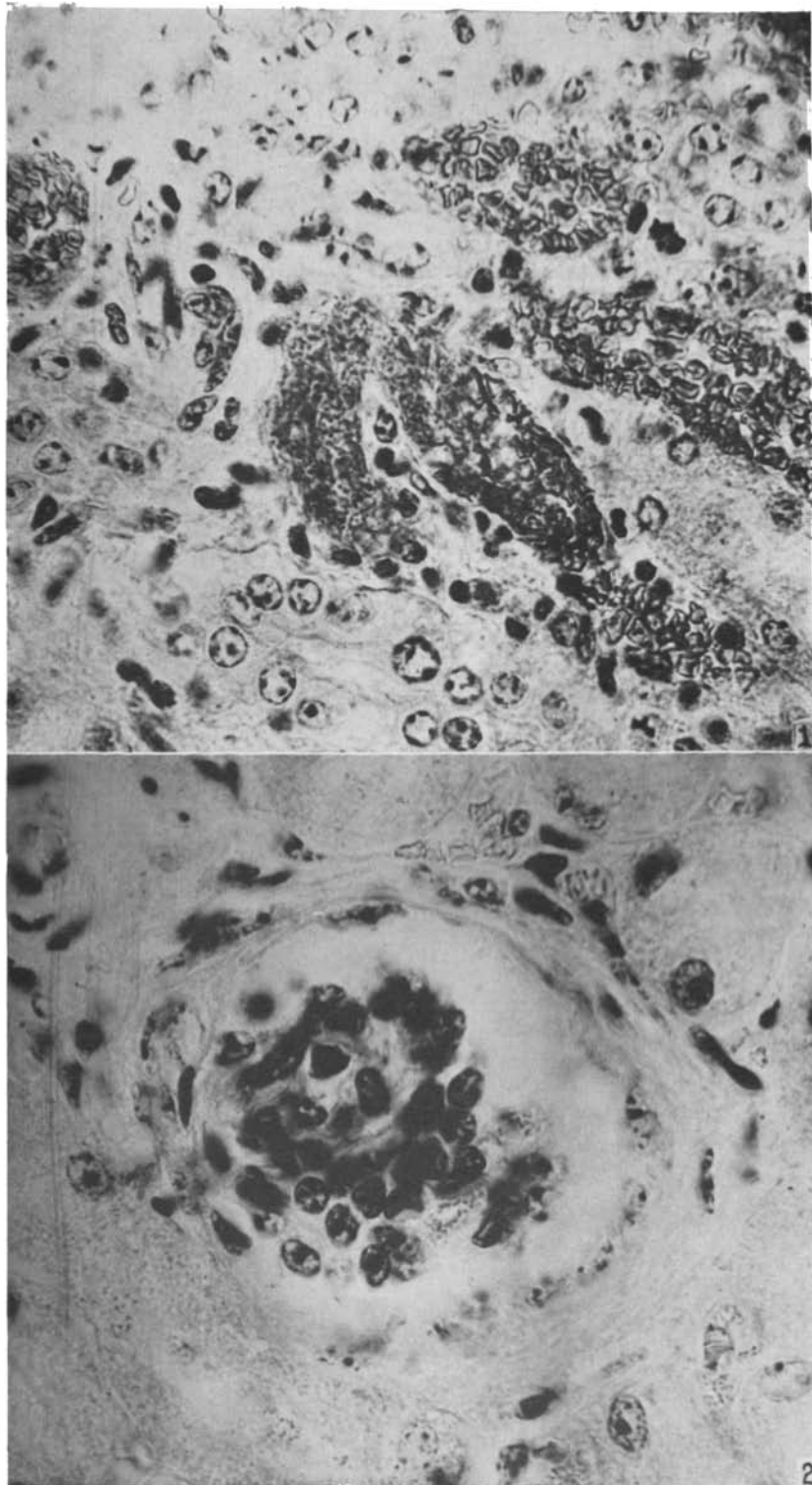
FIG. 3. Kidney of Calf 1125 (see page 418 of text). The capsule is shown in the upper right hand corner of the photograph. $\times 81$.

FIG. 4. Kidney of Calf 1052 (see page 416 of text). $\times 81$.

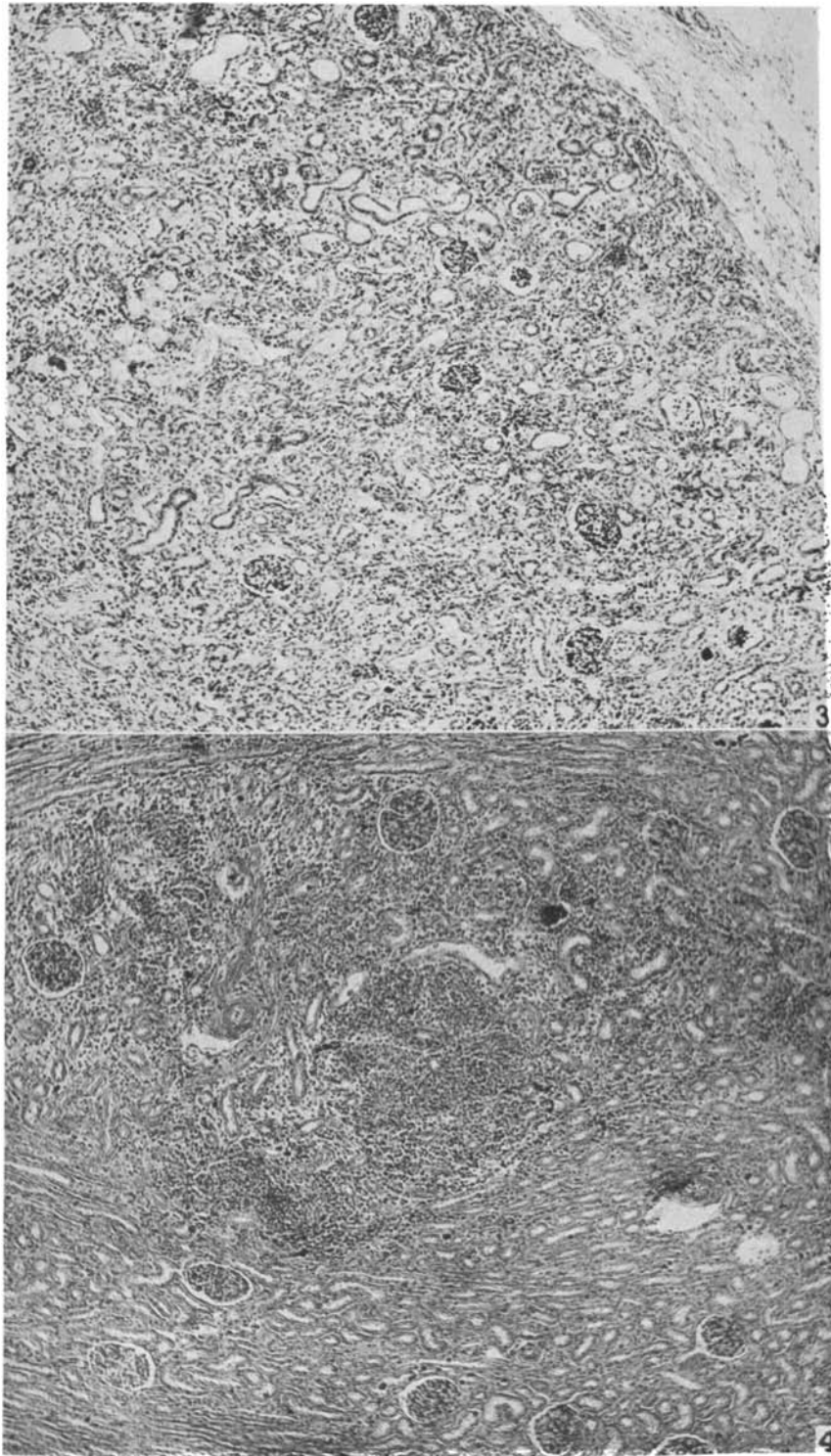
PLATE 17.

FIG. 5. Kidney of Calf 495 (see page 421 of text). Capsule in upper right hand corner. $\times 81$.

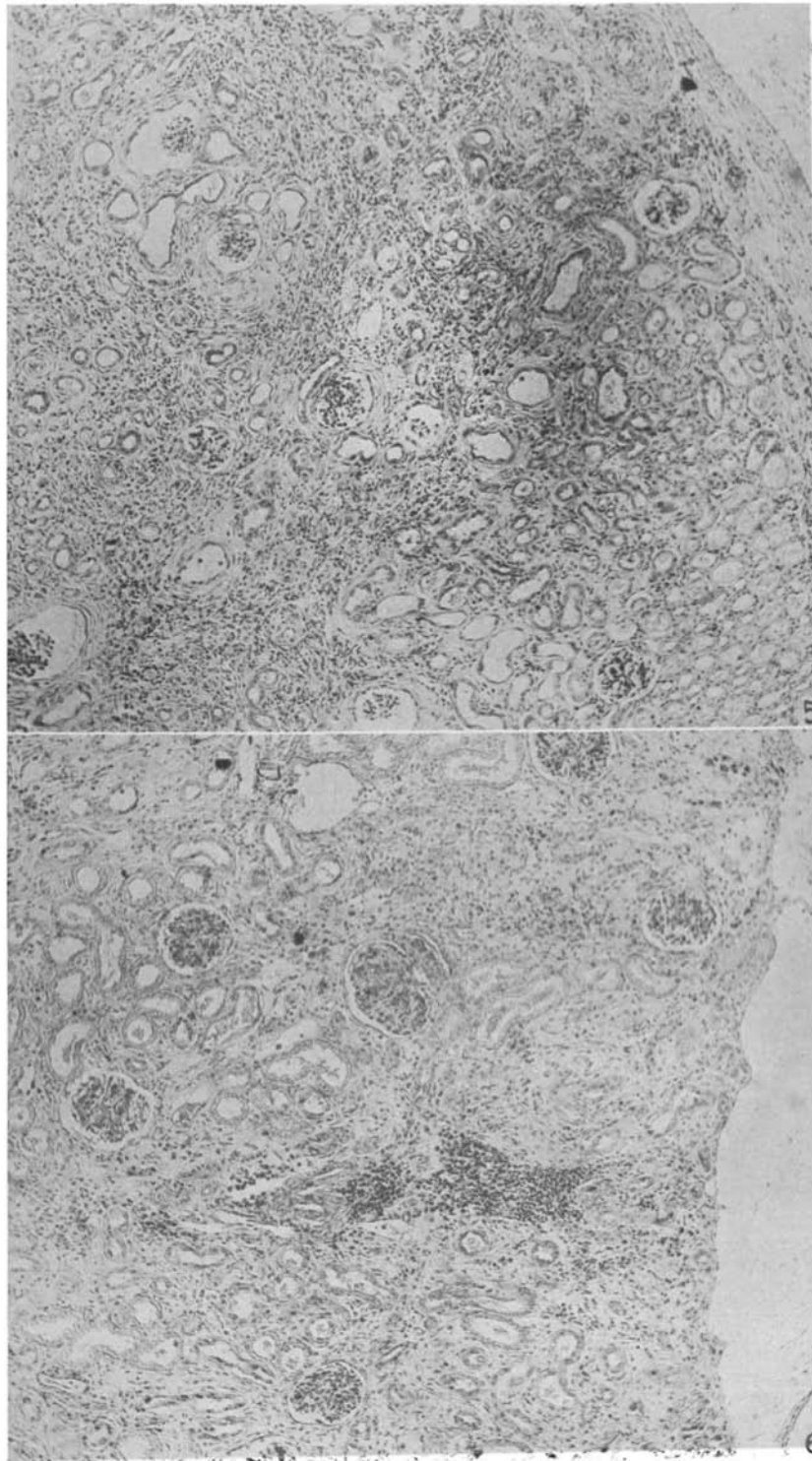
FIG. 6. Kidney of Calf 930 (see page 422 of text). The surface of the kidney appears along the right border of the picture. The capsule is lifted by fluid (edema) and seen only in the lower right hand corner. $\times 81$.



(Smith: Focal interstitial nephritis in the calf.)



(Smith: Focal interstitial nephritis in the calf.)



(Smith: Focal interstitial nephritis in the calf.)