

## ETIOLOGY OF OROYA FEVER.

### VI. PATHOLOGICAL CHANGES OBSERVED IN ANIMALS EXPERIMENTALLY INFECTED WITH *BARTONELLA BACILLIFORMIS*.

#### THE DISTRIBUTION OF THE PARASITES IN THE TISSUES.

By HIDEYO NOGUCHI, M.D.

(From the Laboratories of The Rockefeller Institute for Medical Research.)

PLATES 11 TO 14.

(Received for publication, October 20, 1926.)

Experimental infection with *Bartonella bacilliformis* in young *Macacus rhesus* monkeys varies in severity according to the susceptibility of the individual animals<sup>1,2,3</sup> and is of three general types: (1) severe, fatal affection characterized by extreme anemia, similar to Oroya fever in man, (2) relative benign condition, in which there is moderate anemia or none at all, accompanied by localized skin lesions resembling those of human verruga, (3) mild systemic disease, involving the lymphatic glands and blood.

The pathological changes found in human organs and tissues after death from *Bartonella bacilliformis* infection have been described by Odriozola,<sup>4</sup> Arce,<sup>5</sup> Herculles,<sup>6</sup> and by Strong and his coworkers.<sup>7</sup> The characteristic effects are seen in the liver, spleen, lymphatic glands, and bone marrow. Hypertrophy of the liver is almost invariable,<sup>4, 5</sup> and the spleen is frequently enlarged,<sup>4, 7</sup> though it may

---

<sup>1</sup> Noguchi, H., and Battistini, T. S., *J. Exp. Med.*, 1926, xliii, 851.

<sup>2</sup> Noguchi, H., *J. Exp. Med.*, 1926, xlv, 697.

<sup>3</sup> Noguchi, H., *J. Exp. Med.*, 1926, xlv, 715.

<sup>4</sup> Odriozola, E., *La maladie de Carrion*, Paris, 1896.

<sup>5</sup> Arce, J., *An. Facul. Med. Lima*, 1918, i, No. 1, p. 21; No. 2, p. 130; No. 3, p. 240; No. 4, p. 24.

<sup>6</sup> Herculles, O., *An. Facul. Med. Lima*, 1918, i, 10.

<sup>7</sup> Strong, R. P., Tyzzer, E. E., Sellards, A. W., Brues, C. T., and Gastiaburú, J. C., *Report of first expedition to South America, 1913*, Harvard School of Tropical Medicine, Cambridge, 1915.

be of normal size or less.<sup>5</sup> Infarcts are commonly found in the spleen and sometimes also in the liver.<sup>6, 7</sup> Strong and his coworkers note particularly the areas of degeneration in the liver, beginning about the hepatic veins, apparently due to the activity of the parasite and suggesting the presence of a toxin in the circulating blood. The lymphatic glands are enlarged everywhere<sup>4, 5, 7</sup> and frequently edematous. The hypertrophy is most marked in the mesenteric lymph nodes.<sup>4</sup> The marrow of the long bones is red or mottled with red patches,<sup>4, 7</sup> and distinctly softer than normal. Microscopically there is evidence of phagocytosis by endothelial leucocytes of red cells and polymorphonuclear leucocytes, also increased production of normoblasts.<sup>7</sup> Extensive phagocytosis by endothelial cells is found also to occur in the spleen, while the lymphatic glands often contain many large swollen endothelial cells in which the bacilliform parasites are present in large numbers.<sup>7</sup> Similar intracellular parasites may be found<sup>7</sup> in the blood vessels near ulcerated areas in the intestinal wall. The parasite has a marked predilection for the reticulo-endothelial system and sets up an active and persistent proliferation of endothelial cells in the tissues or organs which it invades.

The characteristic nodular lesions caused by *Bartonella bacilliformis* have occasionally been found to occur in the muscles and viscera as well as on the mucous membranes.<sup>4, 5, 8, 9</sup> Campodónico, in 1895,<sup>10</sup> reported the finding at autopsy, in a young child who succumbed to severe anemia during the course of verruga, of tiny red nodules in all the tissues of the body.

In the early experimental work with *Bartonella bacilliformis* only the milder types of infection were observed, and it was not until the third and fourth generations in monkeys that it was possible to induce, by massive inoculations of passage strains, a fatal disease accompanied by extreme anemia comparable with Oroya fever of man. Five animals succumbed to the infection, and, as in the case of the human disease, the conspicuous changes were found in the liver, spleen, bone marrow, and lymphatic glands. It was desirable, therefore, not only to compare the findings with those occurring in human material, but also to relate the histological changes in a particular tissue with the presence or absence of the parasite. In order better to accomplish this purpose a number of infected animals were sacrificed either at the height of disease, as evidenced by extensive local lesions and a high titer of the parasite in the blood, or during the period of convales-

<sup>8</sup> Odriozola, E., *Crón. méd.*, Lima, 1914, xxxi, 157.

<sup>9</sup> Herculles, O., *Crón. méd.*, Lima, 1914, xxxi, 67.

<sup>10</sup> Campodónico, E., *Crón. méd.*, Lima, 1895, xii, 43.

cence, when the blood findings were negative and the local lesions had subsided.

The important fact should be emphasized that tuberculosis was not encountered among the animals of the present series, notwithstanding special search was made for *B. tuberculosis* because of the possibility of confusion from this source.

Although microscopic examination of all materials—blood, organs, or tissues—was always made, the cultural method was found to be more reliable for determining the presence of *Bartonella bacilliformis*. Moreover, secondary infection is readily detected by this method. About 0.1 cc. of each of several dilutions (from 1:10 up to 1:1,000,000) of blood or saline suspension of tissue is introduced into leptospira medium, and the tubes are kept constantly at 25°C. for 4 to 5 weeks and examined periodically. Growth is often detected only after 2 to 3 weeks.

Films were always made of blood and impression smears of spleen, bone marrow, lymph glands, and liver. They were dried in air, fixed in methyl alcohol for 5 to 10 minutes, and stained with Giemsa's solution for 30 to 60 minutes.

Tissues were fixed in Regaud's fluid, and the sections stained with hematoxylin and eosin for histological study and with Giemsa's solution for detection of *Bartonella bacilliformis*.

The fourteen monkeys (*Macacus rhesus*) serving as material for the present study will be considered in three groups: (1) five animals which died of experimental infection with *Bartonella bacilliformis*; (2) five animals which showed signs of infection, locally and constitutionally, when sacrificed; (3) four animals which had shown signs of infection but were apparently in convalescence when sacrificed.

In the first group, three showed marked and two extreme anemia during the latter part of the disease or at the time of death. In Monkey 25 the red blood cells numbered 1,164,000 per c.mm. and the hemoglobin (Sahli) was 25 per cent; in Monkey 37 the red cells numbered 1,176,000 and the hemoglobin was 15 per cent. In these animals a terminal secondary bacterial infection intervened 12 and 96 hours before death.

There was moderate anemia in some of the animals of Group 2 but none in those of Group 3.

In Group 1 (fatal cases) the clinical picture was that of Oroya fever, and the pathological changes likewise proved to be similar to those

observed in the human infection. In Group 2 (non-fatal cases), the manifestations were characteristic of human verruga.

*Pathological Findings in Fatal Infections with Bartonella bacilliformis.*

The following outline is a composite picture of the characteristic changes noted. The findings in individual instances and the relation of the cultural to the pathological findings are recorded in Table I and in the protocols.

The duration of illness was 56 days in Monkey 17, 36 days in Monkey 25, 25 days in Monkey 30, 29 days in Monkey 35, and 41 days in Monkey 37.

*External Appearances.*

The skin and mucous membranes have a striking waxy yellowish appearance, and the numerous swollen lymphatic glands in the axillary and inguinal regions stand out prominently beneath the stretched skin. Pale nodules are found at the original sites of inoculation on eyebrows and abdominal skin. In an exceptional instance (Monkey 25) there were also numerous spontaneously occurring nodules on various parts of the body.

*Thorax.*

*Lungs.*—Pale yellow, normally crepitant, smooth. Congestion or edema at base in some instances. Bronchial lymph nodes greatly enlarged. Pleuræ anemic; small amount of effusion present.

*Heart.*—Myocardium flabby, pale, contains partially fluid pale red blood and occasionally a small clot. No petechiæ present. The pericardium contains some clear fluid. In one instance (Monkey 25) an acute pericarditis due to secondary invasion was present.

*Abdomen.*

*Liver.*—Pale, flabby in consistency, frequently somewhat enlarged, often shows yellowish mottling. Areas of necrosis and fatty degeneration are often recognizable.

*Spleen.*—Dark bluish red, enlarged, rather firm in consistency. Follicles indistinct. Scattered minute grayish red areas (infarctions) are present in all instances in varying numbers.

*Kidneys.*—Pale, with yellowish gray tint.

*Adrenals.*—Pale yellow.

*Pancreas.*—Normal in appearance.

*Stomach.*—Usually empty, mucosa pale.

*Small Intestine.*—Pale, serosa studded with numerous dark bluish swollen lymph nodes. Mucosa pale. Peyer's patches slightly hypertrophied.

*Large Intestine.*—Similar in appearance to small intestine, swollen lymph nodes on serosa giving it a striking aspect. No ulceration of the mucosa.

*Bladder.*—Normal in appearance.

*Ovaries, Uterus, Testicles.*—Pale, but normal.

*Bone Marrow (Femur).*—Dark grayish red.

*Lymphatic Glands.*—Entire lymphatic system hypertrophied and congested to an extraordinary degree. In the inguinal and axillary regions two or three swollen glands sometimes unite to form an irregular mass, 2 to 3 cm. in longest diameter, pink to deep red in color, and edematous. In the abdominal cavity the swollen lymph nodes are sometimes dark bluish, sometimes bluish red, and by contrast with the pale intestinal wall present a spectacular picture. They range in size from 2 to 6 mm. and are attached so firmly to the intestinal wall that they appear like verrucous nodules.

*Nervous System.*—The brain and spinal cord and their coverings are anemic but otherwise appear normal.

#### *Microscopic Pathology.*

*Liver.*—The normal pattern of cell arrangement is more or less disturbed. The hepatic cells have lost their sharp outline, stain poorly, and are vacuolated. The cells around the hepatic veins are necrotic (Fig. 1). Here and there, on the borders of the necrotic areas, between the liver cells, are engorged macrophages, which often contain erythrocytes, polymorphonuclear leucocytes, and erythroblasts. Around the portal veins are several layers of proliferated endothelial cells. In some specimens yellowish or brownish pigment in granules or small masses is found within the endothelial phagocytes or in endothelial cells lining the sinusoids. The degree of necrotic change around the hepatic veins is variable in the different animals. In some areas the liver cells are clear and homogeneous, in others coarsely granular. A few endothelial cells containing *Bartonella* were found after prolonged search in two of the five livers (those of Monkeys 17 and 30).

*Spleen.*—(Figs. 7, 8, 23.) Many infarctions are found, the periphery showing invasion of leucocytes. Many of the veins are occluded, owing probably to endothelial hyperplasia. The splenic nodules are reduced in size and are often scattered through the proliferating endothelial cells. Engorged macrophages containing erythrocytes are quite abundant. Yellowish brown pigment is present, some in the endothelial leucocytes, some between the splenic cells.

A number of endothelial cells containing masses of elements resembling *Bartonella bacilliformis* were found (Figs. 16, 25), but none of the swollen endothelial cells containing rods and granules such as were seen in human materials by Strong and his coworkers.

*Lymphatic Glands.*—The principal changes in these glands are the increase in the number of endothelial cells and the presence of numerous engorged macrophages. In the mesenteric nodes a large amount of greenish pigment is found in the phagocytic endothelial cells of the sinuses. *Bartonella bacilliformis* has been observed in a few endothelial cells in Monkeys 29 and 30 (Fig. 27).

*Bone Marrow (Femur).*—Numerous macrophages containing erythrocytes, polymorphonuclear leucocytes, and cell débris are present, and there are large numbers of normoblasts in some specimens (Monkeys 17, 25, 30). Some cells, probably endothelial, containing elements resembling *Bartonella bacilliformis* have been found in film preparations (Figs. 15, 26).

The changes are strikingly like those described as occurring in tissues from fatal cases of Oroya fever, the differences being in degree rather than in kind. For example, the changes in the liver and spleen in monkeys are decidedly less pronounced than those seen in such human materials as are at my disposal for comparison, while the reaction in the lymphatic glands is in reverse degree, the more active phagocytosis being observed in monkeys. The origin of the minute necrotic areas in the spleen may be sought in the obstruction of capillary lumina by proliferating endothelial cells.

As in the skin lesions, so also in the spleen and lymph glands, the progressive and persistent proliferation of endothelial cells is usually associated with the presence of *Bartonella bacilliformis* in considerable numbers, as detected by cultures. The extensive zonal necrosis around the veins of the liver, which is less extensively invaded by the parasite, would appear, as suggested by Strong and his coworkers, to be due to the presence of a toxin in the circulating blood.

*Pathological Findings in Animals Sacrificed during the Period of Active Infection.*

The five animals of Group 2 all showed signs of active infection at the time when they were killed by etherization. The period from inoculation to the time of killing was 22 days in Monkey 4, 68 days in Monkey 5, 53 days in Monkey 23, 24 days in Monkey 24, and 28 days in Monkey 29. None of the animals showed severe anemia, although in Monkey 24 there was moderate diminution both in red blood cells and hemoglobin (erythrocytes 3,432,000, hemoglobin 55 per cent). *Bartonella bacilliformis* had been cultivated from the blood of Monkey 23 in a dilution of 1:100,000 16 days after inoculation, but it could not be recovered from undiluted blood 15 days later nor at any subsequent time.

The spleen and lymphatic glands were usually affected, and also the bone marrow as far as studied; the liver was less frequently in-

volved. Except in Monkey 23, of which special mention will be made later, the other organs were always normal in appearance.

The spleen was always more or less enlarged and rather firm; in one instance the surface was rather irregular (Monkey 5). In one animal (Monkey 23) there were numerous grayish brown areas of infarction, 1 to 1.5 mm. in diameter, scattered over the organ, which was a dark bluish red (Fig. 23). The lymphatic glands were in all cases swollen and congested and approached in size those of the fatally infected animals. The bone marrow was active in three animals studied (Monkeys 5, 23, and 24). The liver was affected to a similar degree in two animals (Monkeys 23 and 24); in the other three it was apparently normal. *Bartonella bacilliformis* was seen in a few of the endothelial cells in the liver of Monkey 24. The microscopical findings in the animals of Group 2 were identical with those in the fatally infected animals except that the changes were less pronounced in some respects.

An unusually interesting observation was made in the case of Monkey 23. On the pinkish surface of the lobules of the lungs were noticed a dozen pale, grayish, semitransparent, round nodules, measuring 1 to 2 mm. in diameter, firm, and sharply demarcated from the adjacent normal lung tissue (Fig. 22). Microscopically (Fig. 11), they consisted of numerous large mononuclear cells, many of them vacuolated and filled with dark granular pigment. The capillaries in this area, which were few in number, showed endothelial thickening. Several engorged macrophages and cell debris were also present. In a few of the endothelial cells *Bartonella bacilliformis* was found (Figs. 14, 24).

#### *Pathological Changes in Animals Sacrificed during Convalescence.*

Four animals were sacrificed when apparently in the course of convalescence from a mild infection. None showed fever or local lesions, though the lymphatic glands were still swollen in all instances. The erythrocyte count ranged from 5,472,000 to 6,584,000, and the hemoglobin was 80 to 90 per cent. The animals appeared to be in excellent condition when sacrificed 58 days (Monkey 7), 49 days (Monkey 8), 40 days (Monkey 10), and 30 days (Monkey 13) after inoculation.

The changes in these animals, when still evident, were characteristic. The spleen was somewhat enlarged in three instances and in two showed definite endothelial hyperplasia; in one (Monkey 13) there was a marked increase in fibrous tissue; in another (Monkey 7) the same changes were noted as had been found in the spleens of the actively infected animals. The liver was macroscopically normal in all four animals. The lymph nodes were active in two (Monkeys 7 and 8) but quiescent in the others. The bone marrow was normal in Monkeys 8, 10, and 13, and active in Monkey 7.

The findings suggested that Monkeys 7 and 8 were still infected and that Monkeys 10 and 13 had become free from infection. Cultural studies confirmed this inference, as will appear later.

#### DISTRIBUTION OF *BARTONELLA BACILLIFORMIS* IN THE TISSUES IN THE EXPERIMENTAL INFECTION.

In Oroya fever *Bartonella bacilliformis* persists in the blood until the patient's death. Whether or not various organs and tissues also contain the living parasite has not been determined. The pronounced changes found in certain organs have been assumed to be due either to invasion by the parasite or to the action of a toxin circulating in the blood. Cultural determination of the distribution of the organism in the tissues of experimental animals was, therefore, of special usefulness in establishing a relation between the pathological processes and the presence of the parasite. The results of cultural studies and of examination for pathological changes are recorded in parallel columns in Table I.

As the analysis shows, *Bartonella bacilliformis* was recovered from blood, liver, spleen, lymphatic glands, bone marrow, and local lesions in all instances of fatal infection, except when cultures were lost through contamination. The parasite was not so generally distributed in animals sacrificed during the course of an apparently non-fatal infection, though the local lesions and the changes in the spleen were rather severe. In Monkey 23 the parasite had disappeared from the blood, owing probably to the development of a blood immunity, but persisted in the lymphatic glands and spleen, while in Monkey 29 the blood and nodular tissue contained it but the organs were all free



TABLE I.

<i>M. zhisus</i> No.	Blood		Liver		Spleen		Lymph gland		Bone marrow		Nodule	
	Anemia	Culture	Degree of histological change	Culture	Degree of histological change	Culture	Degree of histological change	Culture	Degree of histological change	Culture	Degree of histological change	Culture
Group 1 (fatally infected)	17	+++	+++	+	+++	+++	+	+++	+++	+	+++	+
	25	+++	+++	+++	+	+++	Cont.	+++	+++	+	+++	+
	30	+++	+++	+++	+	+++	+	+++	+	+	+	+
	35	+	+++	+	+	+	+	+	+	+	+	+
	37	+++	Cont.	+++	Cont.	+++	Cont.	Cont.	+++	Cont.	+	+
Group 2 (sacrificed during active stage of infection)	4	...	-	...	+	...	...	+	...	...	+	+
	5	+	-	+	+	+	+	+	+	+	+	+
	23	-	+++	+++	+	+++	+	+++	+	+	+	+
	24	+++	+	+	+	+	+	+	+	+	+	+
	29	+	+	-	-?	+	+	<+	+	+	+	+
Group 3 (sacrificed during convalescence)	7	-	-	<+	<+	+	<+	+	+	+	+	Had disappeared
	8	-	-	-	-	-	-	-	-	-	-	"
	10	-	-	-	-	-	-	-	-	-	-	"
	13	-	-	-	-	-	-	-	-	-	-	"

Anemia +++ = r.b.c. 1,000,000 to 1,500,000, Hb. 15 to 25 per cent; ++ = r.b.c. less than 3,000,000; + = less than 4,000,000; - = less than 5,000,000; - = over 5,500,000.

Degree of change in tissue varies from marked (+++++) to slight (+).

Cont. = secondary bacterial contamination.

## Summary of Pathological

<i>M. rhesus</i> No.		Liver
17	Inoculation Mar. 15, 1926. Died after 57 days. Fever still present. Nodules active. Anemia marked (r.b.c. 3,112,000, Hb. 50 per cent). Blood culture + at autopsy. Nodule culture + at autopsy	Pale, somewhat enlarged. Structure disturbed, cells along central zones poorly stained. Perivascular proliferation moderate. Greenish pigment present. <i>B. bacilliformis</i> found in a few endothelial cells. Culture contaminated
25	Inoculation Mar. 23, 1926. Died after 36 days. Course practically afebrile. Local lesions extensive, partly generalized. Anemia very severe (r.b.c. 1,624,000, Hb. 25 per cent). Blood (1:100,000) culture + 12 hrs. before death. Culture of nodules taken at autopsy +	Pale, soft, mottled, perhaps enlarged. Structure fairly well preserved but pronounced central necrosis throughout. Numerous phagocytes, polymorphonuclears, and pigments present. Hepatic cells vacuolated. Culture contaminated
30	Inoculation Mar. 31, 1926. Died after 25 days. Fever present. Nodules small but active. Blood (1:10,000 dilution) culture + 3 days before death. Anemia moderate (r.b.c. 3,920,000, Hb. 60 per cent). Blood and nodules taken at autopsy yielded cultures	Pale, appears fatty. Normal structure lost, cells stain poorly, vacuolated and dissociated. Endothelial hyperplasia; some cells contain <i>B. bacilliformis</i> . Many phagocytes in sinusoids. Culture +
35	Inoculation Apr. 12, 1926. Died after 29 days. Fever still present. Nodules small but active. Anemia slight (r.b.c. 4,776,000, Hb. 80 per cent). Blood (1:100) culture + 10 days before death. Blood and nodules taken at autopsy yielded cultures	Probably paler than normal. General structure disturbed. Marked dissociation and vacuolation of cells. Invasion of sinusoids by phagocytes. Proliferation of endothelial cells. Culture +

*and Cultural Findings.*

Spleen	Lymphatic glands	Bone marrow	Remarks
Enlarged, rather firm. Follicles reduced. Endothelial hyperplasia. Active phagocytosis. Fibrin masses and pigments present. <i>B. bacilliformis</i> found. Culture positive	All lymph nodes much swollen and congested. Endothelial hyperplasia and active phagocytosis throughout. Culture +	Dark grayish red. Very active phagocytosis. Numerous normoblasts and polymorphonuclear leucocytes present. Culture +	<i>B. bacilliformis</i> found in all tissues studied
Slightly enlarged, soft. Follicles smaller, outlines of many lost. Numerous perifollicular necrotic foci. Marked endothelial hyperplasia. Active phagocytosis of degenerated polymorphonuclears and erythrocytes. Many normoblasts present. Culture contaminated	Marked swelling throughout. Mesenteric nodes appear like scattered or clustered peas but bluish in color. Pronounced proliferation of endothelial cells and active phagocytosis. Culture contaminated	Dark grayish red. Active phagocytosis. Polymorphonuclears and normoblasts present. Culture contaminated	Terminal bacterial infection (pericarditis) intervened after heart puncture 24 hrs. before death
Enlarged. Follicles thinned and diffuse in places. Endothelial elements increased around vessels; small foci with fibrinous exudate and cell debris. Culture +	General swelling. Endothelial hyperplasia, active phagocytosis, greenish pigments. <i>B. bacilliformis</i> found in a few endothelial cells. Culture +	Grayish red. Active phagocytosis. Polymorphonuclears and normoblasts present. Culture +	<i>B. bacilliformis</i> found in all tissues studied
Dark and soft. Follicles ill defined, pervaded by increased endothelial cells. Active phagocytosis. Culture +	Swelling and congestion throughout. Endothelial hyperplasia. Phagocytosis. Culture +	Grayish red. Active phagocytosis. Culture +	<i>B. bacilliformis</i> found in all tissues studied

*Summary of Pathological*

<i>M. rhesus</i> No.		Liver
37	Inoculation Apr. 17, 1926. Died after 41 days. Fever still present. Small nodule on leg. Blood (1:1,000) + 96 hrs. before death; r.b.c. 1,664,000, Hb. 25 per cent. Autopsy blood contaminated; anemia extreme (r.b.c. 1,176,000, Hb. 15 per cent). Nodules (autopsy) +	Pale and soft. General structure much disturbed. Cells stain very poorly, necrotic along central zones. Small masses of polymorphonuclear leucocytes scattered in sinusoids, where many loaded phagocytes are present. Endothelial proliferation marked. Culture contaminated
4	Inoculation Dec. 8, 1925. Killed after 22 days. Fever present. Nodules active. Blood culture at autopsy +. Nodules at autopsy +	Apparently normal. No culture made
5	Inoculation Dec. 11, 1925. Killed after 68 days. Had become afebrile. Nodules large and active. R.b.c. 4,856,000, Hb. 85 per cent. Blood culture and nodules (autopsy) +	Apparently normal. No culture made
23	Inoculation Mar. 9, 1926. Killed after 53 days. Fever present. Nodules active, extensive. Blood + in 1:100,000, 40 days previously, - 22 days previously and at autopsy. Nodules (autopsy) +	General structure irregular; some ill stained foci. Numerous polymorphonuclears. Moderate endothelial hyperplasia. Culture contaminated
24	Inoculation Mar. 19, 1926. Killed after 24 days. Fever present. Nodules active. Anemia moderate (r.b.c. 3,432,000, Hb. 55 per cent). Blood (1:10) and nodules at autopsy +	Pale, mottled. Moderate degree of central necrosis, uniform structure lost in places. Endothelial proliferation around vessels. <i>B. bacilliformis</i> found in a few endothelial cells. Culture +

*and Cultural Findings.*

Spleen	Lymphatic glands	Bone marrow	Remarks
Dark and firm. Only a few follicles preserved. Necrotic areas (infarctions) showing active phagocytosis found. Increase in endothelial cells. Culture contaminated	Swollen and congested. Endothelial hyperplasia. Active phagocytosis. Polymorphonuclear leucocytes present. Culture contaminated	Grayish red. Active phagocytosis and increase in polymorphonuclear leucocytes. Culture contaminated	Terminal secondary infection by strain of <i>B. paratyphosus</i> A 48 hrs. before death
Somewhat swollen and firm. Considerable increase in endothelial elements. No culture made	Enlarged and congested everywhere. Definite endothelial hyperplasia; active phagocytosis; pigments. No culture made	Not examined	Pure infection with <i>B. bacilliformis</i>
Enlarged, granular surface. Follicles ill defined in many places. A few necrotic areas. Active phagocytosis. Culture +	Moderately swollen and congested. Phagocytosis active. Hyperplasia of endothelial cells. Culture +	Grayish red. Active phagocytosis. Normoblasts present. Culture +	<i>B. bacilliformis</i> found in all tissues studied except liver. Animal moderately resistant
Somewhat enlarged, shows numerous brown patches of infarction. Many perifollicular necrotic areas. Active phagocytosis. Pigments present. Endothelial hyperplasia. Culture +	Greatly swollen and congested. Hyperplasia of endothelial elements. Very active phagocytosis. Culture +	Grayish red. Phagocytosis active. Many polymorphonuclear leucocytes. Culture +	Note absence of <i>B. bacilliformis</i> in blood and persistence in other tissues
Enlarged, bluish red. Many follicles diffuse, interspaced by proliferated endothelial cells. Active phagocytosis. Many normoblasts. Culture +	Swollen and congested. Endothelial hyperplasia and phagocytosis. Culture +	Grayish red. Active phagocytosis. Numerous polymorphonuclears and normoblasts present. Culture +	<i>B. bacilliformis</i> found in all tissues studied. Animal quite susceptible

*Summary of Pathological*

<i>M. rhesus</i> No.		Liver
29	Inoculation Mar. 30, 1926. Killed after 28 days. Fever had been present for 2 wks. Nodules very active. Blood (1:1,000) + day before autopsy. Anemia noticeable. R.b.c. 4,704,000, Hb. 70 per cent. Blood and nodules at autopsy +	Mottled. Microscopically appears normal. Culture -
7	Inoculation Dec. 21, 1925. Killed after 58 days. Fever had subsided 10 days previously. Nodule removed 30 days previously +. Blood + 8 days previously. Blood taken at autopsy +. R.b.c. 5,472,000, Hb. 80 per cent	Appears normal. Culture contaminated
8	Inoculation Dec. 30, 1925. Killed after 49 days. Fever had subsided 7 days previously. Nodules absent. Blood + 14 days previously, - at autopsy. R.b.c. 5,496,000, Hb. 80 per cent	Appears normal. Culture -
10	Inoculation Jan. 8, 1926. Killed after 40 days. Fever had subsided 14 days previously, nodules 3 wks. previously. Blood (1:100) + 30 days previously, - at autopsy. R.b.c. 6,584,000, Hb. 65 per cent	Appears normal. Culture -
13	Inoculation Jan. 19, 1926. Killed after 30 days. Fever had subsided 10 days previously. No nodules. Blood + 19 days previously, - 8 days previously, - at autopsy. R.b.c. 6,104,000, Hb. 90 per cent	Appears normal. Perivascular infiltrations present. Culture -

from it. In the latter instance the organism had apparently not yet invaded the organs.

Of the four animals in which fever and local lesions had been present but had subsided, two (Monkeys 7 and 8) proved to be still carrying *Bartonella bacilliformis* in one tissue or another. Monkey 8 is especially interesting, as the latent infection was demonstrable only in the lymphatic glands. The other two animals (Monkeys 10 and 13) had

*and Cultural Findings.*

Spleen	Lymphatic glands	Bone marrow	Remarks
Enlarged, bluish red. Follicles appear to be of normal size and structure. Moderate endothelial hyperplasia. Numerous normoblasts. Culture -	Swollen and congested. Hyperplasia of endothelial elements, some phagocytosis. Culture +	Not examined	Liver and spleen had probably not yet been invaded. Animal rather resistant
Enlarged, follicles prominent. Only slight hyperplasia of endothelial cells microscopically. Follicles apparently normal. Culture +	Moderate swelling. Slight endothelial proliferation. Culture +	Grayish red. No sections. Culture +	<i>B. bacilliformis</i> found in most tissues studied: evidence of chronicity of infection
Appears normal. Culture -	Marked swelling and congestion. Hyperplasia of endothelial cells. Phagocytosis active. Culture +	Grayish yellow. Apparently normal. Culture -	<i>B. bacilliformis</i> found only in lymph nodes. Animal apparently convalescing
Probably enlarged. Microscopically normal. Culture -	Definitely enlarged, but pale. General hyperplasia. Culture -	Grayish yellow. Normal. Culture -	Had recovered from infection mildness of which was probably due to resistance of animal
Slightly enlarged (?); surface uneven, firm. Definite increase in fibrous tissues. Hyperplasia of endothelial cells. Culture -	Considerable swelling and congestion. Hyperplasia. Culture -	Grayish yellow. Apparently normal. Culture -	Recovered from mild infection. High resistance of animal noted

completely recovered, as indicated by the histological findings and proven by the negative results of cultural experiments.

Brief protocols of all the animals of the present series are recorded above.

## SUMMARY.

The pathological changes observed in the organs in *Macacus rhesus* monkeys which have succumbed to severe infection with *Bartonella*

*bacilliformis* are similar to those found in human organs in persons dying of Oroya fever.

The characteristic changes in the liver are the zonal necrosis of the cells around the hepatic veins, involving active macrophagocytosis of invading polymorphonuclear leucocytes in the necrotic areas, and a marked endothelial hyperplasia in the sinusoids or around the portal veins. In some instances there is fatty infiltration of hepatic cells.

In the spleen persistent hyperplasia of the endothelial cells of the capillaries leads to the formation of minute foci of infarction, owing to occlusion of the lumina. The follicles are dispersed or reduced, and there is an active macrophagocytosis of cellular debris, polymorphonuclear leucocytes, and erythrocytes. In some specimens an increase in normoblasts is noted. Pigment is sometimes present.

The lymphatic system shows general progressive endothelial hyperplasia, with active invasion of macrophages which contain polymorphonuclear leucocytes, erythrocytes, and greenish or dark pigments.

In the bone marrow there is increased activity of macrophagocytes. Numerous normoblasts are found in some instances.

*In one monkey, sacrificed during the course of infection, small, verruga-like nodules were found in the lungs and spleen.*

*Bartonella bacilliformis* has been detected microscopically, though in small numbers, in all tissues showing histological changes. Parallel cultural determinations of the presence of *Bartonella bacilliformis* in the blood, liver, spleen, lymphatic glands, bone marrow, and local lesions established the relationship between the pathological conditions and the presence of the parasite. The organism seems to persist longest in the lymphatic glands. Cultural methods offer a simple and conclusive means for the determination of the presence or absence of the infecting organism.

#### EXPLANATION OF PLATES.

##### PLATE 11.

FIG. 1. Experimental Oroya fever. Section of liver from *M. rhesus* 25, showing a rather characteristic zonal necrosis of the cells around the hepatic veins. Giemsa's stain.  $\times 50$ .

FIG. 2. The same section,  $\times 182$ .

FIG. 3. Human Oroya fever. Section of liver from the case (S. A. 15) from



which the strain of *Bartonella bacilliformis* employed in these investigations was isolated. The necrotic changes of the liver cells are more diffuse than in the experimental infection, but there is a definite tendency to a central type. Giemsa's stain.  $\times 50$ .

FIG. 4. The same section,  $\times 182$ .

FIG. 5. Human Oroya fever. Section of liver from the collection of the Harvard School of Tropical Medicine. Courtesy of Professor R. P. Strong. This patient was free from any verruga lesions and was regarded by the Harvard Commission as a pure case of Oroya fever. The section shows the characteristic central necrosis. Note the striking resemblance between this preparation and that of the monkey liver in Fig. 1.  $\times 50$ .

FIG. 6. The same section,  $\times 182$ .

#### PLATE 12.

FIG. 7. Experimental Oroya fever. Section of spleen from *M. rhesus* 23. A splenic follicle in an infarction zone, showing a perifollicular necrosis and the invasion of the follicle by proliferating endothelial cells, endothelial phagocytes, and polymorphonuclear leucocytes. Giemsa's stain.  $\times 182$ .

FIG. 8. Experimental Oroya fever. Section of spleen from *M. rhesus* 25. An area of infarction where the splenic nodule has practically disappeared. Giemsa's stain.  $\times 182$ .

FIG. 9. Human Oroya fever. Section of spleen, for comparison. A splenic follicle within the infarction, showing a general disorganization, necrosis, and phagocytic invasion. Giemsa's stain.  $\times 182$ .

FIG. 10. Human Oroya fever. Section of spleen from another case. The structure of spleen is greatly disturbed, shows general endothelial hyperplasia, and the presence of macrophagocytes and polymorphonuclear leucocytes. Note the striking resemblance between these lesions and those shown in Figs. 7 and 8. Giemsa's stain.  $\times 182$ .

FIG. 11. Section of one of the nodules in the lung of *M. rhesus* 23. Giemsa's stain.  $\times 50$ .

FIG. 12. The same section,  $\times 182$ , showing the proliferation of endothelial cells within the nodule.

#### PLATE 13.

FIG. 13. *Bartonella bacilliformis*, colonies from a blood agar slant grown for 6 days  $25^{\circ}\text{C}$ . Smear preparation stained with Giemsa's solution for 1 hour, showing the pleomorphism of the organism. Inserted here for comparison with the intracellular forms.  $\times 1,000$ .

FIG. 14. Film preparation from a nodule in the lung of *M. rhesus* 23, showing irregular masses of *Bartonella bacilliformis* within the cytoplasm of an endothelial cell. Giemsa's stain.  $\times 1,000$ .

FIG. 15. Film preparation from the bone marrow (femur) of *M. rhesus* 23,

showing *Bartonella bacilliformis* within one of the endothelial cells. Giemsa's stain.  $\times 1,000$ .

FIG. 16. Film preparation from the spleen of *M. rhesus* 23, showing a cell (endothelial?) containing several small masses (*Bartonella bacilliformis*?). Giemsa's stain.  $\times 1,000$ .

FIG. 17. Section of an experimental skin nodule produced in *M. rhesus* with a strain of *Bartonella bacilliformis* from verruga,<sup>11</sup> showing a dense mass of the parasites within an endothelial cell. Giemsa's stain.  $\times 1,000$ .

FIG. 18. Section of an experimental subcutaneous lesion produced in the chimpanzee<sup>3</sup> with the strain of *Bartonella bacilliformis* from Oroya fever, showing irregularly scattered masses of *Bartonella bacilliformis*. Giemsa's stain.  $\times 1,000$ .

FIG. 19. Section of a skin lesion experimentally produced in an orang-utan,<sup>3</sup> showing a small mass of *Bartonella bacilliformis* (below) and a dense mass of granules, probably of a mast cell (above). Giemsa's stain.  $\times 1,000$ .

FIG. 20. Human Oroya fever. Section of lymphatic gland, showing two swollen endothelial cells, loaded with minute granules, projecting into the lumen of a capillary vessel. Giemsa's stain.  $\times 1,000$ . From Case S. A. 15.

FIG. 21. Human Oroya fever. Section of lymphatic gland, showing the swollen endothelial cells lining a capillary vessel in an oblique section. These cells contain the very minute granules first described by the Harvard Commission as an intracellular phase in the life cycle of *Bartonella bacilliformis*. (Courtesy of Professor Strong.) Giemsa's stain.  $\times 1,000$ .

#### PLATE 14.

FIG. 22. The lungs of *M. rhesus* 23, showing the pale grayish nodules on both lungs. They measured 2 to 3 mm. in diameter. In the middle, near the trachea, is a grayish lymph node of the size of a pea. Natural size.

FIG. 23. The spleen of the same monkey, showing numerous infarctions. Natural size.

FIG. 24. *Bartonella bacilliformis* in an endothelial cell in a film preparation from one of the nodules in the lung of *M. rhesus* 23. Giemsa's stain.  $\times 1,750$ .

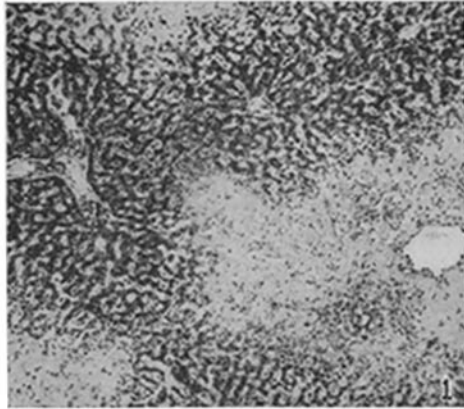
FIG. 25. *Bartonella bacilliformis* in an endothelial cell. Film preparation from the spleen of *M. rhesus* 23. Giemsa's stain.  $\times 1,750$ .

FIG. 26. *Bartonella bacilliformis* (?) in an endothelial cell of the bone marrow (femur) of *M. rhesus* 24. Film preparation. Giemsa's stain.  $\times 1,750$ .

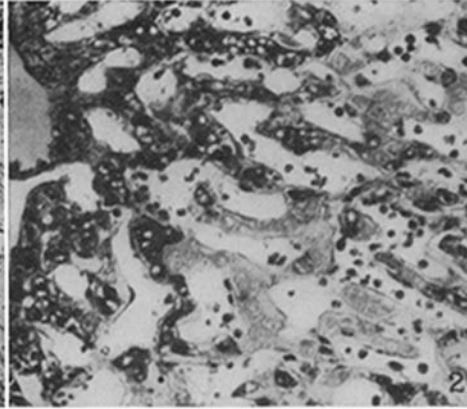
FIG. 27. *Bartonella bacilliformis* in an endothelial cell of the lymph gland of *M. rhesus* 29. Section. Giemsa's stain.  $\times 1,750$ .

---

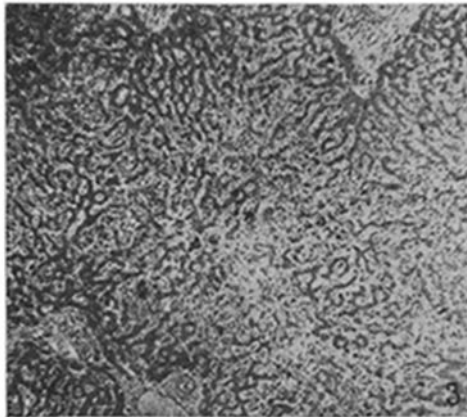
<sup>11</sup> Noguchi, H., *J. Exp. Med.*, 1927, xlv, 175.



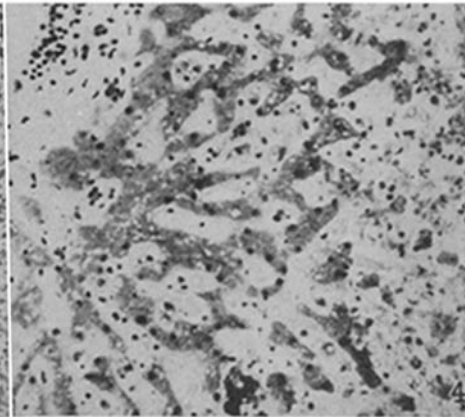
Liver, *M. rhesus* 25.  $\times 50$ .



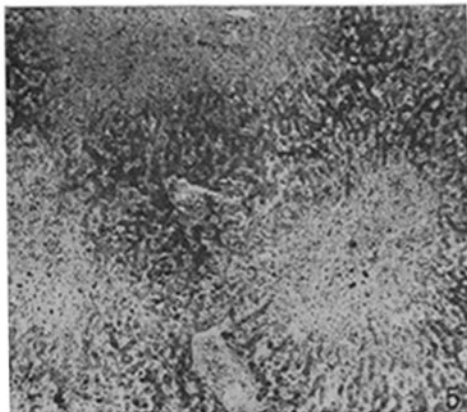
Liver, *M. rhesus* 25.  $\times 182$ .



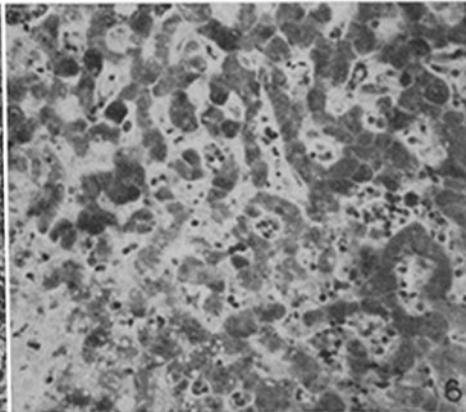
Liver, human Oroya fever.  $\times 50$ .



Liver, human Oroya fever.  $\times 182$ .

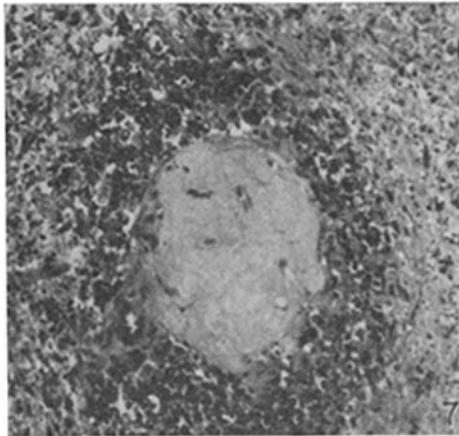


Liver, human Oroya fever.  $\times 50$ .

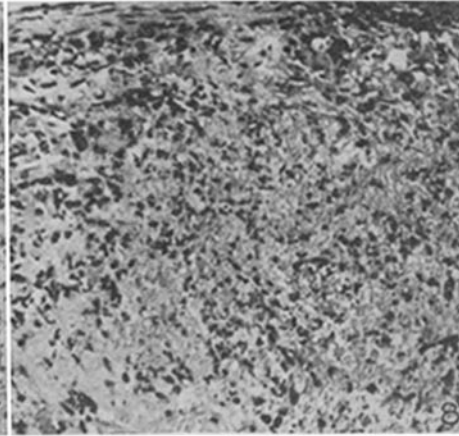


Liver, human Oroya fever.  $\times 182$ .

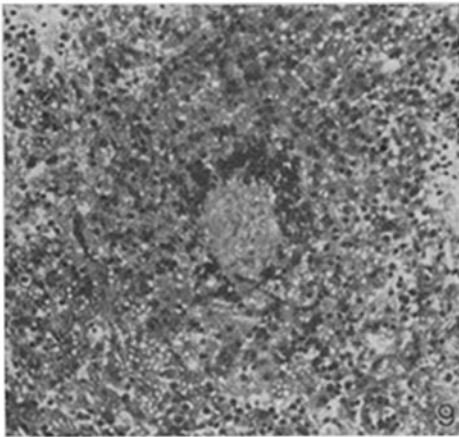
(Noguchi: Etiology of Oroya fever. VI.)



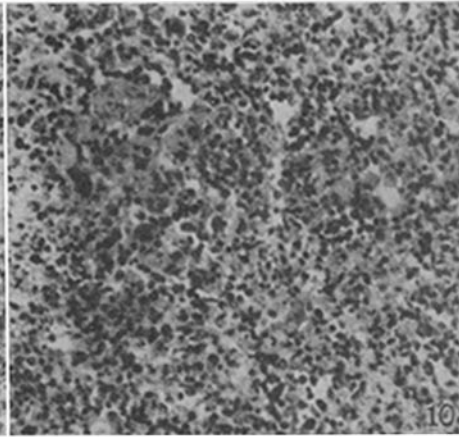
Spleen, *M. rhesus* 23. × 182.



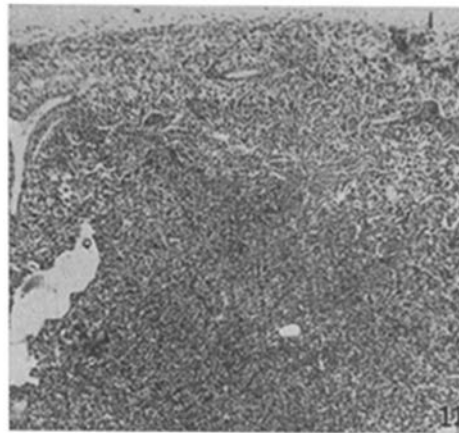
Spleen, *M. rhesus* 25. × 182.



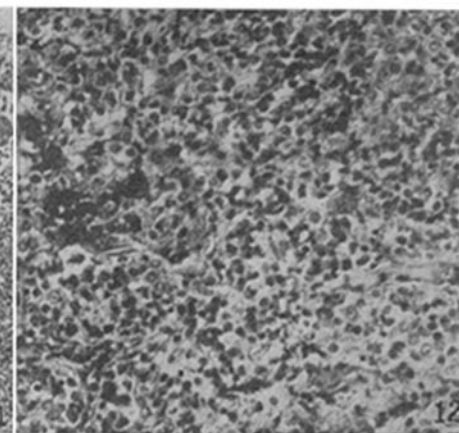
Spleen, human Oroya fever.



Spleen, human Oroya fever.

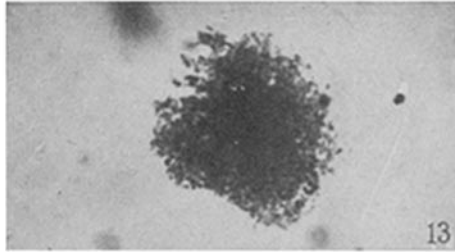


Lung nodule, *M. rhesus* 23. × 50.

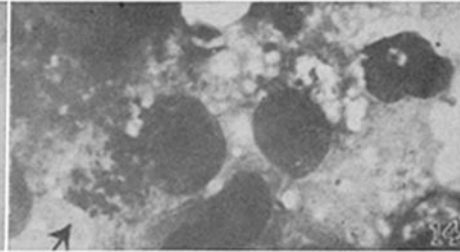


Lung nodule, *M. rhesus* 23. × 182.

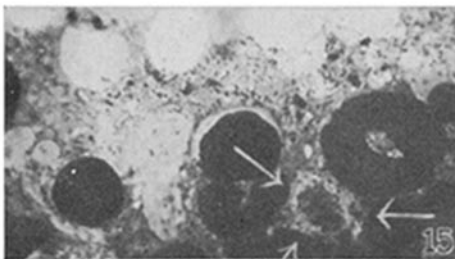
*Bartonella bacilliformis*. Giemsa's stain.  $\times 1,000$ .



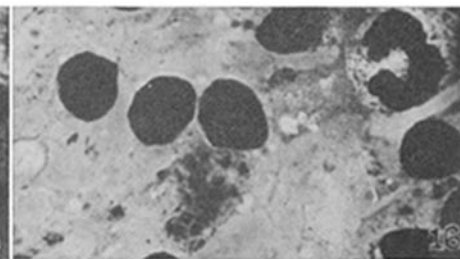
In culture, for comparison.



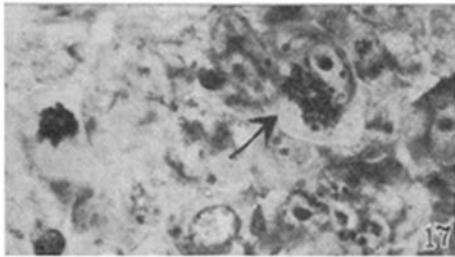
In lung nodule, *M. rhesus* 23.



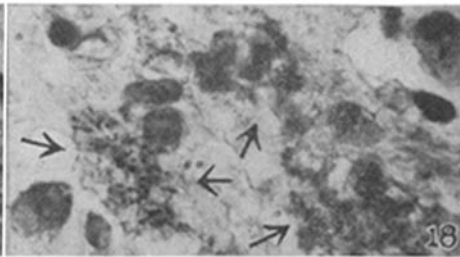
In bone marrow, *M. rhesus* 23.



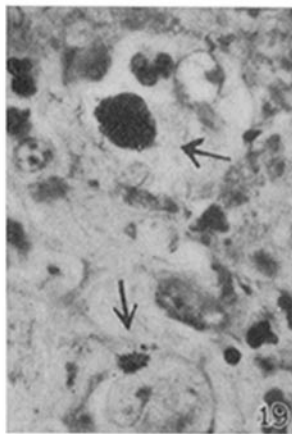
In spleen, *M. rhesus* 23.



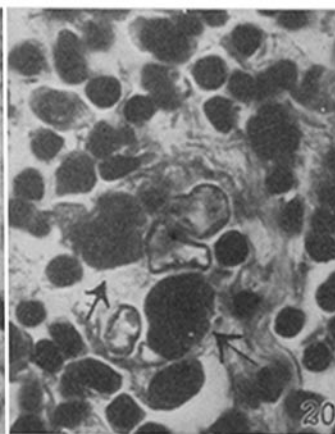
In skin nodule, *M. rhesus*.



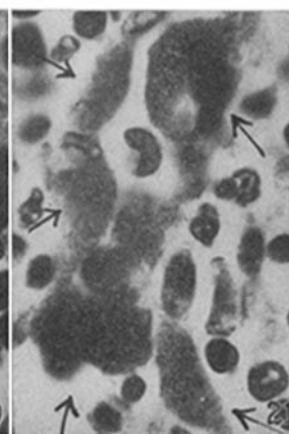
In skin nodule, chimpanzee.



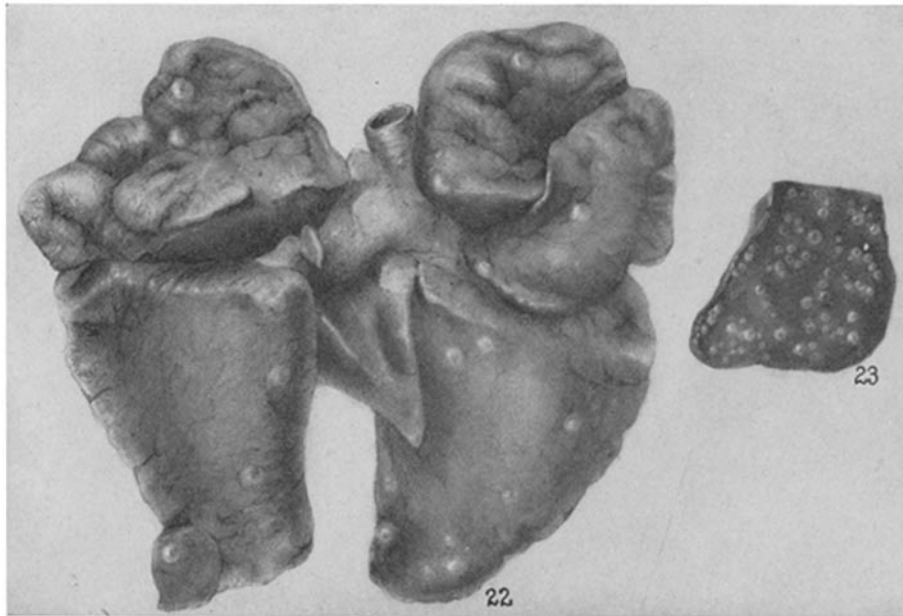In skin lesion, ourang-utan.



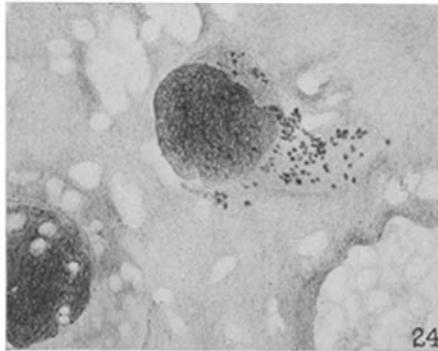
In human lymphatic gland.



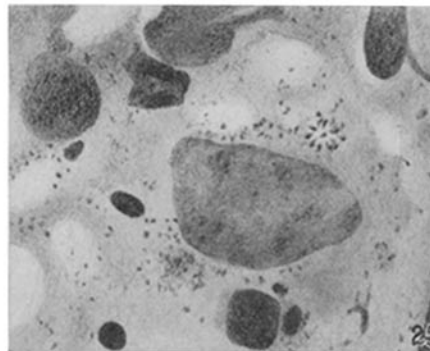
In human lymphatic gland.



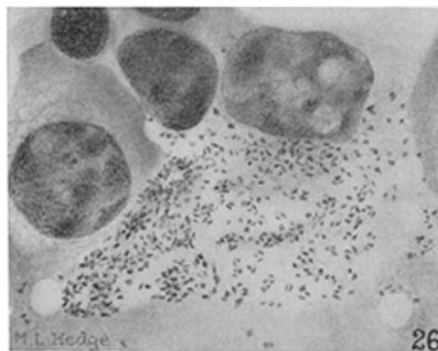
Lesions in lungs and spleen, *M. rhesus* 23.



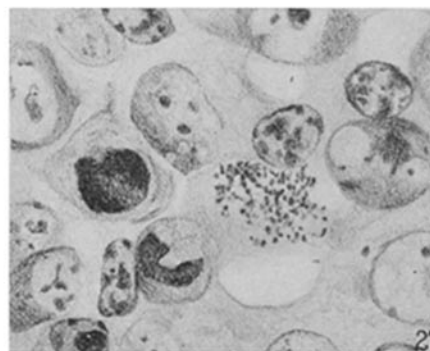
*Bartonella*, lung nodule, No. 23.



*Bartonella*, spleen, No. 23.



*Bartonella* (?), bone marrow, No. 24.



*Bartonella*, lymph gland, No. 29.