

THE FUNCTIONAL AND PATHOLOGICAL RESPONSE OF  
THE KIDNEY IN DOGS SUBJECTED TO A SECOND  
SUBCUTANEOUS INJECTION OF URANIUM  
NITRATE.\*

BY WILLIAM DEB. MACNIDER, M.D.

*(From the Laboratory of Pharmacology of the University of North Carolina,  
Chapel Hill.)*

PLATES 34 TO 37.

(Received for publication, November 3, 1928.)

In the preceding study it was shown that a certain number of dogs (Group II) rendered acutely nephritic from uranium, after having developed the functional response characteristic of such an injury returned to a complete functional normal. It was, furthermore, shown by a study of this group, that their ability to make such a functional readjustment depended upon the power of the respective animals to regenerate or replace in the proximal convoluted tubules two entirely different types of epithelium. In certain of the animals the regenerated epithelium resembled histologically normal proximal convoluted tubule cells, while in other animals in which a similar return in functional response was obtained, there was in addition to the regeneration of the above type of cell, a dominance in regeneration of a low, flattened, apparently less specialized epithelium. The object of the present study is to ascertain by subsequent injections of uranium if there is any difference in the susceptibility of these types of regenerated epithelium to this nephrotoxic agent, and if so, what variation can be obtained in the functional response of such secondarily injured kidneys.

In 1912 Suzuki (1) during his studies on the localization of the nephrotoxic action of uranium described the regeneration of convoluted tubule epithelium and noted a resistance which such animals had developed to a later intoxication by it.

---

\* Aided by a grant from the Ella Sachs Plotz Foundation.

Later than this, Aschoff (2), in reviewing Suzuki's work discussed the increased resistance of the renal epithelium to uranium and interpreted it as a defense mechanism. He did not specifically describe the morphology of the epithelium which had become resistant. In 1916 (3) a study was conducted in this laboratory on animals with a naturally acquired chronic nephritis in which it was shown, first, that a specific type of regenerated epithelium in the convoluted tubules was resistant to an injury from uranium, second, that normal convoluted tubule epithelium failed to manifest this resistance, and, third, that the regenerated cells were furthermore resistant to the toxic action of a general anesthetic. In 1924 Gil y Gil (4), in his research on the immunity of kidney cells to uranium, considered it possible to immunize the kidney of the rabbit against uranium, and that such a state was accomplished by the partial destruction of renal tissue which lead to a parenchymatous contracted kidney. He was able to show by biological methods, as Karsner, Reiman and Brooks (5) had previously shown by chemical methods, that the parenchymatous injury was coincident with the elimination of uranium by the kidney. Very recently Hunter (6) has described the acute renal injury in the rabbit kidney from uranium, has noted the changes of repair and has described the resistance or immunity of the epithelium to uranium.

In the following study the cytological basis for the resistance of the kidney of the dog to uranium will be discussed and the functional basis of this resistance, both when it occurs and when it fails to occur, will be considered in connection with the pathology of the kidney.

#### *Method.*

Forty-one dogs varying in age from 1 to 2 years were used in the experiments. The technique employed, with certain exceptions which will be noted, was identical with that followed in the preceding paper. In the present series of animals, after having obtained the normal observations, the dogs were given 2 mg. of uranium nitrate per kilo subcutaneously. Later in the experiments this amount of uranium, or twice the amount, was given as a secondary injection. In such experiments it becomes necessary to establish as controls, first, that the above amount of uranium will not only induce an acute nephritis, but such a reaction of repair on the part of the animals that a chronic nephritis will develop, second, to ascertain the effect of a second injection of uranium in an animal with an acute nephritis when functionally there is little evidence of recuperation, and, third, after a repair with recuperation has been effected to ascertain what is the anatomical difference in such states of recuperation which may determine the susceptibility or lack of susceptibility of the kidney to uranium.

Eight of the forty-one dogs developed an acute nephritis of such severity that they died from it or the experiments were terminated during its course. Such animals failed to develop any functional improvement and at autopsy showed the usual changes characteristic of this stage of the injury. Four of the remaining

thirty-three animals of the series were not given a second injection of uranium but were permitted to effect a renal repair with the development of a chronic nephritis. The course of the nephritis in the control animal of Experiment 8, Table I, is characteristic of this group and is in general similar to the animals of Group III in the previous study. The findings as indicated by the table do not require any further elaboration.

*The Functional and Pathological Response of the Kidney in Dogs Subjected to a Second Subcutaneous Injection of Uranium Nitrate.*

Secondary injections of uranium were made in dogs at three different stages of their reaction from the initial injection. During the course of the acute nephritis when there was either slight or no evidence of an improvement in renal function, after the animals had returned to a functional normal or after they had developed a chronic nephritis. In the last two groups in order to ascertain anatomically the existence of a chronic nephritis, renal tissue was removed from the upper pole of the left kidney to serve as a control before the secondary injection of uranium was made.

Eight animals were given a secondary injection of 2 mg. of uranium during the course of the acute nephritis when there was either no evidence of an improvement of renal function or when this evidence was slight. The control animal of Experiment 11, Table II, indicates the course of the nephritis in such animals.

Following the first injection of uranium the animal developed an acute nephritis which reached its height functionally on the 9th day. The output of urine, which was 749 cc., contained 2.1 gm. of albumin per liter and numerous granular casts. The elimination of phenolsulphonaphthalein was reduced from the normal of 77 per cent to 6 per cent, and the reserve alkali of the blood from 8.1 to 7.85. There was a retention of blood urea of 56 mg., non-protein nitrogen 124 mg. and creatinine 2.9 mg. On the 16th day of the acute nephritis after the animal had shown a slight functional improvement, the second injection of 2 mg. of uranium per kilo was made. The dog had lost only 0.5 of a kilo in body weight. Following the second injection there was a rapid increase in the indications of diminished renal function. On the 6th day following the injection the output of urine was reduced to 73 cc. and the amount of albumin had increased to 3.4 gm. There was no elimination of phenolsulphonaphthalein, the reserve alkali was reduced to 7.7 and there was a retention of urea nitrogen of 123 mg., non-protein nitrogen 289 mg. and creatinine 7.8 mg. On the 7th day the animal died in convulsions.

The pathological study of the kidneys showed them diffusely congested. The capsule was not adherent and when incised the swollen cortex appeared in the line

TABLE I.  
Control Experiment 8. Duration of Experiment, 4 Months and 10 Days.

| Duration of experiment. Date                   | Weight. Age          | Uranium nitrate | Water intake 24 hrs. | Urine output 24 hrs. | Albumin per liter | Glucose  | Acetone | Casts                                  | Phenolsulphone-phtalein | Reserve pH | Urea per 100 cc. blood | Non-protein nitrogen per 100 cc. blood | Creatinine per 100 cc. blood | Pathology of kidney  |
|--|----------------------|-----------------|----------------------|----------------------|-------------------|----------|---------|--|-------------------------|------------|------------------------|--|------------------------------|--|
|  |                      | mg. per kg.     | cc.                  | cc.                  | gm.               | per cent |         |  | per cent                |            | mg.                    | mg.                                    | mg.                          |  |
| Normal observation<br>10/15/27<br>10/17/27     | 14.7 kg.<br>1-2 yrs. | 0               | 500                  | 484                  | 0                 | 0        | 0       | 0                                      | 86                      | 8.05       | 14                     | 38                                     | 1.2                          | Kidneys appear normal. Capsule not thickened. Glomeruli show early capsular and intercapillary fibrosis. Definite increase in periglomerular and intertubular connective tissue  |
| 10/19/27. 2nd day of intoxication              |                      | 0               | 500                  | 741                  | 1.8               | Present  | Present | Numerous granular                      | 21                      | 7.9        | 35                     | 71                                     | 1.2                          | Epithelium lining convoluted tubules shows evidence in different tubules of degeneration and repair. Degenerative changes consist in cloudy swelling, edema and rarely necrosis. |
| 10/25/27. 8th day of intoxication              |                      | 0               | 500                  | 918                  | 2.0               | Present  | Present | No change                              | 8                       | 7.85       | 52                     | 131                                    | 3.4                          | Processes of repair are shown in replacement of normal tubular epithelium by flattened, frequently undifferentiated cytoplasmic layer with prominent nuclei                      |
| 11/17/27. 1 mo. after intoxication             |                      | 0               | 500                  | 514                  | Present           | 0        | 0       | Few finely granular. Numerous granular | 14                      | 7.95       | 35                     | 78                                     | 3.0                          |  |
| 2/27/28. 4 mos. and 10 days after intoxication |                      | 0               | 500                  | 607                  | Present           | 0        | 0       | No change                              | 48                      | 8.0        | 28                     | 51                                     | 2.0                          |  |

of incision. The cortex was pale in contrast with the medulla, and the glomeruli were prominent. The capillaries were distended with blood, and there was occasionally observed a granular exudate containing fibrin in the subcapsular spaces. There was no periglomerular connective tissue hyperplasia. The proximal convoluted tubule epithelium was in general severely swollen, edematous and necrotic. There was no evidence of epithelial repair either by the regeneration of epithelium normal for the convoluted tubules or by the formation of the flattened type of epithelial cell.

The animals of these six experiments showed a complete lack of resistance to a second injection of uranium when the nephrotoxic agent was given before processes of repair had taken place in the kidney with a return of its function definitely towards the normal. The second injection of uranium served to increase the severity of the epithelial degeneration and intensify the evidence of functional impairment (Fig. 1).

In the second group of ten animals the secondary injection of uranium was made after the dogs had established a complete functional recovery from the first injection. Prior to the second injection kidney tissue was removed to serve as a control for the renal changes developing from the second use of uranium. The control animal of Experiment 21, Table III, is representative of this group.

On the 6th day of the acute nephritis the output of urine was 842 cc. It contained 1 gm. of albumin per liter with granular casts. The elimination of phenolsulphonophthalein had been reduced from the normal of 79 per cent to 8 per cent and the reserve alkali from 8.1 to 7.85. There was a retention of 61 mg. of urea, 128 mg. of non-protein nitrogen and 3.2 mg. of creatinine. On the 24th day, judging from the functional findings, the animal had returned to the normal. There was an output of 470 cc. of urine which did not contain albumin and which was free from casts. The elimination of phenolsulphonophthalein was 68 per cent, the reserve alkali of the blood was normal and there was no evidence of retention. A wedge-shaped piece of tissue was removed from the upper pole of the left kidney. The tissue showed the glomerular capillaries distended with blood and an endothelium which appeared swollen with prominent nuclei. There was no exudate in the subcapsular spaces and no intracapillary or periglomerular connective tissue formation. The epithelium of the convoluted tubules showed marked evidence of regeneration by the formation of cells pyramidal in shape, containing deeply staining nuclei or nuclei in the process of mitotic division. The cells were of the type normal for the proximal convoluted tubules. In other tubule cells these changes had not progressed to the same degree of repair and the epithelium showed evidence of degeneration. The epithelial regeneration in this animal had not been

TABLE II.  
Control Experiment 11. Duration of Experiment, 23 Days.  
Data from the first intoxication by uranium nitrate.

| Duration of experiment. Date  | Weight. Age          | Uranium nitrate<br>ms. per kg. | Water intake 24 hrs.<br>cc. | Urine output 24 hrs.<br>cc. | Albumin per liter<br>gm. | Glucose<br>per cent | Acetone | Casts                             | Phenolsulphone-<br>phthalein<br>per cent | Reserve pH | Urea per 100 cc. blood<br>mg. | Non-protein nitrogen<br>per 100 cc. blood.<br>mg. | Creatinine per 100 cc.<br>blood<br>mg. | Pathology of kidney   |
|---|----------------------|--------------------------------|-----------------------------|-----------------------------|--------------------------|---------------------|---------|-----------------------------------|--|------------|-------------------------------|---|--|---|
|   |                      |                                |                             |                             |                          |                     |         |                                   |  |            |                               |   |  |   |
| Normal observations 10/20/27<br>10/22/27<br>10/24/27. 2nd day of intoxication | 12.2 kg.<br>1-2 yrs. | 0                              | 500                         | 312                         | 0                        | 0                   | 0       | 0                                 | 77                                       | 8.1        | 15                            | 36  | 1.1                                    | Kidneys show a diffuse congestion. Capsule not adherent. When capsule is incised swollen cortex bulges into incision. On section cortex is pale as contrasted with medulla. Glomeruli prominent. Glomerular capillaries distended with blood. Endothelium swollen and nuclei prominent. Capsules not thickened. No periglomerular connective tissue hyperplasia<br>Convuluted tubule epithelium in general severely swollen and vacuolated with areas of necrosis. In a study of large number of sections only 3 mitotic figures have been seen. Flattened type of regenerated epithelium has not appeared in tubules. No definite evidence of repair |
|   |                      | 2                              | 500                         | 608                         | 1.3                      | 0.4                 | Present | Numerous granular                 | 31                                       | 7.9        | 41                            | 80  | 1.1                                    |   |
| 11/3/27. 9 days after intoxication  |                      | 0                              | 500                         | 749                         | 2.1                      | Present             | Present | Numerous granular                 | 6  | 7.85       | 56                            | 124   | 2.9                                    |   |
| 11/8/27. 14th day of intoxication   |                      | 0                              | 500                         | 547                         | 0.2                      | 0                   | 0       | Numerous granular and hyaline     | 18                                       | 7.95       | 38                            | 81  | 2.5                                    |   |
| 11/10/27. 16th day of intoxication  | 11.7 kg.             | 2                              | 500                         |                             |                          |                     |         |                                   |  |            |                               |   |  |   |
| 11/12/27. 2nd day of 2nd intoxication   |                      | 0                              | 500                         | 342                         | 1.4                      | Trace               | Present | Numerous granular and few hyaline | 5  | 7.8        | 76                            | 159   | 3.8                                    |   |
| 11/14/27. 4th day of 2nd intoxication   |                      | 0                              | 500                         | 111                         | 4.2                      | Trace               | Trace   | No change                         | Trace                                    | 7.7        | 114                           | 271   | 7.2                                    |   |

|  |                                 |     |    |     |   |       |           |   |     |     |     |     |   |
|--|---------------------------------|-----|----|-----|---|-------|-----------|---|-----|-----|-----|-----|---|
| 11/16/27. 6th day of 2nd intoxication  | 0                               | 500 | 73 | 3.4 | 0 | Trace | No change | 0 | 7.7 | 123 | 289 | 7.8 | Epithelium of loops of Henle appears normal |
| 11/17/27. 7th day of 2nd intoxication  | Convulsions. Died in air hunger |     |    |     |   |       |           |   |     |     |     |     |   |
| Experiment shows no resistance to 2nd uranium injection when given before processes of repair have taken place in kidney with return of its function toward normal. 2nd injection of uranium increases the epithelial degeneration |                                 |     |    |     |   |       |           |   |     |     |     |     |   |

TABLE III.  
Control Experiment 21. Duration of Experiment, 33 Days.  
Data from the first intoxication by uranium nitrate.

| Duration of experiment. Date       | Weight. Age          | Uranium nitrate<br>mg. per kg. | Water intake 24 hrs.<br>cc. | Urine output 24 hrs.<br>cc. | Albumin per liter<br>gm. | Glucose<br>per cent | Acetone | Casts   | Phenolsulphone-<br>phtalein<br>per cent | Reserve pH | Urea per 100 cc. blood<br>ms. | Non-protein nitrogen<br>per 100 cc. blood<br>mg. | Creatinine per 100 cc.<br>blood<br>mg. | Pathology of kidney   |
|------------------------------------|----------------------|--------------------------------|-----------------------------|-----------------------------|--------------------------|---------------------|---------|---|---|------------|-------------------------------|--|--|---|
| Normal observations<br>10/15/27    | 16.4 kg.<br>1-2 yrs. | 0                              | 500                         | 471                         | 0                        | 0                   | 0       | 0   | 79                                      | 8.1        | 12                            | 34   | 1.3                                    | Microscopic study of tissue removed on 24th day shows many glomeruli which appear larger than normal. Glomerular endothelium contains prominent nuclei. Capillaries engorged with blood. No sub-capsular exudate. Capsules not thickened, no periglomerular fibrosis<br>Convoluted tubule epithelium shows 2 types of changes. Evidence of repair seen in occurrence of mitotic figures in epithelium which in general is characteristic for cells in this part of tubule. Other areas show these cells in various stages of injury as indicated by cloudy swelling and edema |
| 10/17/27                           |                      | 2                              | 500                         | 887                         | 2.1                      | 1.0                 | Present | Numerous finely and coarsely granular           | 38                                      | 7.95       | 33                            | 64   | 1.4                                    |   |
| 10/19/27. 2nd day of intoxication  |                      | 0                              | 500                         | 1085                        | 2.3                      | Present             | Present | Numerous coarsely granular                      | 15                                      | 7.95       | 48                            | 90   | 2.4                                    |   |
| 10/21/27. 4th day of intoxication  |                      | 0                              | 500                         | 842                         | 1.0                      | Trace               | Present | No change                                       | 8                                       | 7.85       | 61                            | 128  | 3.2                                    |   |
| 10/23/27. 6th day of intoxication  |                      | 0                              | 500                         | 561                         | Present                  | 0                   | 0       | Numerous finely granular. Few coarsely granular | 21                                      | 7.95       | 40                            | 78   | 2.2                                    |   |
| 10/29/27. 12th day of intoxication |                      | 0                              | 500                         |                             |                          |                     |         |   |   |            |                               |  |  |   |



|                                       |   |              |     |   |       |         |                                       |       |     |     |     |     |   |
|---------------------------------------|---|--------------|-----|---|-------|---------|---------------------------------------|-------|-----|-----|-----|-----|---|
| 11/2/27. 16th day of intoxication     | 0 | 500          | 681 | Present   | 0     | 0       | No change                             | 48    | 8.0 | 20  | 38  | 1.8 | No epithelial replacement by flattened, less specialized epithelial lining of convoluted tubules which is resistant to uranium<br>At termination of experiment kidneys were swollen and cortex pale with prominent glomeruli. Histologically many glomeruli appeared normal except for intense congestion of capillaries and prominence of endothelium. In others there was matting together of the loops, increase in nuclei and thickening of capsule. Changes in convoluted tubules were those of edema, vacuolation and severe necrosis. No evidence of repair. Epithelium of descending limb of Henle's loop appeared normal |
| 11/10/27. 24th day of intoxication    | 0 | 500          | 470 | 0   | 0     | 0       | 0                                     | 68    | 8.1 | 14  | 32  | 1.2 |   |
| 11/12/27. 26th day of intoxication    | 2 | 500          |     |   |       |         |                                       |       |     |     |     |     |   |
|                                       |   |              |     | Data from the second intoxication by uranium nitrate. |       |         |                                       |       |     |     |     |     |   |
| 11/14/27. 2nd day of 2nd intoxication | 0 | 500          | 879 | 2.0   | 1.1   | Present | Numerous coarsely and finely granular | 20    | 7.9 | 42  | 91  | 2.3 | Epithelial repair of kidney by type of specialized epithelium resembling convoluted tubule epithelium has no resistance to 2nd injection of uranium   |
| 11/16/27. 4th day of 2nd intoxication | 0 | 500          | 381 | 2.3   | 0.8   | Present | No change                             | Trace | 7.8 | 86  | 172 | 4.8 |   |
| 11/19/27. 7th day of 2nd intoxication | 0 | 500 vomited. | 105 | 1.1   | Trace | Present | No change                             | 0     | 7.7 | 105 | 214 | 6.8 |   |

TABLE IV.  
Experiment 3. Duration of Experiment, 3 Months and 18 Days.  
Data from the first intoxication by uranium nitrate.

| Duration of experiment. Date          | Weight. Age          | Uranium nitrate<br>ms. per kg. | Water intake 24 hrs.<br>cc. | Urine output 24 hrs.<br>cc. | Albumin per liter<br>gm. | Glucose<br>per cent | Acetone | Casts  | Phenolsulphone-<br>phthalein<br>per cent | Reserve pH | Urea per 100 cc. blood<br>mg. | Non-protein nitrogen<br>per 100 cc. blood<br>mg. | Creatinine per 100 cc.<br>blood<br>mg. | Pathology of kidney  |  |
|---------------------------------------|----------------------|--------------------------------|-----------------------------|-----------------------------|--------------------------|---------------------|---------|--|--|------------|-------------------------------|--|--|--|--|
| Normal observations<br>10/18/27       | 18.7 kg.<br>1-2 yrs. | 0                              | 500                         | 482                         | 0                        | 0                   | 0       | 0  | 74                                       | 8.0        | 15                            | 37   | 1.4                                    | Changes in kidney have resulted from 2nd injection of 2 mg. of uranium nitrate per kg.<br>Glomerular pathology is similar to that described for animal of Experiment 8, Table I. Definite periglomerular and intertubular formation of connective tissue; both cellular and fibrous following 2nd subcutaneous injection of uranium there developed increase in processes of degeneration of convoluted tubule cells which are normal for this location. Cells show advanced edema and necrosis. Regenerated flattened type of epithelium which has lined many convoluted tubules as process of repair following 1st uranium injection is resistant to 2nd injection of uranium. Such cells show no evidence of degeneration |  |
| 10/23/27                              |                      | 2                              | 500                         | 748                         | 2.3                      | Present             | Present | Numerous granular                            | 15                                       | 7.85       | 32                            | 57   | 3.0                                    |  |  |
| 10/25/27. 2nd day of intoxication     |                      | 0                              | 500                         | 811                         | 2.8                      | 1.1                 | Present | No change                                    | 5  | 7.85       | 49                            | 120  | 4.8                                    |  |  |
| 10/31/27. 8th day of intoxication     |                      | 0                              | 500                         | 400                         | 0.8                      | 0                   | 0       | Few granular. Numerous hyaline               | 10                                       | 7.95       | 45                            | 90   | 4.4                                    |  |  |
| 11/3/27. 11th day after uranium       |                      | 0                              | 500                         | 593                         | Present                  | 0                   | 0       | No change                                    | 55                                       | 7.95       | 30                            | 60   | 3.8                                    |  |  |
| 11/11/27. 19th day after uranium      |                      | 2                              | 500                         |                             |                          |                     |         |  |  |            |                               |  |  |  |  |
| 11/11/27                              | 17.8 kg.             | 0                              | 500                         | 641                         | 1.2                      | Trace               | Trace   | Increase in granular casts. Numerous hyaline | 38                                       | 7.95       | 33                            | 68   | 4.1                                    |  |  |
| 11/13/27. 2nd day of 2nd intoxication |                      | 0                              | 500                         |                             |                          |                     |         |  |  |            |                               |  |  |  |  |

|  |   |     |     |         |   |   |   |   |    |     |      |    |     |
|--|---|-----|-----|---------|---|---|---|---|----|-----|------|----|-----|
| 11/17/27. 6th day of 2nd intoxication            | 0 | 500 | 748 | 0.8     | 0 | 0 | 0 | No change                                     | 44 | 8.0 | 33   | 70 | 4.0 |
| 1/7/28. 1 mo. and 27 days after 2nd intoxication | 0 | 500 | 463 | 0.6     | 0 | 0 | 0 | Few granular. Numerous hyaline                | 63 | 8.0 | 32   | 60 | 1.7 |
| 1/19/28. 2 mos. and 8 days after 2nd uranium     | 0 | 500 | 533 | Present | 0 | 0 | 0 | Occasional finely granular. Numerous hyaline  | 44 | 8.0 | 22.5 | 44 | 2.2 |
| 1/25/28. 2 mos. and 14 days after 2nd uranium    | 0 | 500 | 786 | Present | 0 | 0 | 0 | No change                                     | 33 | 8.0 | 28   | 49 | 3.0 |
| 2/10/28. 2 mos. and 30 days after 2nd uranium    | 0 | 500 | 613 | Present | 0 | 0 | 0 | No change in type of cast. Decrease in number | 50 | 8.0 | 16   | 40 | 2.1 |

aided by the formation of the low, flattened type of cell which has been previously described. Associated with the specialized type of epithelial repair and in the absence of structural changes of repair in the glomeruli, the animal with the exception of a reduced phenolsulphonephthalein elimination returned to a normal functional state (Fig. 2).

On the 26th day from the commencement of the initial uranium intoxication, the dog was given a second subcutaneous injection of 2 mg. of uranium nitrate per kilo. During this period the animal's weight had undergone a reduction of 1.6 kg. On the 4th day following the second injection of uranium there was an output of 381 cc. of urine which contained 2.3 gm. of albumin and numerous coarsely and finely granular casts. The elimination of phenolsulphonephthalein was reduced to a trace and the reserve alkali was reduced to 7.8. There was a retention of urea of 86 mg. non-protein nitrogen 172 mg. and creatinine 4.8 mg. On the 7th day of the acute nephritis following the second injection of uranium the formation of urine was reduced to 105 cc. which contained 1.1 gm. of albumin. There was no elimination of phenolsulphonephthalein, the reserve alkali of the blood was reduced to 7.7 and there was a retention of urea of 105 mg., non-protein nitrogen 214 mg. and creatinine 6.8 mg. The animal was semiconscious, in air hunger and was killed. The kidneys were swollen and the capsule not adherent. On section the cortex was pale in contrast with the medulla. Histologically the glomeruli varied in their reaction. Many of these units appeared normal except for an intense congestion of the capillaries and a prominence of the endothelium. In others, there was a matting together of the loops, an increase in nuclei, some thickening of the capsule and an early formation of connective tissue. The changes in the proximal convoluted tubule epithelium were characterized by edema, vacuolation and extensive necrosis. There was no evidence of repair. The epithelium of the descending limb of Henle's loop appeared normal (Fig. 3).

In this series of animals subjected to a second injection of uranium nitrate after they had returned to a functional normal which was characterized histologically by a process of epithelial repair with the formation of a type of epithelium closely resembling that of normal convoluted tubule epithelium and in which there was no replacement of these cells by a flattened atypical type, the animals have failed to show any resistance to uranium. On the contrary, judging from the severity of the functional response, as well as from the histological changes in the kidney, they appear to have developed an increased susceptibility to the nephrotoxic agent.

The third and final group of fifteen animals for which the preceding groups served as controls were given a second injection of uranium after they had developed an acute nephritis and had later repaired this

injury with the establishment of a chronic nephritis. When the animals had developed such a state functionally tissue was removed from the left kidney to establish its existence histologically and to serve as a control for those changes developing after the second injection. The animal of Experiment 3, Table IV, shows a response characteristic of this group.

On the 8th day of the acute nephritis there was an output of 811 cc. of urine which contained 2.8 gm. of albumin per liter and granular casts. The elimination of phenolsulphonophthalein was reduced to 5 per cent and the reserve alkali to 7.85. There was a retention of blood urea of 49 mg., non-protein nitrogen 120 mg. and creatinine 4.8 mg. On the 11th day the functional evidence of renal injury had shown an improvement. On the 19th day the animal formed 593 cc. of urine which contained albumin and finely granular and hyaline casts. The elimination of phenolsulphonophthalein had increased to 55 per cent, and the reserve alkali to 7.95. There was evidence of retention with a blood urea of 30 mg., non-protein nitrogen 60 mg. and creatinine 3.8 mg. Such changes in function at this period of recovery from the acute nephritis have been characterized histologically in tissue removed at this time by the commencement of changes of structural repair in the glomeruli and by the regeneration in the injured convoluted tubules of two types of epithelium, either a cell which closely resembles the normal convoluted tubule cell or by a flattened imperfectly differentiated cell layer. On the same day that the above observations were made this animal was given a second subcutaneous injection of 2 mg. of uranium per kilo. On the 2nd day of the secondary acute renal injury the output of urine was 641 cc., and contained 1.2 gm. of albumin and an increase in the number of granular casts. The elimination of phenolsulphonophthalein was only reduced from the animal's pathological normal of 55 per cent to 38 per cent, the reserve alkali of the blood was unaffected and there was but a slight increase in blood retention over that observed at the animal's maximum point of recuperation from the first uranium. On the 6th day of the second intoxication from uranium the amount of albumin in the urine had decreased to 0.8 gm. per liter, the output of phenolsulphonophthalein had increased to 44 per cent, the reserve alkali of the blood was normal and the evidence of retention had diminished. From this stage of the experiment until its termination 3 months after the second uranium injury, there was in general continued evidence of functional improvement. At the final observation there was an output of 613 cc. of urine which contained albumin and finally granular and hyaline casts. The elimination of phenolsulphonophthalein was 50 per cent, the reserve alkali of the blood was normal, there was no retention of blood urea and non-protein nitrogen but a retention of 2.1 mg. of creatinine.

The pathological study showed a definite, chronic, fibrous glomerular injury with the formation of periglomerular and intertubular connective tissue. The epithelial reaction showed evidence of degeneration in the convoluted tubule

TABLE V.  
*Experiment 7. Duration of Experiment, 4 Months and 12 Days.*  
 Data from the first intoxication by uranium nitrate.

| Duration of experiment. Date       | Weight. Age | Uranium nitrate | Water intake 24 hrs. | Urine output 24 hrs. | Albumin per liter | Glucose  | Acetone | Casts  | Phenolsulphone-phthalein | Reserve pH | Urea per 100 cc. blood | Non-protein nitrogen per 100 cc. blood | Creatinine per 100 cc. blood | Pathology of kidney  |
|------------------------------------|-------------|-----------------|----------------------|----------------------|-------------------|----------|---------|--|--------------------------|------------|------------------------|--|------------------------------|--|
|                                    |             | mg. per kg.     | cc.                  | cc.                  | gm.               | per cent |         |  | per cent                 |            | mg.                    | mg.                                    | mg.                          |  |
| Normal observations                | 18.1 kg.    | 0               | 500                  | 483                  | 0                 | 0        | 0       | 0  | 75                       | 8.1        | 16                     | 33                                     | 1.8                          | Tissue removed from left kidney 1 mo. and 26 days after commencement of nephritis shows glomeruli in various stages of connective tissue overgrowth. Many capillary loops are obliterated by such changes while others contain blood. Capsules show thickening. Formation of periglomerular and intertubular connective tissue. Epithelium of tubules shows cloudy swelling, edema and necrosis of cells in tubules which have not been repaired. In other tubules repair has taken place by formation of type of flattened cells resistant to uranium. Changes in kidney which have resulted from 2nd injection of 4 mg. of uranium nitrate per kg. similar to those described for animal of Experiment 3, Table IV |
| 11/14/27                           | 1-2 yrs.    | 0               | 500                  | 792                  | 3.0               | 0.3      | Present | Few hyaline.                                       | 20                       | 7.9        | 24                     | 52                                     | 2.0                          |  |
| 11/16/27. 2nd day of intoxication  |             | 0               | 500                  | 811                  | 4.0               | 0.5      | 0       | Numerous granular                                  | 5                        | 7.85       | 97                     | 275                                    | 5.4                          |  |
| 11/21/27. 7th day of intoxication  |             | 0               | 500                  | 614                  | 3.2               | 0.5      | 0       | No change  | 20                       | 7.9        | 160                    | 310                                    | 7.5                          |  |
| 11/28/27. 14th day of intoxication |             | 0               | 500                  | 510                  | 1.1               | 0.       | 0       | No change  | 50                       | 7.95       | 40                     | 60                                     | 3.0                          |  |
| 12/7/27. 24th day of intoxication  |             | 0               | 500                  | 723                  | Present           | 0        | 0       | Decrease in granular and increase in hyaline casts | 45                       | 7.95       | 42                     | 60                                     | 2.8                          |  |
| 12/14/27. 1 mo. after intoxication |             | 0               | 500                  | 723                  | Present           | 0        | 0       | No change  | 45                       | 7.95       | 42                     | 60                                     | 2.8                          |  |

| 1/9/28. 1 mo. and 26 days after intoxication       | 0 | 500 | 583   | Present | 0   | 0 | No change                                  | 60 | 8.05 | 31 | 61 | 2.8 |   |
|--|---|-----|---|---------|-----|---|--|----|------|----|----|-----|---|
| 1/14/28  | 4 | 500 | Data from the second intoxication by uranium nitrate. |         |     |   |  |    |      |    |    |     |   |
| 1/16/28. 2nd day of 2nd intoxication               | 0 | 500 | 748   | 1       | 0.6 | 0 | Hyaline casts. Increase in granular casts  | 51 | 8.0  | 22 | 78 | 3.0 |   |
| 1/20/28. 6th day of 2nd intoxication               | 0 | 500 | 914   | 1       | 0.5 | 0 | No change                                  | 12 | 8.0  | 29 | 72 | 3.6 |   |
| 1/26/28. 12th day of 2nd intoxication              | 0 | 500 | 542   | Present | 0   | 0 | Hyaline casts. Decrease in granular casts  | 31 | 8.05 | 19 | 47 | 2.1 |   |
| 2/26/28. 1 mo. and 12 days after 2nd intoxication  | 0 | 500 | 811   | Present | 0   | 0 | No change                                  | 20 | 8.1  | 18 | 45 | 2.4 |   |
| 3/26/28. 2 mos. and 12 days after 2nd intoxication | 0 | 500 | 510   | Present | 0   | 0 | Few granular casts. Numerous hyaline casts | 53 | 8.1  | 17 | 52 | 1.8 |   |
| Kidney tissue removed                              |   |     |   |         |     |   |  |    |      |    |    |     | normal for convoluted tubules intensified. Regenerated epithelium of flattened, non-specialized type unaffected by 2nd injection of increased amount of uranium |
| 17.7 kg.   |   |     |   |         |     |   |  |    |      |    |    |     |   |

epithelium either primarily normal for this location or regenerated after the first uranium injury. The regenerated flattened type of epithelial cell which lined many of the convoluted tubules resulting as a repair process from the initial injury, showed no indications of degeneration. Such cells stained uniformly, and the nuclei were prominent and hyperchromatic. This is the type of cell which is resistant to uranium and which gives to the kidney its so called immunity to a second uranium injury.

The response obtained from the second injection of uranium in this animal is entirely different both functionally and histologically from the preceding animal of Experiment 21, Table III, Figs. 2 and 3. This animal following a less severe acute nephritis returned to a functional normal which was associated histologically by the repair of the acute tubular injury with the formation of an epithelium closely resembling that of normal convoluted tubule epithelium. Following the second use of uranium the animal developed an acute nephritis which was functionally more severe than the initial nephritis. There was extensive necrosis of the regenerated, specialized convoluted tubule cells. The animal was killed after having developed a state of semiconsciousness and air hunger. The specialized type of convoluted tubule epithelial repair in this animal had no resistance to a second administration of uranium. The non-specialized type of convoluted tubule epithelial repair developed by the animal of Experiment 3, Table IV, was resistant to the second injection of uranium.

In order to emphasize the resistance which a certain type of repaired kidney develops to uranium, three animals of this final group were given an acute nephritis from 2 mg. of uranium per kilo and permitted to effect a recovery with the establishment functionally of a chronic nephritis. The character of the anatomical process in the kidney was determined at such a stage of functional improvement by the removal of a piece of renal tissue for study. Following this, the second injection of uranium was given, in which the amount was increased to 4 mg. per kilo. The animal of Experiment 7, Table V, is representative of the findings in these animals.

The height of the dog's reaction from the first injection of uranium was obtained on the 7th day. At this period the animal formed 811 cc. of urine, which contained 4 gm. of albumin per liter, a few hyaline and numerous granular casts. The 2 hour output of phenolsulphonephthalein was reduced to 5 per cent, the reserve



alkali of the blood to 7.85 and there was a retention of blood urea of 97 mg., non-protein nitrogen 275 mg. and creatinine 5.4 mg. Later in the acute nephritis there was an even higher retention of these bodies. On the 24th day of the acute injury there was definite evidence of functional improvement. The urine contained 1.1 gm. of albumin and the number of granular casts had decreased while the hyaline type of cast was definitely increased. The elimination of phenolsulphonaphthalein had increased to 50 per cent, the reserve alkali to 7.95, the retention of urea to 40 mg., non-protein nitrogen to 60 mg. and creatinine to 3 mg. 1 month and 26 days following the commencement of the acute injury the animal had reached as indicated by previous studies what appeared to be its maximum degree of functional improvement. On this day a wedge of tissue was removed from the upper pole of the left kidney. The tissue showed chronic glomerular injuries as indicated by the capsular and intracapillary formation of connective tissue with the obliteration of capillary loops and with the formation of adhesions between the loops and the capsule. Other capillary loops were patent and engorged with blood. There was a formation of both periglomerular and intertubular connective tissue. The epithelium of the tubules showed cloudy swelling, edema but rarely necrosis in those tubules in which a repair had not taken place or in the tubules in which repair had developed by the formation of specialized cells resembling normal convoluted tubule cells. In other convoluted tubules a predominant type of repair had taken place by the formation of the flattened type of cell which has been shown to be resistant to uranium (Fig. 4). 5 days after securing this tissue for study, the animal was given 4 mg. of uranium nitrate per kilo, nearly twice the total amount of the primary injection. The dog had decreased 0.3 kg. in body weight. On the 2nd day following the second injection of uranium the animal formed 748 cc. of urine which contained only 1 gm. of albumin. There was an increase in the number of granular casts. The elimination of phenolsulphonaphthalein was but slightly decreased from the pathological normal of recuperation of 60 per cent to 51 per cent. The reserve alkali was reduced from 8.05 to 8.0. There was no appreciable increase in the retention of urea, non-protein nitrogen and creatinine. On the 12th day of the secondary acute nephritis the urine contained a heavy trace of albumin, there was a decrease in the number of granular casts, an elimination of phenolsulphonaphthalein of 31 per cent and the reserve alkali was 8.05. There was a slight retention of non-protein nitrogen and creatinine. The experiment was terminated 2 months and 12 days following the secondary use of uranium at which time, with but slight variations, the functional state of the dog had remained unchanged for 3 weeks. The 510 cc. of urine obtained on this day contained a heavy trace of albumin, a few granular and numerous hyaline casts. The output of phenolsulphonaphthalein was 53 per cent, the reserve alkali was normal. There was no retention of blood urea, a retention of non-protein nitrogen of 52 mg. and no retention of creatinine.

The kidneys at autopsy showed an irregular surface, with a thickened and in

areas adherent capsule. The cortex was irregularly thinned. The glomeruli showed an increase in the degree of fibrosis over that which had been observed following the changes of repair secondary to the first acute nephritis from uranium. The convoluted tubules showed three types of changes. Many of the tubules were lined by the flattened, resistant type of epithelium which has been previously described. In such areas there was no evidence of degeneration from the second injection of uranium which was given in twice the original amount. In other convoluted tubules there was evidence of cell degeneration of the specialized cells normal for the convoluted tubules and repair by the flattened type of cell. Lastly, there were convoluted tubules in which there was no evidence of repair but edema and vacuolation of the epithelium (Figs. 5 and 6.).

These last experiments show conclusively the resistance of the kidney to a secondary nephrotoxic action from uranium to be dependent upon the ability of the kidney to repair the initial epithelial injury by the predominant formation of an atypical epithelium for this part of the tubule and not by the regeneration of a specialized cell closely resembling those which are normally found in the proximal convoluted tubules.

#### DISCUSSION AND CONCLUSIONS.

The general subject of renal repair has been considered to a greater or less extent in many of the studies concerned with the experimental production of an acute uranium nephritis, as well as those in which the delayed injury was investigated. In 1911 in a study of the regeneration of renal epithelium in the cat kidney (7) two types of processes were described. In the more common type there was an invasion of the necrotic material in the damaged tubules by nuclei which had arisen from not too severely damaged cells in this location which later acquired their cytoplasmic covering. In the more usual type of regeneration a syncytial-like tongue or bud of poorly staining cytoplasm containing hyperchromatic nuclei was described as arising from cells below the area of necrosis, pushing itself into the necrotic material of the tubule, with a differentiation of the cells which arranged themselves on the basement membrane of the tubule. In later studies (8, 9) the regeneration of epithelium in the convoluted tubules was discussed as arising from a similar syncytial ingrowth into these tubules which originated from the cells in the upper portion of the

descending limb of Henle's loop. The origin of such epithelial ingrowths was first observed by Suzuki (10). In a later paper Oliver (11) described the repair to the epithelium as being due to a wandering into the epithelial detritus of cells which became fixed in the area of degeneration and lead to a repair of the tubules. In a very recent study by Hunter (12) of the acquired resistance of the rabbit kidney to uranium, he considers that the epithelial repair originates from convoluted tubule cells which though definitely altered in appearance, remain alive and attached to the basement membrane. From the studies of repair to the tubules which have been made in the preceding paper as well as in the present investigation, in which in addition to the histological studies, functional observations were included, it is clear that more than one type of repair process may be instituted to replace the loss of proximal convoluted tubule cells. If the initial injury from uranium to the epithelium of these tubules is not too severe as is shown functionally in terms of the severity of the response and the rapidity with which the animal establishes a functional normal, the repair is effected by a regeneration of cells from preexisting tubule cells normal for this location (Fig. 7). Such cells have no resistance against a secondary nephrotoxic action from uranium. On the contrary, as has been shown for cells in this location during the gestation period of the dog, when uranium was used to induce an acute nephritis (13), their susceptibility to the poison may be increased. The present studies have confirmed the observation made first in this laboratory and also by Suzuki and Oliver, that a repair to the convoluted tubules may originate as an ingrowth from below of cells as such or in the form of a syncytial mass into the necrotic material in the proximal convoluted tubule (Fig. 8). There is a replacement of convoluted tubule cells in this instance by an entirely different type of cell and following such a replacement the kidney does not return to a functional normal unless at the same time that this second type of repair is developing there is also taking place to a considerable degree a repair by the first process from preexisting convoluted tubule cells. The flattened type of epithelium originating as an ingrowth from below is resistant to uranium, is less specialized in structure and apparently in function.

## CONCLUSIONS.

The present study permits the following conclusions.

1. Uranium nitrate in the dog has a high degree of selective affinity as a nephrotoxic for the epithelium of the proximal convoluted tubules. The glomeruli participate in the injury and develop obliterative connective tissue changes as evidence of a preexisting acute injury followed by repair.

2. The repair to the degenerated tubular epithelium is accomplished by two processes. First, by a regeneration of convoluted tubule cells from such cells not too severely injured in this location. This type of regenerated epithelium has no resistance to uranium. Second, the regeneration may occur as an ingrowth of cells or as syncytial buds from cells in the terminal portion of the proximal convoluted tubule or from the upper end of the descending limb of Henle's loop. This type of regenerated epithelium which is entirely different cytologically from normal convoluted tubule epithelium is resistant to a second injury from uranium even when the amount of this nephrotoxic agent has been increased to double the amount of the initial injection.

3. The kidney does not develop a local tissue immunity or resistance to uranium in the sense that cells of the same type once injured by it acquire as a result of the injury a resistance. The resistance and apparent but not real immunity is due to another type of cell with resistance having been substituted for a cell with but little resistance. This fact may be looked upon as constituting part of a defense mechanism in the kidney and may in part explain the long duration of certain types of chronic nephritic processes.

4. The functional studies which have been made during the initial injury from uranium to the tubules and during the secondary injury in animals which have either shown a resistance or a lack of resistance, emphasize the importance of the tubular epithelium as a part of a secretory mechanism in urine formation. During periods when the proximal convoluted tubule epithelium is in a state of acute degeneration there is a disturbance in the acid-base equilibrium of the blood, a reduction in the elimination of phenolsulphonephthalein and a retention of urea nitrogen, non-protein nitrogen and creatinine. When this epithelium is regenerated by the formation of a tubular epithelium

normal in character for this location of the tubule, regardless of structural changes in the glomeruli, the above evidence of renal dysfunction returns to the normal. If at such a period this type of regenerated epithelium be injured by a secondary injection of uranium a state of acute renal dysfunction is induced in an intensified form. In those animals in which the repair to the tubules was accomplished by the formation of an atypical type of epithelium in the convoluted tubules as well as by the formation of cells normal in histological appearance for this part of the tubule there was an improvement in the degree of depletion of the reserve alkali of the blood, in the elimination of phenolsulphonophthalein and in the retention of urea nitrogen, non-protein nitrogen and creatinine. Certain of these values did not reach the normal. In such a state of renal repair when a second injection of uranium was given the kidney was found to have developed a marked resistance to it. There was but slight evidence of a depression in renal function. Associated with this acquired functional resistance there was no evidence of injury to the atypical, flattened regenerated epithelium of the proximal convoluted tubules.

## BIBLIOGRAPHY.

1. Suzuki, T., *Nierensekretion*, Fischer, Jena, 1912.
2. Aschoff, L., *Lectures on pathology*, Hoeber, New York, 1924.
3. MacNider, W. deB., *J. Med. Research*, 1916, xxxiv, 177.
4. Gil y Gil, C., *Beitr. path. Anat., u. allg. Path.*, 1924, lxxii, 621.
5. Karsner, H. T., Reiman, S. P., and Brooks, S. C., *J. Med. Research*, 1918-19, xxxix, 163.
6. Hunter, W. C., *Ann. Int. Med.*, 1928, i, 747.
7. MacNider, W. deB., *J. Med. Research*, 1911, xxv, 369.
8. MacNider, W. deB., *J. Exp. Med.*, xxix, 513.
9. MacNider, W. deB., *Arch. Int. Med.*, 1920, xxvi, 1.
10. Suzuki, T., *Nierensekretion*, Fischer, Jena, 1912.
11. Oliver, J., *J. Exp. Med.*, 1915, xxi, 425.
12. Hunter, W. C., *Ann. Int. Med.*, 1928, i, 747.
13. MacNider, W. deB., Helms, S. T., and Helms, S. C., *Bull. Johns Hopkins Hosp.*, 1927, xl, 145.

## EXPLANATION OF PLATES.

## PLATE 34.

FIG. 1. Camera lucida drawing, Leitz, oc. 2, obj. 6. The figure is from the kidney of the control animal of Experiment 11, Table II. The second injection of uranium was given during the initial acute nephritis before there was any evidence of an improvement in renal function. A secondary injection of uranium at such a period increases the severity of the acute pathology and intensifies the evidence of functional impairment. The kidney shows no resistance to uranium. At *a*, is shown a glomerulus with the capillaries distended with blood. The endothelial cells are prominent with deeply staining nuclei. There is no subcapsular exudate. At *b*, are shown convoluted tubules in various stages of edema and necrosis. At *c*, is shown the descending limb of Henle's loop and at *d*, the ascending limb with a normal epithelial lining.

FIG. 2. Camera lucida drawing, Leitz, oc. 2, obj. 6. The figure is from the kidney of the control animal of Experiment 21, Table III. The tissue was removed from the kidney after the animal had made a return to a normal functional state following the initial acute nephritis from uranium. The figure shows at *a*, a large glomerulus with capillaries engorged with blood and endothelial cells with hyperchromatic and hyperplastic nuclei. The capsule is not thickened and there is no periglomerular formation of connective tissue. Many of the convoluted tubules at *b*, show a regeneration of epithelium normal in type for this location of the tubule. In such tubules at *c*, are shown mitotic figures. In other convoluted tubules at *d*, the epithelium shows evidence of degeneration and imperfect repair.

## PLATE 35.

FIG. 3. Camera lucida drawing, Leitz, oc. 2, obj. 6. The figure is from the kidney of the same animal, control Experiment 21, Table III, after the animal had received a second injection of uranium. The figure shows at *a*, a glomerulus with an increase in connective tissue nuclei and an early thickening of the capsule. At *b*, there has occurred an early formation of intertubular connective tissue. At *c*, is shown the convoluted tubule epithelium in an advanced stage of edema, vacuolation and necrosis. The cells of the loops of Henle at *d*, appear normal. The experiment shows that a regenerated type of convoluted tubule epithelium normal for this part of the tubule has no resistance to a secondary injection of uranium. Such cells rapidly become necrotic and renal function is severely depressed.

FIG. 4. Camera lucida drawing, Leitz, oc. 2, obj. 6. The figure is from the kidney of the animal of Experiment 7, Table V. The tissue was removed from the kidney after the animal had reached its maximum degree of functional improvement from the first injection of uranium with the development of a chronic nephritis. The figure shows at *a*, convoluted tubules in which epithelial repair has taken place by the regeneration of cells normal for this location. Evidence of degenera-

tion is found in some of these areas. At *b*, is shown the dominant type of epithelial repair by the formation of an epithelial lining for the convoluted tubules by a flattened type of cell atypical for this location. At *c*, is shown a marked formation of intertubular connective tissue.

## PLATE 36.

FIG. 5. Camera lucida drawing, Leitz, oc. 2, obj. 6. The figure is also from the animal of Experiment 7, Table V, after the second injection of twice the amount of uranium used at the initial injection. The figure shows at *a*, regenerated convoluted tubule epithelium normal for this location in the process of an acute degeneration. Other cells show evidence of repair. This type of epithelium is not resistant to a second injection of uranium. At *b*, is shown the flattened, regenerated type of epithelium which is atypical for this location in the tubule. Such cells show no evidence of injury from the second injection of uranium. There was but slight evidence of any impairment of renal functions from the second injection. At *c*, is shown a diffuse formation of intertubular connective tissue.

FIG. 6. Camera lucida drawing, Leitz, oc. 2, obj. 6. The figure is also from the animal of Experiment 7, Table V. It shows at *a*, a glomerulus in an advanced stage of connective tissue formation and at *b*, and *c*, areas of periglomerular and intertubular connective tissue formation. At *d*, are shown convoluted tubules lined by the flattened type of atypical epithelium which has developed no evidence of injury from the second injection of uranium. This type of epithelial repair is responsible for the resistance which the kidney develops to a second injection of uranium. At *e*, are two small arteries showing a thickening of the middle coats.

## PLATE 37.

FIG. 7. Camera lucida drawing, Leitz, oc. 2, obj. 1/12. The figure is from two areas in the kidney of the animal of Experiment VII, Table V. At *a*, is shown a convoluted tubule in which epithelium normal in character for this portion of the tubule is in the process of regeneration. Mitotic figures are present. At *b*, these tubules are being relined by the flattened resistant type of atypical epithelium. The tubules contain casts. At *c*, is shown part of a glomerulus with fibrous tissue formation, capsular thickening and adhesions between the capillaries and the capsule. At *d*, is shown one of the smaller renal arteries with a thickened middle coat while *e*, shows the diffuse formation of intertubular connective tissue.

FIG. 8. Camera lucida drawing, Leitz, oc. 2, obj. 1/12. The figure is from the kidney of the animal of Experiment 7, Table V. It shows at *a*, a proximal convoluted tubule with epithelium edematous, vacuolated and necrotic. At *b*, are shown convoluted tubules in which the necrotic material has been removed and which have been relined by the flattened, atypical type of cell. At *c*, are shown cells of this type in stages of mitotic division.

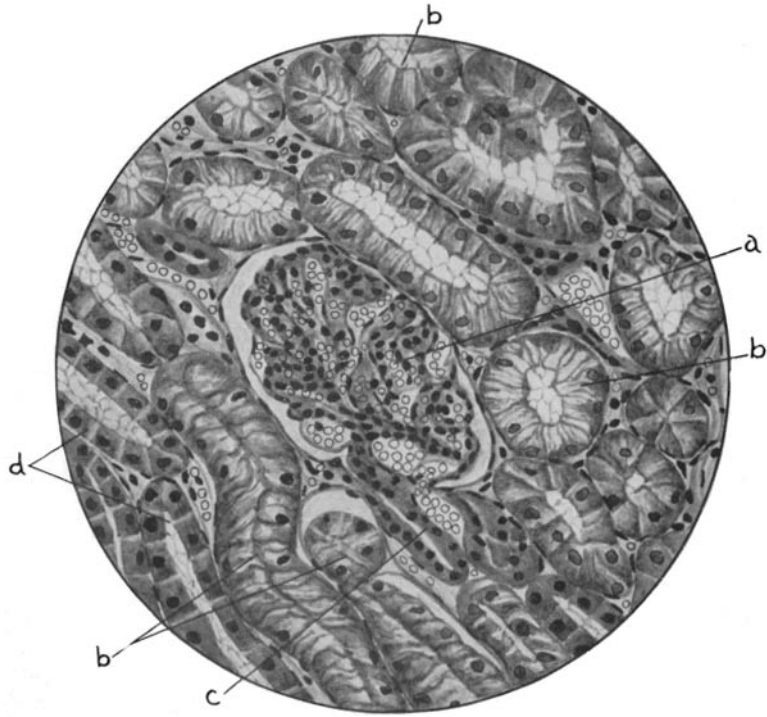

FIG. 1.

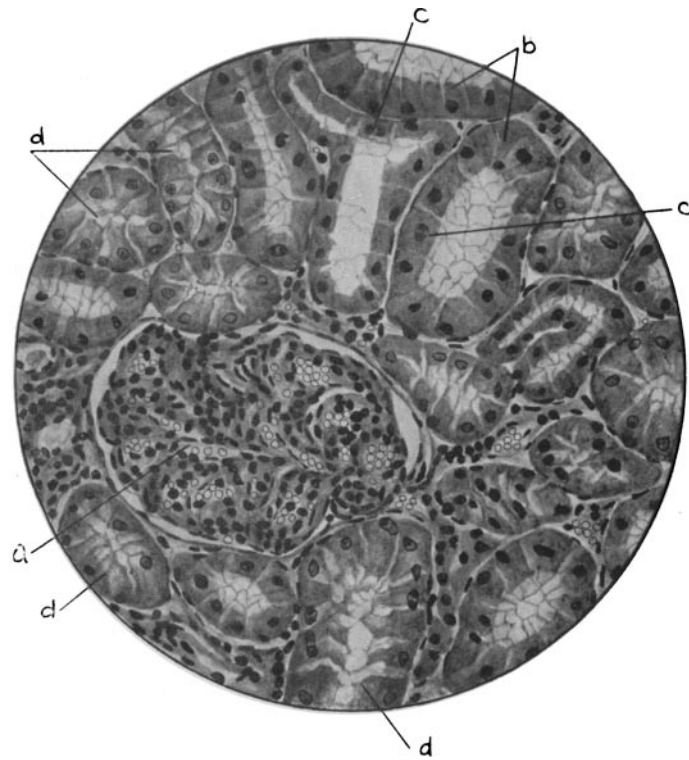


FIG. 2.

(MacNider: Kidney response to uranium nitrate.)



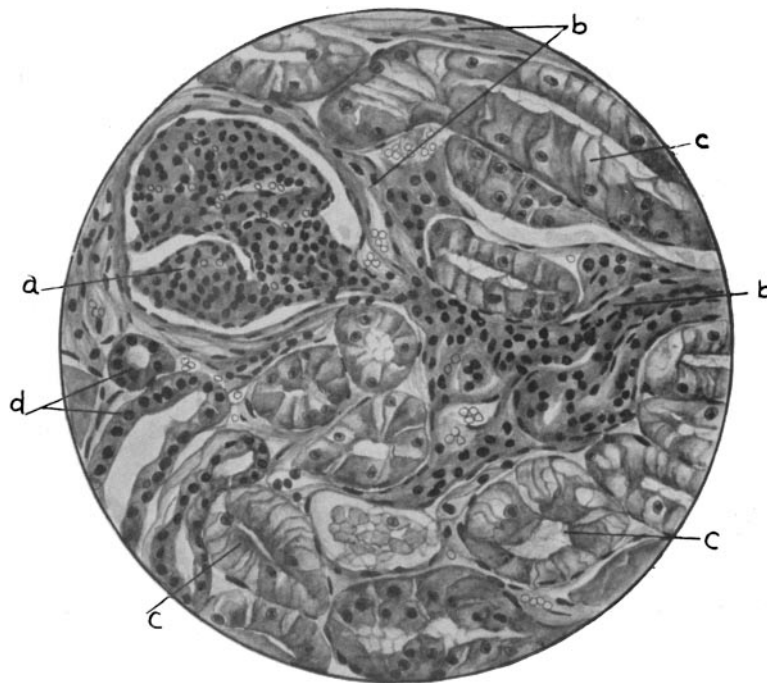

FIG. 3.

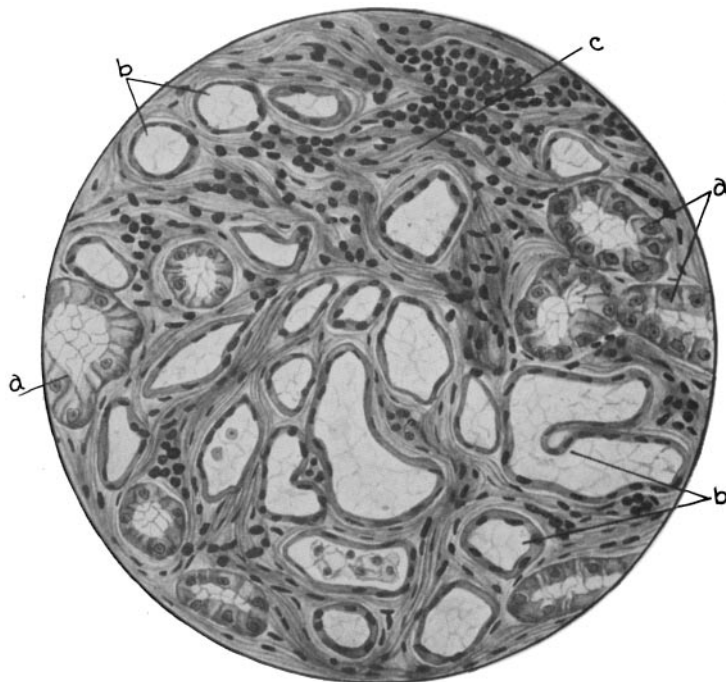

FIG. 4.

(MacNider: Kidney response to uranium nitrate.)

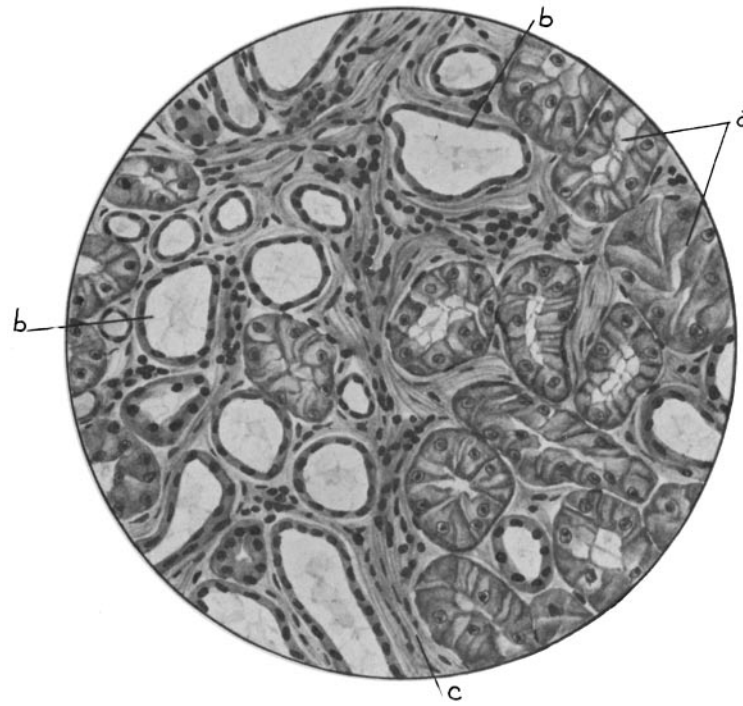


FIG. 5.

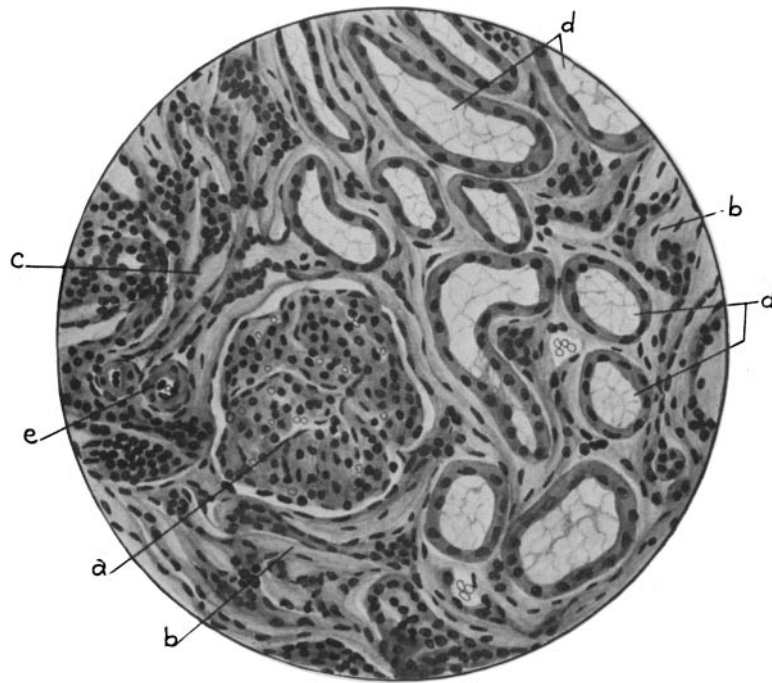

FIG. 6.

(MacNider: Kidney response to uranium nitrate.)

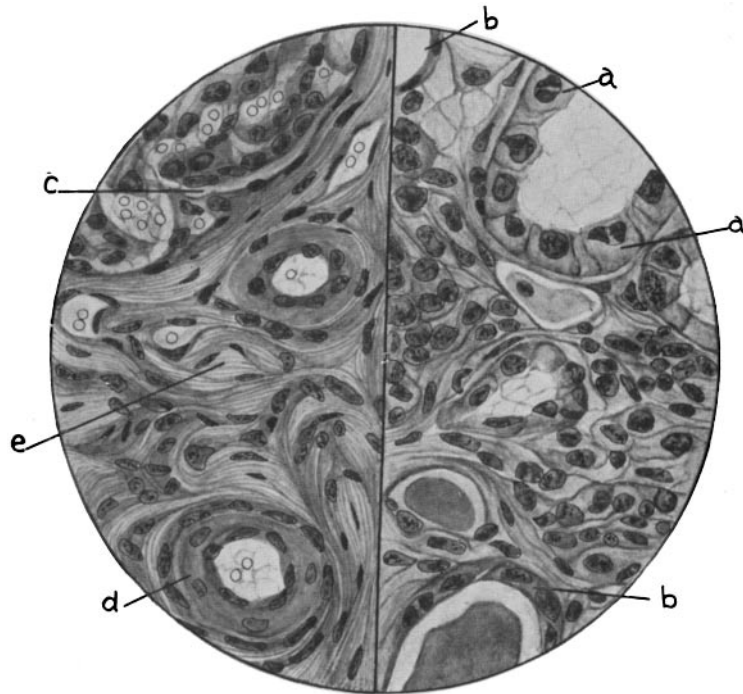


FIG. 7.

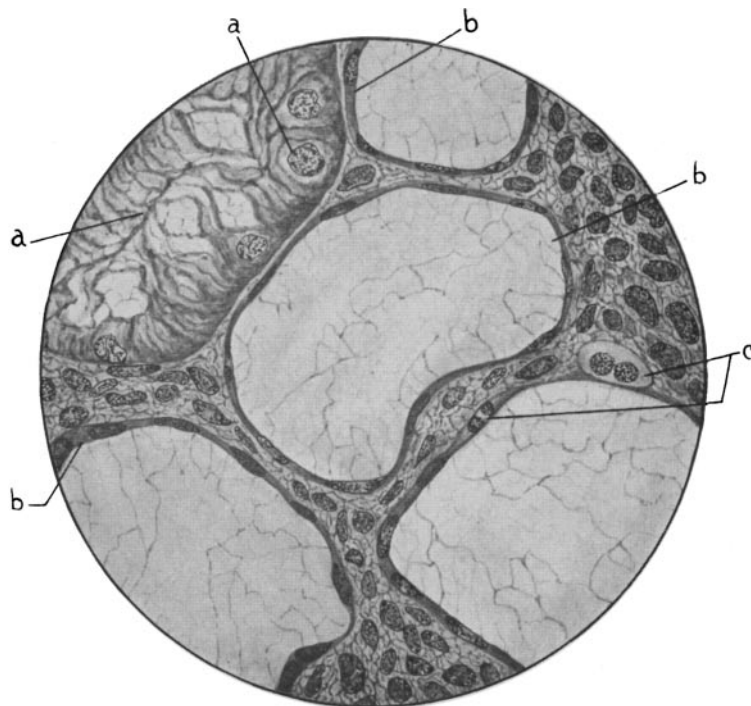


FIG. 8.

(MacNider: Kidney response to uranium nitrate.)