

TOOTH GROWTH IN EXPERIMENTAL SCURVY

BY GILBERT DALLDORF, M.D., AND CELIA ZALL

(From the Laboratory of Physiological Chemistry, Teachers College, Columbia University, the Department of Pathology, Cornell University Medical College, New York, and Grasslands Hospital Laboratory, Valhalla)

PLATES 1 TO 4

(Received for publication, March 22, 1930)

The lesions in the incisor teeth of scorbutic guinea pigs have been repeatedly studied since their recognition by Jackson and Moore (1). This paper is concerned with an associated phenomenon, namely, the rate of tooth growth in scurvy and partial scorbutic states as well as the effect of stress upon growth.

Through the work of Zilva (2), lesions of the roots of the incisor teeth of guinea pigs have been established as the first expression of a deficiency of Vitamin C. Höjer utilized this fact in testing the antiscorbutic value of foodstuffs, the minimal protective dose being the smallest amount of the antiscorbutic which would completely protect the teeth of guinea pigs throughout a 20 day period (3). As Eddy (4) has shown, the minimal protective dose by this method is much greater than by the more generally employed test (the Sherman method), which employs the weight curve of the animal fortified by certain clinical observations as pain over joints, presence of hemorrhages, etc. These and other related facts have been recently emphasized by Hanke (5), and others, and the rôle of Vitamin C in tooth development and health has become a subject of considerable interest.

Rate of Tooth Growth

We have found one reference to the influence of diet on rate of tooth growth. Orban (6) noted the rate of growth of rats' teeth when starch alone was fed and found it less rapid than when wheat, meat and greens were given. Feeding wheat and cod liver oil, the growth rate obtained approximated the rate secured with wheat, meat and greens. The addition of lemon juice did not increase this rate.

In our studies rate of growth was measured by clipping the exposed portion of one of the lower incisor teeth every fifth day. A pocket finger nail clip was

found to be the most satisfactory instrument for the purpose since it was of convenient size, preserved the whole of the fragment intact, and required no prying force, hence producing the minimum of trauma to the root of the tooth. If, after repeated clipping, the tooth became very fragile and brittle it was first cut three-fourths through with a very thin carborundum disk used on a dental engine, and then clipped. By folding the pig's ears forward and keeping the disk wet the operation does not excite the animals. The length of the fragment was measured with vernier calipers. Results have been expressed as averages in millimeters per day. The animals used in the experiment were observed for periods of varying length, the shortest being 20 days and the longest period 90 days.

Since the normal rate of tooth growth was unknown, this was first established, using animals from 4 to 10 weeks of age, and from 110 gm. to 600 gm. In the smaller animals the rate of tooth growth was slightly less rapid than in the larger, but this factor was too small to affect the result of the feeding experiments.

The basal diet used was the Sherman-La Mer (7) to which 1 per cent of cod liver oil had been added. During the period of test the animals were scored by the Sherman method for degree of scurvy and were weighed every fifth day. At the end of the experiment the animals were killed and dissected. The lower jaws, ribs and extremities were removed, fixed, and studied histologically. The incisor roots were sectioned at various levels, one section regularly being removed at the level of the first molar for comparison with Höjer's standards for the estimation of degree of scurvy.

Table 1 summarizes the results obtained by varying amounts of orange juice, tomato juice and turnip greens as the sole source of Vitamin C in combination with Sherman-La Mer basal diet. The group on green vegetables represents the maximum rate of tooth growth and the animals were free of scurvy.¹ In this group the rate of tooth growth was 0.850 mm. daily in contrast to the minimal rate in the control animals of 0.306 mm. daily. In every series the increase in Vitamin C source stimulated growth rate.

Examination of the animals on these diets revealed certain collateral data of value which can be summarized as follows:

1. Animals given basal diet plus 5 cc. of orange juice daily, showed a rate of tooth growth of 0.750 ± 0.002 mm. per day. Slight but definite scorbutic lesions were present in the incisor roots though the long bones and ribs were free of scorbutic changes. The Sherman score showed no scurvy. 5 cc. was therefore not quite adequate for complete protection. 1 cc. of orange juice produced a growth rate of

¹ Greens are notably richer in Vitamin A than fruit juices and it is possible the high maximum with greens may owe something to this factor.

TABLE 1
The Effect of Variation in Amount of Vitamin C Source on Guinea Pig Tooth Regeneration

	Vitamin source	Amount fed daily	No. animals	Days on experiment	Tooth growth mm. per day	Weight gains	Diagnosis by Sherman score	Diagnosis by Højer method
A	Controls	Basal diet only	10	20 days	0.306±.0003	-58 gm.	Acute scurvy	
B	Orange juice	1 cc.	3	20 "	0.450±.002	+40 "	Mild scurvy	0.3
	"	5 "	6	20 "	0.750±.002	+55 "	No scurvy	0.9
	"	0.5 "	3	90 "	0.350±.002	+180 "	Moderate scurvy	
	"	1 "	2	90 "	0.422±.002	+230 "	Mild scurvy	
C	"	5 "	2	90 "	0.750±.002	+255 "	No scurvy	
	Tomato juice	2 gm.	3	20 "	0.505±.003	+20 "	Moderate scurvy	0.3-0.8**
	"	4 "	3	20 "	0.580±.0006	+55 "	No scurvy	0.3
	"	8 "	3	20 "	0.623±.0006	+70 "	No scurvy	0.8
D	"	10 "	6	20 "	0.700±.0005	+68 "	No scurvy	0.8
	Turnip greens	2 "	2	20 "	0.565±.0002	+57 "	Mild scurvy	0.3
	"	4 "	2	20 "	0.640±.0002	+72 "	No scurvy	0.4
	"	6 "	2	20 "	0.735±.0002	+84 "	No scurvy	0.8
E	Mixed green vegetables*	30 "	3	20 "	0.850±.002	+75 "	No scurvy	1.0

* Mixture included spinach, lettuce and carrots.

** An indefinite type of reaction.

0.450 \pm 0.002 mm. to 0.422 \pm 0.002 mm. per day. Pronounced scurvy was found in the teeth but none in the long bones or costo-chondral junctions. The Sherman score was "mild scurvy."

Animals on 0.5 cc. of orange juice showed a rate of growth of 0.371 \pm 0.005 mm. to 0.350 \pm 0.002 mm. per day. Advanced scurvy was present in the teeth and slight changes in the ribs. The Sherman scoring was "moderate scurvy."

Similar results were secured with graded doses of tomato juice and turnip greens. The results are to be found in the table.

2. Animals given basal diet alone showed an average rate of tooth growth of 0.306 \pm 0.0003 mm. per day during the first 15 to 20 days but at the end of that period growth ceased completely. However, after complete cessation of growth, the administration of 5 cc. of orange juice daily (commencing on the twentieth day) after a period of lag of 5 days, restored practically the normal rate of tooth growth. Also, so long as the diet afforded growth factor the rate remained constant for any given diet whether the period was 20 or 90 days.

Influence of Stress on Scorbutic Lesions

In an earlier description of the changes encountered in the skeletal muscles of scorbutic guinea pigs (8), it was shown by one of the authors of this paper that exercise and stress determined largely the location and degree of the lesions. It was natural, therefore, to subject the teeth to similar tests since the anatomical lesions of scurvy probably all have this factor in common. As an amputated tooth would be subject to less stress in gnawing than its fellow of normal length, a comparison of the roots of the two teeth should be significant. For this reason in the animals of the series reported in Table 1, and in a number of others in which one incisor had been amputated, a comparison of the histological changes was made by preparing sections through both teeth just anterior to the separation of the mandibles.

The pulp of the incisors of guinea pigs is persistent, and growth, therefore, continuous throughout life. The pulp is roughly shaped like an elongated cone and covered with a surface of tall, slender and parallel odontoblasts (Fig. 2). Growth occurs through the elaboration, on the surface of this cone, of dentin, and, where exposed, enamel.

If a pig is deprived of antiscorbutic substance changes occur in the pulp. By the fifth day of complete deprivation the odontoblasts become shorter and blunter and lose their regularity of parallelism (Fig. 4). In place of dentin they form a semisolid material (Fig. 6) easily converted into dentin within a day by giving antiscorbutic substances, a phase carefully demonstrated by Wolbach and Howe (9).

If complete deprivation persists, the odontoblasts continue to regress and we have seen in the third week root pulp in which the parenchymal cells have left the dentin, developed into spindle and stellate shapes, and resembled fibroblasts (Fig. 5). Wolbach and Howe reported a similar change in the long bones. Death occurs regularly at this time and later stages have not been seen.

If the diet contains even small amounts of Vitamin C, a complete regression of odontoblasts does not occur and instead of fibroblasts the cells come to resemble osteoblasts, forming an intercellular matrix similar to bone which develops within the pulp until, in late stages, the entire cavity becomes filled with this so-called "osteodentin."

If the tooth has been clipped, the evidence of scurvy, both in amount of "osteodentin" and in the character of the cells will be less pronounced than in its fellow (Fig. 1). This has been consistently true of all the cases examined. In animals on a deficient diet for very short periods the amputated tusk may show a root of nearly normal appearance at a time when scurvy is evident in its fellow.

DISCUSSION

These findings and the evidence of the influence of stress on the lesions, indicate that the scorbutic process is characterized by an inability of certain highly differentiated cells to form the intercellular substances natural to them. In cases of partial deficiency an inferior, substitute material may be formed, less highly differentiated than dentin (bone), but when deprivation is complete the cells dedifferentiate still further and form a still more primitive tissue, namely, fibrous tissue. This is similar to what occurs in the long bones and costo-chondral junction where the osteoblasts, appearing unable to form bone matrix, become fibroblasts.

The reaction is increased by demands made on the structure and the lesion constitutes a faulty reaction to stress in the absence of a necessary material.

CONCLUSIONS

1. The incisor teeth of guinea pigs have a constant rate of growth in health.
2. Deprivation of Vitamin C causes the teeth to cease growing. Readministration of the vitamin restores the growth.
3. Administration of small amounts of antiscorbutic substance results in rates of growth roughly proportional to dosage.
4. Under standard experimental conditions used in the testing of foodstuffs for antiscorbutic value, the rate of tooth growth would appear to be a precise indication of the degree of scurvy, being more delicate than the Sherman score, and more constant as well as more simple, than the Höjer method.
5. Stress in terms of usage appears to exaggerate the scorbutic lesions in the teeth.

REFERENCES

1. Jackson, L., and Moore J. J., *J. Infec. Dis.*, 1916, **19**, 511.
2. Zilva, S., *Proc. Roy. Soc. Med.*, London, 1919, B **90**, 505.
3. Höjer, A., *Brit. J. Expt. Path.*, 1926, **7**, 356.
4. Eddy, W. H., *Am. J. of Pub. Health*, 1930, **19**, 1309.
5. Hanke, M. T., *Inter. Physiol. Congress*, 1929, **13**, 10.
6. Orban, J., *J. Am. Den. Ass.*, 1927, **14**, 1619.
7. Sherman, H. C., La Mer, V. K., and Campbell, H. L., *J. Am. Chem. Soc.*, 1922, **44**, 165.
8. Dalldorf, G., *J. Expt. Med.*, 1929, **50**, 293.
9. Wolbach S. B., and Howe, P. R., *Arch. Path. and Lab. Med.*, 1926, **1**, 1.

EXPLANATION OF PLATES

PLATE 1

FIG. 1. Low power microphotograph of incisor teeth showing differences in structure between amputated (A) and natural (N) teeth in scurvy. The line of odontoblasts (O) is heavier and is formed of longer, more parallel cells in the amputated tooth and the imperfect dentin (N) is narrower.

The difference in breadth of the original dentin is due to the more rapid growth of the amputated tooth and is not related to the scorbutic process.

PLATE 2

FIG. 2. Highly magnified odontoblast line in normal guinea pig tooth. The odontoblasts are slender, parallel and long. The dentin canals are clearly shown.

FIG. 3. Same magnification as Fig. 2. The animal had been given basal diet

plus 3 cc. orange juice daily for 20 days. The cells are shorter and less regular. Near four o'clock an island of imperfect dentin is being formed within the pulp itself by migrated odontoblasts.

PLATE 3

Magnifications same as in Figs. 2 and 3.

FIG. 4. Line of odontoblasts after 5 days on a diet completely deficient in antiscorbutic substance.

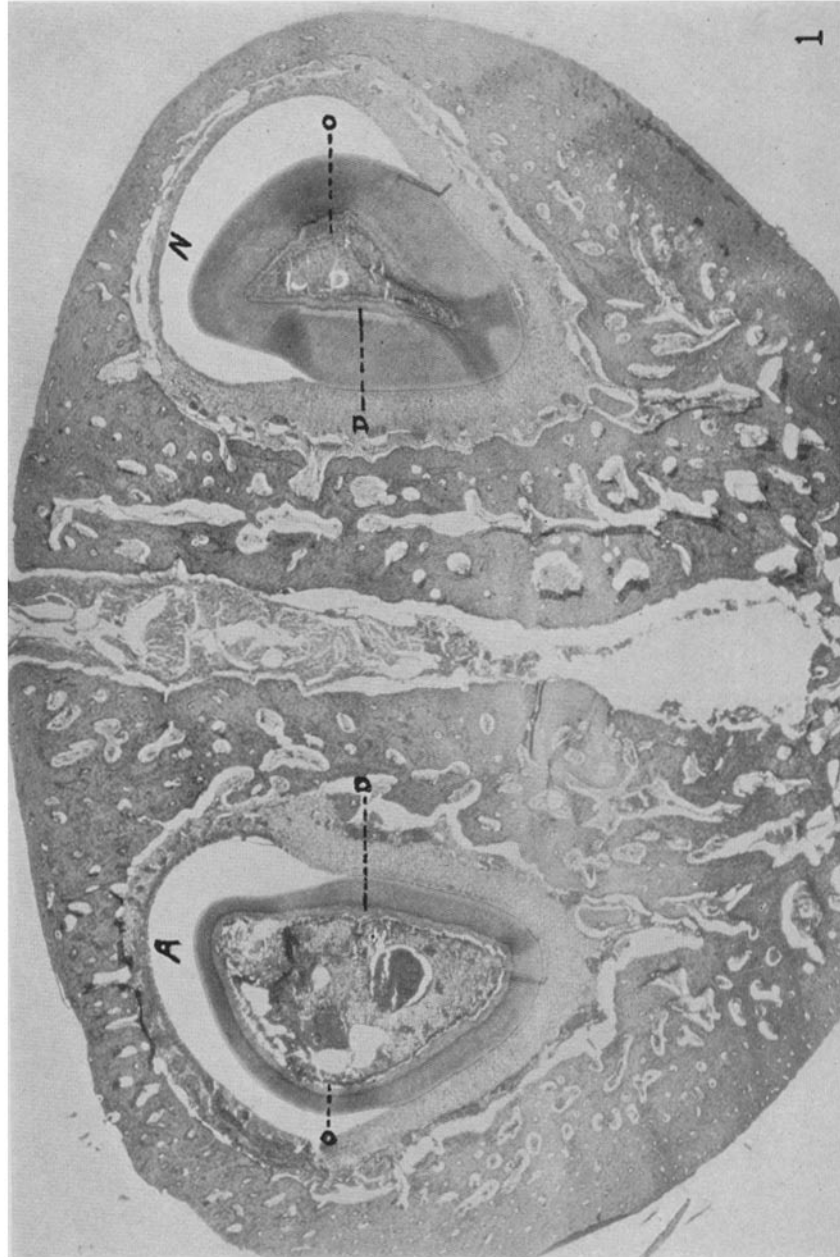
FIG. 5. In this animal, which had been for 21 days without antiscorbutic substance the odontoblasts have lost their natural appearance and resemble fibroblasts.

PLATE 4

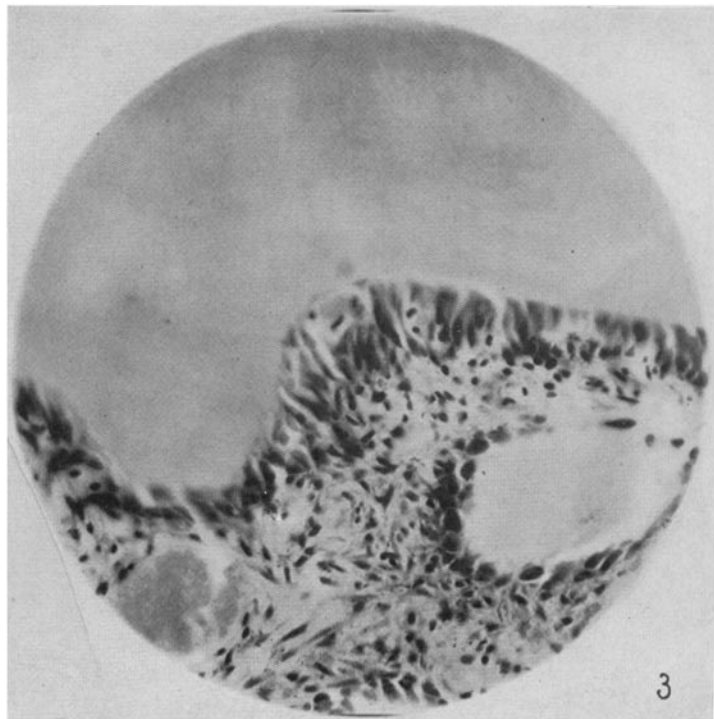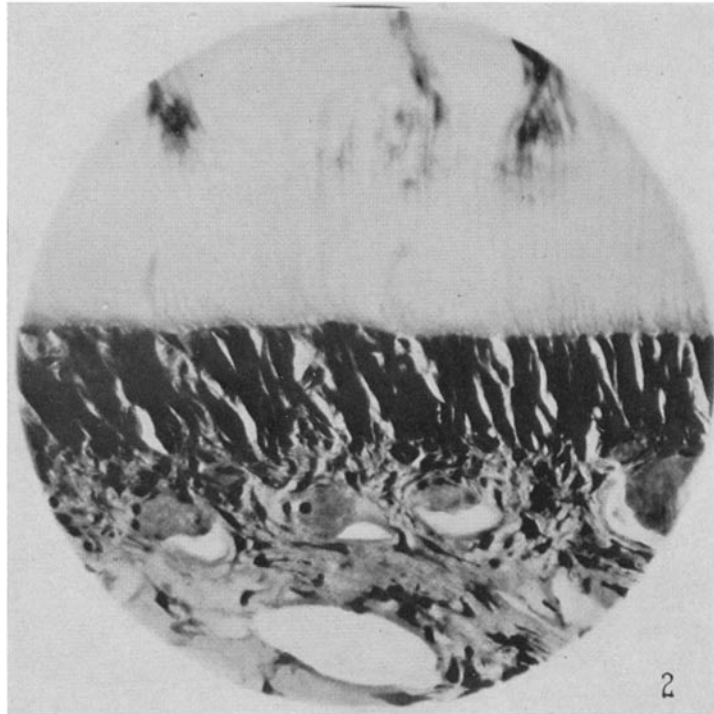
Magnifications same as in Figs. 2 to 5.

FIG. 6. Illustration of recovery of function by odontoblasts. The animal had been on a Vitamin C-free diet for 10 days and was then given orange juice for 5 days. The cells have become more orderly and a zone of fresh pre-dentin has been formed.

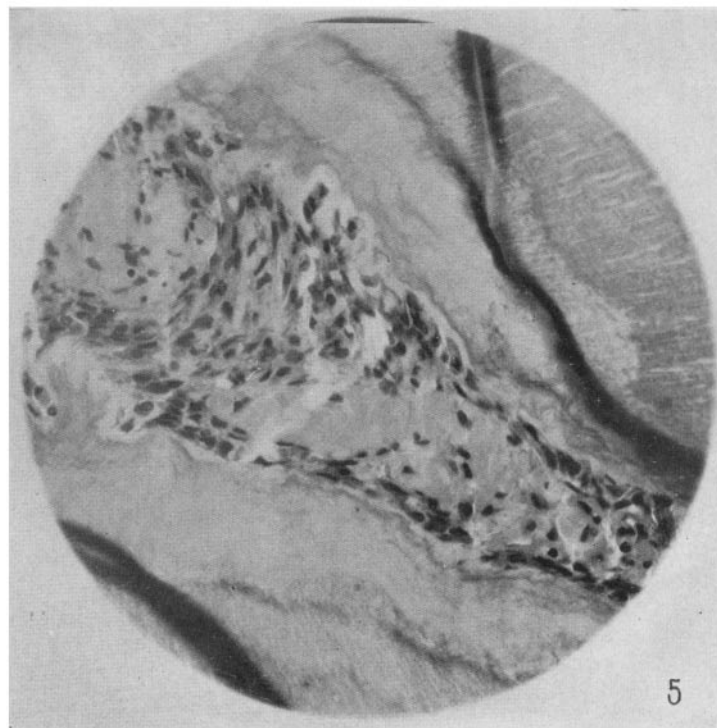
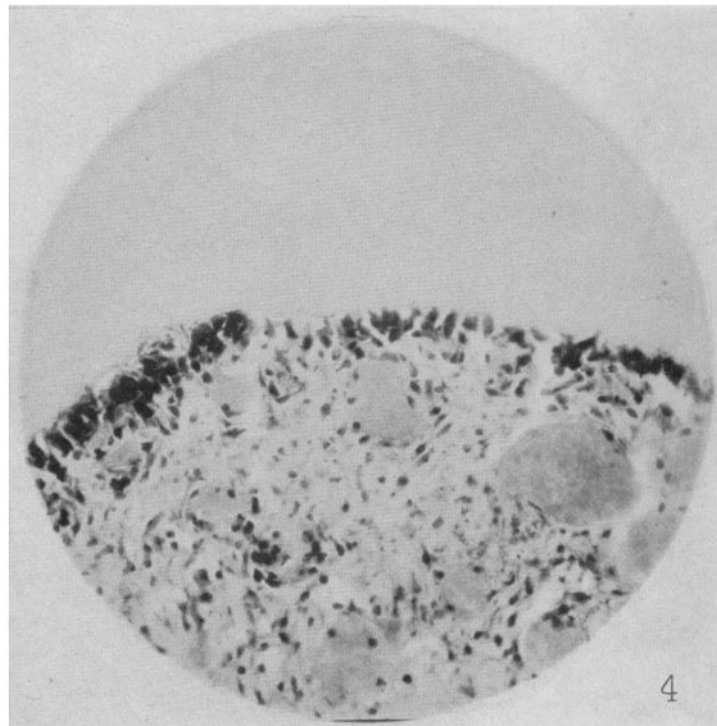
FIG. 7. An animal on basal diet alone for 20 days. The odontoblasts seem to have disappeared.



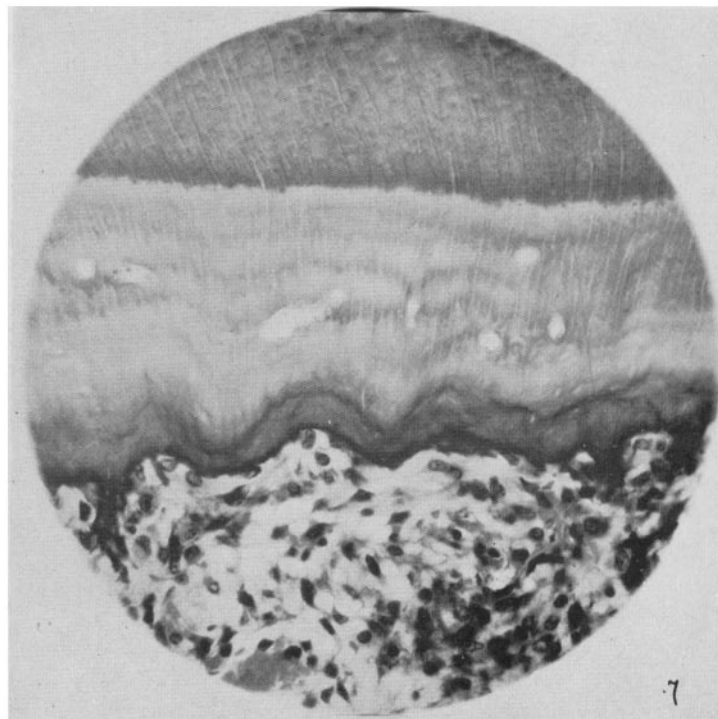
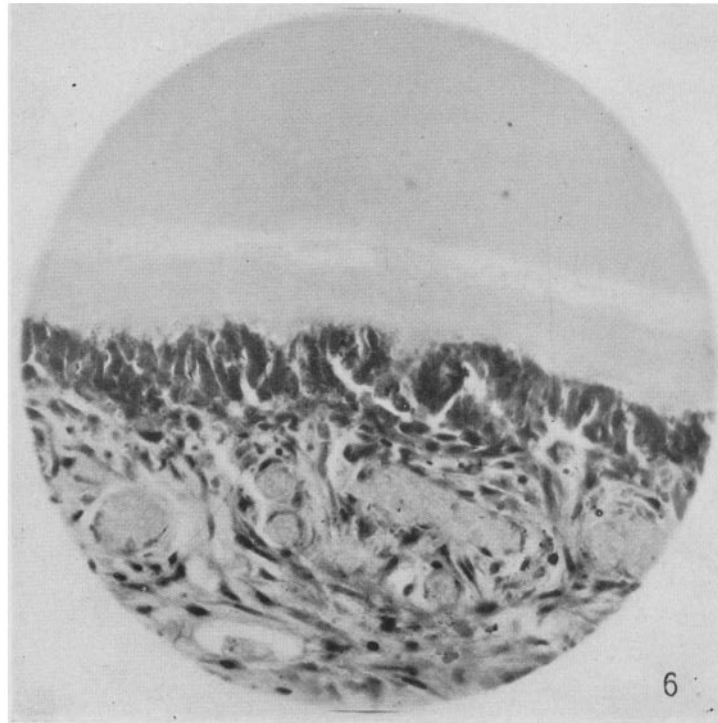
(Dalldorf and Zall: Tooth growth in experimental scurvy)



(Dalldorf and Zall: Tooth growth in experimental scurvy)



(Dalldorf and Zall: Tooth growth in experimental scurvy)



(Dalldorf and Zall: Tooth growth in experimental scurvy)