

## A TRANSMISSIBLE TUMOR-LIKE CONDITION IN RABBITS

By RICHARD E. SHOPE, M.D.

(From the Department of Animal and Plant Pathology of The Rockefeller Institute for Medical Research, Princeton, N. J.)

PLATES 37 TO 40

(Received for publication, June 29, 1932)

This paper deals with a tumor-like condition in a wild cottontail rabbit (genus *Sylvilagus*) and its experimental transmission to domestic rabbits (genus *Oryctolagus*). The term "tumor" is used in its broadest sense to indicate a local swelling consisting of a mass of new tissue.

### *Description of the Original Material*

Three prominent subcutaneous tumors were observed in a wild cottontail rabbit shot in Nov., 1931. The animal was taken immediately to the laboratory and autopsied. Two of the tumors, on the inner and upper aspect of the left hind foot, were egg-shaped and approximately 1.5 x 2 cm. in diameter. The other, which was somewhat larger, was on the left fore leg just below the shoulder. There were no overlying surface abrasions and, although the tumors seemed to be firmly attached to the skin, they were freely movable over the underlying solid skeletal structures.

On section each of the tumors was found to be white, firm, moist, and free from evident necrotic areas. They cut as though fibrous, the cut surface bulged, and the general appearance was that of a fibroma. There was nothing of significance found in the remainder of the autopsy. The condition of the animal appeared good, it was not in the least emaciated, and there were no evidences of metastases in the regional lymph nodes or the organs.

Pieces of each of the tumors were removed aseptically to use in inoculating laboratory rabbits and the remainder was stored in 50 per cent glycerol or put in fixative for histological study.

Histologically the three tumors seemed to be identical.

The main mass was composed of connective tissue cells; many of these resembled fibroblasts and were spindle or polygonal in shape with abundant cytoplasm and large round or oval nuclei. Most of the cells, however, were of the small thin connective tissue type with scant cytoplasm and thin spindle-shaped nuclei (Fig. 1). Mitotic figures were scarce. The arrangement of the cells was rather compact and irregular; in general the long axes were perpendicular to the base of the tumor.

Intercellular fibrils were quite abundant and largely collagenous in character. The blood supply was good and consisted of small vessels whose walls were usually of only endothelium thickness. Some of these vessels were densely cuffed by lymphocytes and plasma cells. Inflammatory cells were not numerous in the tumor substance and consisted largely of eosinophiles and lymphocytes. The base of the tumor, however, was composed of a mass of lymphocytes so densely packed that it almost resembled lymphoid tissue.

The thickened epithelium overlying the tumor presented a histological picture strikingly similar to that seen in *molluscum contagiosum* in man. Great bulbous masses of epithelial cells projected down from the epidermis into the substance of the tumor (Fig. 1). Many of the cells of both the overlying epidermis and the bulbous downward projections were greatly enlarged, the nuclei were pale and vesicular and the cytoplasm was vacuolated and distended by a granular eosinophilic mass in which frequently lay a more definite, discrete, round, eosinophilic inclusion. Such vacuolated and inclusion-containing cells were numerous.

The histological picture of these wild rabbit tumors resembled that of a spindle cell fibroma; it was atypical, however, in that the bases were densely infiltrated with lymphocytes, there was a perivascular round cell cuffing of some of the nutrient blood vessels, and the overlying epidermis showed a peculiar type of hyperplasia and degeneration.

#### *Experimental Transmission*

No difficulty was encountered in transmitting the condition to domestic rabbits by pushing small bits of the original wild rabbit tumors under the skin with a trocar. However, the tumor could only be maintained in serial passage through domestic rabbits when young, actively growing tumors were used as a source of material for transfer and when, on the basis of the experience of Brown and Pearce (1), the testicle was used as the site for inoculation. It was found not only that tumors developed more readily there than in the subcutaneous tissue, but also that such tumors provided a better source of infectious material for maintaining the condition in serial passage.

The tumor-like condition has been transmitted, thus far, only to laboratory and wild cottontail rabbits. Guinea pigs, white rats, white mice, and chickens have resisted infection by the methods used.

#### *Methods*

The clinical picture exhibited by rabbits in which the tumor has been experimentally produced became constant only after the third

serial passage when a satisfactory technique, as described below, had been developed.

As a source of infectious material, tumor-bearing testicle was used alone or mixed with subcutaneous tumor. These tissues were minced finely with scissors, then ground with sterile sand, and finally combined with physiological saline to make an approximately 5 per cent suspension. After this suspension had been allowed to stand undisturbed for 5 to 10 minutes, the supernatant fluid was decanted and used in making inoculations. While the etiological agent persists in the tumors for relatively long periods of time, the most satisfactory results were obtained by using 6 to 9 day old tumors in preparing the suspensions.

This suspension was introduced subcutaneously in dosages of 1 to 2 cc., or intratesticularly in dosages of 0.2 to 1 cc. Usually only one testicle was inoculated, leaving the other for comparison.

#### *Routes of Infection*

When a fully infectious suspension was employed, local tumor formation regularly resulted from inoculation into one or both testicles or subcutaneously in any portion of the body.

When introduced intramuscularly the tumor-inducing agent gave positive results in only about one-third of the cases. These variable results were probably dependent upon whether the injection lodged directly in a muscle bundle or in connective tissue fasciae between muscle bundles. In the former case no tumor was formed while in the latter a large fibrous tumor infiltrating the surrounding muscle resulted.

When an infectious suspension was injected intracutaneously or was rubbed on the scarified skin the results were not constant; usually on the 4th day the epidermis became thickened, elevated, and hyperemic, and minute vesicle formation sometimes occurred. Slight thickening of the underlying subcutaneous tissue was seen in some cases. The condition disappeared after 3 or 4 days, usually leaving a thin, loosely adherent scab.

Inoculation intravenously, even when rather coarse suspensions and large dosages were employed, was without effect, except for the regular formation of a small nodule in the subcutaneous tissue of the ear at the point where the needle was inserted. Likewise, inoculation intraperitoneally with large dosages of demonstrably infectious material resulted in no evidence of tumor formation in the peritoneum or

elsewhere. Intracerebral inoculation has been negative in the few animals used.

Evidence that the condition is not contagious is offered by the fact that normal rabbits placed in the same pens with tumor-bearing rabbits remained free of tumor and were subsequently, after prolonged contact, still susceptible to infection by inoculation. Furthermore, a doe bred to a buck carrying a large tumor in one testicle developed no tumor and gave birth to a normal litter.

Evidences of a generalized disturbance as indicated by loss of appetite or fever were absent. Rabbits bearing large tumors sometimes showed a slight loss in weight which was promptly regained as the tumors regressed. Most of the animals were killed while still carrying large tumors, but among the 30 whose tumors were allowed to regress there was no evidence of illness at any time and no deaths.

#### *Clinical Picture and Pathology of Experimental Disease*

*Subcutaneous Inoculation.*—In a rabbit inoculated subcutaneously the tissue in the region of inoculation was definitely thickened by the 3rd to the 5th day. The following day the thickening was more marked and its borders were more sharply circumscribed so that it began taking on the gross appearance of a tumor. From this point on to the 10th or 12th day after inoculation, increase in size was progressive and rapid. Early in its growth the tumor felt soft and rubbery and small firmer nodules could be palpated in its substance. As it increased in size, it became more solid and developed into a very firm, well circumscribed, usually lobulated tumor with a tense, sometimes glistening, overlying epithelium (Fig. 2). Usually it was freely movable over the underlying skeletal structures and seemed well encapsulated. The eventual size of the tumor varied somewhat depending apparently on such factors as size of dose administered, amount of the inciting agent present in the infectious suspension, age of the tumor used in preparing the suspension, and factors relating to the inoculated rabbit itself. However, a tumor 4 x 6 cm. and 1.5 to 2 cm. in thickness was average. The tumor developed by deepening and filling up the original area of subcutaneous thickening with very little increase in the lateral diameters. When more than one subcutaneous site in a rabbit was inoculated simultaneously, each area developed a tumor which seemed to be uninfluenced by the presence of the others.

Examined when at its maximum size on from the 10th to the 12th day after inoculation, the cut surface of a subcutaneous tumor was white or pinkish white and bulged slightly (Fig. 3). It was moist but not edematous. Pieces of tumor were difficult to grasp with forceps because of their firm rubbery consistency. On section some tumors exhibited two distinct layers of approximately the same thickness held together by a thin layer of rather loose areolar tissue. The upper

layer was continuous with the overlying epidermis while the lower was movable both over the underlying muscle and in relation to the upper layer of the tumor. Sometimes pea-sized or larger nodules of the same firm consistency were a part of these layers of new tissue. Other subcutaneous tumors failed to exhibit a two-layer appearance on cut section and instead were composed of one solid mass of glistening white tissue or groups of closely packed nodules of the same general appearance.

After reaching a maximum size on the 10th to the 12th day, the course of a subcutaneous tumor was variable. Occasionally it persisted with no apparent change in size or consistency for periods ranging from 10 to 15 days, but usually, after 2 or 3 days, a rapid regression took place. If the tumor had reached a size great enough to cause an ischemia of the overlying epithelium with consequent gangrene, regression was more rapid and accomplished partly by sloughing of the gangrenous epithelium and its underlying tumor tissue. All subcutaneous tumors observed in laboratory rabbits have eventually completely regressed when the animals have been permitted to live long enough; in most cases regression has been complete within 35 days after inoculation.

Histologically a 10 day subcutaneous tumor was found to be composed largely of connective tissue cells. These were spindle or polygonal in shape and resembled fibroblasts rather than connective tissue cells. While they were variable in size, most of them were rather large. Their nuclei were round or oval, usually containing clumps of deeply staining chromatin and they possessed an unusual amount of cytoplasm. Mitotic figures were present but not numerous. Occasionally groups of as many as five or six cells whose protoplasm appeared to be continuous were encountered. Intercellular fibrils were abundant and largely collagenous in character. Although the arrangement of the cells was usually loose, some degree of stratification was to be observed. In the lowest layer the long axes of the cells tended to be perpendicular to the base of the tumor and parallel with the nutrient blood vessels. In the layer above, the cells were much more compactly arranged with their long axes generally horizontal. This dense layer was sometimes divided in two by a narrow strip of loose areolar tissue. The upper layer was loosely filled and less definitely arranged than the lowest. In all layers the arrangement was broken by areas of cells which formed whorl-like or otherwise irregular patterns. Scattered among the cells composing the mass of the tumor were small numbers of wandering cells, largely eosinophiles and lymphocytes. At the extreme base of the tumor the lymphocytic infiltration was sometimes marked while just beneath the overlying epithelium were large numbers of eosinophilic and neutrophilic leucocytes. The epithelium did not show the peculiar degenerative changes seen in the original tumor. It was, however, frequently edematous and sometimes showed vesicle formation. The blood supply to the tumor was good and composed largely of small vessels whose walls were usually of only endothelium thickness. In some sections fibroblasts were arranged loosely about blood vessels in such a way as to suggest that they originated from cells in the vascular wall.

In tumors younger than that just described the fibroblastic structure was more loose, the arrangement of the cells more irregular, and mitotic figures were more numerous. In older tumors that were regressing, there was a general, quite marked lymphocytic and leucocytic infiltration, the connective tissue cells stained more faintly and tended to shorten and become round, and the nutrient blood vessels, in many instances, were tightly cuffed with round cells. Small areas of necrosis were also to be seen.

When intramuscular inoculation was successful, large fibrous new growths similar in gross and histological appearance to subcutaneous tumors developed at the site of inoculation, infiltrating the surrounding muscle (Fig. 4).

*Intratesticular Inoculation.*—Rabbits inoculated intratesticularly with a tumor-producing suspension, like those inoculated subcutaneously, showed the first effect on the 3rd to the 5th day. At this time the inoculated testicle was slightly larger and more firm than the normal one, and it continued to increase progressively and rapidly in size and to become more firm. In contrast to the subcutaneous tumor, the testicular tumor continued its growth after the 10th day, not reaching its maximum size until about 20 days after inoculation. Growth became slower, however, after the 10th day. By the 15th to the 20th day, the inoculated testicle seemed to be from 3 to 5 times as large as the uninoculated one when palpated through the scrotum. It was firm, almost hard; and often definite, hard, shotty, projecting nodules could be felt, especially at the upper pole in the region of the epididymis. The scrotum and tunic usually were thickened and edematous and sometimes hard pea-sized, round nodules could be palpated. Not infrequently the inoculated testicle ascended into the abdomen soon after it began its rapid increase in size and remained there.

The typical testicular tumor, 15 to 20 days after inoculation, was found at autopsy to be irregularly lobular in form and 7 to 8 cm. in length and 2 to 3 cm. in its greatest diameter. If it had remained in the scrotum, the tunic, testicle, and scrotum were usually loosely adherent to one another. There were small hard white nodular tumors in the overlying tunic and in the scrotum in addition to the extensive involvement of the testicle. The latter, when removed from the tunic, was found to be mottled purplish white in color, coarsely lobulated, and firm to the touch. The region of the epididymis and cord and almost the entire testicle were composed of what appeared in the gross to be tumor tissue (Fig. 5).

The cut surface of a testicular tumor was similar in appearance to that of a subcutaneous tumor, already described, except that it contained more areas of coagulation necrosis or hemorrhage (Fig. 5). It was white or pinkish white, of a firm rubbery consistency, and appeared to be composed of closely packed and more or less continuous lobulated nodules of varying sizes.

The testicular tumor persisted at its maximum size longer than did the subcutaneous tumor. Large hard nodular testicular tumors were still present 40 days after inoculation, and rabbits autopsied even 2 months after inoculation usually exhibited hard nodular tumors of various sizes on atrophic testicles or in the tunics. Regression, however, could finally be complete, although it was usually accom-

panied by atrophy or marked fibrosis of the involved testicle. Regression was more rapid in cases in which, because of edema or the unusually large size of the tumor, an ischemia of a portion of the overlying scrotum had resulted in a dry gangrene.

Histologically the general types of cells found in testicular tumors were those already described for the subcutaneous tumor. Their arrangement, however, was much more compact and irregular. They formed wide whorls between the seminal tubules, which in most cases had undergone a coagulation necrosis (Fig. 6). In other places they formed more loosely arranged nodules in which were fibroblasts of all sizes and shapes (Fig. 7). Mitotic figures and multinucleated cell masses were more numerous than in the subcutaneous tumors (Fig. 8). Especially to be noted were the masses of young connective tissue cells radiating from blood vessels and forming nodules about them (Fig. 9). Although the blood supply to the testicular tumors was good, it was difficult to find sections without focal areas of necrosis which involved tumor tissue as well as normal structures. This focal necrosis was seen much less frequently in tumors involving only the epididymis and cord. As in subcutaneous tumors, intercellular fibrils, largely collagenous in character, were fairly abundant, small numbers of lymphocytes and eosinophiles were seen, and, near large areas of necrosis, many leucocytes. It cannot be stated definitely whether or not the interstitial cells of Leydig entered into the tumor formation.

The nodular tumors of the tunic presented a peculiar histological picture. In contrast to their firmness on palpation their cells were of extremely loose and irregular arrangement. They were composed largely of fibroblastic cells of moderately compact arrangement at the margins but very loose and widespread in the center. The margins were also frequently densely infiltrated with lymphocytes.

In testicular tumors younger than those just described the fibroblastic invasion of the intertubular spaces was not so extreme, the cells were more irregular and less compact in their arrangement, and more mitotic figures were present. In the gross, testicles bearing younger tumors were purplish red in color, swollen, injected, more edematous and less nodular and less lobulated than those in which the tumor had reached its maximum size. In regressing testicular tumors as in regressing subcutaneous tumors, there was a generalized and extreme lymphocytic infiltration, the connective tissue cells stained more faintly and tended to become rounded, and the nutrient blood vessels were tightly cuffed by lymphocytes.

The possibility that the fibroblastic reaction might be secondary to a preliminary necrosis caused by some agent in the infectious suspensions was eliminated by study of tumors in all stages of development. The first recognizable alteration was hyperplasia of connective tissue and it was never preceded by necrosis. Necrosis, when it did occur, came after the first fibroblastic reaction and appeared to be the result of pressure due to the encroachment of rapidly growing connective

tissue. It was thus the result and not the cause of the fibroblastic proliferation.

Metastases in the neighboring lymph nodes or elsewhere in the body have not been observed in animals inoculated by any route. Occasionally there was an enlargement of the regional lymph nodes draining the area of tumor. Histological preparations of such lymph nodes showed no increased number of connective tissue cells but did show many cells which appeared to be endothelial leucocytes.

#### *Experimental Infection of the Wild Cottontail Rabbit*

It has been possible to infect wild cottontail rabbits with the tumor-producing agent that had been passed through a series of laboratory rabbits. The resulting tumors differed in a number of respects, however, from those produced experimentally in laboratory rabbits. One experiment, typical of three that have been conducted, will be outlined here to indicate the differing reactions of wild and domestic rabbits to the tumor-producing agent.

Both a wild rabbit and a laboratory rabbit as control were inoculated subcutaneously with 1 cc. of infectious tumor suspension from a laboratory rabbit of the eighth serial passage. By the 6th day the control had a firm swelling at the site of inoculation measuring 4 x 7 x 1.5 cm. while the wild rabbit had only a pea-sized nodule. On the 10th day the control's tumor reached its greatest size, measuring 5.5 x 8 x 2.5 cm., whereas the nodule on the wild rabbit showed only a slight increase in size. The tumor in the control rabbit regressed more slowly than normally and by the 17th day still measured 6 x 5 x 2.5 cm. and was very firm. The tumor in the wild rabbit at this time was 6 x 4.5 x 1.5 cm. in size, and it reached its maximum size, 7 x 5 x 2 cm., on the 39th day. By this time the control rabbit's tumor had almost completely regressed. On the 77th day after inoculation the wild rabbit was still carrying intact a subcutaneous tumor measuring 6 x 4 x 1.5 cm. Autopsy at this time revealed a tumor identical in gross and histological appearance with those of the original wild rabbit, even to the molluscum contagiosum-like changes in the overlying epidermis. There were no metastases and the animal had shown no general symptoms during the period it was under observation.

#### DISCUSSION

The tumors of the original wild rabbit had the general gross and histological appearance of a benign fibroma but were atypical microscopically in that some of the nutrient blood vessels were cuffed with round cells, there was a heavy lymphocytic infiltration of the bases of the tumors, and the overlying epidermis showed degenerative changes



similar to those seen in molluscum contagiosum. Testicular or subcutaneous tumors produced experimentally in laboratory rabbits exhibited a histological picture that was even more suggestive of fibroma, as distinct from granuloma, than was that of the original tumors. In experimentally produced tumors in laboratory rabbits the peculiar degenerative changes seen in the epidermis overlying the tumors in the original wild rabbit did not appear. However, a wild rabbit infected with the tumor-producing agent after eight serial passages through laboratory rabbits exhibited this histological peculiarity. This fact seems to indicate that the difference in the pathological pictures seen in wild and domestic rabbits, as regards the epithelial cells, was one of species difference in reaction to the etiological agent.

Clinically the only manifestation of disease in experimentally infected rabbits was the appearance of tumors at the site of inoculation. There were no general evidences of illness and none died.

The sites of infection were limited to the testicles and subcutaneous tissue. Inoculation of animals intramuscularly or intracutaneously did not regularly lead to local positive evidence of infection. The disease was not contagious, and administration of the tumor-producing agent intraperitoneally, intravenously, or intracerebrally was without apparent effect. It is believed that the inciting agent is effective only when brought into close contact with connective tissue cells, and that it acts upon them directly, causing the formation of a fibroma-like tumor at the site of inoculation.

#### SUMMARY

A tumor-like condition has been observed in a wild cottontail rabbit and has been found to be transmissible to both wild and domestic rabbits but not to guinea pigs, white rats, white mice, or chickens. The clinical picture of the experimentally produced condition and the pathological picture of the original and experimentally produced tumors have been described. The tumor has the general appearance of a fibroma. Methods used in transmitting the condition and satisfactory routes of inoculation have been described and discussed.

#### REFERENCE

1. Brown, W. H., and Pearce, L., *J. Exp. Med.*, 1923, **37**, 799, 811.

## EXPLANATION OF PLATES

## PLATE 37

FIG. 1. Section of original wild rabbit tumor. The bulbous projections of epidermis are composed of large vacuolated and inclusion-containing epithelial cells. The main mass of the tumor is made up of spindle and polygonal shaped connective tissue cells. Giemsa.  $\times 100$ .

FIG. 2. Subcutaneous tumor on abdomen 11 days after inoculation. The lobular form and sharply demarcated margins of the tumor are characteristic. Dimensions of tumor 5 x 6 x 2.5 cm.

## PLATE 38

FIG. 3. Cut surface of subcutaneous tumor on abdomen 11 days after inoculation. The tumor is composed of closely packed nodules of glistening white tissue and has the general appearance of a fibroma. Dimensions of tumor 4 x 4.5 x 2 cm.

FIG. 4. Section of tumor in muscle of the thigh showing young proliferating connective tissue invading spaces between muscle bundles. 11 days after inoculation. Phloxine-methylene blue.  $\times 79$ .

FIG. 5. Intact (on left) and section (on right) of two testicular tumors with a normal rabbit testicle for comparison. The upper testicular tumor was removed 18 days, the lower 16 days after inoculation. In the upper specimen the entire testicle is uniformly replaced by tumor tissue, while in the lower specimen the tumor is limited largely to the region of the epididymis and shows a large area of hemorrhage. Kaiserling-fixed specimens.

## PLATE 39

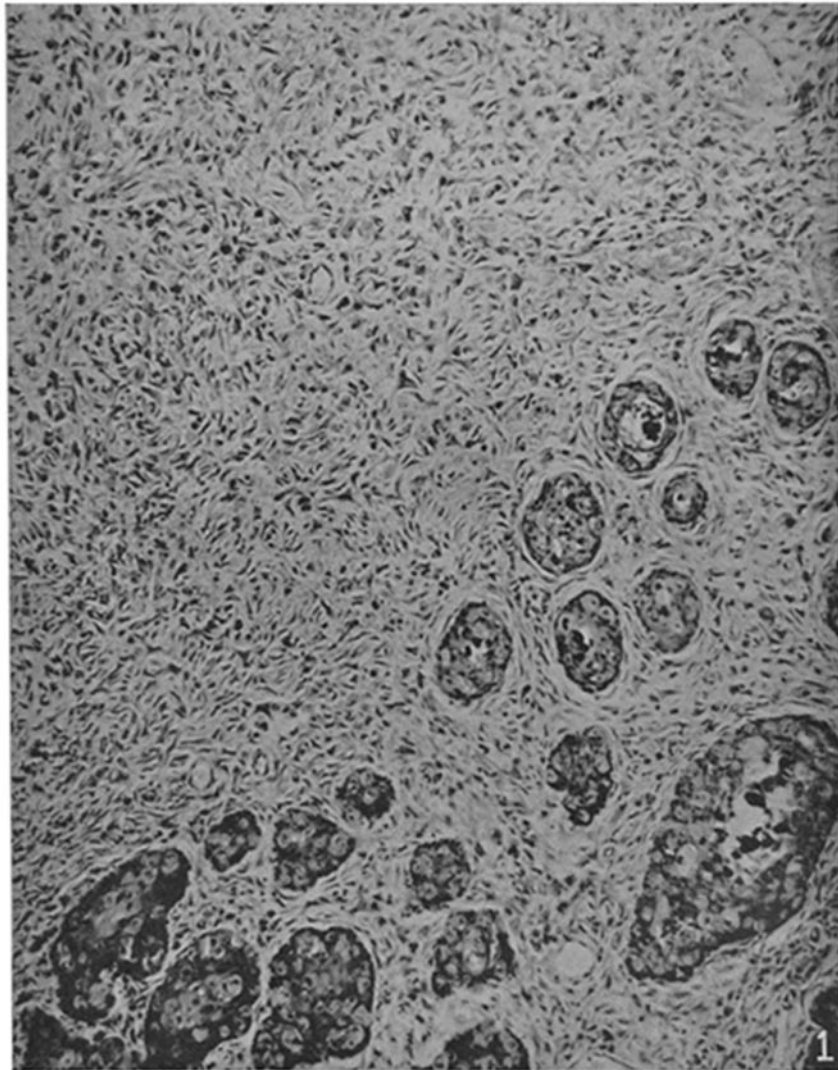
FIG. 6. Section of testicular tumor showing wide strands of young proliferating connective tissue between degenerating seminiferous tubules. 11 days after inoculation. Giemsa.  $\times 94$ .

FIG. 7. Section of testicular tumor from region of the epididymis showing the general cellular arrangement of an actively growing tumor. The cells are of the young connective tissue type. 11 days after inoculation. Giemsa.  $\times 70$ .

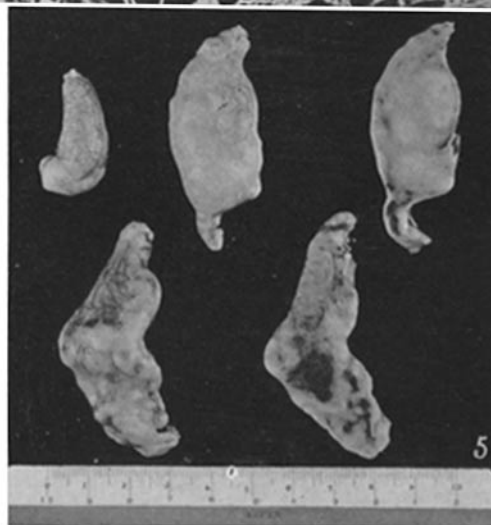
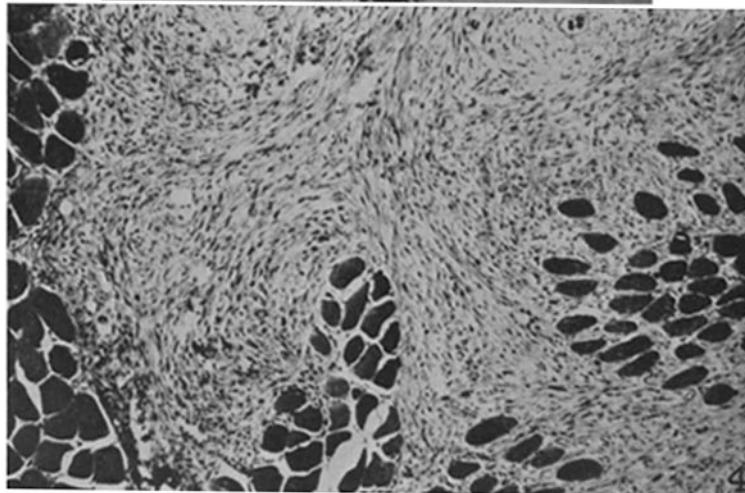
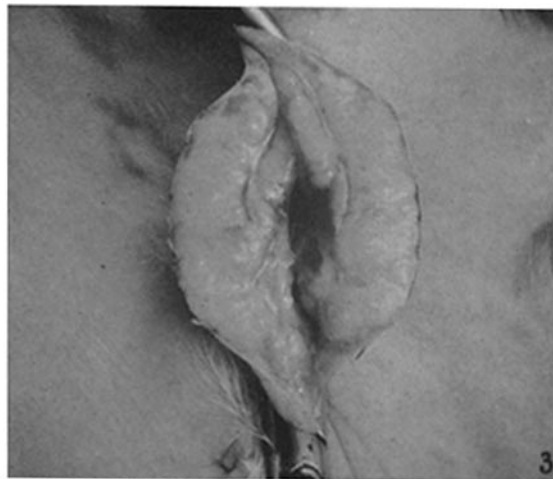## PLATE 40

FIG. 8. Section of testicular tumor showing general appearance of the cells comprising the tumor. Mitotic figures and groups of cells whose protoplasm is apparently continuous can be seen. In the lower left hand portion of the figure is the remnant of a degenerated seminiferous tubule. 11 days after inoculation. Hematoxylin-eosin.  $\times 306$ .

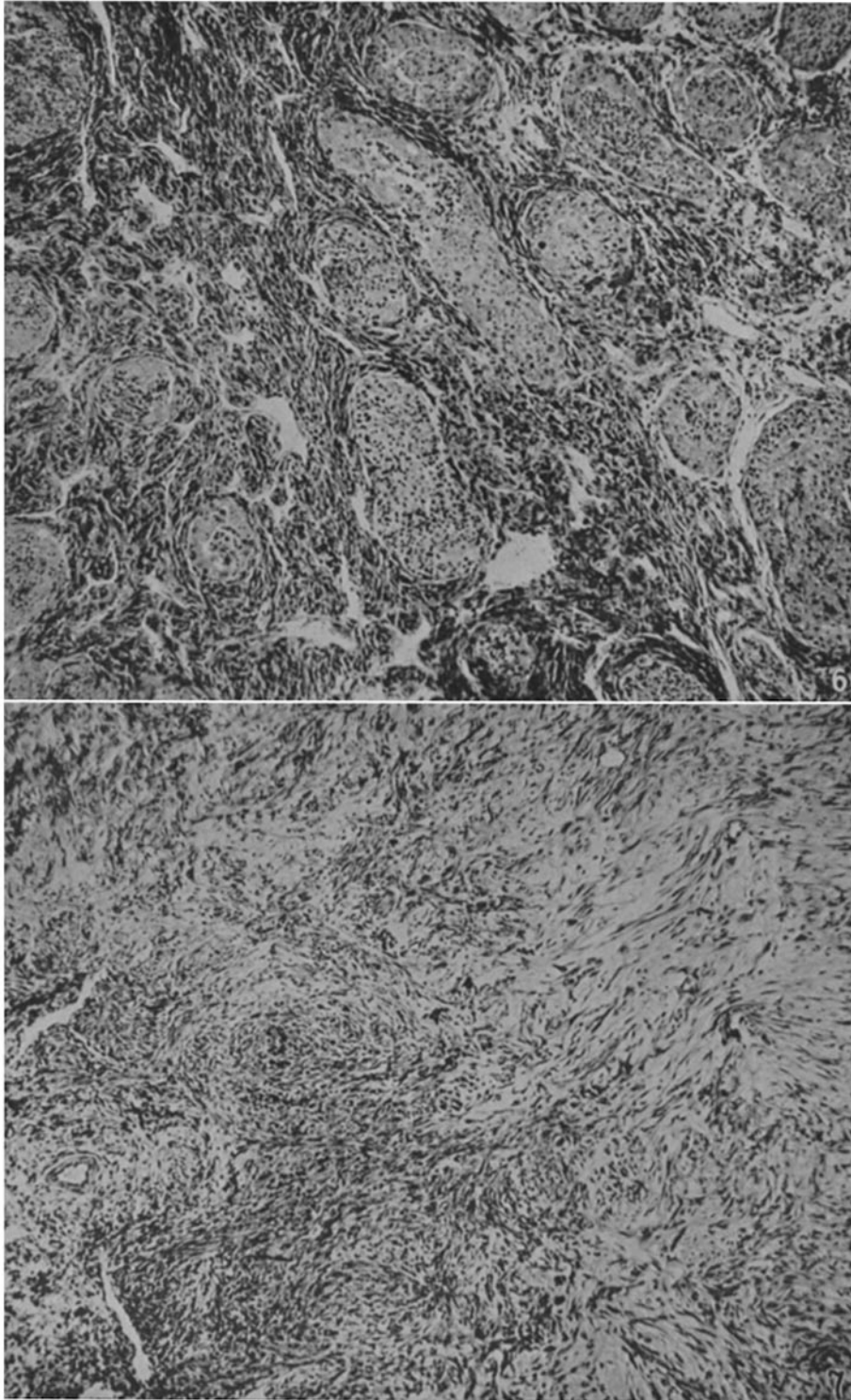
FIG. 9. Section of testicular tumor showing whorl-like arrangement of young proliferating connective tissue about nutrient blood vessels. Connective tissue cells invading surrounding necrotic tissue at margins. 11 days after inoculation. Giemsa.  $\times 87$ .



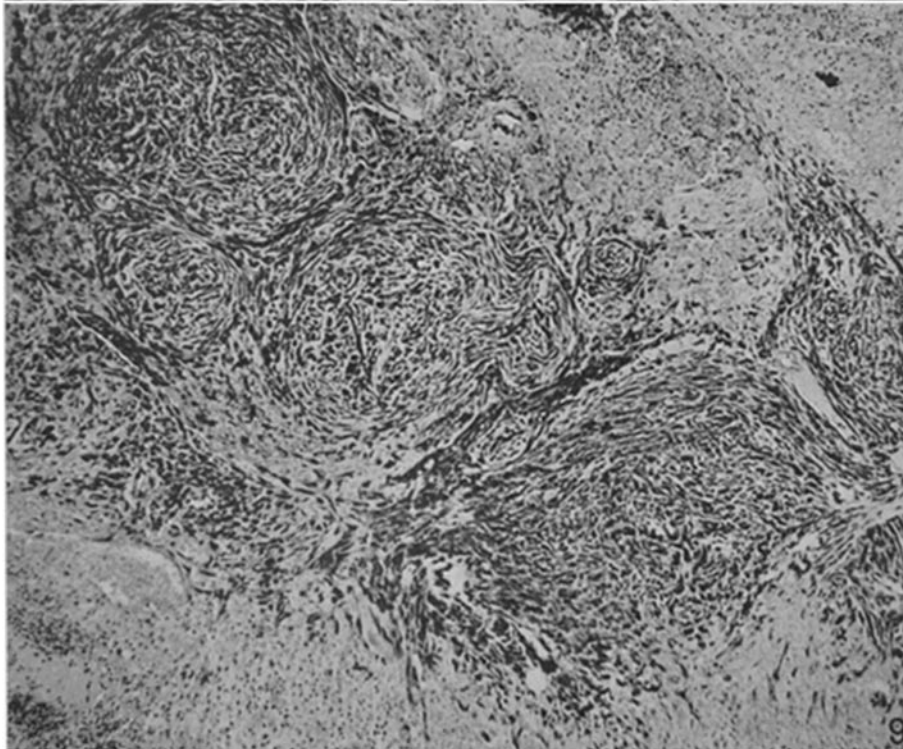
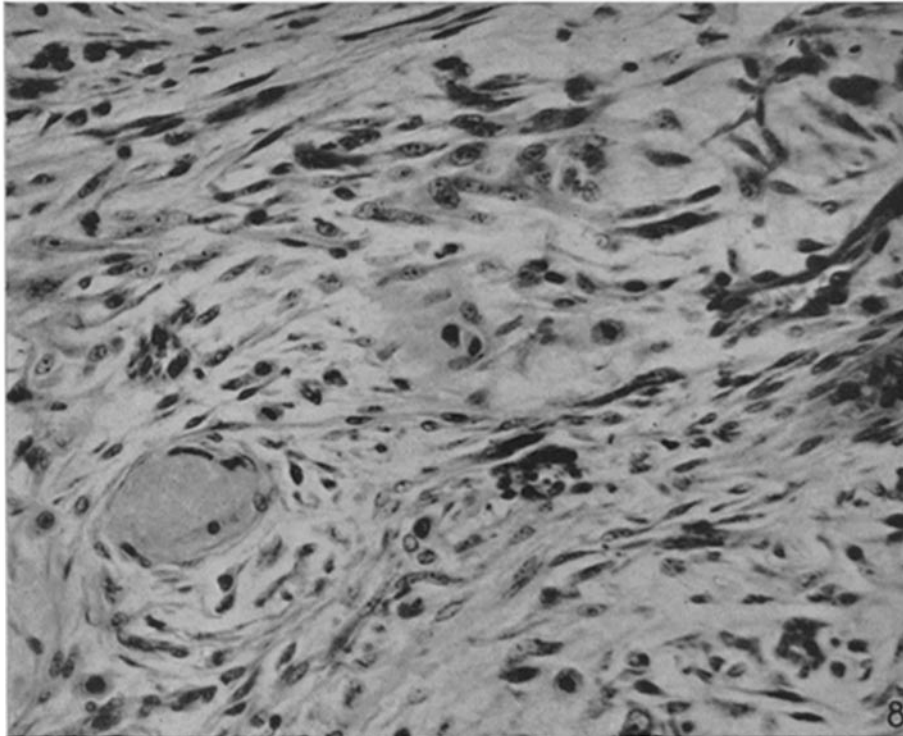
(Shope: A tumor-like condition in rabbits)



(Shope: A tumor-like condition in rabbits)



(Shope: A tumor-like condition in rabbits)



(Shope: A tumor-like condition in rabbits)