

A CORRELATION BETWEEN THE HISTOLOGICAL
CHANGES AND THE FATE OF LIVING TUBERCLE
BACILLI IN THE ORGANS OF REINFECTED
RABBITS

By MAX B. LURIE, M.D.

(From The Henry Phipps Institute, University of Pennsylvania, Philadelphia)

PLATES 10 TO 13

(Received for publication, August 27, 1932)

Since Robert Koch (1) first observed and described the phenomenon that bears his name there have been repeated attempts to elucidate the differences in the reaction to tubercle bacilli of normal and tuberculous animals, with all the implied problems of natural resistance and acquired immunity. Amongst these may be mentioned the work of Lewandowsky, Krause and Peters, Baldwin and Gardner, Jaffé and Löwenstein, Long, and Gardner (2). They conclude that the lesion of reinfection is differentiated from that of the primary infection by the acceleration and intensification of the immediate inflammatory reaction and by the accelerated formation of nodule and tubercle and the abortive nature of these lesions. Kalbfleisch (3) on the other hand maintains that in rabbits only slightly affected with tuberculosis the course of a second infection differs in no way from the course of a primary infection in the conjunctiva, mesentery and skin, and that in extensively diseased rabbits there is only a quantitative difference, observed chiefly in the skin as a more intensive or, less often, as a less intensive reaction in the tuberculous as compared with the normal animal.

The fate of the bacilli of reinfection has also been studied by numerous investigators (4). However no experiments have thus far been reported in which the fate of the living bacilli and the associated histological changes have been studied together in the same reinfected animal. The rôle of inflammation in resistance to reinfection is far from settled.

In recent experiments (5) on the response of the rabbit to a primary infection the fate of living tubercle bacilli cultured from a given tissue was studied in relation to the associated histological changes. It was found that the mononuclear phagocytes in various organs possess an inherently different capacity to destroy tubercle bacilli. If the bacilli fail to be destroyed by these cells they accumulate in the cytoplasm and the greater the number of the microorganisms the more extensive the multiplication of new mononuclear cells by mitosis. When the mononuclears are transformed into mature epithelioid cells and the tubercles have reached their maximum development the bacilli have already undergone extensive destruction and are disappearing. On the basis of these observations the epithelioid cell of tuberculosis may be described as a mononuclear phagocyte that has killed and incompletely digested tubercle bacilli or their products. After multiplication of the tubercle bacilli has ceased regeneration of mononuclears by mitosis becomes less active and Langhans giant cells may be formed from preexisting epithelioid cells. Lymphocytes and granulation tissue surround and permeate the tubercle after the bacilli have been destroyed, and the tubercle retrogresses.

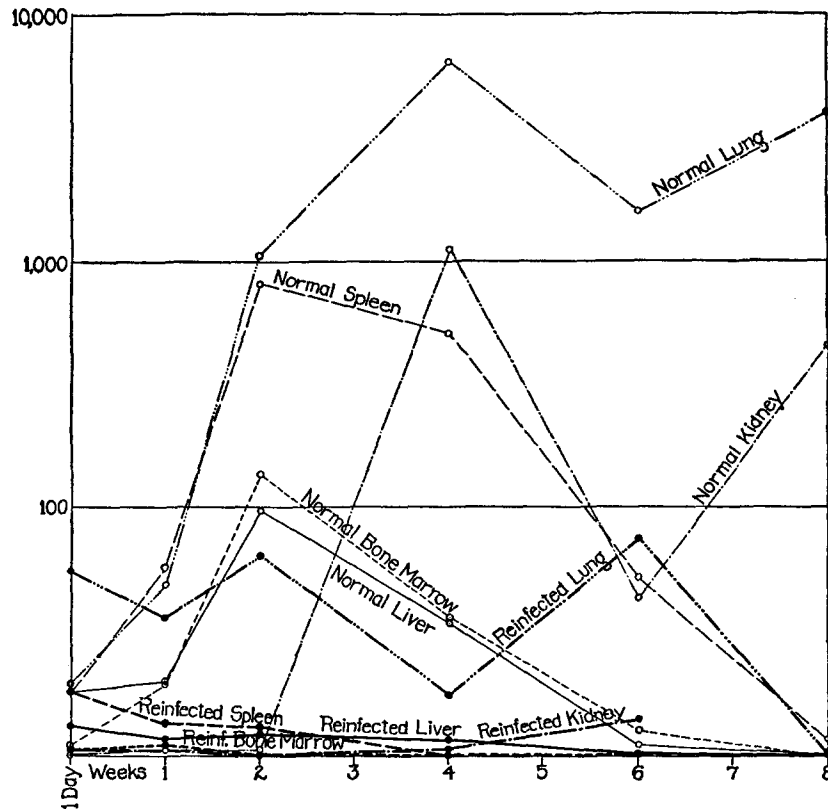
A similar study of the reinfected animal was undertaken to throw further light upon the relation of host and parasite.

Method

A series of rabbits was inoculated intravenously with 0.001 mg. of tubercle bacilli of a human strain (P 48A) per kilo of body weight. It has been shown (6, 1928) that 6 months after such an inoculation the tubercle bacilli have almost completely disappeared from the liver, spleen and bone marrow and have as a rule been greatly reduced in numbers in the lung and kidney. At about this time, therefore, 15 of these rabbits were given intravenously a reinfesting dose of 0.01 mg. of the same strain of tubercle bacilli. Another series of 15 rabbits was infected with the human strain and reinfected with a bovine strain, Bovine C, in the same quantities and by the same route. At the same time two series of normal rabbits, 13 in each, were injected intravenously with 0.01 mg. of these strains, one with the human, and one with the bovine type bacilli.

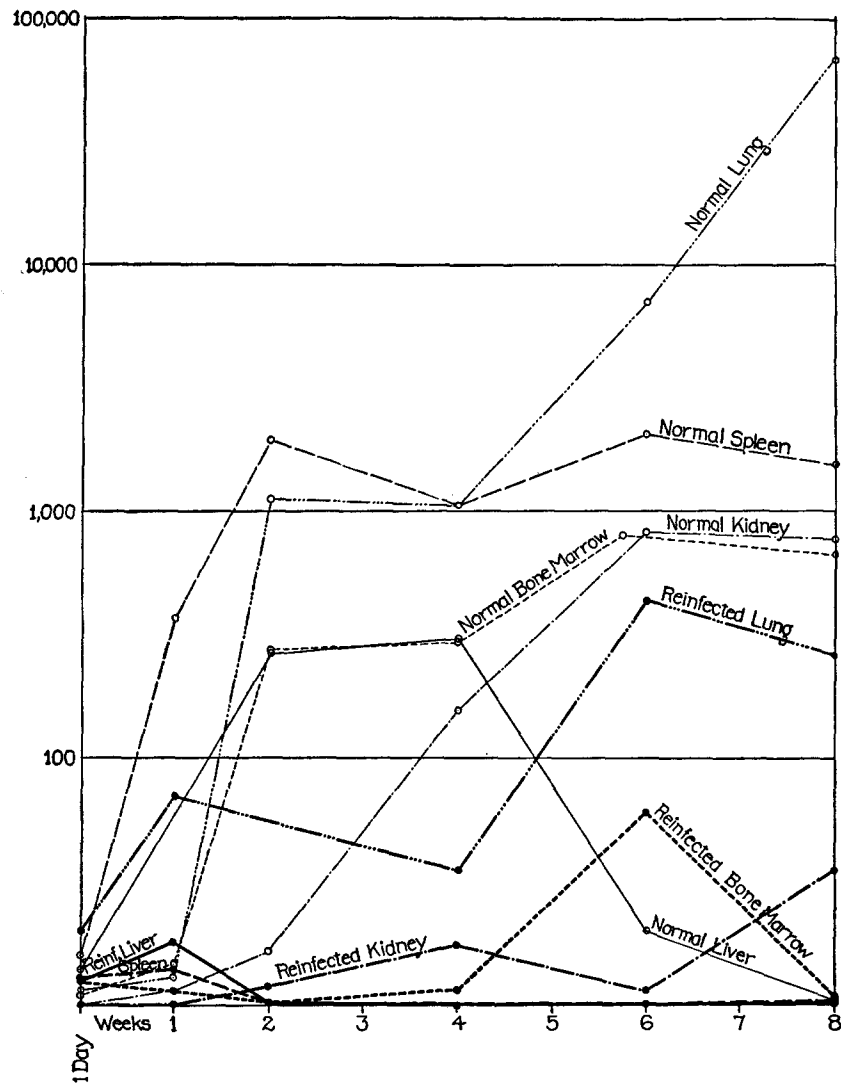
At intervals of 1 day, 1, 2, 4 and 6 weeks and 2 months equal amounts by weight of suspensions of ground lung, liver, spleen, kidney and bone marrow in varying dilutions were seeded directly upon tubes, three of Dorset's and three of Petroff's egg media, and similarly after sodium hydroxide treatment. Two or three rabbits were used for each interval. The number of colonies of tubercle bacilli appearing on the surface of each tube was repeatedly determined, the final reading being

made at the end of 3 months. Sections of all the organs were taken for microscopic examination from the immediate neighborhood of those parts that were cultured. In the reinfected animals care was observed to avoid culturing tissues that were apparently affected by the primary infection. In addition sections of the primary



TEXT-FIG. 1. Each point plotted on the light lines represents the average number of colonies cultured from 10 mg. of a given organ from each of two or three rabbits at varying intervals of time following a primary intravenous inoculation of 0.01 mg. of tubercle bacilli of human type (P 48 A). The points plotted on the heavy lines represent the average number of colonies cultured from the same amount of tissue of a similar number of rabbits reinfected with 0.01 mg. of the same strain 6 months after a primary intravenous inoculation of 0.001 mg. of P 48 A per kilo.

lesion were also prepared for microscopic study. The sections were stained with hematoxylin and eosin and by the Ziehl-Neelsen method for tubercle bacilli with hematoxylin as a counterstain.



TEXT-FIG. 2. Each point plotted on the light lines represents the average number of colonies cultured from 10 mg. of a given organ from each of two or three rabbits at varying intervals of time following a primary intravenous inoculation of 0.01 mg. of tubercle bacilli of bovine type (Bovine C). The points plotted on the heavy lines represent the average number of colonies cultured from the same amount of tissue of a similar number of rabbits reinfected with 0.01 mg. of the same strain 6 months after a primary intravenous inoculation of 0.001 mg. of tubercle bacilli of human type (P 48 A) per kilo.

The fate of the human and of the bovine type tubercle bacilli in the organs of the normal and reinfected animals has been reported in detail (6, 1929) and is contrasted in Text-figs. 1 and 2. Each point plotted represents the average of two or three rabbits except when the cultural characteristics of the bacilli and the associated histological changes were definitely due to residual primary lesions. This necessitated the exclusion from the curves of 7 out of 90 observations of the liver, spleen and bone marrow of rabbits reinfected with human or bovine bacilli. The inclusion of these data would not materially change the trend of these curves. In the lung and kidney however, the persistence of the primary lesion necessitated the omission of 20 out of 60 observations. In the lung, moreover, there were sometimes lesions that could not be clearly ascribed either to the primary infection or to the reinfection. This explains the irregularity of the curves for this organ. In comparing the heavy lines indicating reinfection with the light lines indicating primary infection the immediate destruction of the bacilli with the former is obvious.

The fate of these bacilli in the 26 normal and in the 30 reinfected rabbits is here correlated with a study of the associated lesions. This relation as observed in the liver, spleen and bone marrow is described first, because residual lesions and tubercle bacilli of first infection were very rarely found in these organs.

The terminology used in the description of the various cells observed is discussed in a former report (5).

The Liver, Spleen and Bone Marrow after Reinfection with Human and Bovine Type Tubercle Bacilli

Findings after 24 Hours.—

Reinfection with Human Strain.—In Rabbit R 14¹ there was an extensive pulmonary tuberculosis remaining from the primary infection; 720 colonies were isolated from the lung. 3 colonies were obtained from the liver. There was a marked accumulation of mononuclear leucocytes in the liver sinusoids; many of these were detached Kupffer cells. Polymorphonuclears were very rare amongst them. At the periphery of the lobule the mononuclears were often gathered into compact nodules spreading the liver cords apart. Some of them had abundant reticulated cytoplasm. They contained no tubercle bacilli or acid-fast particles. Essentially the same observations were made in Rabbit R 16 (Fig. 3).

In the lung of Rabbit R 15 two isolated tubercles remained from the primary infection and 56 colonies were isolated from this organ. 12 colonies were cultured from the liver. There were fewer mononuclears and more polymorphonuclears than in the previous rabbit. Occasionally there were diffuse infiltrations of the liver sinusoids localized at the periphery of the lobule. The cytoplasm of the mononuclears was less abundant (Fig. 2).

¹ The numbers used to designate the animals are the same as in the paper on the fate of the bacilli of reinfection (6, 1929).

Reinfection with Bovine Strain.—A similar difference was found between two rabbits, Nos. R 42 and R 43, reinfected with bovine type bacilli. In one, No. R 43, with only a few residual lesions in the lung, from which 20 colonies were cultured, the liver showed a diffuse infiltration of the sinusoids by polymorphonuclear and mononuclear cells. In No. R 42, the lung of which was affected by a massive caseous tuberculosis with excavation, and yielded 8,300 colonies, the liver sinusoids were free of infiltrating cells and the mononuclear nodules were smaller, less numerous, more sharply circumscribed, had more abundant cytoplasm and much less prominent polymorphonuclear intermixture than in No. R 43. In No. R 43 the polymorphonuclears were more often free and intact; in No. R 42 they were more often engulfed by the mononuclears and disintegrating within them. 11 colonies were isolated from the liver of the former rabbit; no tubercle bacilli could be cultured from the latter.

Primary Infection with Human Strain.—From the livers of Nos. R 1 and R 2, 14 and 18 colonies respectively were isolated. There was a slight diffuse infiltration of the liver sinusoids by polymorphonuclears. Many of the Kupffer cells were swollen and their nuclei vesicular, and in the cytoplasm were occasionally seen coarse deeply staining acid-fast globules. Some of these cells were detached and rarely small groups of them were found in the sinusoids (Fig. 1).

Primary Infection with Bovine Strain.—In Rabbits R 29 and R 30 essentially the same though more intense reaction was found in the liver; 13 colonies were isolated from the first and 3 from the second rabbit.

From these findings it is clear that the immediate inflammatory reaction as expressed by the outpouring of polymorphonuclears and the accumulation of mononuclears is both intensified and accelerated in the reinfected animal. As a rule fewer bacilli are isolated after reinfection than after primary infection, indicating a greater initial destruction of the bacilli. This initial destruction is most complete in the presence of extensive residual primary lesions. It is associated with sharply circumscribed nodular accumulations of mononuclears in which the polymorphonuclears remain only as infrequent disintegrating cells within the abundant cytoplasm of the mononuclears; there is no general infiltration of the tissues by these cells. In the presence of slight or healed primary lesions the inflammatory reaction is more generalized and extensive, the nodular accumulation of mononuclears is less sharply demarcated, the polymorphonuclears are much more abundant and their phagocytosis by mononuclears, whose cytoplasm is slightly developed, is less in evidence; the bacilli are less effectively destroyed.

Findings after 1 Week.—

Reinfection with Human Strain.—From the liver of Rabbit 17 no colonies were obtained; from No. R 18 one single colony was cultured; both rabbits harbored residual primary lesions in the lung. In both, the lesion in the liver was inconspicuous and consisted of a few minute epithelioid and giant cell tubercles up to 150 micra in diameter. Isolated Langhans giant cells were also found in the sinusoids.

There was no primary lesion in the lung of No. R 19. 8 colonies were isolated from the liver; the tubercles were much more numerous and larger than in the previous rabbit, and isolated giant cells were less frequent. Some of the tubercles were resolving.

Reinfection with Bovine Strain.—There was a slight residual primary lesion in the lung of No. R 45. 31 colonies of bovine type were isolated from the liver, indicating considerable multiplication of the microorganism. The associated lesion was extensive, consisting of larger and more numerous compact tubercles than in any animal thus far described. Giant cells were less frequently found than in the other rabbits of this interval, and surrounding some of the epithelioid cells were mononuclears, amongst which mitotic figures were occasionally seen. A single tubercle bacillus was found within an epithelioid cell (Fig. 4). Rabbit R 44 is discussed below.

Primary Infection with Human Strain.—38 colonies were isolated from the liver of No. R 4. In the sinusoids minute collections of polymorphonuclears were occasionally seen intermixed with several large mononuclears with vesicular nuclei, in the cytoplasm of which acid-fast particles or a rare intact tubercle bacillus was sometimes found. Mononuclears were more numerous in similar collections in the liver of No. R 3; 11 colonies were isolated.

Primary Infection with Bovine Strain.—Essentially the same histological changes were found in Rabbits R 31 and R 32. Fewer colonies were isolated.

Thus again, 1 week after inoculation the reaction in the tuberculous animal is much further advanced than in the normal animal. With the first infection there are only minute collections of polymorphonuclears and mononuclears; whereas after the reinfection well formed mature epithelioid and giant cell tubercles have appeared. The bacilli have entirely disappeared from that reinfected rabbit in which, in association with the persistence of the primary lesion, tubercles are very inconspicuous, and have been less completely destroyed in that animal in which, in association with the complete disappearance of the primary lesion, tubercle formation is more widespread.

Bacilli of the more virulent type had actually multiplied in one animal. This multiplication was associated with a more extensive lesion in which some of the tubercles were still in an early stage of develop-

ment with continued mitosis of mononuclears, although some were mature and some already resolving.

Findings after 2 Weeks.—

At the end of this period only occasionally was a single colony or several colonies of bacilli, whether of human or bovine strain, isolated from the liver of 19 of the 20 reinfected rabbits. The single exception was Rabbit R 49 sacrificed 4 weeks after reinfection with bovine type bacilli. From the liver of this rabbit 18 colonies were isolated and evidence was obtained of invasion of the blood stream by the bacilli from the primary lesion as in Rabbit R 44 described below. Together with the disappearance of the bacilli of reinfection the lesions had retrogressed, leaving only an occasional Langhans giant cell or a collection of disintegrating epithelioid cells. These were characteristically found in the lymph vessels in the periportal spaces, which were often filled with vacuoles (Fig. 6), and there were more of them in rabbits reinfected with the bovine type, although the bacilli were just as rarely isolated from these animals.

Normal rabbits similarly infected showed marked multiplication of the bacillus. Thus 380 colonies were isolated from Rabbit 34, 2 weeks after a bovine infection. There were numerous oval tubercles composed of a core of epithelioid cells and occasionally giant cells surrounded by large mononuclears, often in mitosis (Fig. 5). Intact tubercle bacilli and acid-fast particles were found within the epithelioid cells and the first stages of caseation had appeared in some of the tubercles. Similar observations were made with the human primary infection except that caseation was not noted.

Two weeks after inoculation both the bacilli and the associated lesion in the liver of the reinfected animal have largely disappeared, whereas in the normal animal the bacilli are rapidly multiplying and the lesions rapidly extending.

The bacilli of reinfection are not completely destroyed in the liver even 2 months after reinfection, when an occasional isolated colony may be cultured. The connective tissue cells in the periportal canals are much increased, consisting of lymphocytes, occasional plasma cells, mononuclears and fibroblasts. There still may be found a rare giant cell, as after 2 weeks.

The relations between the fate of the bacilli of reinfection and the histological changes in the spleen and bone marrow were the same as in the liver. From these organs isolated colonies were repeatedly cultured in the absence of any microscopic tuberculous lesions.

The Lung after Reinfection with Human and Bovine Type Tubercle Bacilli

The correlation between the fate of the bacilli and the histological changes in the lung could not always be ascertained with the same degree of certainty as in the liver, spleen and bone marrow because a lesion of variable character often remained from the primary infection in this organ, and the number of contained bacilli varied accordingly. Furthermore, as will be shown later, in some rabbits there was clear evidence of tubular spread of the lesion from these foci. The age of a given lesion as indicated by its appearance could therefore not always be used as a criterion to differentiate between that due to endogenous spread and that due to the exogenous reinfection. Nevertheless certain definite relations were observed that in general are the same as those in the other organs.

Findings after 24 Hours.—

Reinfection with Human Strain.—Two isolated tubercles remained from the primary infection in No. R 15. 56 colonies were obtained in cultures. There were localized, though not sharply demarcated, infiltrations of the alveolar septa by large mononuclears with some polymorphonuclears. Macrophages laden with carbon particles often occupied what was left of the alveolar spaces. There was a considerable general accumulation of polymorphonuclears in the small vessels and in the septa. Both phases of the reaction were more marked than at the same interval with the primary infection.

There were small numbers of discrete tubercles in the lung of No. R 16. 1,030 colonies were isolated. The nodal thickenings were more extensive and more sharply delimited than in No. R 15. There were very few polymorphonuclears. The primary lesion in No. R 14 was extensive; 720 colonies were isolated. Histological changes due to reinfection could not be determined.

Reinfection with Bovine Strain.—There were a few residual tubercles in the lung of No. R 43, some with calcification. 20 colonies were isolated. There was intense acute inflammation and an accumulation of polymorphonuclears. These often plugged small blood vessels and infiltrated the septa in compact masses. Here and there were found small nodal collections of mononuclears intermixed with polymorphonuclears. No. R 42 showed a very extensive primary lesion. 8,300 colonies were isolated. It could not be ascertained if there was any lesion due to reinfection.

Thus the difference in reaction between the normal and the tuberculous animal as observed in the lung after 24 hours is the same as in the

liver, but more intense. Alveolar phagocytes play a more important rôle in the reaction of the reinfected than of the normal animal.

Findings after 1 Week.—

Reinfection with Human Strain.—One isolated tubercle 4 mm. in diameter remained in the lung of No. R 17. 6 colonies were cultured from an area that grossly appeared unaffected, but microscopically showed rare nodules up to 320 micra in diameter. These were often situated in alveolar spaces. They were composed of a core of young and mature epithelioid cells, or a rare giant cell, often containing carbon particles and frequently surrounded by a ring of mononuclears, polymorphonuclears and lymphocytes (Fig. 8). Some nodules were less mature and mitoses of mononuclears were seen about them. No. R 18 showed smaller and more mature tubercles probably due to reinfection. There were cavities in the base of both lungs. 61 colonies were isolated.

No lesions were visible in the gross in the lung of No. R 19. 40 colonies, apparently due to the reinfection, were isolated. The tubercles were from four to six times more numerous than in Rabbit R 17 and were considerably larger, a few as large as 500 micra. The accumulation of mononuclears about tubercles was much more conspicuous and diffuse, and mitotic figures were more frequent. Some of the larger tubercles showed the first stages of caseation (Fig. 9). The lymph follicles were not affected. Tubercle bacilli could not be seen histologically.

Reinfection with Bovine Strain.—There were two residual tubercles in each lung of No. R 45. 70 colonies were isolated. The lesion was essentially the same as in No. R 19 but more extensive. Here too caseation was found in a larger tubercle. The lymph follicles remained intact. No tubercle bacilli were seen. There remained very extensive primary lesions in the lung of No. R 44; 30,000 colonies were isolated. No lesions due to reinfection could be distinguished.

Primary Infection with Human Strain.—48 and 50 colonies respectively were isolated from the lung of Nos. R 3 and R 4. There were very rare nodular collections of mononuclears with hyperchromatic nuclei, with occasional mitosis at the periphery. Within these nodules were one or two cells with abundant cytoplasm and vesicular nuclei, sometimes containing two or three tubercle bacilli (Fig. 7). The lymph follicles were hypertrophied, showing a moderate number of mitotic figures. Occasionally they contained several aggregations of large cells, in which acid-fast particles were found.

Primary Infection with Bovine Strain.—The mononuclear nodules were larger and more frequent in Rabbits R 31 and R 37. Polymorphonuclears persisted in them. Bacilli were found within the mononuclears. No direct culture was obtained.

One week after a first inoculation there are minute interstitial nodules of mononuclears in the lung. After reinfection tubercles are formed; they are frequently situated in the alveolar spaces, and the

epithelioid cells often contain carbon particles. The intrapulmonary lymph follicles in the reinfected animal are not affected; in the primarily infected animal they are hypertrophied and contain early tuberculous foci.

As in the other organs the lesion is less extensive and more mature in the animal in which, in association with the persistence of the primary lesion, the bacilli of reinfection are almost completely destroyed. They are more extensive and in an earlier stage of development with continued mitoses of mononuclears in the animal in which, in association with the complete or almost complete healing or disappearance of the primary lesion, the bacilli of reinfection, whether of human or bovine type, are less completely destroyed.

It is noteworthy that in this latter group, small foci of caseation were seen in tubercles 1 week after reinfection. With the primary infection caseation was not found until the 2nd week with the bovine type, and not until the 4th week with the human type bacilli.

Findings after 2 Weeks.—

The tubercles were resolving. The cytoplasm of the epithelioid cells was filled with vacuoles, which in some coalesced, leaving only shreds of cytoplasm. The dissolution of the epithelioid cells had caused wide spacing between them. Lymphocytes, fibroblasts and capillaries surrounded and permeated the tubercles. Only a very small number of bacilli could be cultured; 6 colonies were isolated from one rabbit reinfected with the human type bacillus. With the bovine reinfection the disintegration of epithelioid cells was similar but much less in degree (Fig. 12). On the other hand the lesion was rapidly advancing both with human and bovine type primary infections. Early tubercles composed of a core of young epithelioid cells containing numerous bacilli surrounded by a ring of mononuclear cells, many in mitosis, with islands of young epithelioid cells in the lymph follicles, characterized the lesion of the primary infection with the human type bacillus. 1,580 colonies were isolated from such a lung. The bovine type primary infection at this time showed in addition an extensive diffuse infiltration of mononuclears in the septa with numerous mitoses, and the first stages of caseation had appeared in the larger tuberculous foci where numerous tubercle bacilli were found (Fig. 11). 1,200 colonies were isolated from such a lung.

Findings after 4 Weeks.—

4 weeks after reinfection the bacilli both of the human and bovine types had largely disappeared. Except for a rare very much disintegrated tubercle composed

of phantom-like vacuolated epithelioid cells, the lung after reinfection with the human type was free from lesions due to exogenous reinfection. 10 and 20 colonies respectively were isolated from Rabbits R 22 and R 24. From Rabbits 48 and 50, reinfected with the bovine bacillus, 10 and 60 colonies respectively were isolated. The residual tubercles were more numerous and their disintegration less far advanced. Frequently microscopic tissue defects had resulted from the disintegration of the epithelioid cells.

Two weeks after reinfection resolution of tubercles in the lung is beginning with the human type, and with both types the bacilli have largely disappeared. With the bovine type this process of disintegration is not conspicuous until the 4th week.

Although this is usually the fate of the bacilli of reinfection and the lesions to which they give rise in the lung, occasionally considerable multiplication of the bovine bacillus is found in this organ. This is illustrated in Rabbit R 53.

X-ray examination of the lungs before reinfection showed no tuberculous lesions. When the rabbit was killed 6 weeks after reinfection there were uniformly distributed discrete tubercles 1 to 3 mm. in diameter, some with punctate caseous centers. 540 colonies with the dysgonic characteristics of the bovine type were isolated. Microscopically the lesions were of two types. In one interstitial tubercles were surrounded by a heavy ring of lymphocytes, which together with ingrowing capillaries permeated the tubercles (Fig. 14). There were giant cells at the periphery. There were no tubercle bacilli and there was no caseation in such tubercles. Some of them were resolving. The larger and less frequent lesion was of combined interstitial and intraalveolar nature. Very rarely an isolated tubercle bacillus was seen in the neighborhood of minute foci of caseation. Infrequent mitotic figures were observed amongst the mononuclears infiltrating the septa about the pneumonic foci. Here there were many giant cells. By far the greater part of the parenchyma was free from tuberculosis. The lymph follicles were unaffected.

By contrast in a normal animal similarly infected most of the parenchyma was consolidated by conglomerate tubercles with extensive foci of caseation. Caseous pneumonia predominated, and the advancing edge of the focus was a mass of mononuclear cells with frequent mitoses (Fig. 13). Tubercle bacilli were found throughout the lesion but were especially numerous in the pneumonic areas. Lymphocytes did not surround or infiltrate the tubercles to any extent. The intrapulmonary lymph follicles were largely replaced by tuberculous tissue with central foci of caseation. 12,500 colonies were isolated from this lung.

It is evident that with the complete disappearance of the primary lesion bovine bacilli may persist in moderate numbers in the lung even 6 weeks after reinfection in small localized pneumonic areas with slight foci of caseation about which mitosis of mononuclears has not

yet ceased, although they have completely disappeared from the small, discrete, healing (Fig. 14) and resolving interstitial tubercles in the same lung. The intrapulmonary lymph follicles were not affected. In a primary infection at this time there is a massive multiplication of the microorganism in association with a generalized pneumonic process with unabated multiplication of mononuclears, extensive caseation and destruction of the intrapulmonary lymph nodes. It is noteworthy that even in Rabbit R 53 the bacilli of reinfection have completely disappeared from the liver and spleen and are present in much smaller numbers in the bone marrow than in the lung. This difference, as well as the larger initial lesions, and the slower resolution of these in the lung than in the other organs even in animals that completely destroyed the bacilli of reinfection, indicates that the acquired immunity is superimposed on the natural resistance of a given organ and is greater in an organ that has an initial greater resistance against the tubercle bacillus.

The Occurrence in the Kidney

Few tubercle bacilli of reinfection were isolated from the kidney after reinoculation with the human or bovine types. No inflammatory reaction was noted 24 hours after intravenous infection and as a rule no tubercles formed subsequently. That some tubercle bacilli of reinfection reached the kidney was indicated by the few residual bacilli isolated from rabbits in which the primary lesions had disappeared, in association with a rare abortive tubercle. Such instances were more frequent in the bovine type series.

These observations suggest that in the presence of a certain degree of immunity the small numbers of tubercle bacilli that are retained in the kidney are destroyed by the mononuclear cells *in situ* without causing any inflammation and without subsequent tubercle formation. Yet in the normal animal the kidney is the organ where the bacilli reach great numbers and where they cause extensive lesions, second only to those in the lung.

The Relation of Residual Primary Lesions to Reinfection

It is evident therefore from the foregoing experiments that in all the organs the bacilli of exogenous reinfection and the abortive lesions to which they give rise soon disappear whether they are of the identical

strain that was used for the primary infection or another, even if of more virulent type. Furthermore, the more extensive the primary lesion the more rapid and complete the destruction of these bacilli and the less conspicuous and more ephemeral the lesions caused by them. Yet these residual lesions in the lung and kidney themselves may harbor innumerable bacilli of the first infection, and may gradually extend until the whole organ is almost completely destroyed. A correlation between histological changes and the fate of bacilli in these animals indicates that there is no incongruity between this demonstrated immunity to the more virulent bovine bacillus of reinfection and the persistence and continued multiplication of the less virulent human type bacilli in the residual primary lesions. This is illustrated by Rabbit 44.

X-ray examination of the lung before reinfection with bovine type bacilli showed an extensive disseminated tuberculosis. 1 week after reinfection the animal was killed and 30,000 colonies of eugonic (presumably human) type were isolated from the relatively unaffected part of the lung. In the gross there was an extensive pulmonary tuberculosis with pus-containing cavities, and tuberculosis of the joints of all four extremities. Microscopically, the greater part of the lung parenchyma was consolidated by conglomerate foci of compact, homogeneous and cell-free caseous tissue in which tubercle bacilli were found with great difficulty. Here and there however there were caseous foci infiltrated with large numbers of both mononuclear and polymorphonuclear cells; the caseous material was broken up and often appeared as islands in a mass of pyknotic dead cells. Here tremendous numbers of bacilli, at times in actual colonies, had accumulated, apparently multiplying in the softened caseous material (Fig. 15). The surrounding partially thrombosed blood vessels occasionally showed tubercle bacilli. Some of these foci had broken into the bronchi (Fig. 16), and aspirated caseous material carrying large numbers of bacilli were seen lying free in the alveoli in the relatively unaffected parts of the lung from which the culture was made. Fresh foci of caseation surrounded by epithelioid cells in which there were bacilli in smaller numbers were also found in this location.

From the liver, spleen and bone marrow 28, 69, and 12 colonies respectively, all of the eugonic type, were isolated. Polymorphonuclears were conspicuous in these organs. Deeply staining acid-fast particles and hemoglobin pigment were found in the phagocytic mononuclears of these organs, which cells were at times seen in mitotic division. Rare minute epithelioid and giant cell tubercles were seen in them (Fig. 10).

From the kidney 1,630 colonies of the same type were isolated. There was a large wedge-shaped lesion undergoing a process of softening similar to that in the lung.

Similar observations were made in other rabbits of this series.

Thus the caseous foci in lesions of first infection undergo softening in a certain stage of their development. In these areas there are invading mononuclear and polymorphonuclear cells, which may undergo necrosis. Here there seems to be rapid and unhindered multiplication of the bacillus. Disintegrating caseous foci rupture into the bronchi and tremendous numbers of living tubercle bacilli may be aspirated into alveoli far removed from the original focus, there setting up fresh lesions, which in turn may undergo the same cycle and by tubular spread gradually cause the destruction of the organ. A similar process may take place in the kidney.

As softening progresses blood vessels may be involved in the rapidly extending caseous process, and although thrombosis occurs in most of them bacilli may invade the blood stream, and may be distributed to the various organs as with primary intravenous inoculation. In the liver they induce an acute inflammatory reaction and many of them are destroyed by the Kupffer cells. These cells undergo mitosis and the remaining bacilli are destroyed by abortive tubercles as were the bacilli of exogenous reinfection.

It is noteworthy that the tubercles were much more numerous and larger, and that there was no acute inflammation in the liver of No. R 45 (Fig. 4), a rabbit re-infected similarly to No. R 44 with bovine type bacilli. There were slight, healing residual lesions in the lung and 31 colonies of the bovine type were isolated from the liver. In this rabbit therefore the bacilli are due to the exogenous reinfection of the previous week. In No. R 44 however (Fig. 10), the infrequency of well formed tubercle in the liver suggests that the bacilli of exogenous reinfection of the previous week were destroyed and left little if any trace of their presence, whereas the abundance of polymorphonuclear leucocytes and the cultural characteristics of the bacilli indicate that they are more recently derived from the pulmonary lesion of primary infection.

That the bacilli that invade the various organs from the blood stream are there destroyed was clearly seen in Rabbit R 16. Here 24 hours after reinfection with human type tubercle bacilli only three colonies were cultured from the liver. No tubercle bacilli were obtained from the spleen. Nevertheless these organs contained several resolving epithelioid and giant cell tubercles, which must be attributed to the presence of tubercle bacilli at an earlier period brought there by the blood from the primary lesion, which showed areas of softening.

It is plain that the moderate numbers of tubercle bacilli of first infection that reach the various organs by way of the blood stream are rapidly destroyed. But in the lung the immunity brought about by

the first infection is overwhelmed by the massive seeding of bacilli from the aspirated material from softened areas.

DISCUSSION

From these observations certain inferences may be drawn in regard to the nature of immunity in tuberculosis. On the basis of the demonstration by animal inoculation that tubercle bacilli may persist in the lesions of reinfection Selter (7) has maintained that immunity to tuberculosis is not primarily due to the destruction of the bacilli of reinfection but to the tolerance of the tissue cells to the presence of the bacilli so that they fail to produce tuberculous lesions. Kalbfleisch (3) maintains that reinfected animals do not destroy tubercle bacilli more readily than the normal animal. Hedwal (8) has come to the same conclusion. That tubercle bacilli may persist in the tissues in complete absence of even microscopic lesions has been established by numerous observers. With the cultural method, by which the numbers of bacilli present can be determined, it has been found that a rare isolated tubercle bacillus may remain in tissues in which no lesions are visible with the microscope. However it is clear from the observations reported here that the failure of development of lesions is associated with an all but complete destruction of the bacilli, which may be accomplished within 24 hours in the liver, spleen and bone marrow of the more resistant animals, with moderate quantities of tubercle bacilli of moderate virulence in the presence of extensive primary lesions. With the healing or disappearance of the primary lesion this immediate destruction is less marked and the subsequent destruction of the bacilli is associated with the accelerated appearance of abortive tubercles. The degree of immunity to tuberculosis is therefore a function of the increased capacity of the tissue cells to destroy tubercle bacilli and varies directly with the extent of the primary lesion. However, the immunity is rarely sufficient completely to annihilate the microorganism.

In interpreting the cellular changes that accompany the increased destruction of the bacilli of reinfection one must bear in mind the succession of cells that characterize inflammation in general, namely polymorphonuclears, mononuclears and lymphocytes, and also the conclusion drawn from former experiments (5) that the epithelioid

cell of tuberculosis is a mononuclear cell that has destroyed and partially digested tubercle bacilli or their products.

In the presence of sufficient immunity, such as occurs with the persistence of extensive primary lesions, the bacilli of reinfection may be completely destroyed by phagocytosis in the mononuclear cells *in situ*, and there will be no immediate general or local infiltration of the tissues by polymorphonuclear and mononuclear cells, and no subsequent tubercle formation. This is seen when small numbers of tubercle bacilli of reinfection are retained in the kidney in sufficiently immune animals. When larger numbers reach a given organ, there is a slight accumulation of polymorphonuclears, which the mononuclears encompass and destroy, together with the bacilli, within 24 hours. Most of the nodules progress no further and by the end of a week they have all disappeared. A rare, minute, mature epithelioid and giant cell tubercle may be left indicating that in this focus the disintegration of the tubercle bacilli was incomplete. After this time the few residual tubercles resolve and the tissues return to their normal condition.

In the presence of partial immunity, such as occurs with the complete or almost complete disappearance of the primary lesion, the immediate inflammatory reaction is more intense and generalized, the bacilli are less completely destroyed and the accumulation of both polymorphonuclears and mononuclears continues for a longer time. More of the mononuclear nodules progress to tubercle formation at the end of a week and if the growth of the bacillus is incompletely suppressed new mononuclear cells accumulate and continue to form by mitosis around these tubercles. Thus the destruction of the bacilli of reinfection is a function of the acceleration and intensification of the inflammatory process. The more complete destruction is associated however not with the greater intensification but with the greater acceleration of the sharply localized inflammation. It has been seen that small numbers of bacilli can be destroyed by the mononuclear phagocytes *in situ* without inflammation. Hence the greatest immunity is associated with the absence of any lesion, a partial immunity with the more rapid formation of tubercle followed by its rapid disappearance.

Caseation developed in the lung of rabbits with little or no primary lesion 1 week after reinfection with either the human or bovine type bacillus in association with slight multiplication of the microorganism.

In the lung of normal rabbits 2 weeks after infection with the human type bacillus no caseation developed despite the presence of very much larger numbers of bacilli. The earlier appearance of caseation in the reinfected animal can be explained in part at least by the well known fact that the tubercle bacillus and its products destroy the cells of the tuberculous animal but leave unharmed the tissues of the normal animal (8).

It is noteworthy that the intrapulmonary lymph follicles remained intact in the reinfected animal even in the presence of the smallest degree of immunity, whereas in the normal animal they became the seat of extensive tuberculosis. This would indicate that most of the bacilli introduced intravenously into rabbits do not reach the lymph follicles primarily as maintained by Krause, but are drained from foci in the lung parenchyma, as recently maintained by Vorwald (10). In the reinfected animal they are destroyed wherever they localize and few if any are carried to the tributary lymph nodes.

The persistence of tremendous numbers of human type tubercle bacilli in the primary lesions of some reinfected rabbits and their gradual extension to the ultimate almost complete destruction of the organ despite the demonstrated immunity to the more virulent bovine bacilli of exogenous reinfection, are due to the process of softening and cavity formation that overtakes the old caseous foci. There is a massive accumulation of viable bacilli in the unorganized material of the softened areas, which leads to a rapid extension of the caseation and to tubular spread of tremendous numbers of bacilli (Fig. 16), which overwhelm the existing immunity. By the same process these bacilli enter the blood vessels but owing to the rapid formation of thrombi only moderately small numbers invade the general circulation whence they are filtered and destroyed by the organs, like the bacilli of exogenous reinfection (Fig. 10).

CONCLUSIONS

1. Immunity to reinfection is a function of the increased capacity of the mononuclear phagocytes to destroy tubercle bacilli and varies directly with the extent of the primary lesion; however it is rarely sufficient to annihilate completely the microorganism. This acquired immunity is superimposed on the natural resistance of a given organ.

2. In the presence of sufficient immunity, such as occurs with the persistence of an extensive primary lesion, small numbers of tubercle bacilli are destroyed by the mononuclear cells *in situ* without local or general infiltration of the tissues by polymorphonuclear or mononuclear leucocytes. Larger numbers of bacilli are destroyed within 24 hours by an accelerated formation of sharply localized nodules of mononuclear phagocytes. These progress no further and are absorbed or result in inconspicuous microscopic collections of epithelioid and giant cells.

3. In the presence of less immunity, such as occurs when the primary lesion has almost completely healed, the immediate inflammatory reaction is more intense and diffuse and persists longer. It results in a less rapid disappearance of the bacilli and in a more extensive formation of tubercles. These appear much earlier than in the normal animal and soon resolve.

4. Tubercle bacilli of reinfection may be destroyed even though the primary lesion in the lung and kidney is progressive. This is due to an unhindered extracellular multiplication of the bacilli in the caseous foci that undergo softening and excavation. Resistance may be overwhelmed by the spread of tremendous numbers of living bacilli from these foci through the bronchi or renal tubules, while the moderate numbers of reinfecting bacilli reaching the organs by way of the blood stream are destroyed.

REFERENCES

1. Koch, R., *Deutsch. med. Woch.*, 1891, **17**, 101.
2. Lewandowsky, F., *Die Tuberkulose der Haut*, Berlin, Julius Springer, 1916.
Krause, A., and Peters, D., *Am. Rev. Tuberc.*, 1920, **4**, 551. Baldwin, E. R., and Gardner, L. U., *Am. Rev. Tuberc.*, 1921, **5**, 429. Jaffé, H., and Löwenstein, E., *Beitr. Klin. Tuberk.*, 1922, **50**, 129. Long, E. R., *Am. Rev. Tuberc.*, 1924, **9**, 215. Gardner, L. U., *Am. Rev. Tuberc.*, 1930, **22**, 379.
3. Kalbfleisch, H. H., *Beitr. Klin. Tuberk.*, 1928, **70**, 465.
4. Römer, P. H., *Beitr. Klin. Tuberk.*, 1909, **13**, 1. Patterson, R. C., *Am. Rev. Tuberc.*, 1917, **1**, 353. Kraus, R., and Hoffer, G., *Deutsch. med. Woch.*, 1912, **38**, 1227. Manwaring, W. H., and Bronfenbrenner, J., *J. Exp. Med.*, 1913, **18**, 601. Rist, E., Kindberg, L., and Rolland, J., *Ann. méd.*, 1914, **1**, 310, 375.
5. Lurie, M. B., *J. Exp. Med.*, 1932, **55**, 31.
6. Lurie, M. B., *J. Exp. Med.*, 1928, **48**, 155; 1929, **50**, 747.

7. Selter, H., *Beitr. Klin. Tuberk.*, 1923, **55**, 318.
8. Hedwal, E., *Acta Soc. Med. Suecanae*, 1930, **56**, 1; *Z. Tuberk.*, 1931, **60**, 97.
9. Stewart, F. W., Long, P. H., and Bradley, J. I., *Am. J. Path.*, 1926, **2**, 47. Rich, A. R., and Lewis, M. R., *Proc. Soc. Exp. Biol. and Med.*, 1928, **25**, 596. Aronson, J. D., *J. Exp. Med.*, 1931, **54**, 387.
10. Vorwald, A. J., *Am. Rev. Tuberc.*, 1932, **25**, 74.

EXPLANATION OF PLATES²

All microphotographs were made from sections stained by hematoxylin and eosin except those shown in Figs. 6, 8, 10, 15 and 16, which were stained by the Ziehl-Neelsen method and counterstained with hematoxylin.

PLATE 10

FIG. 1. Liver of Rabbit 2, 24 hours after a primary infection with tubercle bacilli, human type. 18 colonies were isolated. Swollen Kupffer cells and slight infiltration of the sinusoids with polymorphonuclears. $\times 600$.

FIG. 2. Liver of Rabbit 15, 24 hours after reinfection with tubercle bacilli, human type. 12 colonies were isolated. Slight residual primary lesions in the lung. Diffuse infiltration of liver sinusoids with polymorphonuclear and mononuclear cells, the latter with scanty cytoplasm. $\times 600$.

FIG. 3. Liver of Rabbit 16, 24 hours after reinfection with tubercle bacilli, human type. 3 colonies were isolated. Moderate primary residual lesions in the lung and kidney. Sharply circumscribed nodule composed of mononuclears with abundant cytoplasm; the polymorphonuclears are almost entirely absent. $\times 600$.

FIG. 4. Liver of Rabbit 45, 1 week after reinfection with tubercle bacilli, bovine type. 31 colonies of the dysgonic type were isolated. Slight residual primary lesion in the lung. Extensive formation of tubercles surrounded by numerous mononuclears. $\times 140$.

PLATE 11

FIG. 5. Liver of Rabbit 34, 2 weeks after a primary infection with tubercle bacilli, bovine type. 380 colonies were isolated. An advancing tubercle with a core of epithelioid cells surrounded by extensive mononuclear infiltration. $\times 200$.

FIG. 6. Liver of Rabbit 47, 2 weeks after reinfection with tubercle bacilli, bovine type. 1 colony in three specimens was isolated. Vacuolated Langhans giant cells in the portal spaces. $\times 200$.

FIG. 7. Lung of Rabbit 4, 1 week after a primary infection with tubercle bacilli, human type. 50 colonies were isolated. A nodule of lymphoid mononuclear cells in a septum; no mature epithelioid cells. $\times 200$.

FIG. 8. Lung of Rabbit 17, 1 week after reinfection with tubercle bacilli, human type. 6 colonies were isolated. Slight residual primary lesion. Mature epithelioid tubercle; no caseation. $\times 200$.

² Approximate magnification is indicated for each figure.

PLATE 12

FIG. 9. Lung of Rabbit 19, 1 week after reinfection with tubercle bacilli, human type. 40 colonies were isolated. No residual primary lesion. Extensive tubercle formation with marked accumulation of mononuclears about the tubercle and caseation in an early stage in the center. $\times 200$.

FIG. 10. Liver of Rabbit 44, 1 week after reinfection with tubercle bacilli, bovine type, 28 colonies of the eugonic type were isolated. Numerous caseous pus-containing cavities in the lung and tuberculosis of the joints. Hemoglobin pigment in a Kupffer cell with mitosis of one of these just below and to the left of the Langhans giant cell; infiltration of sinusoids with mononuclear and polymorphonuclear cells. $\times 600$.

FIG. 11. Lung of Rabbit 34, 2 weeks after a primary infection with tubercle bacilli, bovine type. 1,200 colonies were isolated. Part of a large tubercle with massive accumulation of mononuclears with very few epithelioid cells; caseation in an early stage is seen in the upper portion of the tubercle. $\times 200$.

FIG. 12. Lung of Rabbit 46, 2 weeks after reinfection with tubercle bacilli, bovine type. 300 colonies of the eugonic type were isolated. Regressive intra-alveolar tubercle surrounded and permeated by lymphocytes. $\times 200$.

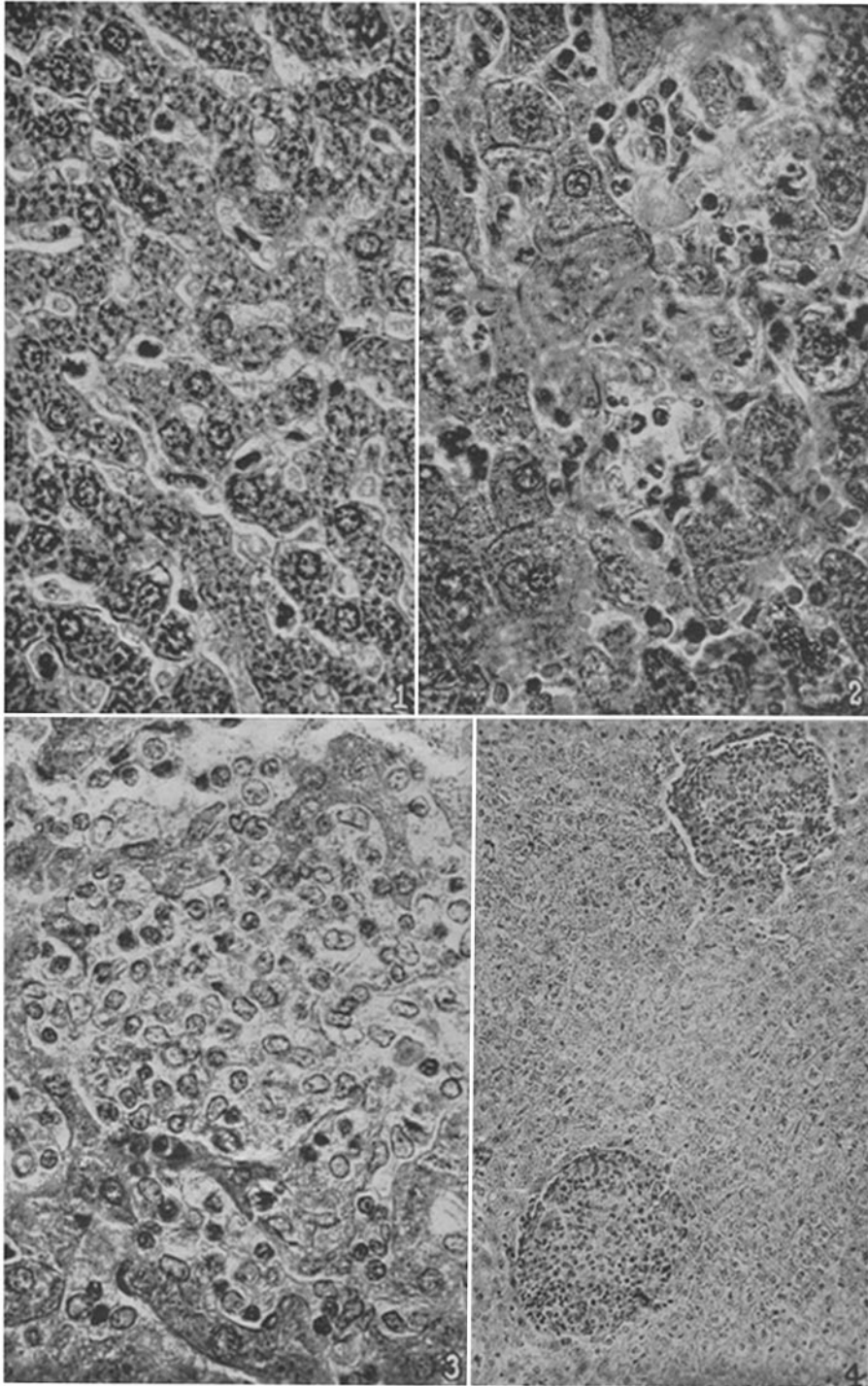
PLATE 13

FIG. 13. Lung of Rabbit 37, 6 weeks after a primary infection with tubercle bacilli, bovine type. 12,000 colonies were isolated. Extensive caseous interstitial tubercles surrounded by numerous mononuclears; caseous pneumonia is prominent. $\times 200$.

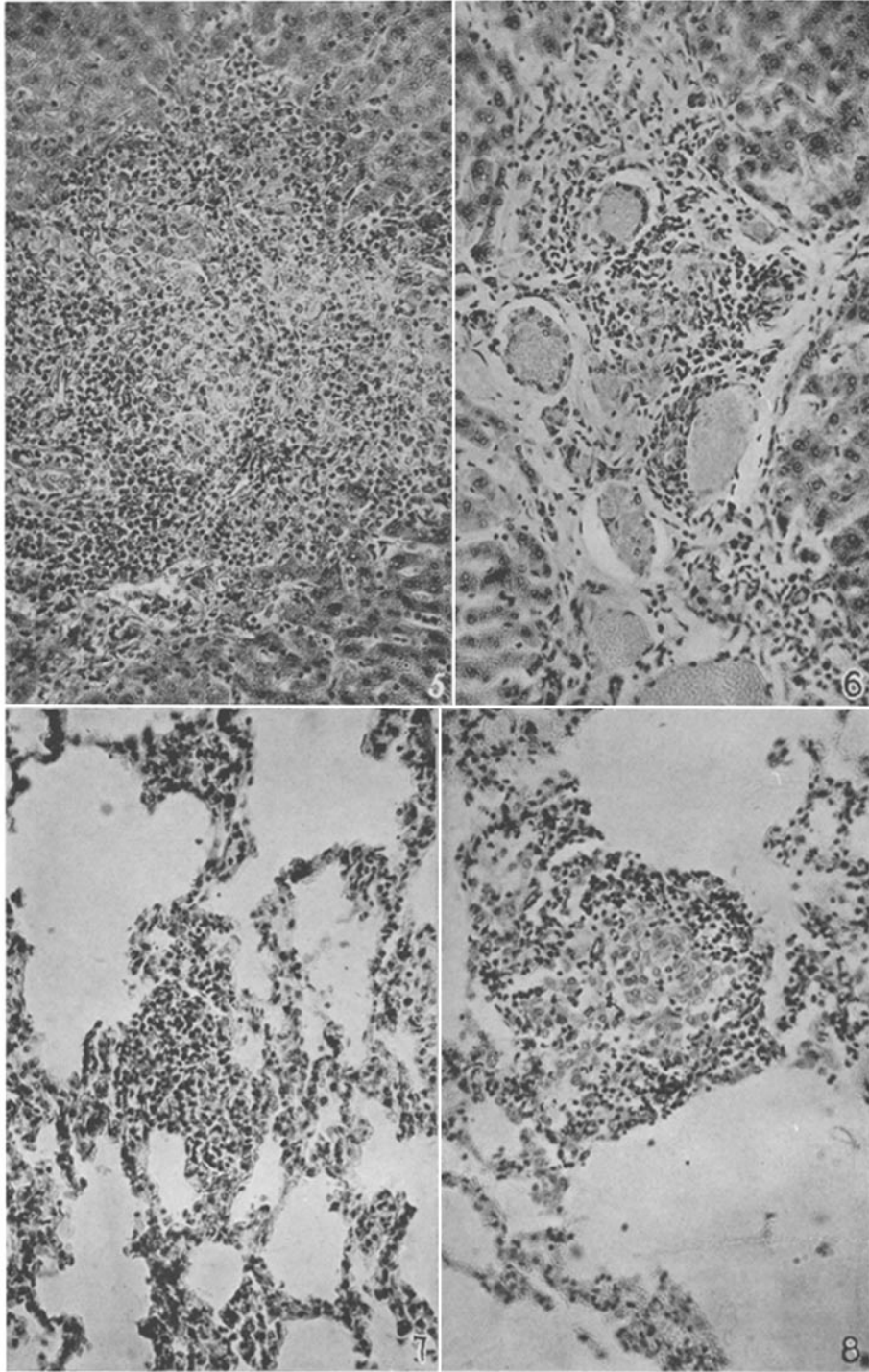
FIG. 14. Lung of Rabbit 53, 6 weeks after reinfection with tubercle bacilli, bovine type. 540 colonies of the dysgonic type were isolated. $\times 200$.

FIG. 15. Lung of Rabbit 44, 1 week after reinfection with tubercle bacilli, bovine type. 30,000 colonies of the eugonic type were isolated. An area of caseous tissue undergoing softening with numerous pyknotic cells and large numbers of tubercle bacilli. $\times 600$.

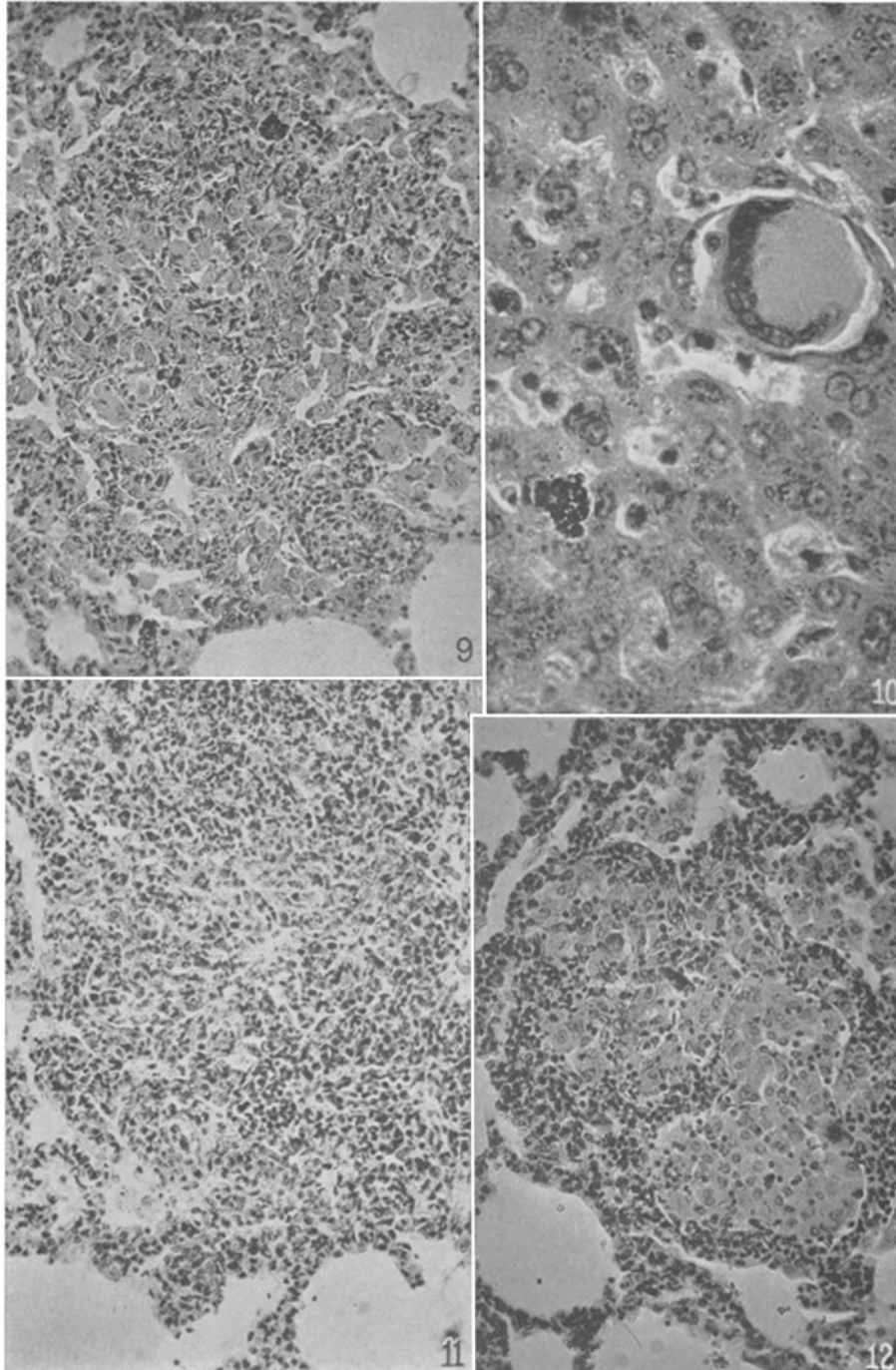
FIG. 16. Disintegrating caseous tissue in a bronchus from the same lung as in Fig. 15. $\times 600$.



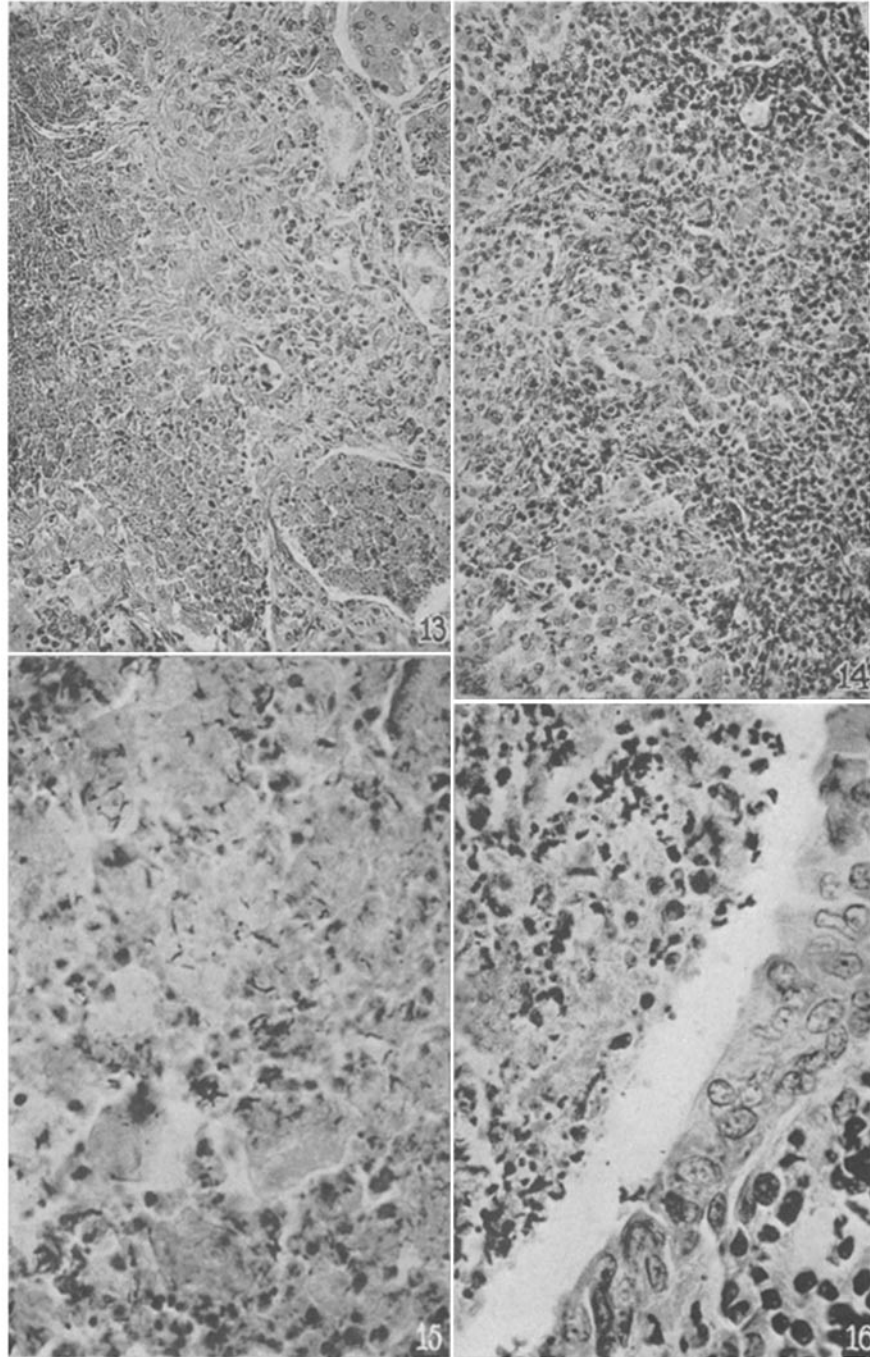
(Lurie: Living tubercle bacilli in organs)



(Lurie: Living tubercle bacilli in organs)



(Lurie: Living tubercle bacilli in organs)



(Lurie: Living tubercle bacilli in organs)