

## STUDIES ON THE ETIOLOGY OF RABBIT POX

### III. TESTS OF THE RELATION OF RABBIT POX VIRUS TO OTHER VIRUSES BY CROSSED INOCULATION AND EXPOSURE EXPERIMENTS

BY CH'UAN-K'UEI HU, M.D., PAUL D. ROSAHN, M.D., AND  
LOUISE PEARCE, M.D.

*(From the Laboratories of The Rockefeller Institute for Medical Research)*

PLATES 27 AND 28

(Received for publication, September 26, 1935)

In the first paper of this series (1) the experimental transmission of rabbit pox from spontaneous cases of the disease and the pathogenic properties of the causative agent, a filterable virus, were reported. The clinical characteristics of the experimentally induced disease which were described in the second paper (2) were found to be indistinguishable from cases of spontaneous pox.

The work on experimental pox included experiments on the immunological aspects of the reaction to the infection, in which connection comparisons with other filterable viruses were made. The experiments which dealt with the inoculation of recovered (immune) rabbits are reported in this paper. In this study the viruses of pox, vaccinia, virus III disease, and infectious myxoma of rabbits were used in various combinations. The results on the exposure of recovered rabbits to clinical cases of pox are also presented, the original infections in these cases being pox, vaccinia, or virus III disease. And finally, the results on the cutaneous reaction of a calf to inoculation with pox, dermovaccine, culture (dermo) vaccine, and neurovaccine are also included. The following paper contains the results of serum-virus neutralization experiments (3).

#### *Materials and Methods*

*Rabbit Pox Virus.*—Tissue emulsions were prepared from the testicles of rabbits with an acute pox orchitis. The animals for the most part belonged to the

regular passage series of the Xy171 strain of virus and had been inoculated intratesticularly (1). 10 to 15 per cent emulsions by weight were made with Locke's solution by grinding the tissues with alundum. In the case of Berkefeld V tissue filtrates, bacterial sterility was tested against *B. prodigiosus* in the usual manner (1).

*Vaccine Virus.*—The vaccine virus used for the majority of the experiments was the New York City Board of Health virus grown in tissue culture for many generations by Dr. T. M. Rivers and then usually passed for 1 or more generations in rabbits by intratesticular injection. Neurovaccine virus which was carried in rabbits by intratesticular inoculation was also obtained from an early acute orchitis. With both specimens of vaccine virus, 10 to 15 per cent emulsions of testicular tissue were prepared in the same manner as pox virus; the tissue emulsions were not filtered.

In the experiments in which a calf was inoculated, fresh vaccine lymph supplied by the New York City Board of Health was used. It was labelled "670. Good until 5-6-33." It was used on Apr. 19, 1933.

*Virus III.*—The source of this virus was also an early acute orchitis following intratesticular inoculation. The tissue emulsions employed were prepared in the same manner as those of pox and vaccine viruses. The emulsions were not filtered.

*Infectious Myxoma.*—A 10 per cent unfiltered tissue emulsion of the virus was employed. It was injected intradermally in 0.25 cc. doses.

*Animals.*—All experiments with one exception were carried out on rabbits, most of which were hybrid stock purchased from dealers. The majority were male animals 4 to 6 months of age. For one experiment a 75 kilo Jersey Holstein calf 3½ months old was used.

*Dosage and Route of Injection.*—These features of inoculation are stated in connection with the description of the various experiments.

#### *Immunity of Recovered Pox Rabbits to Reinoculation with Pox Virus*

The reaction of recovered pox rabbits to reinoculation with pox virus was investigated in 27 cases; 13 animals had had the spontaneous and 14 the experimental infection.

In the spontaneous cases reinoculation was carried out 2 to 7 weeks after symptoms had been noted, and in the experimentally infected rabbits 49 to 97 days or a mean of 64 days after inoculation. The animals were distributed in 8 experiments; in 4, comprising 9 rabbits, Berkefeld V tissue-virus filtrates were used, and in 4 experiments on 18 rabbits, unfiltered tissue emulsions were employed. For the majority of rabbits, intradermal injections of 0.1 to 0.3 cc. were given; both full strength virus and dilutions ranging from 1:10 to 1:100,000 were employed and a total of 91 sites were injected. 1 animal was injected intravenously with 1.0 cc. and both corneas were scarified and 3 rabbits were injected intratesticularly with 0.5 or 1.0 cc. doses; full strength virus emulsion was used for these cases.

Each experiment included normal control animals injected by similar routes but usually with smaller doses than those employed for the recovered rabbits.

The results of all reinoculation tests were uniformly negative in contrast to the uniformly positive results in the normal controls. An example of these findings is given in Table I. In no instance was rein-

TABLE I  
*Results of the Intradermal Injection of Rabbit Pox Virus (Unfiltered) in Rabbits Recovered from Rabbit Pox*

Rabbit	Virus dilutions 0.2 cc. dosage	Days after injection (Rectal temperature (°F.))						
		1	2	3	4	5	6	7°
		104.4°	102.9°	103.1°	102.7°	103.0°		101.2°
Recovered spontaneous case	1.0	±	++	+	+	±	0	0
	0.1	0	±	0	0	0	0	0
	0.01	0	±	0	0	0	0	0
		103.1°	101.5°	102.6°	102.7°	102.6°		102.7°
Recovered experimental case	1.0	+	++	++	+	0	0	0
	0.1	+	+	+	+	0	0	0
	0.01	0	+	+	+	0	0	0
		100.6°	103.2°	103.8°	104.4°	104.2°		
Normal control	0.1	±	++	+++	++++	+++++	+++++	Found dead
	0.01	0	+	++	+++	++++	++++	
	0.001	0	0	+	++	+++	+++	
	0.0001	0	0	0	+	++	++	
	0.00001	0	0	0	0	+	+	
	0.000001	0	0	0	0	+	+	

In this and other tables the plus signs represent the relative size and appearance of the lesions. + and ++ indicate swelling and congestion and possible slight edema; +++, +++++, and ++++++ represent increasingly larger areas with marked hemorrhage, edema, and necrosis.

oculation of recovered spontaneous or experimental pox rabbits associated with the development of local or generalized lesions other than a slight cutaneous thickening, or in the lower dilutions of virus a small slightly congested cutaneous swelling which persisted for 1 to 4 days. With unfiltered virus emulsions, there were occasional instances of slight transient edema and of slight superficial necrosis. Few of the

lesions attained a diameter of a centimeter and the majority were smaller. By the end of a week and usually before this time the skin appeared normal, while in the normal controls, on the other hand, the cutaneous lesions were still progressing actively. The results in the intravenously and intratesticularly injected rabbits were likewise negative.

The results of these experiments show that recovery from either the spontaneous or the experimental infection with pox renders the rabbit refractory to an injection of pox virus. The condition is apparently a true immunity since, as will later be shown (3), the sera of recovered rabbits possessed complete neutralizing properties when combined with active virus.

Such questions as the time of development of immunity, its completeness with respect to different tissues, and its duration could not be investigated. There was some clinical evidence to suggest that the immunity develops by stages or degrees. In both the spontaneous and experimental disease it was occasionally noted that reactivation and reinduration of skin papules occurred after healing was well advanced, and in both conditions, but more frequently in the experimental infection, new lesions developed when older ones were regressing. True relapse, however, was not observed.

#### *Crossed Inoculation Experiments with Immune Rabbits*

The comparisons of pox with other viruses comprised first the inoculation of pox recovered rabbits with the viruses of virus III disease, with dermo- and neurovaccine, and with the virus of infectious myxoma of rabbits, and second the inoculation of virus III and vaccinia recovered rabbits with pox virus.<sup>1</sup> For clarity and in order to save space, the results are presented in three sections in which the respective experiments dealing with virus III, infectious myxoma, and vaccinia are discussed and in this order.

<sup>1</sup> Experiments with rabbit pox and the Shope fibroma virus were kindly carried out by Dr. Carl TenBroeck and will be reported by him. Suffice it to say here that there was apparently no specific relationship between the two viruses.

*Virus III Experiments*

*Pox Recovered Rabbits.*—It was found that pox recovered rabbits were susceptible to inoculation with virus III.

Experiments were carried out on 6 rabbits; 2 had recovered from the spontaneous disease noted 25 and 30 days previously and 1 of these animals had also been injected with filtered pox virus 15 days previously with negative results. 4 rabbits had recovered from the experimental disease, the inoculations of which had been made 31, 32, 37, and 52 days previously by the intratesticular, intradermal, or intranasal routes. All 6 rabbits were injected intradermally at 1 or 2 sites with full strength virus III tissue emulsion in 0.3 cc. doses. 2 of the rabbits were also injected intratesticularly with 1.0 cc. doses. The animals were distributed in 3 experiments each of which included similarly inoculated normal rabbits.

The results were uniformly positive, that is, the reactions which developed in the pox recovered rabbits were comparable to those of the control animals. At all 9 sites of intradermal injection congested cutaneous swellings developed on the 1st or 2nd day, increased in size for 3 or 4 days, and then subsided. Some edema and slight hemorrhage was noted in 2 and superficial necrosis in 3 lesions. An orchitis of moderate grade, comparable to that observed in normal animals, developed in the 2 rabbits inoculated intratesticularly. Fever was recorded in 1 of these rabbits and in another inoculated intradermally.

*Virus III Recovered Rabbits.*—The results of 4 tests showed that rabbits which had previously been inoculated with virus III were not refractory to inoculation with pox virus and that the resulting infection was similar to that developed by normal rabbits.

One rabbit inoculated intratesticularly with virus III 14 days previously was injected intratesticularly with 0.4 cc. doses of pox tissue-virus filtrate and intradermally with 0.1 cc. doses of 4 dilutions of the filtrate ranging from 1:1 to 1:1,000. 3 rabbits inoculated in both testicles and intradermally with virus III 14, 21, and 23 days previously were injected intradermally with 0.2 cc. doses of unfiltered tissue-pox virus in 6 dilutions ranging from 1:10 to 1:1,000,000.

The local lesions which developed at each injection site were indistinguishable from those of the normal controls as regards time of development, appearance, and course. In addition, there developed in each rabbit a typical febrile reaction, a characteristic generalized maculopapular eruption of the skin, and well defined signs of eye and nasal involvement.

The results on recovered pox and virus III rabbits inoculated with the heterologous virus indicate that the two viruses are neither identical nor do they possess any immunological relationships one with the other.

*Infectious Myxoma Experiment*

Rabbits which had recovered from rabbit pox were as susceptible to the virus of infectious myxoma as normal rabbits.

The experiment which demonstrated this fact was carried out on a group of 12 rabbits of which 8 were recovered pox rabbits, 4 spontaneous and 4 experimental cases, and 4 were normal controls. The symptoms of the spontaneous cases had been observed 3 weeks to 2 months previously while the experimental cases had been inoculated 29 to 33 days previously. Myxoma virus was injected intradermally in doses of 0.25 cc.<sup>2</sup>

The reaction of the pox recovered animals to the myxoma virus was indistinguishable from that of the normal controls as measured by the length of the incubation period, the character of the ensuing lesions, and the time of death. All the animals were moribund 8 days after inoculation and were killed.

The results of the experiment indicate that the virus of rabbit pox is not identical with that of infectious myxoma and that there is no immunological relationship between them. Since infectious myxoma is an invariably fatal condition in normal rabbits, experiments with myxoma immune rabbits or with immune serum could not be made.

*Vaccine Virus Experiments*

*Pox Recovered Rabbits.*—Consistently negative results with one possible exception were obtained on 5 recovered pox rabbits injected with full strength culture vaccine virus.

One animal had been inoculated intranasally with pox virus 31 days previously and the others were spontaneous cases whose symptoms had been noted 4 to 6 weeks previously. The duration of recovery was estimated at 2 to 5 weeks. 4 male rabbits were injected intratesticularly with 0.5 or 1.0 cc. doses and intradermally at several sites with 0.2 or 0.3 cc.; a doe was injected intradermally. In 3 cases, virus was applied to the scarified corneas and in 2 cases to scarified skin areas. The rabbits were distributed in 3 experiments which included similarly inoculated normal rabbits.

During the first 48 hours after injection, the color of the skin about the injection site or along the lines of scarification was pale yellow or yellowish pink, but there was no cutaneous thickening or other change and by the 3rd day the skin had a normal appearance. No palpable alteration of the injected testicles was detected. In 1 animal in which virus had been dropped in the eyes, slight conjunctival and pericorneal injection and slight clouding of the corneas developed on the 3rd day, persisted for 2 to 3 days and then subsided. No reaction was observed in the eyes

<sup>2</sup> We are indebted to Dr. T. M. Rivers for the inoculation of myxoma virus and for the subsequent clinical observations.

of the other 2 pox immune rabbits given a conjunctival instillation of vaccine virus. In the normal rabbits injected with culture vaccine virus by the same routes, typical vaccinal reactions developed in each injection site.

*Vaccinia Recovered (Culture Virus) Rabbits.*—Variable results were obtained on 19 vaccinia recovered rabbits injected with pox virus.

The vaccinal infection was produced by culture vaccine virus injected by the intradermal or intratesticular route; in 16 animals the interval between the 2 injections was 18 to 32 days and in 3 it was 45 to 68 days. For 11 rabbits Berkefeld filtrates of pox tissue emulsions were employed and for 8 unfiltered emulsions. 13 animals were injected intradermally at 56 sites with 0.1 to 0.25 cc. doses of full strength and diluted emulsions. 2 animals were given intratesticular injections of 0.5 or 1.0 cc.; 3 rabbits were injected intravenously with 1.0 cc. and 2 of them also received intradermal injections while both corneas of the third animal were scarified; in 1 animal virus was dropped on the scarified corneas. The rabbits were distributed in 7 experiments which included normal rabbits similarly injected.

The results of the experiments were as follows: In the cases in which pox virus *filtrates* were used, no local reaction was detected in the injected testicles or eyes, but in 3 of the 7 cases injected intradermally there were peculiar cutaneous changes at the sites in which full strength virus and dilutions of 1:10 and 1:100 had been used. On the day after injection, there was a small circular diffuse swelling, the area was resistant and the skin quite congested. During the following 2 or 3 days the lesions increased in size to a diameter of half a centimeter or more; the induration and congestion were more pronounced; and some edema developed. Hemorrhage and necrosis were not observed. By the 4th or 5th day the swelling had subsided and the skin appeared normal. No generalized lesions were observed in 8 of the 11 rabbits injected with filtrates, but in 3 animals cutaneous papules developed.

In 1 rabbit injected intradermally, 2 small pink papules developed in the shaved skin of the injection area on the 4th day and persisted for 48 hours. In a rabbit inoculated intratesticularly a papule appeared in the shaved skin of the body on the 4th day and persisted for 3 days. The 3rd instance was in a rabbit inoculated intravenously; 2 small and 3 medium sized papules developed in a shaved skin area of the body on the 4th day and persisted for 5 days. Fever and other evidence of constitutional disturbance were not observed. It may be pointed out that there was no essential difference in the periods of time between the 1st injection of vaccine virus and the 2nd of pox virus in the case of the 3 rabbits with cutaneous papules and the 8 rabbits in which none was observed. In all 11 animals the interval was 18 to 32 days.

In the tests with the more potent *unfiltered* pox virus which were limited to intradermal injections, the local reaction resembled the occasional lesion observed with filtrates, but it was more pronounced. 8 vaccine immune rabbits distributed in 3 experiments were injected at 28 sites with doses of 0.25 cc. full strength virus.

TABLE II  
Results of the Injection of Unfiltered Rabbit Pox Virus in Rabbits Recovered from a Vaccinal Infection (Culture Virus)

Rabbit	Dosage Intradermal injection	Days after inoculation (Rectal temperature (°F.))							
		1	2	3	4	5	6	7	8
A	cc. 0.25	102.3°	102.6°	103.0°	103.3°	103.6°	102.6°	102.6°	0
	"	+	+	+	{ Indurated flat yellowish pink swellings with whitish centers	>	>	>	0
	"	+	+	+		>	>	>	0
	"	+	+	+		>	>	>	0
B	"	102.6°	102.6°	103.0°	103.0°	103.6°	102.6°	102.6°	0
	"	+	+	+	As above	>	>	>	0
	"	+	+	+		>	>	>	0
	"	+	+	+		>	>	>	0
C	"	102.2°	102.8°	102.5°	102.9°	103.6°	103.0°	103.0°	0
	"	+	+	+	+	>	>	>	0
	"	+	+	+	+	>	>	>	0
	"	+	+	+	+	>	>	>	0
Normal control	0.25 cc. of dilution	102.0°	103.9°	103.0°	104.5°	101.9°	101.9°	99.6°	Found dead
	0.1	0	+	+	+	<	<	{ Large swollen areas with edema, hemorrhage, and necrosis	
	0.01	0	+	+	+	<	<		
	0.001	0	±	+	+	<	<		
	0.0001	0	0	+	+	<	<		
0.00001	0	0	0	+	<	<			
0.000001	0	0	0	+	<	<			

6th day—macular papular rash on body and ears; lip papules; bilateral orchitis; profuse nasal discharge; popliteal adenitis; weak and ill

Signs + to + + + + + as in Table I. < = lesions progressing. > = lesions regressing.



3 typical protocols are summarized in Table II. It will be noted first that in the recovered vaccinia rabbits a cutaneous reaction was noticeable within 24 hours, whereas in the normal control rabbit it did not occur until the 2nd day. The normal rabbit, however, was injected with smaller doses, that is, dilutions of virus ranging from 1:10 to 1:1,000,000. In the vaccine immunes, the reaction comprised small red or yellowish red firm cutaneous swellings which increased rapidly in size and by the 3rd or 4th day were 3 or 4 cm. in diameter. The margins of the lesions were not sharply demarcated but faded out into normal skin. On the 2nd and 3rd days some edema and a few small areas of hemorrhage and superficial necrosis had developed in certain lesions. The height of the reaction was usually reached on the 3rd or 4th day. Regression then began and by the 7th or 8th day the lesions comprised firm cutaneous thickenings usually with a scaling surface. A febrile reaction in 3 of the 8 rabbits was first noted on the 2nd and 3rd days. No generalized lesions were observed, none of the animals appeared ill, and there were no fatalities.

The pronounced reactions of the normal control rabbits to both Berkefeld filtered and unfiltered pox tissue emulsions were entirely typical. The protocol of the normal control in Table II gives a good idea of the comparative size and course of the lesions produced by various dilutions of virus. The lesions comprised well defined congested cutaneous swellings which increased very rapidly in size and in which marked hemorrhage, edema, and necrosis were conspicuous features. Fever at some time was regularly observed and generalized manifestations were frequent.

The results of these two groups of experiments show first, the highly refractory state of recovered rabbit pox animals to culture vaccine virus injected intratesticularly, intradermally, and by the scarified skin and cornea routes, and second that recovered vaccinia rabbits are highly but not absolutely protected against inoculation with pox virus injected intradermally, intravenously, or intratesticularly. The reaction of the vaccine immune animals to intradermal injections of pox virus appeared to be of an accelerated or hypersensitive type in so far as the early development and the appearance of the local lesions was concerned, but in addition some lesions continued to be active and persisted for upwards of a week although in no case was the result comparable to that obtained in normal rabbits. A few instances of fever and a minor papular eruption of the skin were observed, but none of the rabbits became ill and none died. These findings point to some relationship between pox virus and vaccine (culture) virus.

*Neurovaccine Recovered Rabbits.*—Crossed inoculation of rabbits recovered from neurovaccinia had to be limited for various reasons to a single experiment (Table III). The experiment also included rabbits which had recovered from infection

TABLE III  
*The Reaction of Rabbits Immune to Dermo- (Culture) Vaccine Virus, Neurovaccine Virus, and Rabbit Pox Virus to the Intradermal Inoculation of These Viruses*

Rabbit	0.3 cc. at 3 sites Rabbit pox virus Days after inoculation							0.3 cc. at 3 sites Neurovaccine virus Days after inoculation							0.3 cc. at 3 sites Culture vaccine virus Days after inoculation							
	1	2	3	4	5	6	7	1	2	3	4	5	6	7	1	2	3	4	5	6	7	
Culture Vaccine Immune																						
A	+	+++	+++ E	+++ EHN	<	>	+++	+	++	++	++	>	>	+	+	+	+	>	>	+	+	
B	+	+++	+++ E	+++ EHN	<	>	+++	0	++	++	++ N	<	>	+	+	+	+	>	>	±	0	
C	+	+++	+++ E	+++ EH	<	>	+++	0	++	++	++ E	+++ HN	>	>	+	+	+	+	>	>	±	0
Neurovaccine Immune																						
A	+	++ E	+	++ E	+++ N	<	+	0	++	++	++ N	<	<	+	+	+	+	>	>	+	±	
B	0	+	+	++ N	+++ N	<	+	0	++	++	++ N	<	<	+	+	+	+	>	>	0	0	
C	+	+++ E	+++	+++ EHN	+++ N	<	+++	0	++	++	++	+++	<	<	+	+	+	+	>	>	±	0
D	+	+++	+++	+++ E	+++ E	<	+	0	++	++	++ E	+++	<	<	+	+	+	+	>	>	+	±

Rabbit Pox Immune													
A	+	+	+	+	+	+	+	+	+	+	+	+	+
B	0	+	+	+	+	+	+	+	+	+	+	+	+
C	0	±	+	+	+	+	+	+	+	+	+	+	+
D	0	+	+	+	+	+	+	+	+	+	+	+	+

Normal Control													
A	+	+	+	+	+	+	+	+	+	+	+	+	+
B	+	+	+	+	+	+	+	+	+	+	+	+	+

Signs + to +++++ as in Tables I and II. < = lesions progressing; > = lesions regressing. E = edema; H = hemorrhage; N = necrosis. \* = confluent lesions.

with culture vaccine virus or experimental pox, so that the results supplement those discussed in the preceding section. The reinoculation of the three viruses was carried out on 4 rabbits 66 to 75 days after inoculation with neurovaccine virus, on 3 rabbits 66 to 74 days after inoculation with culture vaccine virus, and on 4 rabbits 66 to 136 days after inoculation with pox virus. There were 2 normal controls. In the case of each virus pooled emulsions were prepared from the testicles of 3 rabbits with an acute marked orchitis. Unfiltered full strength emulsions were used. 3 intradermal 0.3 cc. doses of each virus were injected in each rabbit, the pox virus on the right side of the body, the culture vaccine virus on the upper left, and the neurovaccine virus on the lower left side. Since the three reactions to each virus in individual animals were quite similar, they have been represented by one sign in the summary of results in Table III.

The results in the normal animals will first be described. There were definite differences in the character of the reaction to the three viruses as shown particularly by the rate of development of the lesions, their size and duration, and the presence and degree of edema, hemorrhage, and necrosis. The reaction to pox virus was the most severe and that to culture vaccine the least, while the response to neurovaccine occupied an intermediate position. The pox lesions were well developed on the 2nd day, they soon became very large and confluent, and were still active at the end of a week (Fig. 1). Pronounced edema, hemorrhage, and necrosis were present in all of them. The neurovaccine lesions did not develop as soon or as rapidly as the pox lesions and by the 6th and 7th days were definitely regressing (Fig. 2). They preserved a nodular, circumscribed character and were not confluent. Edema, hemorrhage, and necrosis developed but to a considerably less degree than in the pox lesions. In the case of culture vaccine virus, the lesions were comparatively small, edema was not marked, hemorrhage, and necrosis were comparatively limited, and healing was practically complete by the end of a week (Fig. 2).

The intradermal reaction of 3 *vaccinia immune* rabbits to a 2nd injection of culture virus was practically negative. There were small nodular lesions on the 2nd day which did not persist (Table III). In the photograph taken on the 6th day, the injected areas show only a luxuriant hair growth (Fig. 4). With neurovaccine and pox virus, on the other hand, the results were positive, but the pox lesions were much the larger and showed more edema, hemorrhage, and necrosis (Figs. 3 and 4). In both cases, however, the lesions were less pronounced than those of the normal controls and regression was well under way by the end of the week.

In the case of 4 rabbits *recovered from neurovaccinia* and reinoculated with this virus, definite cutaneous lesions developed in all 12 sites of injection (Table III). Nodular congested and somewhat edematous swellings were noted on the 2nd day. They increased in size for 2 or 3 days, some necrosis developed, and then definite regression began; the appearance on the 6th day is shown in Fig. 6. The general character and degree of the reaction indicated a partial but not a complete refractory state to reinoculation of neurovaccine. The reaction of these animals to intradermal injection of culture vaccine was practically negative. There were 4

instances of small transitory nodular swellings, but by the 4th day the skin in all 12 injection sites appeared normal and continued so (Fig. 6). In contrast to these results the intradermal injection of pox virus uniformly produced well marked positive reactions with edema, hemorrhage, and necrosis, as shown in the photograph in Fig. 5 taken on the 6th day. The lesions were more pronounced than those of the homologous neurovaccine but were less marked than those in the normal controls and in the culture vaccine immune animals.

The reaction of 2 of the 4 *pox immune* rabbits to reinoculation with pox virus was considered negative (Table III); the interval between the 1st and 2nd inoculations was 66 days. The slight lesions which developed comprised small flat superficial areas of thickening which developed on the 2nd and 3rd day, the skin was faintly reddened and slight transient edema developed in some instances, but there was no hemorrhage or necrosis. A week after injection the skin was but slightly thickened and discolored (Fig. 7). A similar reaction was observed in 1 of 2 other pox immunes inoculated 136 days previously, but in the 2nd of these older immune animals a peculiar response was obtained which was classified as positive (Table III). The day after injection the skin about the injection sites was somewhat thickened and congested; the areas then enlarged in extent but only slightly in depth, and gradually the skin became cherry red and then a deep reddish brown color. There was a slight transient edema but no necrosis. The margins of the lesions were well defined. Regression began on the 5th day and healing was soon accomplished. The reaction of all 4 pox immune rabbits to injection with culture vaccine virus was negative; the slight skin changes on the 2nd day did not persist thereafter. In the case of neurovaccine virus, the reaction was considered to be partially positive (Table III) but it was clearly much less marked than that which developed in the normal controls. The lesions had the same general appearance as those in the normal rabbits but they developed a day later, did not attain as large a size, and their circumscribed nodular character was more pronounced. Their appearance on the 6th day when regression had begun is seen in Fig. 8. There was no obvious difference in the neurovaccine lesions which developed in the more recent as compared with the older pox immune animals.

The results of this comparative experiment supplement the suggestions regarding the nature of pox virus which arose from the observations on the experiments with culture vaccine virus described in the preceding section. In the first place, the modified reaction to intradermal injection of the viruses of pox, culture vaccinia, and neurovaccinia in rabbits immune to one of them indicates some common relationship. Rabbits which had recovered from pox, culture vaccinia, or neurovaccinia were completely refractory to culture vaccine. Culture vaccinia recovered rabbits were partially refractory to pox and were even more so to neurovaccine virus. Neurovaccine recovered

rabbits were partially refractory to neurovaccine but little more than were the culture vaccine immunes; they were somewhat refractory to pox virus and on the whole more so than were the culture vaccine immunes. Pox recovered rabbits were with one possible exception refractory to reinoculation with pox. They showed a partial refractoriness to the neurovaccine which, however, was probably less effective than that of neurovaccine immunes to reinoculation with neurovaccine, but which was more effective than the refractory state of the neurovaccine immunes to pox virus. From the standpoint of a refractory state to intradermal injections of all three viruses, the rabbits which had recovered from pox were more efficiently protected than were those which had recovered from neurovaccinia or culture vaccinia. And on the whole, the neurovaccine immune rabbits were more efficiently protected than the culture vaccine immunes. In this connection, it should be pointed out that the positive reactions of culture vaccine recovered rabbits to injection of pox virus in the present experiment were much more pronounced than those of previous experiments. It is not unlikely that the reason for the present result is connected with the longer period between vaccination and the pox injection and a consequent diminution of immunity.

In the second place, while the cutaneous lesions of the three viruses produced by intradermal injection in normal animals had a general resemblance one to another, there were well defined and consistent differences between them with respect to the rate and degree of development, the degree of hemorrhage, edema, and necrosis, the duration of activity, and the initiation and rate of healing. Differences of the same order were also observed in the lesions produced in the recovered (immune) animals of the experiment. From this standpoint of severity of reaction, pox virus was by far the most potent and culture vaccine the least while neurovaccine was less potent than pox virus but much more potent than culture vaccine. The rapid invasive growth of pox lesions with confluence of adjacent lesions was especially marked. The lesions of neurovaccine virus, on the other hand, were circumscribed and nodular, and the degree of edema, hemorrhage, and necrosis was very much less than in the lesions of pox virus. Although these differences were regularly observed, it must be remembered that the opportunity for studying neurovaccinia was limited and that

a greater experience might have shown them to be less pronounced or less uniform. It is difficult to say upon the basis of such a criterion as the general character of cutaneous lesions how far one is justified in assuming that essential differences between viruses exist. That these three viruses did not produce lesions of similar degree or severity, however, was certain, and from this standpoint it is permissible to conclude that at least they exhibited qualitative differences of pathogenicity.

*Exposure of Rabbit Pox, Virus III, and Vaccinia Immune Rabbits to Pox*

The exposure of rabbits which had recovered from pox, virus III, or vaccine infections to cases of pox took place in two rooms containing many animals with pronounced clinical symptoms of the disease. The rabbits with the exception of 12 young animals of one experiment were kept in individual cages and all were fed and cared for by the same persons. Before taking up the results on immune rabbits, the findings on normal rabbits exposed to room and cage infection will be presented.

*Normal Rabbits.*—Exposure experiments with normal animals were limited since this aspect of the work was done in connection with the investigations on the spontaneous disease (4).

Four normal adult rabbits were placed in the rooms at different times. All developed pox. In 3 cases the first clinical manifestations of the infection were noted on the 6th, 11th, and 15th days respectively; one animal was found dead on the 21st day while the others recovered from infections classified as moderately severe. The incubation period of the disease in the 4th animal is not known, but fever, a popliteal adenitis, and a few regressing cutaneous papules were observed on the 26th day.

Six young rabbits, the control animals in an experiment with vaccine immune animals to be described, were kept in the same pens with rabbits with marked clinical pox. All developed the disease; it was of moderate or marked severity in 5 cases and mild in the 6th (Table IV). The earliest lesion was observed on the 5th day. In 2 other animals lesions developed on the 6th, in 1 rabbit on the 9th, in another on the 12th, and in the last animal on the 14th day respectively. The 2 fatalities occurred on the 14th and 21st days. A 3rd animal with marked symptoms became seriously ill and was killed on the 14th day. The mean incubation period of the disease in the 3 adult rabbits was 10.7 days and in the 6 young animals in actual contact with pox cases was 8.7 days.

*Pox Recovered Rabbits.*—During the 5 months in which most of the work on experimental rabbit pox was carried out, many rabbits which had recovered from

either the experimental or the spontaneous infection were caged in the same rooms with active cases of experimental pox. The duration of exposure ranged from a

TABLE IV  
*Results of the Cage Exposure to Rabbit Pox of Vaccinated (Culture Vaccine) and Normal Rabbits*

Rabbit	Fever		First lesion	Clinical manifestations			Result
	First record	Highest recorded					
Vaccinated Rabbits							
1	13	105.5	12	Popliteal adenitis.	Lip papules.	Nasal discharge	Recovered
2	11	104.9	14	" "	Diarrhea		"
3	10	105.3	10	" "	Lip papules.	Conjunctival discharge	"
4	6	105.6	12	" "	Nasal discharge		"
5	10	104.1	12	" "	Diarrhea		"
6	6	104.1	5	" "	Lip papule		"
Normal Rabbits							
1	12	104.2	12	Popliteal adenitis.	Nasal discharge		Recovered
2	7	105.6	5	" "	Marked general mucocutaneous rash.	Diarrhea	Dead 21st day
3	—	103.7	14	" "			Recovered
4	6	106.8	6	" "	Mucocutaneous rash.	Nasal discharge	"
5	6	107.0	6	" "	Marked mucocutaneous rash.	Nasal discharge. Diarrhea	Dead 14th day
6	6	107.4	9	" "	Marked mucocutaneous rash.	Nasal and conjunctival discharge. Keratitis. Diarrhea	Moribund; killed 14th day

few days to 3 months or more. In no instance was there any clinical evidence of reinfection.

*Virus III Recovered Rabbits.*—When the crossed inoculation and virus-serum neutralization experiments were in progress, rabbits inoculated with virus III were kept in a separate room. At the expiration of this work, 4 virus III immune



animals were transferred to a pox room. All developed clinical pox. In 2 rabbits lesions were first noted on the 10th day and in the others on the 12th and 14th days respectively. 2 of the cases were mild and the animals recovered; the course and outcome of the infection in the others is not known as the animals were killed shortly after the diagnosis was made.

*Vaccinia Recovered Rabbits.*—There was no clinical evidence of the spread of pox to adult vaccine immune rabbits.

The 19 rabbits previously inoculated with culture vaccine virus and subsequently injected with pox virus were transferred to a pox room at the time of the pox injection. In 4 instances the wire mesh sides of the cages were placed in direct contact with those of rabbits with florid pox. The interval between vaccination and the time of exposure and injection of pox virus was 18 to 32 days or a mean of 23 days in the first group of 11 rabbits and 25 to 68 days or a mean of 39 days for 8 animals. The duration of exposure was variable but in most cases it was 2 or 3 months and in none less than a month.

As soon as it was reasonably certain that under these conditions vaccine immune rabbits did not develop clinical pox, an experiment was carried out in which actual contact of vaccine immunes with active cases of pox was insured.

Two litters comprising 12 English-Lilac hybrids 2½ months of age which had been weaned 12 days previously were procured from a breeding colony in which no evidence of pox had been detected. 6 rabbits were kept in strict isolation during the period of vaccine immunization of their 6 litter mates. Vaccination was carried out by the intradermal injection of 0.2 cc. of culture vaccine tissue emulsion. A typical cutaneous lesion with swelling, congestion, moderate edema, and slight necrosis developed in each rabbit. The first indication of a positive reaction was noted on the 2nd day and by the 7th the lesions were regressing. 16 days after vaccination all 12 rabbits were put in two pens with rabbits showing pronounced pox symptoms. Each pen contained 3 vaccinated and 3 unvaccinated litter mates and 1 rabbit with well marked clinical manifestations of the disease resulting from the intradermal inoculation of a Berkefeld V tissue-virus filtrate derived from the 9th serial filtrate passage of the Xy171 strain of pox virus (1).

The results of the experiment, which are summarized in Table IV, show that contrary to what had been expected on the basis of previous findings, the vaccinated rabbits developed clinical signs of a pox infection. The disease was much less severe, however, than in the unvaccinated control litter mates.

In 5 controls the disease was moderate or marked and the symptoms included 4 instances of a generalized papular rash. Rectal temperatures above 104°F. were recorded, the mean value of the highest readings being 106.4°F. The mean time of the first record of fever was 7.4 days and of the the first lesions of the 5 animals was 7.6 days. There were 2 fatalities on the 14th and 21st days respectively and a 3rd animal whose condition became serious was killed on the 14th day. The 6th control had a mild infection.

All 6 vaccinated rabbits developed mild infections and recovered. Fever was observed in each case but the average of the highest readings was 104.8°F., a value considerably below that for the controls. The mean time of the first record of fever was 9.3 days, that is, 2 days later than the control value. The clinical manifestations included a popliteal adenitis in all animals, papules on the lips in 2 cases, conjunctival secretion in 1, nasal discharge in 2, and a diarrhea in 2 cases respectively. There was no instance of a generalized cutaneous eruption. The mean time at which the first lesions were detected was 11.1 days after exposure, that is 4 days later than for 5 controls, or 2.4 days later if the 6th control is included.<sup>3</sup> Post mortem examination on the 26th day showed enlarged indurated popliteal lymph nodes in each animal, bronchopneumonia with lung papules in 2 cases, and suggestive changes of the liver in a 3rd case. The 3 recovered con-

<sup>3</sup> It was not known at the time this experiment was done that intradermal vaccination of the rabbit with vaccine virus may give rise to generalized manifestations, one of which is a generalized papular eruption of the skin and mucocutaneous borders (5). This information was obtained as a result of the vaccination of the breeding colony in 1933-34, the winter following the pox epidemic and the present investigations on experimental pox. In the light of this information, the question arises whether the lesions observed in the 6 previously vaccinated young rabbits which developed after cage exposure to pox, were manifestations of an acquired pox infection or generalized manifestations of vaccinia. The most convincing evidence against the latter possibility is the time at which the lesions developed in connection with the fact of a positive vaccination reaction. The mean time of development was 27 days after vaccination and all 6 animals had had a positive local reaction. The mean time at which generalized vaccinal lesions were observed in a large group of vaccinated adult rabbits was 6 to 10 days after vaccination, and there were but few cases in adults with a negative vaccination. In the young rabbits of one experiment (mean age 48 days) the great majority of the cases of generalized disease occurred in animals with a positive local reaction and at a mean time of 7 days after vaccination. In another experiment comprising slightly younger rabbits (mean age 38 days) the majority of the comparatively few cases of generalized manifestations which developed after a positive vaccination were detected within the first fortnight. There was also a small group of recently weaned animals in some of which generalized lesions developed at a mean time of 25 days after vaccination, but 90.0 per cent of these rabbits had had a negative vaccination.

trols which were also killed on the 26th day showed a similar condition of the lymph nodes and in 1 animal a patchy pneumonia of uncertain significance.

The results of this experiment show that under certain conditions it is possible for rabbits previously vaccinated with vaccine virus to contract rabbit pox from cage exposure. The clinical manifestations, however, were much less severe than those which developed in the unvaccinated litter mates, and the conclusion that vaccination may afford a marked measure of protection against pox is thus clearly indicated. But the fact that vaccine immune rabbits developed clinical pox even in mild degree raises the question of why a similar result was not obtained in any of the 19 previously vaccinated rabbits which were not only exposed to pox but were also injected with pox virus. It is true that in the one case the animals were in actual contact with pox rabbits while in the other they were exposed to a room infection. In view, however, of the highly contagious nature of the infection the difference between cage and room exposure is probably of little significance.

There were three other respects, however, in which the 6 animals of the cage exposure experiment differed from the other 19 vaccine immune rabbits.

First, the latter animals were injected by one or another route with pox virus at the time they were transferred to the pox rooms. Had any degree of susceptibility to pox existed at this time, one might have expected that the combination of virus inoculation and continuous ample opportunity for room infection would have resulted in the development of pox manifestations in some if not in all cases. In certain of these rabbits as was previously pointed out, the reaction to the injection of pox virus suggested that such a susceptibility did exist, but the manifestations which developed were even of a more minor nature than that observed in the animals of the cage experiment. Perhaps the explanation is concerned with an initial partially incomplete resistant state which was rapidly augmented to complete resistance by the reaction to the injection of pox virus.

Second, there was a difference in the time interval between vaccination and exposure to pox. In the cage exposure experiment this period was 16 days, and in the case of the other 19 animals it varied from 18 to 68 days. In 6 of these rabbits, however, it was 18 to 21 days, and in 7 others 24 to 28 days, so that the actual difference in a comparable number of rabbits was slight. A period of 16 days is generally regarded as being sufficient for the establishment of an efficient vaccinal immunity to reinoculation with certain exceptions such as a delayed corneal immunity of individual animals.

Third, there was an age difference. The 19 vaccinated rabbits which did not develop clinical pox after pox inoculation and pox exposure were mature animals approximately 6 months of age or older. The 6 vaccinated rabbits which developed a mild but definite pox infection after cage exposure were recently weaned animals  $2\frac{1}{2}$  months of age at the time of vaccination. Comparatively little is known regarding the influence of age on the reaction of the rabbit to experimental disease, but in the case of syphilis, for example, young rabbits have been regarded as being particularly susceptible and an analogous condition exists with respect to tuberculosis.<sup>4</sup> Recent experience with the vaccination of a rabbit breeding colony has shown that the reaction of animals to intradermal injections of vaccine virus differs in different age groups (5). Several years' observation on this breeding colony has emphasized the fact that one of the critical periods in the life of the rabbit is that of weaning. This period during which the animal must adapt itself to a self-sustaining existence is not infrequently characterized by evidence of a disturbed economy, as for example, an increase in the incidence of gastrointestinal disorders or of such infections as snuffles. In the pox epidemic, there was a very high mortality among animals less than 14 weeks of age and the highest rate occurred among those 4 to 8 weeks old (4). The complex physiological adjustments which take place during the weaning period may impose such a strain upon the animal's capacities that the responses to various conditions are quite different from those which occur at other ages.

In the particular observations under discussion there was no doubt that vaccination in young recently weaned rabbits did not afford the degree of protection against pox that was exhibited by mature vaccinated animals. It is possible that the natural resistance of young rabbits to pox is so much less than that of older animals that the mechanism of vaccinal immunity does not afford a comparable protection. An alternative explanation concerns a possible deficiency in the quality of the vaccinal immunity of young rabbits or a delay in its effective functioning. In this connection one must consider the possibility that the tissues of the portal of entry, presumably those of the respiratory tract in the present case, do not develop a vaccinal immunity effective against pox to the same degree or at the same rate as do other tissues such as the skin.

#### *Reaction of the Calf to Inoculation of Pox and Vaccine Viruses*

The comparisons between rabbit pox and vaccinia included observations on the cutaneous reaction of a calf to the several viruses applied to the scarified skin.

The skin on both sides of the body was shaved and scarified immediately before inoculation. On the right side 1.0 cc. unfiltered pox virus tissue emulsion was rubbed into the prepared area. On the left side 1.0 cc. each of culture vaccine

<sup>4</sup> Personal communication from Dr. J. H. Geiger.

virus, of the New York City Board of Health vaccine, and of a tissue emulsion of neurovaccine virus were rubbed into three areas separated by broad strips of unshaven skin. 2 rabbits were similarly inoculated with the four viruses in 0.25 cc. doses and in addition, the same amount of each virus was inoculated on 1 each of 4 rabbits by the same route of cutaneous scarification. Finally, 2 rabbits were injected in both testicles with 0.5 cc. of pox virus for the routine passage of the strain; virus was also applied to the scarified skin.

The results on the calf showed the development of a positive reaction to each virus but the pox lesions were considerably larger and much more persistent than those of the three specimens of vaccine virus. The lesions of the Board of Health vaccine were next in scale while those of neurovaccine and culture vaccine were less pronounced.

During the first 2 days the lines of scarification in all the vaccine areas were congested and prominent while those in the pox area were barely perceptible. On the 3rd day, however, several small papules were noted in the pox, the neurovaccine, and the Board of Health vaccine sites and on the 4th day in the culture vaccine area. These lesions and those which subsequently developed were confined to the lines of scarification. By the 5th and 6th days well developed lesions were present. The predominating type was a papule, but in some instances vesicles were forming and pustules were later observed. And by this time well defined differences in the grade or severity of the 4 lesions were apparent. The pox lesions comprised comparatively large papules and umbilicated vesicles in which hemorrhage and necrosis were conspicuous and in addition some lesions were edematous. The majority were discrete but some were confluent and crusts were forming. Of the vaccinia lesions those produced by the Board of Health virus were the largest but they were less numerous than the pox lesions and the majority were much smaller. Furthermore, there was much less hemorrhage and necrosis, comparatively little umbilication, and no edema. Crusts were beginning. There were more neurovaccine than Board of Health virus lesions, but they were much smaller and more superficial. Slight hemorrhage, necrosis, and crusting were present but no edema. In the case of culture vaccine virus, the reaction was comparatively slight. A few small papules had developed and there was a suggestion of beginning necrosis, hemorrhage, and vesicle formation but the lesions were much less pronounced than those of the other viruses. These differences in severity or grade of reaction continued to be maintained and were especially striking a week after inoculation as is shown by the photographs in Figs. 9 and 10. By this time umbilication and crusting of the pox lesions were particularly conspicuous.

By the 10th day the few culture vaccine papules had shown rapid regression and were almost healed. Those of neurovaccine virus had also shown marked regression; they now consisted principally of superficial fibrous thickenings of the

skin covered by thin blackish partially detached crusts. The lesions of the Board of Health vaccine virus were beginning to heal. There were 3 or 4 comparatively large and still resistant lesions with slight umbilication and thin dry reddish black scabs; the others were small and dry with flaky yellowish crusts. The pox lesions were just beginning to regress; their size which was quite uniform was approximately the same as that of the largest Board of Health vaccine lesions. Practically all were umbilicated, the large central depressed portion being covered with a thick tenacious black or reddish black crust. On the 15th day when the experiment was terminated, the culture vaccine area was practically negative. All that remained of the neurovaccine lesions were a few small dry scabs covering slight cutaneous thickenings. The smaller lesions of the Board of Health vaccine were also healed; the few larger ones could still be detected but rapid resolution and healing were evident. The pox lesions were definitely regressing but they were still large and prominent. Post mortem examination of the calf revealed no gross abnormalities of the viscera.

The results on the rabbits inoculated with the same specimens of viruses used for the calf are of interest from a comparative standpoint.

Two rabbits were injected intratesticularly and on a scarified skin area with pox virus. Both developed fever and a typical orchitis with scrotal edema. One died on the 5th day without developing cutaneous lesions either in the inoculated area or elsewhere. The other animal developed a papular skin eruption on the 4th day which was not confined to the lines of scarification; recovery eventually took place. This case was one of the rare instances in which intratesticular injection of pox virus was not associated with a fatal outcome (1). It is probable that the potency of this particular specimen of virus was lower than usual.

Each of the four viruses was used for the inoculation of a rabbit by the scarified skin route and in addition, 2 rabbits were inoculated with all four viruses as was done in the case of the calf. In each injection area a well marked reaction developed. Speaking generally, the most marked reaction was observed with pox virus, next in order was that of neurovaccine, while those of the culture vaccine and of the Board of Health vaccine virus were less pronounced. On the day following inoculation the skin along the lines of scarification was swollen and congested. By the 3rd day this change was conspicuous and in addition small papules were developing in the scarifications. On the 4th and 5th days definite differences in degree of the four reactions became apparent. The pox lesions comprised broad bands or welts of swollen hemorrhagic edematous skin with central lines or streaks of necrosis covered by black crusts. Papules of the same character, that is with hemorrhage, edema, and necrosis, were present not only in these areas, but in the shaved skin outside them. The neurovaccine lesions were similar in appearance but the degree of swelling, hemorrhage, and edema was less marked and the necrosis was more superficial and less extensive. In the case of both the Board of Health and the culture vaccine lesions, the skin along the scarified lines was very much less swollen and congested than with

either the pox or the neurovaccine lesions. There was an accumulation of fine dry yellowish crusts along the lines which was especially abundant in the Board of Health vaccine lesions, and in addition there were many discrete and confluent small papules, the majority of which had yellowish or yellowish red centers covered with thin dry crusts.

A week after inoculation the pox lesions for the most part still appeared active although some of the more superficial portions were beginning to heal. Areas of skin between and beyond the scarifications had become edematous and hemorrhagic and here there was no indication of regression. In the rabbit inoculated only with pox virus, papules in distant skin areas and of the mucocutaneous borders of the lips had developed, together with a nodular orchitis and a popliteal adenitis. Similar lesions were observed in both rabbits inoculated with pox and the three vaccine viruses, but not in the rabbits inoculated only with the respective vaccine viruses. In contrast to the continued activity of the pox lesions a week after inoculation, the lesions of the three vaccine viruses had regressed considerably, particularly in the case of the Board of Health and culture vaccines. By the 10th day healing of the pox lesions was well under way.

The reactions of the calf and the rabbit to pox virus, on the one hand, and to the three vaccinia viruses, on the other, were of the same order as far as the size, general character, and course of the local lesions were concerned, but there were definite species differences with respect to the vaccine viruses. In the case of the calf the reaction to pox virus was more pronounced than any of the reactions to the vaccine viruses. Of the latter, the reaction to the Board of Health vaccine was more pronounced than those of neurovaccine and of culture vaccine. In the case of the rabbit, pox virus again induced the most severe lesions, but those of neurovaccine were more marked than those of the Board of Health and the culture vaccines.

The results of this experiment indicate, as did the others reported in this paper, that a relationship of some sort but not complete identity exists between the virus of rabbit pox, on the one hand, and dermo- and neurovaccine viruses, on the other.

#### SUMMARY AND CONCLUSIONS

Experiments are reported in which it was shown that rabbits which had recovered from experimental or spontaneous rabbit pox were refractory to inoculation of pox virus injected by various routes, and in addition did not develop clinical manifestations of the disease under conditions of exposure to florid cases of pox.

It was found that pox recovered rabbits were susceptible to inocula-

tion with the virus of virus III disease of rabbits and that virus III recovered rabbits could be successfully inoculated with pox virus. Furthermore, virus III recovered rabbits developed pox when subjected to room exposure in the same manner as did normal rabbits. It thus appears that there is no specific relationship between the two viruses.

Rabbits which had recovered from experimental or spontaneous pox were found to be just as susceptible to inoculation with the virus of infectious myxoma of rabbits as were normal rabbits, a result which demonstrates that there is no specific relationship between these viruses.

Rabbits which had recovered from experimental or spontaneous pox were refractory to inoculation with culture dermovaccine virus, but vaccine recovered rabbits were not completely refractory to inoculation with pox virus. Under conditions of exposure to clinical cases of pox, adult vaccine immune rabbits did not develop clinical manifestations of pox, but young, recently weaned vaccinated rabbits did contract mild but definite clinical pox.

Experimental pox recovered rabbits were partially refractory to inoculation with neurovaccine virus and neurovaccine recovered rabbits were partially refractory to inoculation with pox virus. The refractory condition of the pox immune rabbits appeared to be more pronounced than that of the neurovaccine immunes.

The cutaneous lesions which developed from the intradermal injection of pox, neurovaccine, and culture vaccine viruses showed definite differences with respect to the rate and persistence of active growth, amount of edema, hemorrhage, and necrosis, and the degree of tissue destructiveness. These features were most pronounced in the lesions of pox virus and were least marked in the lesions of culture vaccine virus. The differences were particularly apparent in normal rabbits, but they were also present in the lesions which developed in immune animals.

It was found that the calf was susceptible to inoculation with pox virus applied to a scarified skin area. There were many similarities in the appearance and course of the pox lesions to those resulting from culture vaccine virus, the New York Board of Health vaccine, and neurovaccine virus similarly inoculated. But the pox lesions



were most numerous, much the largest and most destructive, and by far the most persistent while next in order were those of the Board of Health dermovaccine.

The results of these various experiments showed that a close relationship obtains between pox virus, on the one hand, and vaccine virus and neurovaccine virus, on the other, but it cannot be said that pox virus is identical in all respects with either one of these viruses. The findings indicated that the relationship between pox and neurovaccine viruses is closer than that between pox and culture vaccine viruses. Upon the basis of the results observed in culture (dermo) vaccine immune rabbits inoculated with or exposed to pox, it appeared that vaccination with vaccine virus offered a method of protection against rabbit pox.

#### BIBLIOGRAPHY

1. Pearce, L., Rosahn, P. D., and Hu, C. K., *J. Exp. Med.*, 1936, **63**, 241.
2. Rosahn, P. D., Hu, C. K., and Pearce, L., *J. Exp. Med.*, 1936, **63**, 259.
3. Rosahn, P. D., Hu, C. K., and Pearce, L., *J. Exp. Med.*, 1936, **63**, 379.
4. Greene, H. S. N., *J. Exp. Med.*, 1934, **60**, 427, 441; 1935, **61**, 807; **62**, 305.
5. Pearce, L., Rosahn, P. D., and Hu, C. K., *Proc. Soc. Exp. Biol. and Med.*, 1934, **31**, 657; *Arch. Path.*, 1934, **18**, 579.

#### EXPLANATION OF PLATES

FIGS. 1 through 8. 6 days after intradermal injection of testicular tissue-virus emulsions. Each virus injected at 3 sites in 0.3 cc. doses.

#### PLATE 27

FIGS. 1 and 2. Normal control rabbit. Fig. 1. Right side injected with rabbit pox virus: active massive confluent lesions with extensive hemorrhage, edema, and necrosis. Fig. 2. Upper left side injected with dermo- (culture) virus: small lesions practically healed. Lower left side injected with neurovaccine virus: well advanced regression of moderate sized nodular lesions; subsidence of edema and hemorrhage and healing of necrotic areas.

FIGS. 3 and 4. Dermo- (culture) vaccine immune rabbit. Fig. 3. Right side injected with rabbit pox virus: regressing large necrotic lesions. Fig. 4. Upper left side injected with dermo- (culture) vaccine virus: negative; luxuriant growth of hair. Lower left side injected with neurovaccine virus: marked regression of moderate sized lesions.

FIGS. 5 and 6. Neurovaccine immune rabbit. Fig. 5. Right side injected with rabbit pox virus: regressing moderate sized lesions; hemorrhage, edema, and necrosis still present. Fig. 6. Upper left side injected with dermo- (cul-

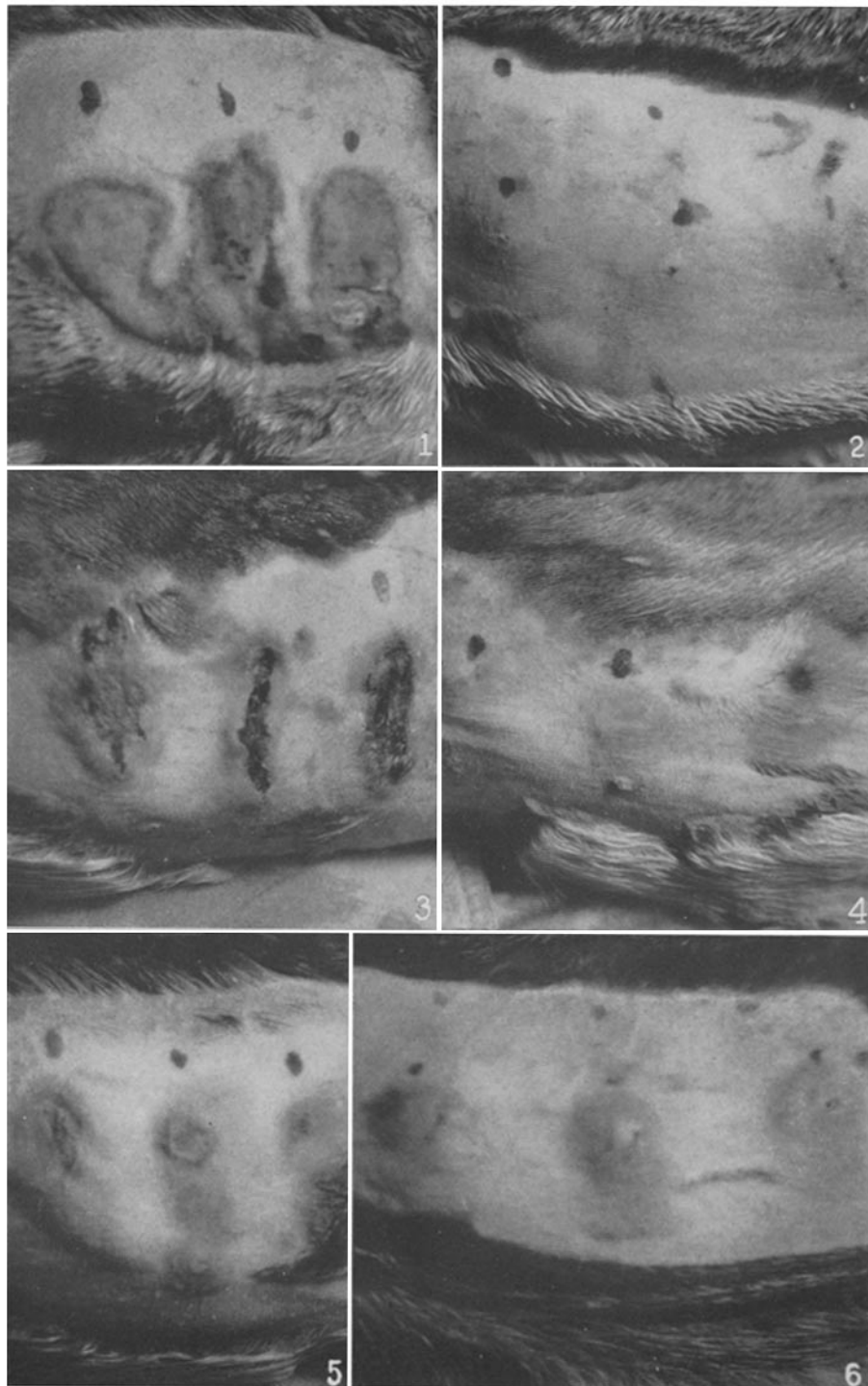
ture) vaccine virus: negative. Lower left side injected with neurovaccine virus: regressing moderate sized lesions; some edema, congestion, and slight necrosis still present.

PLATE 28

FIGS. 7 and 8. Rabbit pox immune rabbit. Fig. 7. Right side injected with rabbit pox virus: negative; small superficial cutaneous thickenings. Fig. 8. Upper left side injected with dermo- (culture) vaccine virus: negative. Lower left side injected with neurovaccine virus: partially positive; regressing small nodules.

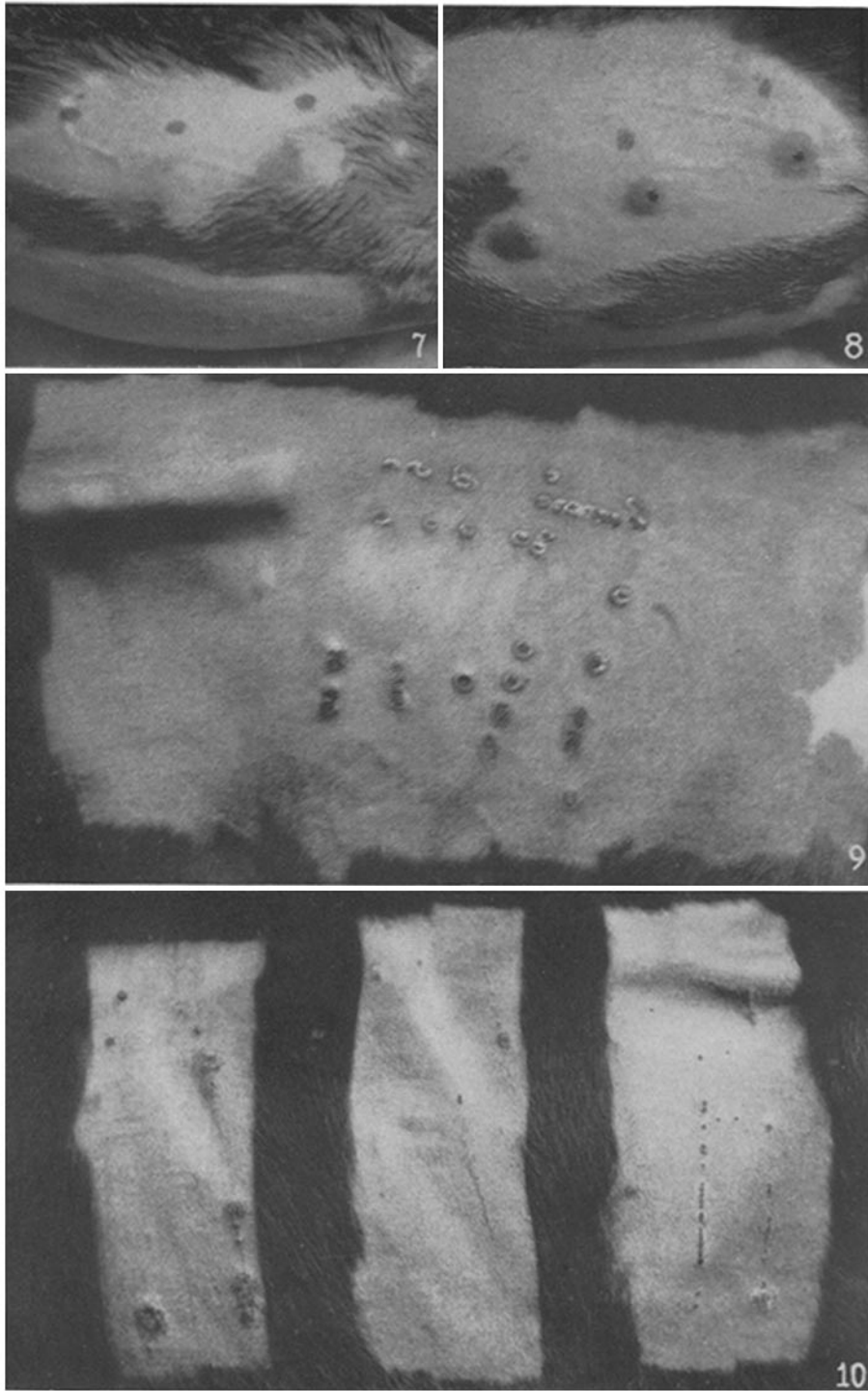
FIG. 9. Cutaneous reaction of a calf 8 days after the application of rabbit pox virus to a scarified area on the right side of the body.

FIG. 10. Cutaneous reactions of a calf 8 days after the application of vaccine viruses to scarified areas on the left side of the body; same animal as in Fig. 9. Left area, New York City Board of Health dermovaccine; middle area, dermo- (culture) vaccine virus; right area, neurovaccine virus.



Photographed by Joseph B. Haulenbeek

(Hu *et al.*: Etiology of rabbit pox. III)



Photographed by Joseph B. Haulenbeck

(Hu *et al.*: Etiology of rabbit pox. III)