

PRODUCTION OF EXPERIMENTAL OSTEOMYELITIS IN
RABBITS BY INTRAVENOUS INJECTION OF
STAPHYLOCOCCUS AUREUS

By R. H. S. THOMPSON,* M.D., AND R. J. DUBOS, PH.D.

(From the Hospital of The Rockefeller Institute for Medical Research)

PLATES 4 AND 5

(Received for publication, April 28, 1938)

In the course of experiments designed to compare the virulence of different strains of staphylococcus in rabbits, it was observed that two of the animals developed well characterized bone lesions following the intravenous injection of a certain strain of *Staphylococcus aureus*.

The literature concerning the production of staphylococcal osteomyelitis in experimental animals reports many conflicting results; most workers failed to produce the condition unless elaborate procedures were resorted to in the hope of localizing the staphylococci in the bones. As early as 1885, however, Rodet (1) had succeeded in producing bone abscesses in rabbits by the intravenous injection of cultures of *Staphylococcus aureus*, and even before that time other attempts had been made involving the preliminary production of local trauma by fracture or contusion of the bones. Yet in 1922 Starr (2) stated that he found "great difficulty in producing osteomyelitis in the dog, even with staphylococci or streptococci of known virulence in man," and was finally induced to use the laborious technique of ligating the appendix and its mesentery, after which he injected the mixed organisms from the peritoneal exudate into a nutrient artery or into a traumatized metaphysis; by this means he succeeded in producing acute osteomyelitis in growing dogs, but in every case the animal died within 48 hours, so that the late changes of bone destruction and sequestration were never seen. Various other more or less elaborate techniques have also been used; thus Kuwahata (3) and Takahashi (4) first fed their animals on a diet deficient in ascorbic acid, while Haldeman (5) implanted cultures into holes drilled into the metaphysis. Yet as late as 1935 Baudet and Cahuzac (6) injected staphylococci into rabbits by the intravenous, subperiosteal, and intrametaphyseal routes, and concluded that it was impossible to produce a true osteomyelitis in experimental animals. Shioda (7) on the other hand, obtained consistent results by the intravenous injection of a strain of staphylococcus isolated from a case of osteomyelitis; his publication,

* Adrian Stokes Travelling Fellow, Gillson Research Scholar of the Society of Apothecaries of London.

however, is more concerned with the pathology of the condition than with the problem of its production.

The present paper records observations on osteomyelitis which appeared in rabbits following inoculation with a strain of *Staphylococcus aureus*. They seem the more worth recording in view of the contradictory results which have been obtained by other workers.

Methods and Materials

1. *Description of the Strain.*—The strain of staphylococcus (OH) used in this study was isolated from the lungs in a fatal case of bronchopneumonia admitted to this hospital 19 years ago. During these 19 years the culture has been transferred once a month on meat infusion agar; it was not possible to find any record of animal passage. The strain belongs to the *aureus* type, although it forms only very small amounts of the orange pigment. No effort has been made to place it in any of the recent schemes of classification of staphylococci. The culture is strongly hemolytic and forms an active coagulase. Throughout the present work it has been carried in meat infusion broth.

2. *Experimental Procedure.*—Rabbits were infected intravenously with a small dose of a broth culture, and were then observed daily for the development of any swelling, tenderness, or loss of function of any of the limbs. In 3 of the experiments x-ray photographs were taken of the animals before death and also of any inflamed bones after removal from the body at autopsy. In many of the cases, particularly where no obvious suppuration was visible, smears of the bone marrow were stained and examined microscopically for the presence of staphylococci and for evidence of an inflammatory reaction.

The autopsies were carried out with the primary purpose of detecting any bone lesions; particular attention, however, was also paid to the condition of the joints, in the hope of deciding whether lesions in the metaphyses of the long bones were due to a primary osteomyelitis or to a spread from a primary purulent arthritis. In all cases in which the pus was cultured on blood agar plates, staphylococci were recovered in pure culture from the bone abscesses. Any bones presenting evidence of inflammation, or of a periostitis, were removed from the body at autopsy; the majority of the soft tissue around the bone was then cut away, and the bone lesion more clearly defined.

Virulence of the Strain for Rabbits

Since the culture (OH) had been maintained on nutrient agar over a period of 19 years, an effort was made to raise its virulence by animal passage.

The culture was injected into normal rabbits by the intravenous route. In its original condition the culture failed to cause obvious signs of infection when used

in amounts of 0.5 cc. or less; on the other hand 2 rabbits inoculated with 1 cc. died within 24 hours and a pure culture was recovered from the heart blood. This passage strain was injected into new rabbits; one of the animals inoculated with 0.5 cc. culture under the conditions described in Experiment 1 became pyrexial and was killed after 17 days. A pure culture of *Staphylococcus aureus* was recovered from a bone abscess found at autopsy and this culture was designated as OH 172.

Culture OH 172 has been inoculated into a number of normal young and adult rabbits. In all cases 0.1 cc. was found to kill the animals within 48 hours after injection, whereas 0.01 and 0.001 cc. caused the development of a chronic form of infection associated with pyrexia.

It is evident, therefore, that the virulence of the strain for the rabbit increased markedly as a result of animal passage.

The Production of Experimental Osteomyelitis in Rabbits

The following experiment had been planned in order to test the virulence of this particular strain of staphylococcus. The infection became subacute in 2 of the infected rabbits; they developed swellings in the regions of the limbs. As it was suspected that the underlying cause might be an osteomyelitis, autopsies were carried out.

Experiment 1.—4 rabbits were inoculated with the heart blood culture of the OH strain mentioned above; 2 received 0.1 cc. (rabbits 1 and 2) and 2 received 0.01 cc. (rabbits 3 and 4).

Rabbit 1 died 4 days later; culture of the heart blood gave a mixed growth of staphylococci and Gram-negative cocci. This culture was discarded. The other 3 rabbits remained apparently normal, and were reinoculated with larger amounts of the same culture, rabbit 2 receiving 1 cc. of culture and rabbits 3 and 4, 0.5 cc. each. Rabbit 2 developed a palpable fluctuating swelling of the left knee, and was killed on the 20th day after reinfection. Rabbit 3 developed a massive, fluctuating swelling in the region of the left shoulder joint and was killed on the 17th day. Rabbit 4 died on the 2nd day after reinfection; no autopsy was performed.

Autopsy Findings.—Rabbit 2. Left knee joint distended in the gross with yellow, viscous pus. Extensive bone destruction of lateral and posterior surfaces of lateral condyle of left femur. Area of softening and hyperemia also present on lateral aspect of upper end of tibial portion of left tibiofibula. Right knee joint contained small amount of seropurulent fluid; marked softening and hyperemia, with subperiosteal bleeding points, of medial aspect of upper end of right tibia; bone very readily penetrated by a blunt probe; medullary cavity contained viscous semipurulent material. Bone marrow smear from left femur showed large

numbers of staphylococci, many of which were undergoing destruction, many polymorphonuclear leucocytes, and extensive phagocytosis. Bone marrow smear from left tibia showed very few staphylococci and large numbers of polymorphonuclear leucocytes.

Rabbit 3. Large abscess containing yellowish white, inspissated pus surrounding upper end of left humerus and left shoulder joint. Humero-acromial joint disorganized, and joint cavity full of pus. Extensive bone destruction of head and neck of left humerus, and replacement of the marrow with pus. A pure culture of *Staphylococcus aureus* was recovered from this abscess; as already mentioned, this culture was designated as OH 172, and subsequent experiments were carried out with this strain. Moderate bone destruction of glenoid cavity of scapula. Encapsulated subperiosteal collection of pus present on the outer side of twelfth left rib, at about two-thirds of the way along its length from the costovertebral joint. Bone marrow smear from humerus showed large numbers of staphylococci and pus cells; moderate amount of phagocytosis also present.

In view of the positive results obtained in 2 of the animals in Experiment 1, 3 more rabbits were infected.

Experiment 2.—3 normal adult rabbits (Nos. 5, 6, and 7) were inoculated with 0.1 cc. each of a culture of OH 172. All 3 rabbits died within 48 hours. On account of the acute course of the infection autopsies were not performed.

It is apparent that, in order to obtain convincing evidence of bone inflammation in rabbits inoculated with staphylococci, it is essential to arrange the experimental conditions so as to obtain a relatively prolonged course of the infection. To achieve this end an attempt was made to establish in rabbits a low grade of immunity, prior to infection, by immunizing them with suspensions of killed staphylococci. The results described above, illustrating the virulence of the culture, have shown that if the infective dose be high enough, the rabbits die within a very few days; care was therefore taken to avoid using infective doses large enough to cause a fulminating course of the infection.

Experiment 3.—6 normal adult rabbits (Nos. 8 to 13) weighing about 2000 gm. each, were immunized with the following materials.

(a) 2 cc. of formol were added to 150 cc. of a broth culture of OH 172; the bacterial suspension was allowed to stand at room temperature for 48 hours. It was then centrifuged and resuspended in 15 cc. of $m/20$ phosphate buffer at pH 7.0.

(b) 200 cc. of a broth culture OH 172 were brought to pH 4.3 with acetic acid, and allowed to stand at this pH for 5 days at 37°C. The cells were then centrifuged and resuspended in 20 cc. saline.

(c) The cells from 150 cc. of a broth culture OH 172 were centrifuged, re-suspended in 15 cc. saline, and then heated at 80°C. for 30 minutes.

The animals received 0.5 cc. of the bacterial suspension by the intravenous route on 3 consecutive days. Rabbits 8 and 9 received the formalized suspension; rabbits 10 and 11 the cells killed with acetic acid; and rabbits 12 and 13 the heat-killed cells. All 6 rabbits were inoculated 1 week later with 0.1 cc. of a broth culture of OH 172. Rabbits 8, 10, 11, and 12 became very sick; rabbit 12 died on the 8th day, rabbits 10 and 11 on the 9th day, and rabbit 8 on the 10th day; in none of them was it possible to obtain clinical evidence of any localized inflammation. Rabbits 9 and 13 developed a chronic condition; x-ray photographs were taken of their hind limbs on the 24th day.

X-Ray Photographs of Rabbit 9.—Large area of rarefaction present in the metaphysis at upper end of left tibia, visible in both anteroposterior and lateral views.

X-Ray Photographs of Rabbit 13.—Upper end of right fibula thickened, with a rounded area of rarefaction present in it. Localized area of rarefaction also present in compact bone at medial aspect of upper end of left tibia.

By the 29th day rabbit 13 was showing marked loss of use of both hind limbs. Rabbit 9, however, appeared no worse, so 0.5 cc. of a broth culture of the same staphylococcal strain was injected intravenously. Both animals were killed on the 33rd day. Rabbits 10 and 12 showed evidence of bone inflammation at autopsy.

Autopsy Findings.—Rabbit 8. Large collection of pus overlying upper end of right fibula; on dissection an area of bone destruction was discovered at lateral aspect of upper end of bone, with frank pus in medullary cavity. Large abscess also present in lower end of left femur; left knee joint contained a serous exudate. Localized collection of pus attached to 9th right rib, with bony destruction of wall of rib and pus in medullary cavity. Bone marrow smears from lesions in fibula and femur both showed presence of large numbers of staphylococci and pus cells.

Rabbit 9. Marked roughening and absorption of bone in region of upper metaphysis of left tibia, with multiple bleeding points on raising the periosteum. Bone easily perforated by blunt probe. Area of irregular subperiosteal new bone also present on shaft of left tibia. X-ray photograph of left tibia after death showed marked rarefaction of head of the bone. Bone marrow smear showed presence of Gram-positive cocci, a few polymorphonuclear leucocytes, and some lymphocytes.

Rabbit 11. Abscess present in soft tissues overlying anterolateral aspect of right tibia. Underlying bone presented an area of spongy new bone deposition.

Rabbit 13. Marked irregular thickening of upper half of right fibula, with an abscess eroding through posterior wall at upper end. Small, localized bone abscess at upper end of medial border of left tibia; posterior surface of upper end of the bone also showed marked softening and hyperemia. X-ray photograph

of the bones after death showed irregular thickening of upper end of right fibula with several rounded areas of rarefaction; mottling of upper end of right tibia with small area of rarefaction in compact bone along medial aspect. Bone marrow smear from fibula showed presence of large numbers of staphylococci and pus cells; smear from left tibia showed many pus cells, but no cocci.

X-ray photographs of the bone lesions in rabbits 9 and 13 are shown in the accompanying plate (Figs. 1 to 7).

The results of the previous experiments show that under suitable conditions it is possible to produce inflammation of the bones in normal adult rabbits by the mere intravenous injection of staphylococci. In view of the fact that in human beings staphylococcal osteomyelitis is much more common in young individuals than in adults, it was of interest to apply the experimental procedure used in Experiment 3 to younger rabbits.

Experiment 4.—9 young rabbits (Nos. 14 to 22), about 2 months old, were immunized on 3 consecutive days by the intravenous injection of 0.5 cc. of a formalized suspension of staphylococci (prepared as in Experiment 3). The 9 rabbits were inoculated 7 days later with 0.1 cc. of a culture of OH 172. Rabbits 15, 16, 18, and 22 were found dead on the morning of the 2nd day; autopsies were not done, as it was considered too early to show any macroscopic bone changes. The other 5 rabbits died at various times within the next 8 days; all of them showed marked weakness and loss of appetite, but it was not possible to detect in them any definite localizing signs suggestive of bone involvement.

Autopsy Findings.—Rabbit 14. Suppurative arthritis of right knee joint. No visible bone suppuration or inflammation. Right femur and right tibiofibula removed for x-ray examination. X-ray photographs of femur showed mottling and trabeculation of upper end of bone, with a circumscribed area suggestive of advanced bony absorption in the neck. Right tibia showed no abnormality. Bone marrow smear from neck of right femoral head showed many polymorphonuclear leucocytes, a few Gram-positive cocci and many Gram-negative cocci at varying stages of autolysis; extensive phagocytosis.

Rabbit 17. Marked hyperemia of soft tissues overlying upper end of right tibiofibula. On dissection, right fibula seen to be hyperemic and roughened, with multiple subperiosteal bleeding points; no suppuration or advanced bone destruction. Bone marrow smear from fibula showed many Gram-positive cocci and pus cells.

Rabbit 19. No evidence of bone inflammation. Slight suppurative arthritis of right ankle joint.

Rabbit 20. Suppuration and bone destruction in left scapula, near the vertebral border. Also in upper end of right tibia at its posterior aspect. Suppura-

tive arthritis of right elbow joint, with bone abscess in lateral border of olecranon process of right ulna. X-ray photographs of isolated bones showed extensive bone destruction along vertebral border of left scapula; area of rarefaction at lateral aspect of upper end of left tibiofibula. On dissecting away the soft tissues surrounding the lower end of the left tibiofibula, an area of destruction of the wall of the bone was discovered corresponding to the lesion in the x-ray picture, the cavity being filled with yellowish white pus. Bone marrow smears from scapula, right tibia, and left tibiofibula all showed the presence of large numbers of staphylococci and some pus cells.

Rabbit 21. Inflammation and hyperemia of soft tissues overlying posterior aspect of lower end of left femur; subjacent bone hyperemic and roughened, with bleeding points on raising the periosteum; bone readily penetrated by blunt probe. Bone marrow smear showed large numbers of staphylococci and polymorphonuclear leucocytes; some phagocytosis and some leucocytes undergoing destruction.

The results of Experiment 4 show that culture OH 172 is so virulent for young rabbits that most of them survived the injection of 0.1 cc. of the culture for only a few days, even though they had received a course of immunization prior to infection. In the hope of prolonging the course of the disease, the infective dose was therefore cut down to 0.01 cc.

Experiment 5.—6 young rabbits (Nos. 23 to 28) were given 3 courses of immunization by a method similar to that used in the preceding experiment. 7 days after the last immunizing dose each of them received 0.01 cc. of a broth culture of OH 172. On the following day all the animals became pyrexial; daily rectal temperatures were taken throughout the course of the disease:

Rectal Temperatures

Day.....	1	2	3	4	6	7	8	9	10	11	13
Rabbit 23	106.1	106.2	106.7	106.1	105.5	104.7	102.8	98.6	102.9	102.1	Killed
24	106.2	106.3	105.9	105.4	105.9	105.5	104.7	105.1	—	99.8	Killed
25	106.4	105.7	105.8	105.1	105.1	105.1	104.6	104.4	Killed		
26	106.4	106.0	106.3	105.4	105.3	105.3	104.4	103.4	Died		
27	105.8	106.0	106.6	105.1	105.1	103.5	102.6	101.6	—	Killed	
28	105.6	106.6	106.4	105.2	105.6	105.3	105.1	102.6	Killed		

All 6 rabbits became very sick; palpable swellings became noticeable in the limbs; and x-ray photographs were taken of the animals on the 7th day.

X-Ray Photographs on the 7th day.—Rabbit 23. Area suggestive of rarefaction at lower end of left femur.

Rabbit 24. Marked evidence of rarefaction at lower end of right femur, with appearance suggestive of sequestration. Suggestion of bony absorption at upper end of right tibia.

Rabbit 25. No bone abnormality observed.

Rabbit 26. Area of rarefaction with suggestion of sequestration at upper end of left tibia.

Rabbit 27. No bone abnormality observed.

Rabbit 28. Area of rarefaction at head of right femur, with suggestion of bone destruction at lower end of the bone just above the condyles.

Rabbits 23 and 24 had x-ray pictures taken again on the 13th day and then were killed.

X-Ray Photographs on 13th day.—Rabbit 23. Marked rarefaction at lower end of left femur; small rounded area of rarefaction also present at upper end of left tibia.

Rabbit 24. Large area of rarefaction with suggestion of sequestration at lower end of right femur. Similar appearance present at upper end of right tibia. Rarefaction also visible on lesser trochanter of right femur and at medial aspect of lower end of left femur. Bone erosion also apparent at head of left fibula.

Autopsy Findings.—Rabbit 23. Abscess with extensive bone destruction at lower end of left femur, situated on the posteromedial aspect of medial condyle. Suppuration and bone destruction also present at posterior aspect of upper end of left tibia and at upper end of right tibia.

Rabbit 24. Abscesses with varying degrees of bone destruction found at the following sites: lateral aspect of upper end of left fibula; medial aspect of lower end of left tibia; medial aspect of upper end of right tibia; anterior aspect of lower end of right femur; anterior aspect of lesser trochanter of right femur; medial aspect of lower end of left femur; lateral aspect of greater trochanter of left femur; olecranon process of right ulna; posterior aspect of upper end of left humerus; 7th right rib; vertebral border of right scapula.

Rabbit 25. Abscesses with varying degrees of bone destruction present in greater trochanter of right femur, upper end of right fibula, upper end of left tibia (with sequestrum), medial aspect of head of left humerus, upper end of right tibia, lower end of left tibia, and lower end of right femur. Right knee joint contained a serous exudate, but no pus. Bone marrow smears from right fibula and left tibia showed many polymorphonuclear leucocytes and much phagocytosis; a few extracellular Gram-positive staphylococci.

Rabbit 26. Area of spongy hyperemic bone, with multiple subperiosteal bleeding points, at lateral aspect of upper end of left tibia; no suppuration visible on surface of bone. Small abscess over anterior border of right tibia, with subjacent area of bony roughening with some new bone deposition. Bone marrow smear from left tibia showed marked infiltration with polymorphonuclear leucocytes; some evidence of phagocytosis; no extracellular cocci seen.

Rabbit 27. Small, localized abscess over lesser trochanter of left femur; area of bone destruction in subjacent bone with a separated sequestrum. Abscesses with bone destruction also present on medial aspect of upper end of left tibia, medial and inferior aspect of head of left humerus and 10th right rib.

Rabbit 28. Large abscess with bone destruction at posterior aspect of medial condyle of right femur. Suppuration and bone destruction also present at head of right femur. Suppurative arthritis of right hip joint. Bone marrow smear from lower end of femur showed large numbers of staphylococci and pus cells.

The X-ray photographs of some of the bone lesions in Rabbits 24 and 25 are shown in the accompanying plate (Figs. 8 to 15).

Experiment 6.—The 3 rabbits (Nos. 29 to 31) in this experiment were used for a virulence test of culture OH 172. Since two of them developed bone lesions they have been included in the present series.

Rabbit 29 was injected with 0.0001 cc. of a broth culture of OH 172, rabbit 30 with 0.001 cc., and rabbit 31 with 0.01 cc. All 3 rabbits became pyrexial. Rabbit 29 developed a gross swelling in the region of the left knee. Rabbit 30 progressed without the development of any physical signs. Rabbit 31 developed a massive, tense swelling of the right fore leg, and was killed on the 9th day. The other 2 animals were killed after x-ray photographs had been taken on the 19th day.

X-Ray Photographs on 19th Day.—Rabbit 29. Rarefaction with loss of outline of medial condyle of left femur; some blurring of epiphyseal line.

Rabbit 30. No bone abnormality observed.

Autopsy Findings.—Rabbit 29. Suppurative arthritis of left knee joint. Extensive bone destruction of lower end of left femur with erosion through the epiphysis and articular surface. Articular surface of upper end of left tibia also eroded, but lesion did not progress deeply into the bone, and appeared to be secondary to the advanced suppuration in the joint cavity.

Rabbit 30. No evidence of bone inflammation.

Rabbit 31. Bone abscess with sequestration at posterior aspect of lower end of right tibia. Suppuration and bony destruction present at lower end of left humerus, with suppurative arthritis of the elbow joint. Small abscess with area of bone erosion also present at upper end of left humerus. Very extensive bony destruction and suppuration in the right humerus, affecting almost the entire thickness of the bone, and bursting through and eroding a large area of the lateral aspect of the bone. Subperiosteal collection of pus attached to 3rd right rib; on dissection it was found to have tracked out from the rib, the medullary cavity containing thick white pus.

A summary of the lesions found in the autopsies described above, together with the length of the disease process in days, is given in Table I. Table II shows the number and localization of the lesions found. Photograph of bone abscesses in a humerus and in a rib is shown in Text-fig. 1.

TABLE I
Summary of Lesions

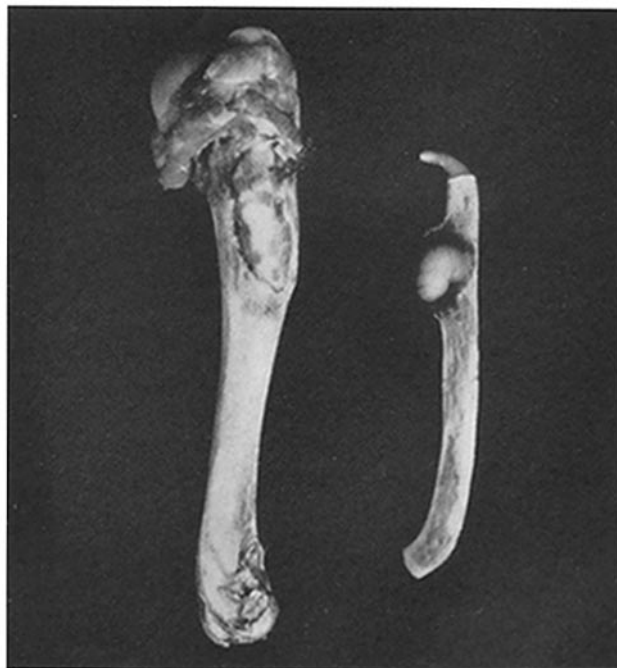Rabbit	Length of disease process <i>days</i>	Number and distribution of bone lesions
1	4	Nil
2	20	(1) Lower end left femur (2) Upper end left tibia (3) Upper end right tibia
3	17	(1) Head left humerus (smear) (2) 12th left rib
4	1	Nil
5	1-2	Nil
6	1-2	Nil
7	1-2	Nil
8	10	(1) Upper end right fibula (2) Lower end left femur (3) 9th right rib
9	33	Upper end left tibia
10	9	Nil
11	9	Right tibia (subperiosteal osteogenesis)
12	8	Nil
13	33	(1) Upper end right fibula (2) Upper end left tibia
14	4	Neck right femur
15	2	Nil
16	2	Nil
17	2	Upper end right fibula
18	2	Nil
19	5	Nil
20	8	(1) Vertebral border left scapula (2) Upper end right tibia (3) Olecranon process right ulna (4) Lower end left tibiofibula

TABLE I—*Concluded*

Rabbit	Length of disease process	Number and distribution of bone lesions
	<i>days</i>	
21	3	Lower end left femur
22	2	Nil
23	13	(1) Lower end left femur (2) Upper end left tibia (3) Upper end right tibia
24	13	(1) Upper end left fibula (2) Lower end left tibia (3) Upper end right tibia (4) Lower end right femur (5) Upper end right femur (6) Lower end left femur (7) Upper end left femur (8) Olecranon process right ulna (9) Upper end left humerus (10) 7th right rib (11) Right scapula
25	10	(1) Lower end right femur (2) Greater trochanter right femur (3) Upper end right fibula (4) Upper end right tibia (5) Head left humerus (6) Upper end left tibia (7) Lower end left tibia
26	10	(1) Upper end left tibia (2) Upper end right tibia
27	11	(1) Lesser trochanter left femur (2) Upper end left tibia (3) Head left humerus (4) 10th right rib
28	10	(1) Lower end right femur (2) Head right femur
29	19	(1) Lower end left femur (2) Upper end left tibia
30	19	Nil
31	9	(1) Lower end right tibia (2) Lower end left humerus (3) Upper end left humerus (4) Upper end right humerus (5) 3rd right rib

TABLE II
Number and Localization of Lesions

Total number of animals used.....	31
Number of animals surviving immediate toxic effects of injection.....	22
Number of animals with bone lesions.....	18
Total number of lesions.....	55
Relative frequency of site of lesions:	
Upper end of tibia.....	14
Lower end of femur.....	9
Upper end of femur.....	6
Upper end of humerus.....	6
Fibula.....	5
Ribs.....	5
Lower end of tibia.....	4
Scapula.....	2
Ulna.....	2
Lower end of humerus.....	1
Shaft of tibia.....	1



TEXT-FIG. 1. Photograph of bone abscesses after removal of bones from the body and after the soft tissues had been dissected away. The humerus shows an area of bone destruction on its anterior aspect with pus lying in the eroded area; the rib shows an encapsulated collection of pus issuing from its external surface.

DISCUSSION

The object of the present study is to describe the conditions under which a certain strain of staphylococcus (OH) causes the development of bone lesions in rabbits; the study is not aimed at an analysis of the pathology of staphylococcal osteomyelitis.

The strain of staphylococcus used in this work had been cultivated on meat infusion agar over a period of 19 years; it proved to be of a very low degree of virulence for the rabbit. Following animal passage, however, and especially after recovery of the strain from a bone abscess discovered in one of the rabbits infected with a large dose, the virulence increased so markedly that 0.1 cc. of the culture was sufficient to kill adult animals in 24 to 38 hours.

Such a fulminating course of the infection is not favorable for the development of easily recognizable bone lesions, and it seemed likely that the production in the rabbits of a low degree of antistaphylococcal immunity (antibacterial or antitoxic) would help towards the production of a chronic type of infection. The data, however, are not sufficient to demonstrate that immunization was of great significance in determining the development of bone lesions, and it is possible that satisfactory results would have been obtained by the mere injection of small infective doses into normal rabbits (Experiment 6). On the other hand, immunization did appear to stabilize the animals against the early lethal effect of larger doses of staphylococci, and thereby facilitated the production of progressive bone inflammation through a wider range of infective doses.

In any case the results do show that staphylococcal osteomyelitis has been produced in a large number of experimental animals. 31 rabbits in all have been used; 9 of these animals died shortly after they had been infected with living staphylococci, before sufficient time had elapsed to allow the development of bone lesions recognizable with the naked eye. Of the 22 animals in which the infection assumed a subacute course, lasting from 1 to 3 weeks, 18, or 81.8 per cent showed definite macroscopic evidence of bone inflammation. In the cases where frank suppuration and advanced bone destruction were absent, microscopic examination of stained smears taken from the bone marrow, in every case supported the slight macroscopic evidence such as subperiosteal hyperemia and visible sponginess of

the bone. The bone lesions varied from mere hyperemia and softening of the bone, with multiple subperiosteal bleeding points, to advanced abscess formation with suppuration and extensive bone destruction.

Fifty-five bone lesions were present in the 18 animals showing evidence of bone inflammation; of these 47 occurred near the ends of the long bones, yet only 8 of these were associated with a purulent arthritis; moreover, from an examination of the sites of bone destruction in the isolated bones, and from the appearance of the articular cartilages, we feel that the purulent arthritis, when present, was probably secondary to the bone lesion, being caused by a spread of the inflammatory process in the metaphysis through the epiphysis and articular surface. A serous effusion into neighboring joint cavities was, however, a fairly common concomitant of metaphyseal lesions, while in one case (rabbit 19) a purulent arthritis was present without any coexisting bone inflammation.

Several points of interest have emerged suggesting a close similarity between the experimental condition and the disease as occurring in children. Firstly, the characteristic predilection of the organism to produce inflammation in the metaphyses of the long bones, particularly at the upper end of the tibiofibula and at the lower end of the femur. Secondly, the relative infrequency of spread of a metaphyseal abscess through the epiphysis into the neighboring joint cavity. Thirdly, the pyrexial course of the infection in the acute stage, with lapse into a chronic condition of advanced suppuration in those animals that survived the acute stage. And, fourthly, in chronic cases the presence of multiple bone abscesses.

Multiple abscesses in the kidneys, often bilateral, were present in the majority of cases, but the muscles and other viscera were usually strikingly free from signs of inflammation.

In view of the ease with which the results described in the present paper were obtained, it is surprising that the literature on the subject should contain so many conflicting results, but from the present work it seems possible that at least three factors are of importance in the experimental production of staphylococcal osteomyelitis. Firstly, it would appear that the particular strain of staphylococcus used may play a deciding rôle in the production of the condition experimentally;

whether or not the strain of staphylococcus used in this study possesses a special affinity for bone tissue, in other words, whether there exist "osteostains" of this bacterial species, must remain, for the present, an open question. Secondly, it appears to be of importance in facilitating the detection of early lesions to arrange the experimental conditions in such a way as to bring about a relatively prolonged type of infection, and the results reported here suggest that preliminary immunization may be a decided help in achieving this end by rendering the animals more resistant to the early lethal effects of large doses. And thirdly, there are indications suggesting that the use of young rabbits, with a high degree of vascularity in the growing metaphyses, influences favorably the production of the condition, a fact that is borne out when the age incidence of staphylococcal osteomyelitis in human beings is recalled.

SUMMARY

1. The conditions under which a certain strain of staphylococcus (OH 172) causes in rabbits the development of bone inflammation have been described.

2. The virulence of the strain for rabbits was markedly raised by passage through this animal species, and especially after the culture had been recovered from a bone abscess.

3. The results indicate that it is possible to produce consistently inflammation of the bones of rabbits by the mere intravenous injection of a suitable strain of staphylococcus, without resorting to any elaborate operative technique designed to localize the organisms in the bones. It appears also that the inflammatory process so produced bears a close resemblance to staphylococcal osteomyelitis as occurring in human beings.

BIBLIOGRAPHY

1. Rodet, A., *Compt. rend. Acad. sc.*, 1885, **99**, 569.
2. Starr, C. L., *Arch. Surg.*, 1922, **4**, 567.
3. Kuwahata, H., *Deutsch Z. Chir.*, 1930, **222**, 374.
4. Takahashi, R., *Arch. klin. Chir.*, 1934, **181**, 103.
5. Haldeman, K. O., *Surg., Gynec. and Obst.*, 1934, **59**, 25.
6. Baudet, G., and Cahuzac, M., *Rev. chir.*, 1935, **73**, 801.
7. Shioda, T., *Arch. klin. Chir.*, 1936, **185**, 141.

EXPLANATION OF PLATES

PLATE 4

FIG. 1. Right knee of rabbit 9, 24 days after infection, no abnormality.

FIG. 2. Left knee of rabbit 9, 24 days after infection; area of rarefaction present at upper end of tibia.

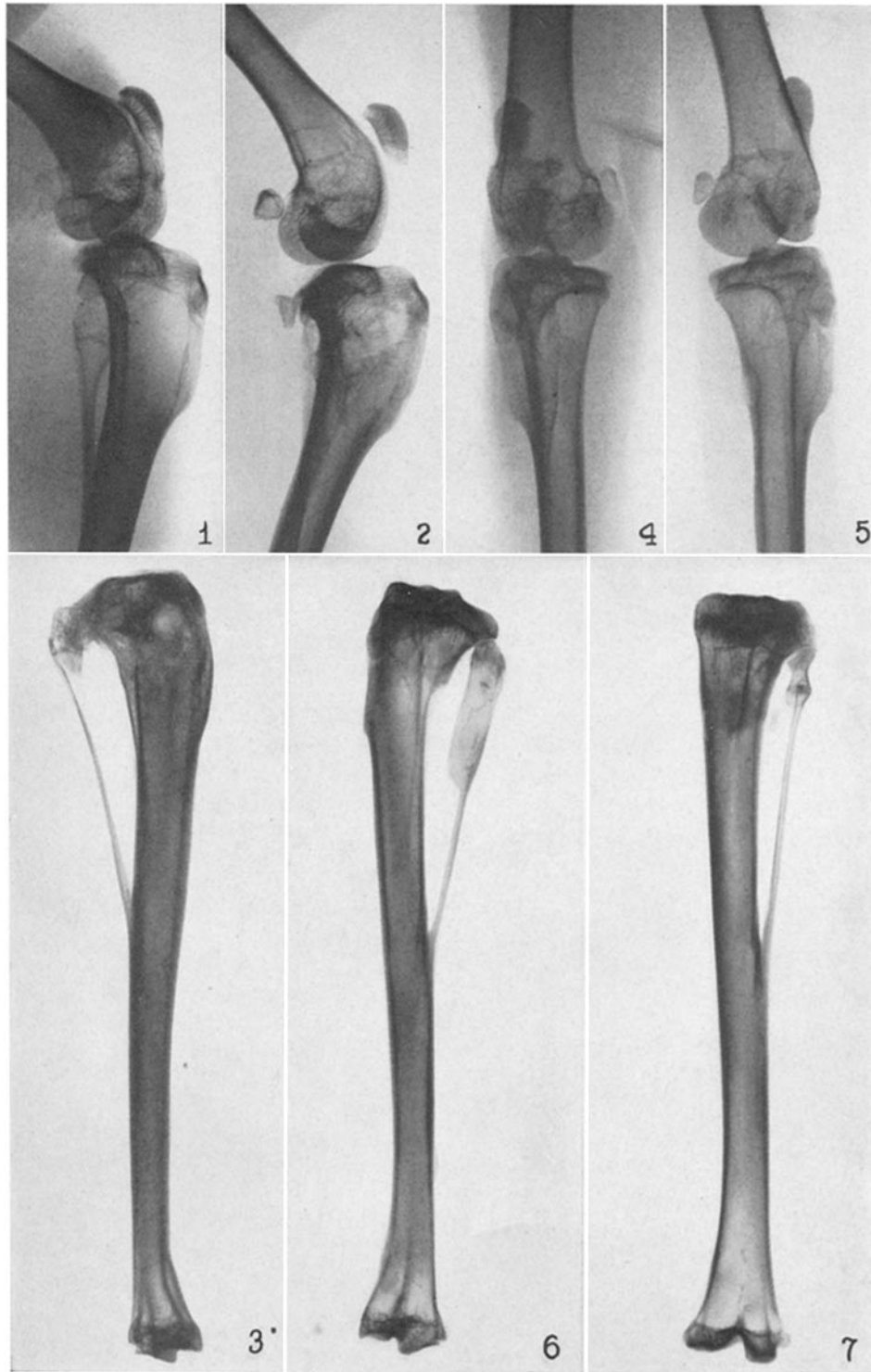
FIG. 3. Left tibiofibula of rabbit 9 showing area of rarefaction at upper end of tibial portion.

FIG. 4. Right knee of rabbit 13, 24 days after infection; thickening of fibula showing rounded area of rarefaction.

FIG. 5. Left knee of rabbit 13, 24 days after infection; localized area of rarefaction at upper end of tibia.

FIG. 6. Right tibiofibula of rabbit 13; thickening and rarefaction of fibular portion.

FIG. 7. Left tibiofibula of rabbit 13; rarefaction of compact bone at upper end of tibial portion.



(Thompson and Dubos: Experimental staphylococcus osteomyelitis)

PLATE 5

FIG. 8. Right knee of rabbit 24, 7 days after infection; rarefaction at lower end of femur and at upper end of tibia.

FIG. 9. Left knee of rabbit 24, 7 days after infection; no abnormality.

FIG. 10. Right knee of rabbit 24, 13 days after infection; changes more advanced than in Fig. 8; suggestion of sequestration in femoral lesion.

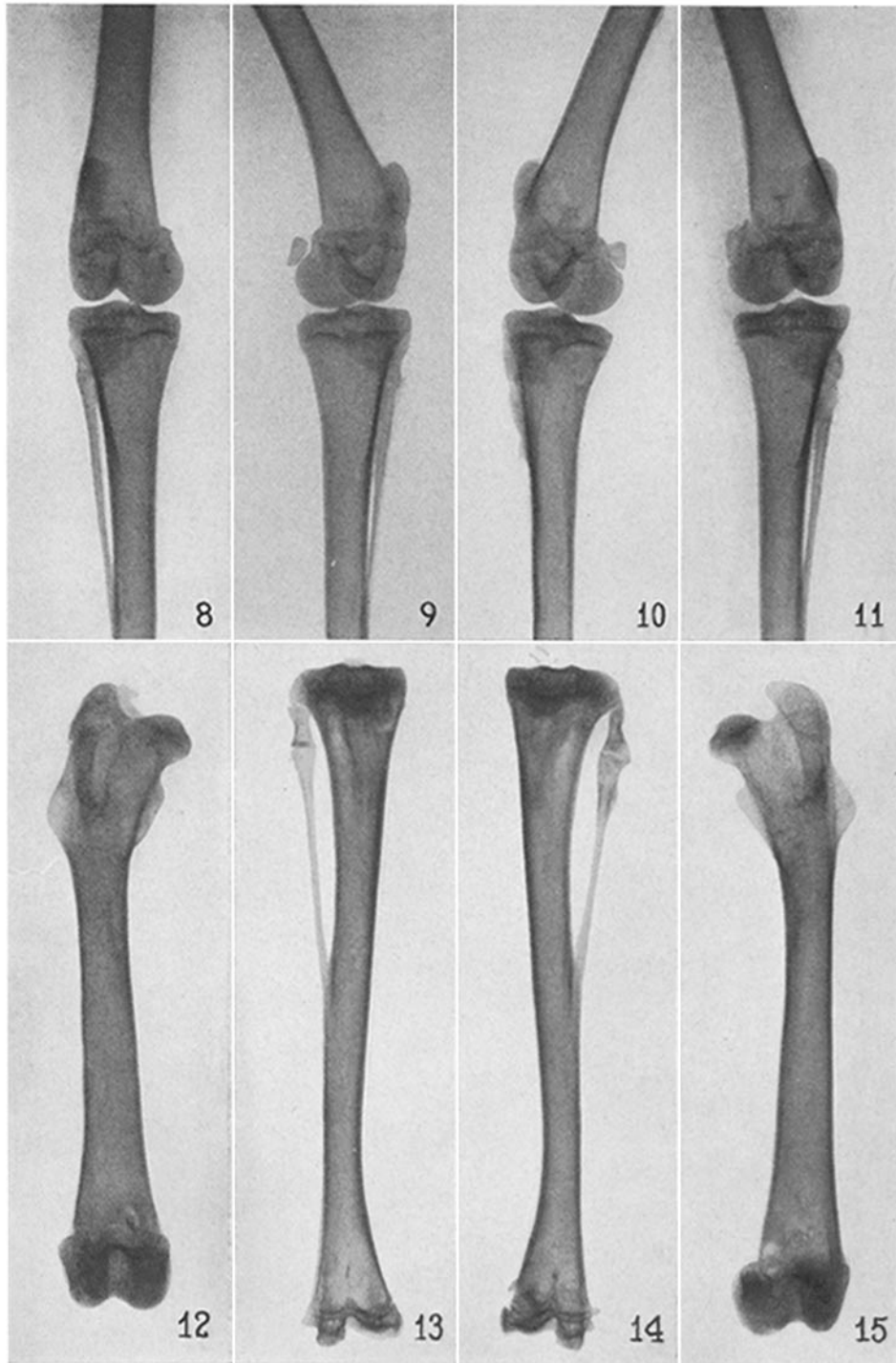
FIG. 11. Left knee of rabbit 24, 13 days after infection; rarefaction at medial aspect of lower end of femur; also erosion of upper end of fibula.

FIG. 12. Right femur of rabbit 24; lesion with appearance of sequestration at lower end.

FIG. 13. Right tibiofibula of rabbit 24; rarefaction at upper end of tibial portion.

FIG. 14. Left tibiofibula of rabbit 24; irregularity at upper end of fibula; rarefaction at medial aspect of lower end of tibiofibula.

FIG. 15. Left femur of rabbit 23; rarefaction at lower end above the medial condyle; sequestrum visible.



(Thompson and Dubos: Experimental staphylococcus osteomyelitis)