

HISTOLOGICAL CHANGES FOLLOWING OVARIECTOMY IN MICE

I. dba HIGH TUMOR STRAIN*

BY ELIZABETH FEKETE, GEORGE WOOLLEY, PH.D., AND C. C. LITTLE, Sc.D.

(From the Roscoe B. Jackson Memorial Laboratory, Bar Harbor)

PLATES 1 TO 3

(Received for publication, April 16, 1941)

The formation of nodular hyperplasia of the suprarenal cortex and the development of mammary tumors in dba mice ovariectomized at birth have been reported by us in a short paper (1). Since then further data have been secured which enable us to follow the suprarenal changes from their earliest manifestation to the fully formed abnormalities and correlate these with the changes taking place in the vagina, uterus, and mammary glands.

The observations are based on data collected from 95 dba female mice which were ovariectomized at birth and killed at different ages. This particular strain has about 50 per cent breast tumor incidence in the virgin females.

Method

The ovariectomy was performed on the first post partum day. The mice were anesthetized by chilling. They were placed on a sheet of paper in the freezing compartment of an electric refrigerator for about 7 minutes. Small dorsal incisions were made and each ovary, together with its capsule and part of the oviduct, was removed. A dissecting microscope was used to aid in locating these organs. Each incision was closed by one stitch taken with fine white silk thread. The mice survived the operation well, and their mothers readily accepted and continued to take care of them.

At the autopsy of every animal a careful search was made to ascertain whether any ovarian regeneration had taken place. All suspicious areas were sectioned but in no case was ovarian regeneration found.

Changes in the Suprarenal Gland

In all the castrated animals killed after 3 to 4 months of age the suprarenals show characteristic changes which progressively lead to the formation of nodular hyperplasia. Most of the glands were studied on serial sections.

The earliest changes consist of the hypertrophy of a few cells of the zona

* Supported in part by a grant from the Josiah Macy, Jr., Foundation, and in part by a grant from The Jane Coffin Childs Memorial Fund for Medical Research.

glomerulosa. Normally the cells of this zone are small and have relatively large compact nuclei and slightly basophilic cytoplasm. Their cell outlines are indistinct. After undergoing hypertrophy the nuclei become large and vesicular. The cytoplasm increases in amount, accumulates lipoid, stains lighter, and the cell outlines are more distinct. Such cells occasionally are found in the process of cell division (Fig. 1). Simultaneously groups of small, densely arranged cells appear immediately below the capsule and spread around the hypertrophied cells. These subcapsular cells are polyhedral in shape, having deeply staining round nuclei and slightly basophilic cytoplasm. They soon extend in between the cell columns of the zona fasciculata and here they become spindle-shaped and strikingly resemble the cells of the ovarian stroma. As the subcapsular cells increase in number by mitosis they are seen first to interrupt the normal arrangement of the cells of the zona fasciculata, and later to invade and replace the cells of all three zones of the cortex. This invasion soon results in the formation of a wedge-shaped abnormal area such as is shown in Fig. 2. After the apex of the wedge reaches the medulla the sinusoid circulation of this part is disturbed and large blood-filled lakes are often found surrounding the abnormal areas. The changes described frequently occur at 2 or 3 different parts of the cortex.

Gradually the small polyhedral subcapsular cells of the abnormal area increase considerably in size; the cytoplasm accumulates lipoid and the nucleus becomes vesicular (Fig. 3). Later the enlarged cells form groups of cell nests, which are surrounded by spindle-shaped cells (Fig. 4). At this stage these enlarged cells are indistinguishable from the hypertrophied zona glomerulosa cells. By the increase in the size of the cell components the wedge-shaped areas change into rounded nodules, and often involve large parts of the cortex (Fig. 5). The structure of such nodules resembles those lutein cells of mouse ovaries which develop from atretic follicles. The cytoplasm of some of these cells often contains yellow pigment. Occasionally the pigmented cells fuse and form large multinuclear giant cells.

In some cases the enlarging abnormal nodules cause bulging of the surface (Fig. 6). In other cases the nodules project toward the center of the gland and push the medulla into an eccentric position. In several glands enlargements occur in both directions (Fig. 7). Still further growth results in the invasion and finally in the breaking through of the capsule, after which a mushroom-like outgrowth occurs and results in the involvement of the surrounding adipose tissue (Fig. 8). In extreme cases large areas of the surrounding tissues are involved. Since the circulation is seriously disturbed, necrosis, thrombosis, and calcification in the central area have been seen to occur (Fig. 9).

The same suprarenal frequently contains several abnormal nodules which may show different phases of the changes described. Even in the most

extreme involvement some normal cortical and medullary tissue is always present. The advanced changes are visible in the gross, enlarging the gland and giving it a nodular outline.

Diffuse carcinoma of the suprarenal appeared in four animals. In three of these mice one gland was entirely involved, while the other gland showed nodular hyperplasia. In the carcinomatous glands two kinds of cells predominate: (1) The first type of cell is usually present at the periphery and at some places forms adenomatous areas. These are small polyhedral cells with dark staining oval nuclei, containing coarse chromatin granules, which are very similar to the subcapsular cells, present at an early stage of nodular hyperplasia. (2) The second type of cell forms the central part of the tumors and is arranged in diffuse rounded areas. In these cells the cell outlines are indistinct, the oval and vesicular nuclei are lighter staining and contain very fine chromatin granules. Both areas show mitotic activity. In one of these tumors areas of necrosis and calcium deposits were found. Metastasis was not observed. All three of these animals were between the ages of 18 and 20 months.

In a fourth animal belonging in the same age group and showing far advanced nodular hyperplasia, a small area of diffuse carcinoma composed of the first type of cells showing very active growth was present (Fig. 9).

Changes in the Uterus

The uterus remains undeveloped and has a very small diameter until about 6 to 7 months of age. Microscopic sections during this period show the typical slit-like lumen, lined by inactive epithelial cells, the small atrophic uterine glands, and the dense cellular lamina propria which are so characteristic of this organ in castrated animals (Fig. 10).

The gradual changes which begin to take place between 7 and 12 months after castration are identical with those induced in the uterus of castrated animals by the injections of estrogen. An increase in the diameter is noticeable in the gross. Microscopic observations show an enlarged uterine lumen, an increase in the height of the epithelial cells and active cell division. The uterine glands also undergo similar changes. The lamina propria becomes greatly thickened by marked edema and hyperemia and, therefore, appears less cellular. The thickening of the muscle layers is mainly due to a size increase of the smooth muscle fibers, although occasionally mitosis also occurs (Fig. 11). The increase in size of the uterus reaches its height between about 11 and 16 months. Fig. 12 shows a section of the uterus at 15 months after castration. The epithelial cells show considerable mitotic activity and edema of the lamina propria is marked.

In many animals the uterine glands are greatly dilated and contain secretion. After about 550 days there is a slight decrease in size and hyperemia is less

marked. Individual variations exist in the degree of development, which seem to be correlated with the abnormal condition of the suprarenal glands.

Changes in the Vagina

Vaginal smears of several animals were examined. Estrous cycles were detected, although they occurred irregularly. Many of the vaginas were sectioned and examined microscopically. The observed changes taking place here were also comparable with the changes which can be induced by estrogen injections in the adult ovariectomized animals.

TABLE I

This table indicates the approximate time of the changes taking place in the suprarenal and the accessory sex organs. The observations did not include all the accessory sex organs of all animals.

Age	Suprarenal			Uterus			Vagina			Mammary glands examined microscopically			Tumors of mammary glands			
	No. of mice examined	Normal	Changing	Nodular hyperplasia	No. of mice examined	Typical castrate	Stimulated	No. of mice examined	Typical castrate	Stimulated	No. of mice examined	Under developed	Stimulated	Adenoma	Carcinoma	Other tumors
	mos.	per cent	per cent	per cent		per cent	per cent		per cent	per cent		per cent	per cent			
3-6	6	33.3	66.6		6	100		4	100		6	100				
6-9	5		40	60	3	66.6	33.3	3	66.6	33.3	4	75	25			2
9-12	6		16.4	83.6	16	16.4	83.6	3		100	5		100			3
12-15	14		14.2	85.8	13	30.7	69.3	1		100	7		100		2	11
15-18	23			100	19		100	8		100	15		100	1	9	4
18-21	30			100	25		100	19		100	25		100	1	18	16
21+	11			100	10	10	90	4		100	6		100	1	5	1

The epithelial lining of the vagina remains in an atrophic condition until about 6 to 7 months after castration. Gradually marked thickening of the stratified epithelial lining is noticeable. Cornification, mucification, as well as invasion with leukocytes, are easily recognizable phases.

The Mammary Glands

All mammary glands of the experimental animals were examined by palpation and the glands of 68 mice were studied microscopically. In general the glands remained rudimentary for about 8 months, and were comparable in size to the gland system of a 3 weeks old female. After that period the ducts gradually lengthened and the formation of end-bulbs occurred. In many

cases the ducts proximal to the nipples were irregularly dilated. Later, side-branches developed from the preexisting ducts, and some alveolar areas were formed. An unevenness in the length and branching of the different glands of the same animal was frequently noticed. The youngest mouse to show a malignant mammary tumor was 14 months of age. Between the ages of 14 and 27 months the autopsy records of 75 animals show that 37 of them had tumors of the mammary glands (3 adenomas and 34 carcinomas).

Table I shows the data in tabulated form.

DISCUSSION

It is a generally accepted fact that the endocrine function of the ovaries dominates the uterus, vagina, and the mammary glands. Post pubertal ovariectomy results in the cessation of cyclic activities and in degeneration of these organs. The degree of atrophy is proportional to the time which passed between ovariectomy and autopsy (2). After injections of estrogen, rapid changes take place in the uterus and vagina and result in a recovery of these organs from the castrate condition (3). According to Allen (4) these changes are valuable criteria of ovarian endocrine function.

In the present experiment, although the animals were ovariectomized at birth and careful examination showed that no ovarian regeneration has taken place, the vagina, uterus, and mammary gland slowly recovered from the castrate condition and reached a state which they presumably can attain only under the influence of estrogen. The probability, therefore, exists that estrogen originated in some other organ in the absence of ovaries. The consistent nodular hyperplasia of the suprarenal cortex and close morphological similarity of these nodules to lutein-like cells of the ovaries points to the abnormal suprarenals as the possible source of estrogen.

A comparison of our results with the experiments conducted by Parkes and Brambell (5, 6) is instructive. These investigators exposed the ovaries of mice at birth to x-ray irradiation. The sterile ovaries evidently produced estrogen since the uteri and vaginas of these animals killed at adult ages did not show castration changes, but appeared stimulated. Estrous cycles developed in a normal manner and ceased after ovariectomy. In trying to analyze which ovarian elements were responsible for the production of estrogen the investigators came to the conclusion that the cords of cells which, after irradiation, proliferated from the germinal epithelium together with their connective tissue sheaths were the probable chief source. They state that the tissue of this "first proliferation often becomes like luteal tissue, the epithelial cells becoming like luteal cells, with connective elements of the sheath growing in amongst them like the thecal cells of the corpus luteum." The photomicrograph which illustrates this luteal-like ovarian tissue in their article has a striking resemblance to the structure of the areas of suprarenal nodular

hyperplasia of our experimental animals. Fig. 13 shows such an area for comparison. The close and common regional embryonic origin of the ovary and suprarenal cortex might account for the possibility that proliferating undifferentiated subcapsular cells of the suprarenal produced areas which were not only similar in structure to the ovaries but also in hormone production.

The time element in the production of these suprarenal areas is evidently an important one. The formation of hyperplastic nodules is a slow, gradual process, and the effect of estrogen on the uterus, vagina, and mammary glands can be definitely detected only after about 8 to 10 months. It is possible that late castration does not leave sufficient life span for markedly effective changes.

It seems important to emphasize the possibility that all strains of mice do not have the capability in the same degree for suprarenal changes following castration. Some evidence is already at hand pointing to the fact that in the C57 black mice, castrated at birth, the vagina, uterus, and mammary glands do not in all cases recover from the castrate state.

Clinical data seem to indicate that suprarenal cortical tumors in women lead to virilism. However, it should be kept in mind that to detect the effect of estrogen-producing components of abnormal suprarenals in the presence of even perhaps atrophied sterile ovaries would be more difficult. That such possibility might exist should be kept in mind. Frank (7) described two cases in which a large carcinoma of the suprarenal cortex in women was accompanied by increased amount of estrogen excretion in the urine. Pregnancy tests were negative.

In man a feminizing effect of suprarenal cortical tumors expressed by the enlargement of the breasts has been noted. Simpson (8) summarized five such reports and added a new case history. He stated that in his case "the adrenal tumor and its metastases were the source of the estrogenic hormone." In all these cases, where observations of the testes are included, it was stated that they were smaller than normal.

The feminizing effect of hyperplastic suprarenal nodules in castrated male mice has been observed and reported by us (9) and will be described more fully in a later paper.

CONCLUSIONS

1. In dba mice ovariectomized at birth the vagina, uterus, and mammary glands showed a gradual recovery from the castrate state, and finally reached the stage which they presumably can attain only under the influence of estrogenic hormones. Tumors of the mammary glands developed in 37 animals, of 75 examined, between the ages of 14 and 28 months (3 adenomas and 34 carcinomas).

2. As ovarian regeneration had not taken place the probability that estrogen originated in some other organ in the absence of the ovaries is suggested.

3. The consistent nodular hyperplasia of the suprarenal cortex and close morphological similarity of cells of these nodules to lutein-like cells of the ovaries points to the abnormal suprarenals as possible sources of the estrogenic hormones.

BIBLIOGRAPHY

1. Woolley, G., Fekete, E., and Little, C. C., *Proc. Nat. Acad. Sc.*, 1939, **25**, 277.
2. Parkes, A. S., *The internal secretions of the ovary*, New York, Longmans, Green and Co., 1929.
3. Allen, E., Doisy, E. A., *et al.*, *Am. J. Anat.*, 1924, **36**, 133.
4. Allen, E., *Sex and internal secretions*, Baltimore, The Williams & Wilkins Co., 1939.
5. Parkes, A. S., and Brambell, F. W. R., *J. Roy. Micr. Soc.*, 1927, **47**, 97.
6. Brambell, F. W. R., Parkes, A. S., and Fielding, U., *Proc. Roy. Soc. London, Series B*, 1927, **101**, 95.
7. Frank, R. T., *Proc. Soc. Exp. Biol. and Med.*, 1934, **31**, 1204.
8. Simpson, S. L., and Joll, C. A., *Endocrinology*, 1938, **22**, 595.
9. Woolley, G., Fekete, E., and Little, C. C., *Endocrinology*, 1941, **28**, 341.

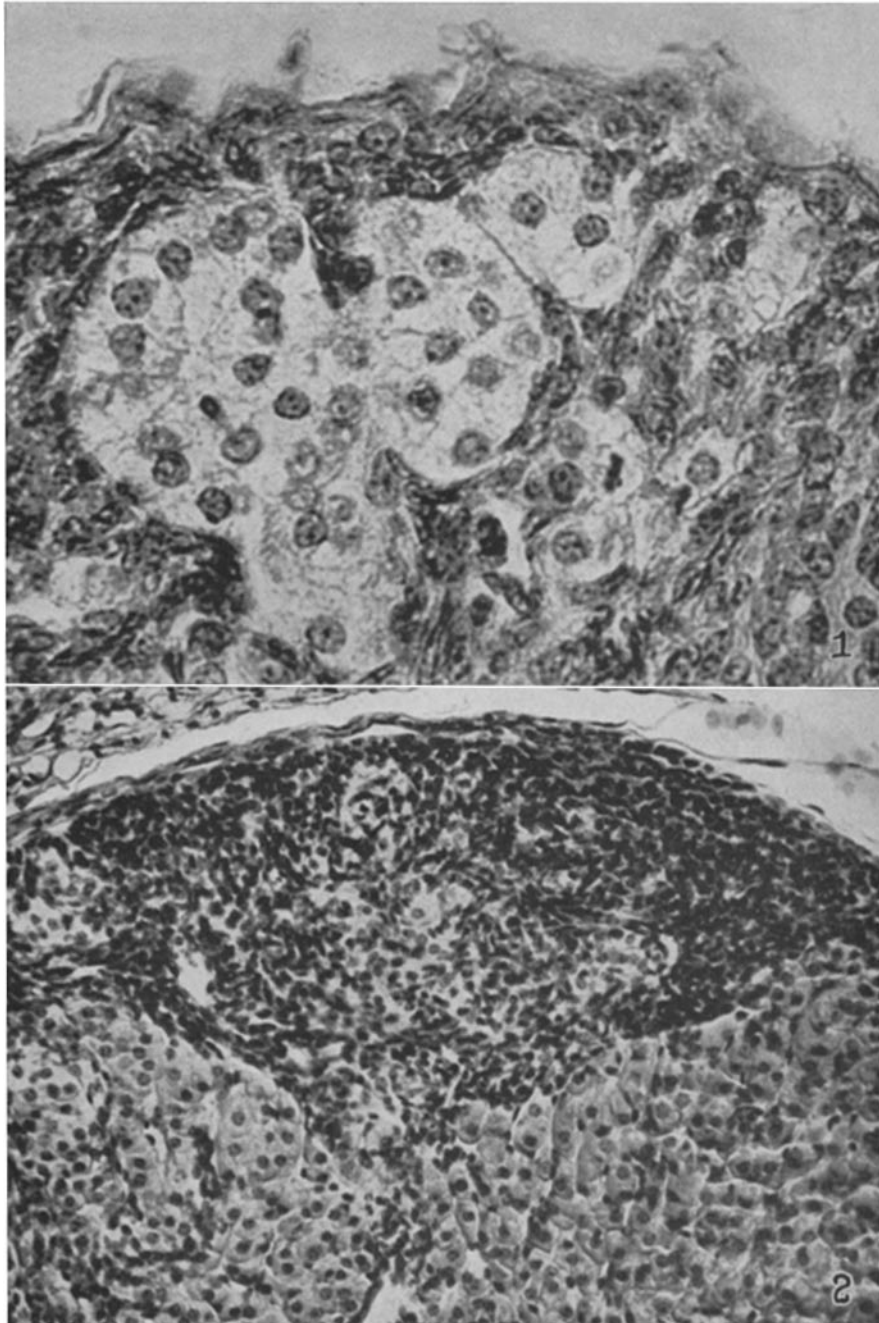
EXPLANATION OF PLATES

All the sections used for illustration were stained with hematoxylin and eosin.

PLATE 1

FIG. 1. Suprarenal of a 3 months old mouse showing hypertrophy of a group of zona glomerulosa cells. Note the mitotic figure. $\times 600$.

FIG. 2. Suprarenal of a $7\frac{1}{2}$ months old mouse showing the wedge-shaped area formed by proliferating subcapsular cells. $\times 300$.



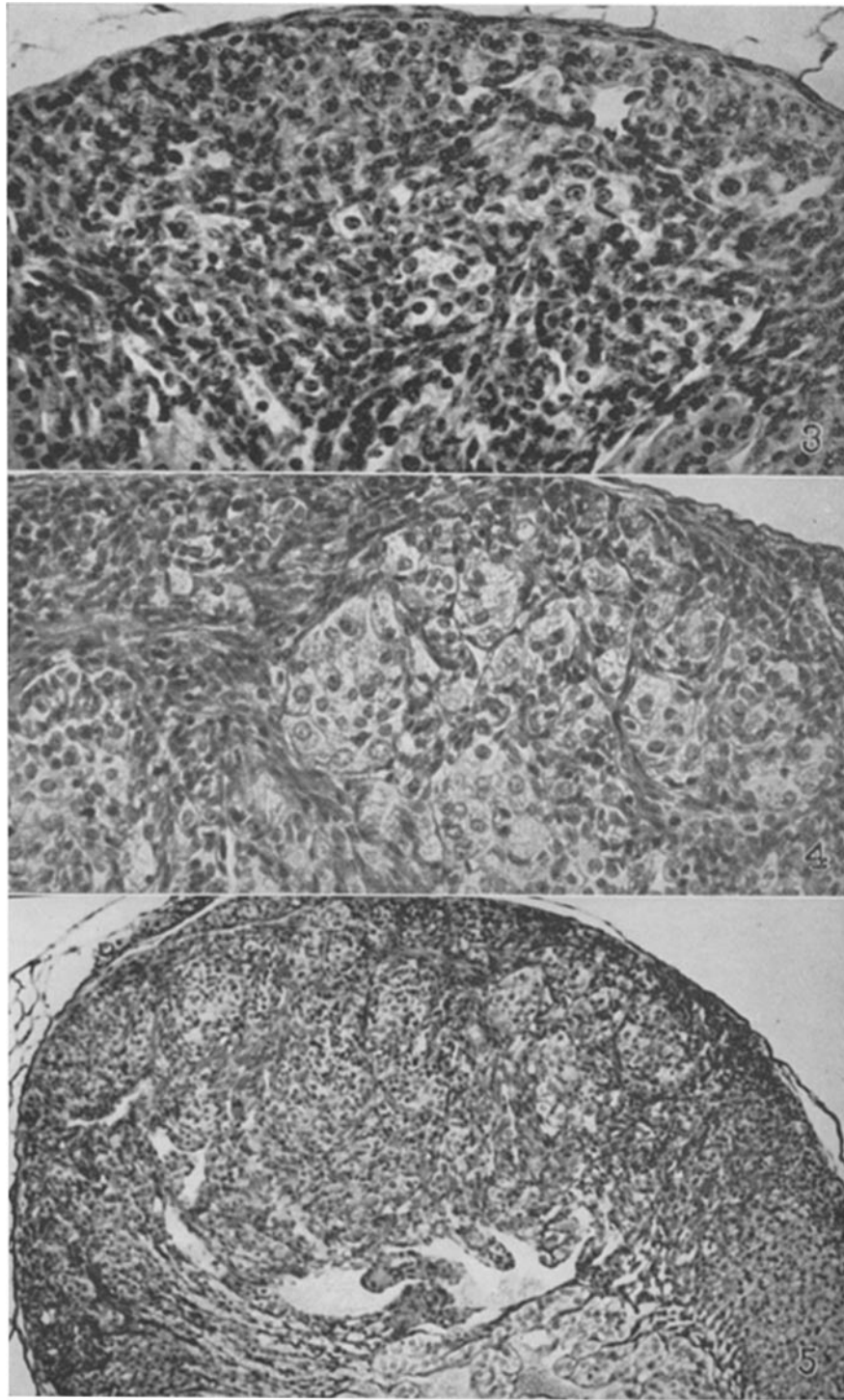
(Fekete *et al.*: Histological changes following ovariectomy. I)

PLATE 2

FIG. 3. Suprarenal of an 8 months old mouse showing beginning hypertrophy of the subcapsular cells in the wedge-shaped area. $\times 300$.

FIG. 4. Suprarenal of a $10\frac{1}{2}$ months old mouse showing groups of enlarged cells surrounded by spindle shaped cells. $\times 275$.

FIG. 5. Suprarenal of a $10\frac{1}{2}$ months old mouse showing a round nodule of hyperplasia extending from the capsule to the medulla and showing typical blood lakes. $\times 100$.



(Fekete *et al.*: Histological changes following ovariectomy. I)

PLATE 3

FIG. 6. Suprarenal of a 19 months old mouse with advanced nodular hyperplasia. $\times 20$.

FIG. 7. Suprarenal of a 20 months old mouse showing the extension of abnormal nodules toward the center and toward the periphery of the gland. Note that the capsule has been broken through and the surrounding adipose tissue invaded. $\times 20$.

FIG. 8. Suprarenal of a 12 months old mouse showing that the abnormal area broke through the capsule and invaded the surrounding adipose tissue. $\times 66$.

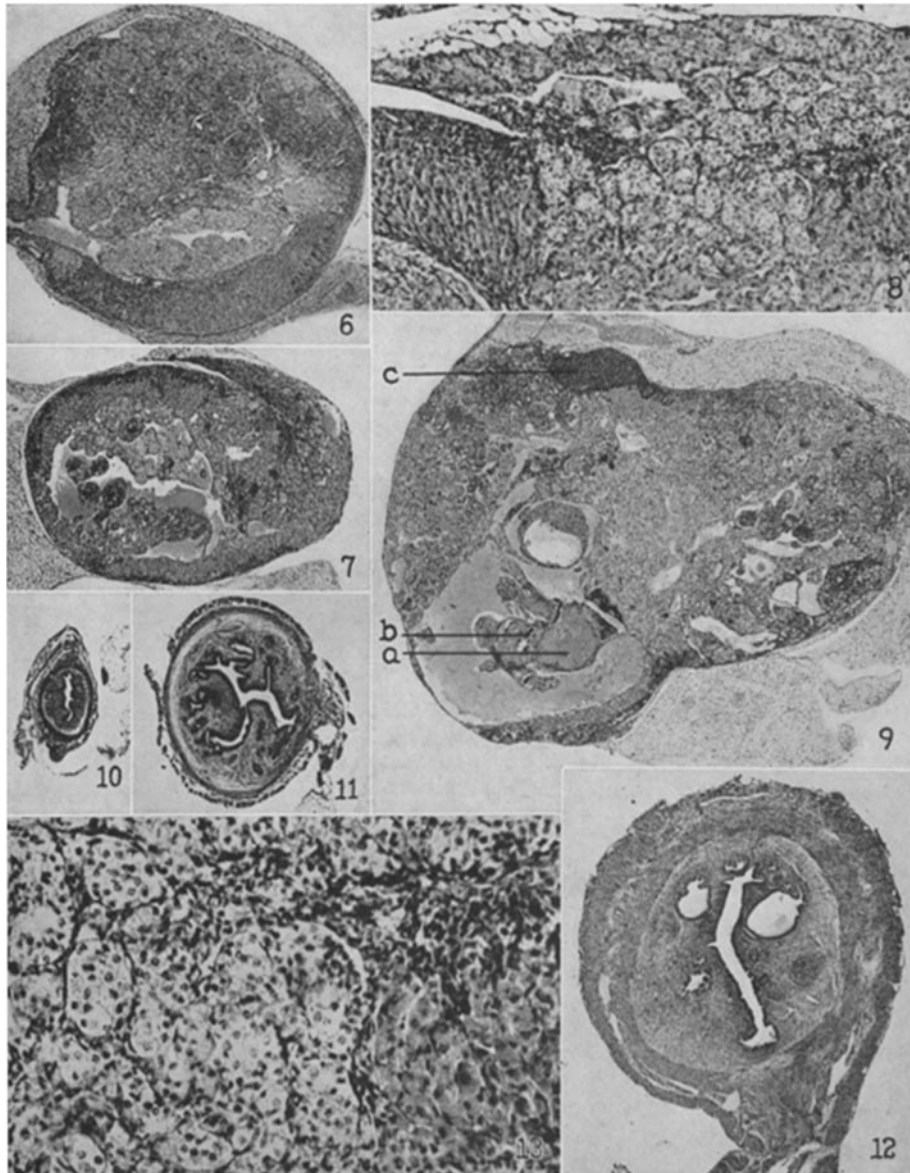
FIG. 9. Suprarenal of a 20 months old mouse showing extreme case of nodular hyperplasia accompanied by thrombosis (*a*) and calcification (*b*). Note the small area of diffuse carcinoma at (*c*). $\times 20$.

FIG. 10. Cross section of the uterus of a 4 months old mouse showing typical castrate state. $\times 20$.

FIG. 11. Cross section of the uterus of a 10½ months old mouse showing recovery from the castrate state. $\times 20$.

FIG. 12. Cross section of the uterus of a 15 months old mouse showing enlarged uterine glands. $\times 20$.

FIG. 13. Same suprarenal as shown on Fig. 8, at higher magnification to show structural details. $\times 183$.



(Fekete *et al.*: Histological changes following ovariectomy. I)