

THE BEHAVIOR OF POX VIRUSES IN THE RESPIRATORY
TRACT

IV. THE NASAL INSTILLATION OF FOWL POX VIRUS IN
CHICKENS AND IN MICE

By JOHN B. NELSON, PH.D.

*(From the Department of Animal and Plant Pathology of The Rockefeller Institute for
Medical Research, Princeton, New Jersey)*

PLATE 9

(Received for publication, June 7, 1941)

The work which is here reported was undertaken in part as an extension of our previous observations on the behavior of pox viruses in the respiratory tract (1, 2) and in part to determine whether or not fowl pox virus was capable of simulating the clinical syndrome of chickens referred to as roup. Roup, which is also known by a variety of names as infectious catarrh, infectious rhinitis, and fowl coryza, is defined as a communicable disease of natural occurrence in chickens characterized by nasal and ocular inflammation which may or may not be accompanied by an outward discharge.

Even before the etiology of roup was established a number of investigators, Haring and Kofoed (3), Beach (4), Doyle and Minett (5), were agreed that it was a distinct entity and unrelated to fowl pox. Their evidence was incomplete but was nevertheless significant since reciprocal protection was not demonstrable. We began an investigation of the syndrome in 1932 shortly after De Blicke (6) had shown that the influenza-like bacterium now known as *Hemophilus gallinarum* was of etiological significance. His work and ours (7-9), which led to the recognition of three clinical types of the disease, were likewise in agreement with these conclusions and afforded ample evidence that roup may occur naturally and be reproduced experimentally in the absence of fowl pox. Much of the earlier work was concerned with the skin inoculation of normal birds with nasal exudates from naturally infected chickens, fowl pox virus not infrequently being demonstrable. The actual nasal instillation of virus suspensions or of exudates was only occasionally undertaken, with scant reference to the results even though an ocular-nasal form of fowl pox was recognized. Our observations as outlined in this paper are largely concerned with this route of introduction, nasal injections of fowl pox virus being made in the absence of the causative agents of roup.

Source and Activity of the Virus

The strain of virus used in most of the following experiments was one obtained locally in 1937 from a field case of fowl pox and maintained thereafter by occasional skin passage in susceptible birds.

Saline suspensions of crusts or of the contents of vesicles produced typical pox when rubbed into the follicles of the leg after removal of the feathers. This method was always used for testing the activity of the virus in the skin, 3 to 6 months old Rhode Island Red, Barred Rock, or cross-bred birds being employed. Enlargement of the follicles was generally observed on the 3rd day but was occasionally delayed until the 4th day after inoculation. The reaction progressed rapidly thereafter, reaching its height on about the 7th day when the follicles were markedly nodular, often reddened at the base, and capped by a dirty white tip. Retrogressive changes set in quickly and scabbing frequently occurred without apparent vesiculation. The area of inoculation covered 50 to 75 feather follicles all of which were generally involved. At the height of the reaction the intervening skin between the follicles was sometimes thickened and on removal showed marked subcutaneous edema. Later the entire area was often covered by a thick reddish brown crust. Inoculated birds rarely showed any obvious generalized response to the virus.

In sections of the skin stained with phloxin-methylene blue there was an initial hyperplasia of the follicular epithelium followed by necrosis and a widespread formation of cell inclusions. Most sections also showed a marked infiltration of lymphocytic cells around the follicles and also in the deeper layers of the skin. In films of vesicular fluid impregnated with silver by the Morosow method elementary bodies were usually demonstrable in the roughly circular groupings which appear to be particularly characteristic of fowl pox.

The activity of the Princeton virus was compared with that of a known strain of fowl pox which was kindly supplied by Dr. F. R. Beaudette of the New Jersey Agricultural Experiment Station in New Brunswick, N. J. This virus had been carried through 49 transfers in embryonated eggs. Each of the two fowl pox strains was tested by follicular inoculation in 3 chickens, with complete reciprocal protection. There was also a reasonably close parallel, both qualitatively and quantitatively, in the reactions produced by them. Elementary bodies appeared to be somewhat more numerous in films from chickens inoculated with the Beaudette strain.

Nasal Instillation of the Virus Propagated by Skin Passage

Reaction in the Nasal Passages.—The results of a preliminary experiment in which 8 chickens were injected intranasally with a follicular suspension of the Princeton fowl pox strain indicated survival for at least 15 days. Although elementary bodies and specific mucosal changes characterized by epithelial hyperplasia and inclusion formation were demonstrable, these findings were irreg-

ular and the only certain test for the presence of virus was the cutaneous inoculation of a susceptible chicken with nasal washings.

The suspension used in this experiment was prepared from the 7th follicular passage of the virus. The contents of about 15 pox were removed on the 7th day after inoculation and pooled in 5 cc. of saline. Small unmeasured amounts of the suspension were introduced with a capillary pipette in the nasal passages of 8 birds by way of the palatine cleft. The chickens used for nasal instillation were 2 to 3 months old and were usually younger than those employed for follicular inoculation. The infected birds were held under quarantine in separate cages and killed in pairs on the 10th, 11th, 14th, and 15th days. At autopsy 5 of them showed some thickening of the nasal mucosa but in only 2, killed on the 10th day, were pock-like nodules observed. A thick mucocellular material was aspirated from the nasal passages with a pipette but there was little if any increase in volume over that removable from uninfected birds. The sinuses, larynx, trachea, pharynx, and eyes were normal in all of the chickens and there was no discharge from the nares. There were no symptoms of nasal irritation or of a generalized response to the virus, nor any indication of a subsequent involvement of the skin.

Elementary bodies were demonstrable in silver impregnated films of nasal washings from 6 of the infected chickens (Fig. 1). Sections from 4 of them showed epithelial hyperplasia and inclusion formation (Fig. 2). Nasal washings from 2, killed on the 10th and the 15th day, produced a typical skin reaction on follicular inoculation in susceptible birds.

Transmission by Nasal Passage.—Following establishment of the virus in the upper respiratory tract of a susceptible chicken it was maintained for 12 successive nasal passages at intervals of 10 to 11 days. In the last 7 passages the suspensions used for nasal instillation were also tested by skin inoculation, all of them containing sufficient virus to produce a typical follicular reaction.

The initial suspension was made from the 8th skin passage of the virus. The subsequent inocula were prepared by suspending nasal scrapings or the catarrhal material removed on aspiration in 2 cc. of saline. The passages were carried out at intervals of 10 to 11 days, injection being by way of the palatine cleft. 7 of the infected birds showed visible thickening of the nasal mucosa, accompanied in one instance by erosion of the epithelial lining of the turbinates. Pox-like lesions were not encountered but epithelial hyperplasia with inclusion formation was observed in sections of the nasal mucous membrane from 4 birds. Sections from 3 showed some edema and cellular infiltration. The eyes, sinuses, and tracheas were again normal and there was no discharge from the nares. Elementary bodies were demonstrable in silver impregnated films of nasal washings from 10 of the 12 chickens. The extent of the skin reaction in the birds which received a follicular inoculation of the nasal suspensions was indicative of a moderate titer of virus, the number of involved follicles varying from 25 to 60.

Transmission by Direct Contact.—The communicability of the nasally established virus was determined by contact experiments in which a susceptible bird

was placed in the same cage with one previously infected by nasal instillation. Development of the virus in the upper air passages of the initially infected birds, 9 in number, was indicated by direct microscopic examination or by subsequent protection tests. There was no demonstrable transfer of the virus from these birds to those in direct contact with them.

Three groups of chickens were used in this experiment. 2 of the initially infected birds were injected intranasally with nasal washings from passage 10 of the transmission series. 3 were similarly injected with nasal washings from passage 11 of the same series, and 3 with a suspension prepared from the 13th skin passage. The susceptible chickens in Group 1 were placed in contact with the infected ones on the 2nd day after nasal instillation, those in Group 2 on the 4th day, and those in Group 3 on the 5th day. The exposed birds in Group 1 were killed on the 9th day of contact, while those in Groups 2 and 3 were killed on the 14th or 15th day. All of them remained normal during the period of exposure. At autopsy the nasal passages of the exposed birds showed no apparent involvement, nor were elementary bodies demonstrable in silver impregnated films. The feather follicles of susceptible birds inoculated with nasal washings from each contact chicken showed no reaction during a period of 2 weeks.

Protection against Follicular Inoculation.—Nasal instillation of the virus maintained by dermal passage or by nasal passage afforded complete protection to a subsequent follicular inoculation. None of the 9 birds in this series showed any local reaction when fowl pox virus was introduced into the skin 4 to 6 weeks after the initial nasal instillation.

7 of the infected birds from the contact series and 2 additional ones were used in this experiment. 3 were injected intranasally with nasal washings from passage 11 of the transmission series and were tested 47 days later by follicular inoculation with a suspension made from the 13th skin passage. A susceptible chicken was similarly inoculated at the same time. 6 of the birds were injected intranasally with the 13th skin passage suspension and were tested, together with a susceptible chicken, 31 days later with virus from the 14th skin passage. The 9 birds which had received the initial nasal instillation were held under observation in separate cages and examined daily for at least 2 weeks. None of them showed any involvement of the inoculated area during the period of examination. In the 2 susceptible birds there was a typical local reaction which began on the 3rd day and covered a wide area of skin.

*Nasal Instillation of the Virus Propagated by
Transfer in Embryonated Eggs*

Reaction of the Virus in the Nasal Passages and Its Transmission.—The Princeton strain of fowl pox was established in the nasal passages of susceptible chickens following nasal instillation of membrane suspensions from the 6th, 34th, and 50th transfers in embryonated eggs and was subsequently main-

tained for 5 passages by the injection of nasal washings. In 10 of the 15 birds used in this series there was no apparent mucosal reaction, elementary bodies were not detectable, and the presence of virus was demonstrated only by the follicular inoculation of susceptible birds. The concentration of virus in the nasal washings as indicated by the number of follicles involved on subinoculation tended to be low.

The virus was isolated in a pure state, free of bacteria, and maintained for 50 transfers by inoculation of the chorioallantoic membrane of 10 day embryonated hen's eggs. Prior to inoculation the membrane was retracted by the Burnet method. Approximately 10 per cent suspensions in saline were prepared by grinding the inoculated membranes after incubation of the eggs for 3 to 4 days at 37°C. At this time the chorioallantois showed a wide, confluent or semiconfluent, central area of hyperplasia. Typical fowl pox inclusions were demonstrable in sections and elementary bodies in silver impregnated films. The embryo was usually alive and active.

2 chickens were inoculated, one *via* the palatine cleft and one by way of the feather follicles, with suspensions of the 6th, 34th, and 50th egg transfers of the virus. The 3 birds which received the follicular inoculation showed a typical fowl pox reaction which began on the 3rd day and involved 50 to 75 follicles. The virus which was established by nasal instillation was subsequently maintained for 5 passages by injecting a saline suspension of nasal washings at intervals of 10 or 11 days. With each passage the follicles of a susceptible bird were inoculated with the same suspension used for the following nasal instillation. One bird in each of the 3 passage series showed macroscopic involvement of the nasal mucosa. Elementary bodies were demonstrable in nasal films from one bird in each of the first 2 series and from 2 birds of the 3rd series. In 8 of the birds inoculated dermally with nasal suspensions the reaction approximated that with skin or egg membrane suspensions, 40 to 60 follicles being involved. In 7 of these birds there was a reduced reaction involving only 10 to 30 follicles.

Communicability and Protective Action of the Virus.—Susceptible chickens placed in direct contact with birds infected by nasal instillation of the 34th egg membrane transfer and exposed to them for approximately 2 weeks showed no resulting skin lesions nor was virus demonstrable in the nasal tract either by direct examination or by follicular inoculation. A sufficient degree of immunity to inhibit development of the virus in the feather follicles was not afforded by nasal instillation of the egg membrane suspension. The reaction which attended follicular inoculation of the initially infected birds, after a period of 6 weeks, was however atypical and indicative of partial protection.

The 34th egg membrane suspension used in these inoculations was made at a later date than that in the preceding experiment. Rubbed into the feather follicles of a susceptible chicken it produced a typical reaction over a wide area. There was no apparent involvement of the local mucosa on nasal instillation nor were elementary bodies demonstrable in films. Development of the virus was indicated, however, by

a follicular reaction following the inoculation of nasal washings. The titer of virus in the nasal suspension was probably low as only 20 follicles were involved.

A susceptible chicken was placed in the same cage with each of 3 birds on the 4th day after nasal instillation of the egg membrane suspension. Contact was maintained through the 16th day when the exposed birds were removed and killed. At autopsy there were no skin lesions; the nasal mucosa appeared normal; elementary bodies were absent; and nasal washings were inactive on follicular inoculation in susceptible birds.

The initially infected birds were held for 31 days and tested by dermal inoculation with a suspension of the 12th skin passage of the virus. Each of the 3 birds showed swelling of the follicles on the 3rd day but the reaction did not progress to the formation of typical pox. The follicles were definitely nodular by the 5th day, as many as 40 being involved, but there was neither congestion nor vesiculation. The follicles remained nodular without scab formation through the 13th day when the chickens were killed.

TABLE I
The Survival of Fowl Pox Virus in the Lung of the Mouse Following Nasal Instillation

No. of days to autopsy	No. of mice	No. of mice with lung lesions	No. of virus recoveries from lung
3	14	14	14
5	12	7	5
7	11	8	4
10	8	7	0

Nasal Instillation of the Virus in Mice

Mice injected intranasally with egg membrane suspensions of fowl pox showed no symptoms indicative of either a general or a local development of the virus. At autopsy the mucous membrane of the upper respiratory tract appeared normal; there was no exudate in the nasal passages, and elementary bodies were not detectable in nasal washings. The specific virus was regularly recoverable, however, from the lung through the 3rd day after nasal instillation and irregularly through the 7th day. Its presence was generally attended by a slight but readily recognized pulmonary reaction. The number of virus recoveries and of involved lungs at intervals of 3, 5, 7, and 10 days is presented in Table I.

Etherized mice weighing 15 to 20 gm. were infected with the Princeton strain of fowl pox virus by inhalation, the nose being held for 8 or 10 respirations in a Petri dish containing a saline suspension of the virus. Approximately 10 per cent suspensions of bacteriologically sterile membranes removed from embryonated eggs on the 3rd or 4th day after inoculation were employed. They included the 6th, 12th, 34th, and 50th egg transfers. The infected mice were killed on the 3rd to 10th day; the nasal passages were exposed, and from some of them silver impregnated films were made of material aspirated with a capillary pipette. The lungs were removed and examined microscopically at a magnification of around 10 diameters. They were then

ground with a little saline, after removal in some cases of a small piece for sectioning, in a glass tissue grinder and suspended in several cubic centimeters of the same diluent.

All of the infected mice were normal in appearance when brought to autopsy; their coats were smooth, and those killed on the 7th day or later had generally gained in weight. The only pathological change encountered at autopsy was a slight reaction in the lung which was best observed under a dissecting microscope at low magnification. It resembled the reaction previously described in the lungs of mice infected intranasally with variola virus (2). The lungs showed single or multiple patchy areas of solidification, grayish in color or tinged with pink, which contrasted sharply with the pale foamy structure of the normal pulmonary tissue. Histologically there was a marked increase in the number of mononuclear cells and lymphocytes around bronchioles and blood vessels and in discrete islands just beneath the pleural surface or centrally located (Fig. 4). In a few sections the alveoli showed mononuclear cells and erythrocytes. Some of the bronchioles contained desquamated epithelial cells but there were no cell inclusions. The membranes of embryonated eggs inoculated with lung suspensions generally showed discrete foci varying from 5 to 100 or more, indicative of a low concentration of virus. The membrane from an egg inoculated with the suspension of a lung removed from a mouse on the 7th day after nasal instillation is shown in Fig. 3. The subinoculation of membranes with discrete foci resulted in a typical confluent or semiconfluent reaction covering a wide area.

DISCUSSION

Fowl pox virus from active skin lesions was repeatedly established in the upper respiratory tract of normal chickens and recovered in mucosal washings for as long as 15 days after nasal instillation. Multiplication of the virus was clearly indicated by its maintenance for 12 successive host passages, the resulting dilution factor being much greater than the titer of the original inoculum. The experimentally infected birds showed no skin lesions and no external evidence of nasal or ocular involvement. The lack of conjunctival manifestations is in contrast to the findings recorded during a natural outbreak of uncomplicated fowl pox in which 20 per cent of 50 chickens with skin lesions also showed unmistakable signs of ocular inflammation.

A specific mucosal reaction was only irregularly observed at autopsy. Many of the infected birds showed no evidence of nasal involvement although fowl pox virus was readily demonstrable. Indeed the only certain test for the presence of virus was the activity of nasal washings on subinoculation in the skin of a normal bird. The nasal passages sometimes contained a thick catarrhal material but frank exudation was rarely observed and the adjacent sinuses were invariably normal. The condition of the upper respiratory tract in the presence of fowl pox virus is very different from that in the presence of the causal agents of roup. Natural or experimental roup infection is frequently attended by a nasal discharge which with the coryza of slow onset may persist for weeks. At autopsy a copious mucopurulent or catarrhal exudate is almost invariably present in the nasal passages and the sinuses. Birds infected with

roup may or may not show ocular involvement, but if they do it occurs in conjunction with nasal inflammation and not as an independent manifestation.

Fowl pox virus established in the upper air passages following nasal instillation was readily transmitted by the passage of nasal washings but it was not transmitted by direct contact. Development of the virus in the nasal mucosa is not attended by an outward discharge and presumably the amount of virus which escapes by way of the nares is too small to infect an exposed bird. The volume of inoculum used experimentally contained a relatively high concentration of virus. It is probable that the nasal tract as such is of little significance in the spread of fowl pox under natural conditions. It should be borne in mind, however, that in nature such factors as coexisting infections, unfavorable dietary and climatic conditions, and strain differences might influence the outward and inward nasal passage of the virus.

The nasal establishment of fowl pox virus was attended by protection of at least 4 to 6 weeks duration against development of virus in the skin on subsequent follicular inoculation. The number of birds tested was too small, however, to warrant any conclusions as to the constancy or duration of the protection afforded by nasal immunization. Doyle and Minett (5) had noted earlier that the presence of fowl pox virus in the nasal passages of naturally infected birds did not necessarily result in protection against cutaneous inoculation.

The preceding observations were from chickens injected intranasally with fowl pox virus from active skin lesions. Virus propagated for as many as 50 transfers in embryonated eggs was also established in the nasal tract and maintained for a sufficient number of passages to indicate multiplication. In general the activity of the virus after carriage in fertile eggs appeared to be somewhat less than that tested directly from the skin. Elementary bodies were rarely demonstrable in nasal films from infected birds and inclusion bodies were not observed in sections of the mucosa. Birds injected with the 34th egg transfer were not completely protected against development of the cutaneous strain on subsequent follicular inoculation. The number of birds tested was again too small to be certain whether the failure to afford complete protection was the result of some change brought about by transfer in the egg or was simply an expression of variability attendant on nasal immunization.

The behavior of the egg transfer strain of fowl pox virus on nasal instillation in mice resembled that of variola virus (2). There were no attendant symptoms and no apparent changes in the nasal mucosa. The specific virus was recoverable, however, from the lung through the 7th day, survival being accompanied by a slight pulmonary reaction.

SUMMARY

Fowl pox virus from active skin lesions was established in the upper respiratory tract of normal chickens by nasal instillation and maintained for 12

successive passages. The nasal infection was not communicable by direct contact but did afford protection, for at least 6 weeks, against subsequent development of the virus in the skin.

Multiplication of the virus in the nasal passages was only irregularly attended by specific mucosal changes and was not accompanied by the vigorous counter-reaction engendered by the causal agents of roup.

The same strain of virus on propagation in embryonated eggs also survived and multiplied in the nasal tract but with somewhat reduced activity, the 34th egg transfer failing to afford complete protection. Nasal instillation in mice was followed only by a reaction in the lung from which the virus was recoverable through the 7th day.

BIBLIOGRAPHY

1. Nelson, J. B., *J. Exp. Med.*, 1938, **68**, 401.
2. Nelson, J. B., *J. Exp. Med.*, 1939, **70**, 107.
3. Haring, C. M., and Kofoed, C. A., *Am. Vet. Rev.*, 1912, **40**, 717.
4. Beach, J. R., *J. Am. Vet. Med. Assn.*, 1920-21, **58**, 301.
5. Doyle, T. M., and Minett, F. C., *J. Comp. Path. and Therap.*, 1927, **40**, 247.
6. De Blicck, L., *Vet. J.*, 1932, **88**, 9.
7. Nelson, J. B., *Proc. Soc. Exp. Biol. and Med.*, 1932-33, **30**, 306.
8. Nelson, J. B., *J. Exp. Med.*, 1936, **63**, 509.
9. Nelson, J. B., *J. Exp. Med.*, 1938, **67**, 847.

EXPLANATION OF PLATE 9

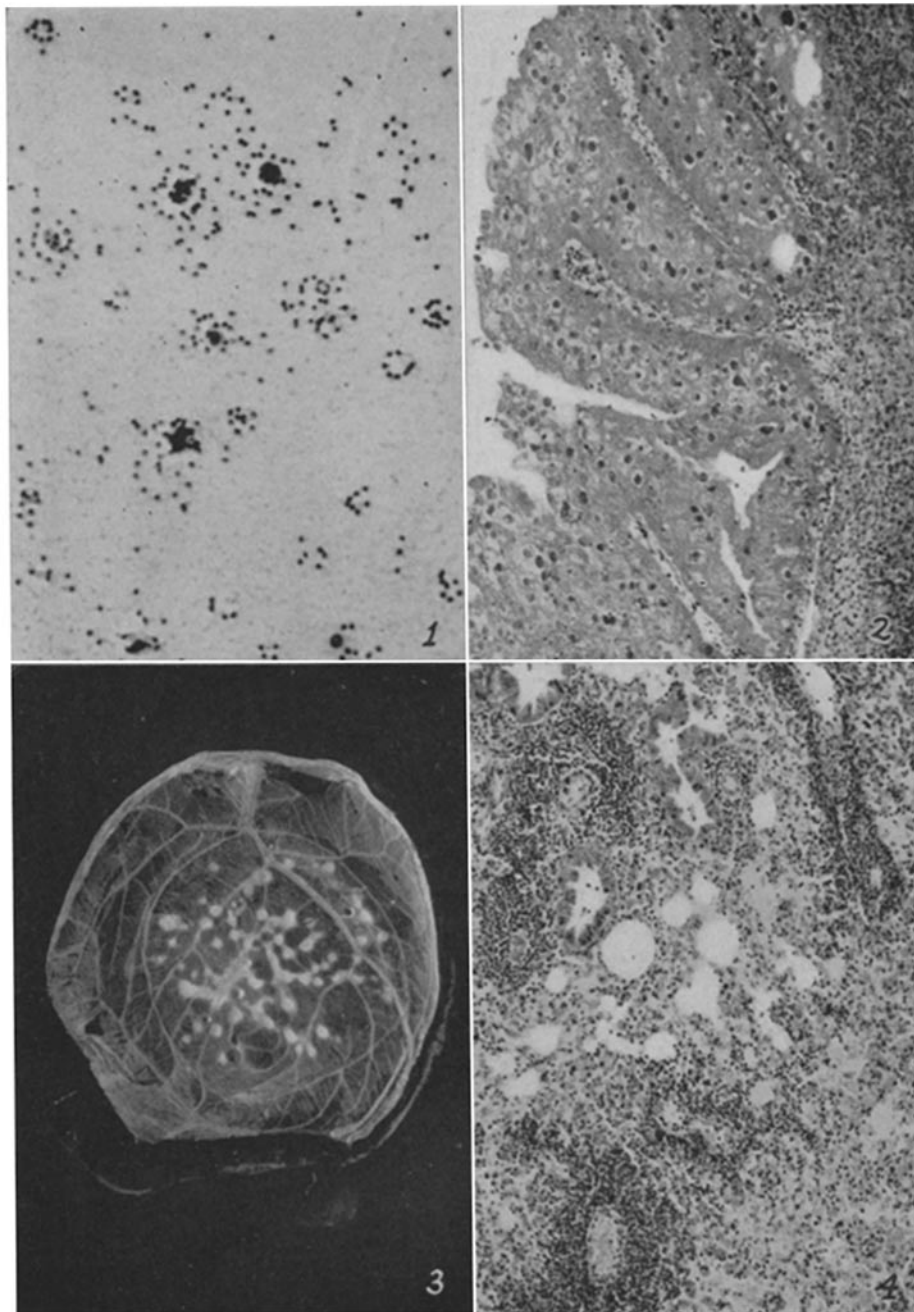
FIG. 1. Elementary bodies in silver impregnated film of nasal washings from a chicken infected with fowl pox by nasal instillation. $\times 1580$.

FIG. 2. Section of nasal mucosa showing epithelial hyperplasia and inclusion bodies from a similarly infected chicken. Phloxin-methylene blue. $\times 113$.

FIG. 3. Specific foci in the chorioallantois of an embryonated egg inoculated with lung suspension from a mouse killed 7 days after nasal instillation of fowl pox virus. $\times 1.15$.

FIG. 4. Section of a lung showing cellular reaction in alveoli and around vessels from a similarly infected mouse. Phloxin-methylene blue. $\times 100$.

The photographs were taken by Mr. J. A. Carlile.



(Nelson: Pox viruses in the respiratory tract. IV)