

## EXPERIMENTAL GONOCOCCUS INFECTION OF THE CHICK EMBRYO

By FREDERIK BANG,\* M.D.

(From the Department of Pathology, Vanderbilt University School of Medicine, Nashville)

PLATES 16 AND 17

(Received for publication, June 19, 1941)

The chick embryo in recent years has been infected with a variety of bacteria, and the reactions to such infection have been found to parallel closely in their basic features those of the respective natural diseases in man (1).

The chorio-allantoic membrane of embryo chicks was first infected with gonococci by Morrow and Berry (2) in 1938, and they were able to cure the infection with sulfanilamide. Hill and Pitts also (3) established 15 strains of these microorganisms on the membrane. Since then the membranal infection has been used more extensively for the study of the relative efficacy of sulfanilamide and its derivatives (4). However, the reaction of the chick embryo to the gonococcus and the adjustment of it to continued growth in this environment has not been carefully studied.

We have attempted to do so by study of both membranal inoculation of 10 day embryos and intra-amniotic injection of 14 to 15 day embryos.

### *Method*

The course of an experimental infection may be followed by making a series of samples from one living host, or by the infection of a number of hosts, and the subsequent fixation and sectioning of certain ones. Both of these methods were followed in the study of the reaction of the chick embryo to nine different strains of gonococci.

Eight strains of *Neisseria gonorrhoeae* were isolated from typical cases of acute gonorrheal urethritis at Marine Hospital, Baltimore, and Vanderbilt Hospital, Nashville. They were identified by the following characters: small, smooth, glistening colonies on heated blood agar, positive oxydase reaction, Gram-negative staining, and typical biscuit-shaped diplococci. One strain was furnished by the American Type Culture Association.

The membranes of 10-day old chick embryos were exposed according to Goodpasture and Buddingh's method (5), and infected either by means of a platinum wire loop from a 24 hour heated blood agar plate or a drop of saline suspension of gonococci of about 100,000 per cc. Cover-slips were placed over the opening and sealed with vaseline; or the egg shell flap was replaced and sealed with paraffin. The

---

\* Fellow in Medicine of the National Research Council.

infected eggs were reincubated at 36°. Smears and occasionally cultures were made with a platinum wire loop. Gram stains were done on all smears.

14- to 15-day old chicks were inoculated intra-amniotically with 0.1 cc. of standard saline suspension of gonococci from a 24 to 36 hour heated blood agar plate. The technique has been described by Polk, Buddingh, and Goodpasture (6).

Histological sections were made of representative embryos at various stages of infection. After the amniotic fluid had been smeared and cultured the embryo was fixed in Zenker's fluid with 10 per cent acetic acid. Paraffin blocks were made of the head, thorax, and abdomen, and the sections were stained routinely with hematoxylin and eosin. Those sections which showed histological evidence of infection were stained for bacteria with Wright's stain.

#### *General Findings*

*Gross Appearance of Membranal Infection.*—The 24 hour infected membrane may show little or no clouding, with only a dull sheen everywhere, or the leucocytic response may be more localized, and small pockets of pus may collect in depressions of the membranes. The latter type is more apt to occur when the membrane is infected by means of a loop, while infection with a drop of saline suspension commonly yields a more diffuse reaction. In the more heavily infected embryo small hemorrhages may occur throughout and clouding is particularly concentrated along the course of the large vessels.

Later, one of three things may happen. (1) The infection may completely disappear, leaving a normal appearing membrane. (2) A localized ulcer with ragged edges and containing pus in its center may form. (3) Finally, the infection may overwhelm the embryo, the vessels becoming thrombosed and the membrane almost devoid of circulating blood.

*Smear of Membrane.*—Since the gonococci rarely penetrate deeply into the chorio-allantoic membrane of 10 day chicks, a day-to-day study of smears from the surface of the membrane is a particularly useful method of following the infection. This is entirely analogous to a study of urethral smears from human cases of gonorrhoea.

A leucocytic response to the bacteria occurs within 4 hours in some cases and is always present within 12. It varies in intensity, as does the number of organisms. Although some phagocytosis always appears, the majority of organisms are usually not phagocytosed. More extensive phagocytosis occurs in the "localized" infections where almost all the gonococci may be intracellular.

*Effect of Immune Sera on Phagocytosis.*—Chicken immune serum was obtained by the injection of saline suspensions from 48 hour blood plate cultures into two adult chickens twice weekly for 2½ months. These sera agglutinated in 1:160 dilution. Introduction of two drops of serum onto the surface of membranes infected 4 to 24 hours previously failed to increase phagocytosis above that of controls in two experiments. Three controls and three experi-

mental embryos were used in each experiment. Clumping of the gonococci could however be seen in the smears for several hours after addition of serum.

*Progress of the Infection.*—The embryo may die within 2 or 3 days, or may localize and eventually throw off the infection. When the majority of organisms are phagocytosed the chances of recovery are very great, and chicks usually hatch out normally. Avery (7) found that 10 day embryos inoculated with one strain of *N. gonorrhoeae* on the membrane, occasionally yielded on hatching a chick from which the organisms could be recovered by culture of the blood during the first 1 or 2 days.

*Distribution of Infection.* The extent of the infection and the deep reaction of the tissues can be studied in histological sections. These were made at 12 hours and at daily intervals up to 5 days. The membrane at 24 hours is only slightly thickened; there is a slight exudate consisting of polymorphonuclears, a few mononuclears, and occasionally a little superficial hemorrhage (Fig. 1). The ectodermal layer may be reduplicated at scattered points and occasionally ulcerated.

By the 2nd day the ulceration of the ectoderm has become more marked and the ectoderm itself has thickened. The exudate is heavier, more plastic (Fig. 2), and contains clumps of organisms, some of them phagocytosed by polymorphonuclears. Scattered focal hemorrhages occur deeper in the edematous membrane. If the membrane has been inoculated with a loop, the necrosis and reaction may be concentrated, so that a crater-like ulcer is formed (Fig. 3) by the central destruction of ectoderm and consequent exposure of the mesoderm. It is filled with cell detritus, polymorphonuclears, and scattered organisms. The edges are formed by proliferating ectoderm. A rare polymorphonuclear cell with organisms may be found in the edematous mesoderm. At this stage the embryo itself often succumbs, apparently due to toxic products from the membranal infection accounting for multiple scattered small hemorrhages observed throughout the various tissues and organs. Bacteria are not demonstrable in the embryo.

By the 3rd day and thereafter the whole structure of the membrane may be changed. Islands of ectoderm may have been broken off and caught in the thickened inflamed mesoderm. The destruction of cells is less extensive, but hemorrhages in the mesoderm are more common. Most remarkable in all of these sections is the absence of the gonococci in the deeper portions of the membrane. Apparently the mesodermal reaction is due to some diffusible product of the bacteria rather than to the presence of the bacteria themselves.

*Extent and Distribution of Infection in 14 to 15 Day Embryos.*—Intra-amniotic injection of 14 to 15 day embryos exposes a variety of tissues and organs to infection. It has been particularly successful in the study of the meningococcus, whereby septicemia and meningitis were produced (Buddingh and Polk (8)). Four strains of gonococci were studied in this way.

Three of the strains were isolated at the Vanderbilt Hospital and the fourth was furnished by the American Type Culture Association.

As a rule living infected embryos were killed and fixed for histological study 24 and 48 hours and occasionally 72 hours after inoculation. About equal numbers of each strain were studied. Cultures of amniotic fluid and heart blood were taken at this time from 28 of 41 embryos studied in this manner.

The results are summarized in Table I.

All of the amniotic cultures were strongly positive. The positive blood cultures showed 6 to 8 colonies per drop.

Of the 41 embryos studied histologically only 14 showed a reaction to infection. Pneumonitis and bronchitis (Fig. 4) were most common but in no case was there complete occlusion of the bronchi by exudate nor was a widespread pneumonitis present (Fig. 8). Sinusitis and infection of the thoracic and ab-

TABLE I  
*Heart's Blood Cultures*

Strain	No. of cultures	No. positive
L. B.	4	0
L. B.	8	3
After 15 chorio-allantoic membrane passages		
A. W.	10	0
E. M.	6	0

dominal air sacs were also common (Fig. 5). The latter presumably represented a direct extension from the pneumonitis.

In only one embryo was a purulent meningitis observed (Fig. 7). This embryo had a positive blood culture. The meninges were thickened by a diffuse exudate made up chiefly of polymorphonuclears. Cocci were scattered throughout the exudate (Fig. 6) but only occasional ones were phagocytosed by polymorphonuclears.

#### *Virulence*

Bacteremia and meningitis occurred only in infection with the strain of gonococci which had been "modified" by passage on the chorio-allantoic membrane. This immediately raises the question of a possible change in "virulence." The early bacteriologists who worked with gonococci were wont to test the specificity of their cultures by inoculation in human beings. In this way four investigators found that the gonococci preserved their pathogenicity over a number of transfers in appropriate artificial media. Bumm (9) produced urethritis with the 20th generation, Anfuso (10) with the 7th, and Wertheim

(11) after 27 days of culture. Finger *et al.* (12) had studied one strain which maintained its virulence after more than 4 months of artificial cultivation.

Early in our work on drug therapy of membranal infection (4) it was found that strains of organisms inoculated in similar doses varied in their ability to live and multiply on the membrane. This is not dependent solely on previous duration of growth on artificial media; for one strain when placed on the membrane immediately after cultivation from the urethral discharge failed to kill the embryo, and persisted in smears and cultures for only 3 to 4 days. The type strain of *N. gonorrhoeae*, isolated in 1937, furnished by the American Type Culture Association, could be recovered from the membrane after 2 or 3 days incubation.

That virulence or killing power may vary with adjustment to continued growth on the membrane is shown by Table II. The percentage of 10 day embryos killed within 3 days after membranal inoculation is taken as a measure of the virulence. The strain of gonococcus used in this experiment, on isola-

TABLE II

Membrane transfer	No. of embryos inoculated	No. dead in 3 days	Percentage dead
0	15	4	27
14-16	12	5	42
17-26	28	23	82
31-35	8	8	100

tion from the human cases failed to kill 10 day embryos. It had been grown on blood plates for about a month before serial chick passage was undertaken. It was then transferred from membrane to membrane at 2 day intervals with only an occasional blood plate transfer.

Since it is known that the gonococcus can be gradually adapted to adverse conditions, this may well represent an adaptation to the embryo, and death may have been caused by increased capacity for rapid multiplication rather than any change in toxicity or invasiveness.

With this change it was noted that the colonies obtained by culture of the 17th membranal passage had become very sticky so that they were hard to suspend in saline. Smears showed an abnormal amount of mucoid material. Capsular material could not be demonstrated by Hiss's method. This change in the gonococcus is also demonstrable in the older embryos inoculated intra-amniotically, as seen in Table III.

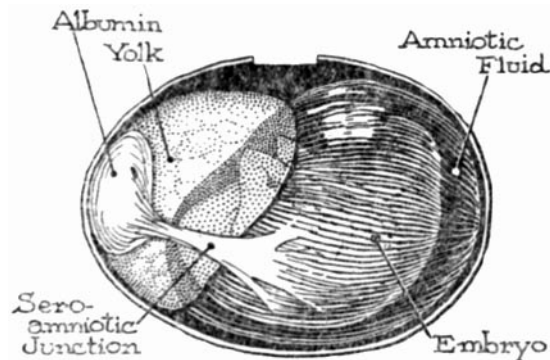
Strain L. B. killed a greater number of embryos in less time, after it had become adjusted to the embryo. This difference is probably not significant in itself but agrees with the other data.

Embryos inoculated intra-amniotically frequently recovered from the in-

fection by the 2nd day, and later hatched. This may be partially due to the development of conditions unfavorable for the gonococci. The sudden release of albumin into the amnion which takes place following the rupture of the sero-amniotic junction (Text-fig. 1) on the 14th day (13) may make the amniotic fluid less favorable for the growth of gonococci. This is in keeping with the failure of gonococci to multiply in the albumin of infertile eggs, while they ap-

TABLE III

Strain	Time of culture on artificial media	Age of embryo	No. inoculated	No. dead	Mortality
Type L. B.	4 yrs.	14	12	4 (3 days)	33
	1-2 wks.	14	20	5 (2 days)	25
	After 15 membranal transfers	14	30	13 (18 hrs.)	43
A. W.	2 mos.	15	13	3 (2 days)	23
E. M.	2 days	13	13	5 (1 day)	38



TEXT-FIG. 1. Diagram of 14 day chick showing amniotic cavity, and sero-amniotic junction. Made from embryo hardened *in situ* by boiling.

parently are able to multiply in the yolk (14). Attempts to grow gonococci in unheated amniotic fluid of 10, 12, and 15 day embryos were unsuccessful.

#### *Comparison with Meningococci*

Susceptibility of the chick embryo to experimental infection by both meningococci (8, 15) and gonococci brings out certain interesting differences between these two closely related organisms.

1. The meningococcus kills susceptible embryos quickly, but the gonococcus is often not fatal even to 10 day embryos.
2. Meningococci usually invade the membrane of 10-day old chicks, localize on the endothelium of blood vessels, and spread from there to the embryo itself. Gonococci rarely penetrate the 10 day membrane and thus rarely spread to the embryo.
3. Meningococci introduced intra-amniotically into 14 to 15 day embryos produce septicemia and often meningitis. Gonococci only occasionally gain the blood stream in small numbers, and meningitis is rare.

These differences in biological behavior thus correspond to the differences in disease-producing qualities of the two organisms in the human host.

#### *Pathology of Acute Urethritis*

Little has been added to our knowledge of the pathology of acute gonorrhoeal urethritis since the classical work of Finger, Ghon, and Schlagenhauser in 1894 (12). They inoculated three convicts intra-urethrally with pure cultures of gonococci 2 and 3 days before execution and then obtained sections of the urethra. At first the gonococci occurred in scattered groups over the epithelium, particularly in the lacunae. They penetrated the connective tissue only where the epithelial layer was absent. Leucocytes pushed through the epithelial layer and engulfed an occasional gonococcus. By 3 days there were a massive inflammation and a great number of gonococci, most of which were phagocytosed. Many others were found in rows between the columnar epithelial cells of the pars pendula and also around the desquamated squamous cells of the thickened epithelial layer. They did not penetrate deeper into the tissues. Otherwise the process was entirely similar to any acute infection.

Study of a case (V-28-76) of gonorrhoeal urethritis at the Vanderbilt Hospital of 3 weeks duration revealed essentially the same findings. Smears had been found positive 2 days before the patient's accidental death. Bacteria were easily demonstrable scattered between the epithelial cells and in the leucocytic exudate (Wright's and Gram's stains). However they were also found clumped together in columnar epithelial cells. A slight vacuole surrounded the bacteria and separated them from the cytoplasm of the cell. We have been unable to demonstrate gonococci within the epithelial cells of the chick embryo.

The infection of the chorio-allantoic membrane of the 10 day chick reproduces all of the essential characteristics of acute urethritis in man. Following the initial multiplication and spread of bacteria on the surface of the membrane, there are a leucocytic exudate, a desquamation of epithelium (Fig. 9), and later phagocytosis, which may be partial or complete. A thickening of

the squamous ectoderm, and a deep inflammation in the mesoderm in the presence of few or no bacteria are characteristic.

Infection of the amniotic cavity allows the bacteria to spread to the embryo, occasionally to produce bacteremia and meningitis.

#### SUMMARY

1. The reaction of the chick embryo to nine strains of gonococci was studied. Four of these were inoculated intra-amniotically in 14 to 15 day embryos.
2. Infection of the 10 day chorio-allantoic membrane was localized and accompanied by polymorphonuclear leucocytic phagocytosis.
3. Infection was either transitory or persisted until hatching. Several strains killed the 10 day embryo in 3 days.
4. Chicken immune sera placed on the infected membranes failed to affect phagocytosis.
5. Slight sinusitis, bronchitis, and infection of the pulmonary alveoli were common following intra-amniotic injection of 14 to 15 day embryos. Infection also extended to the pulmonary and abdominal air sacs.
6. Serial passage on the membrane so modified one strain that it killed a greater percentage of both 10 day and 14 day embryos. The infection after modification was also accompanied by bacteremia and meningitis in one embryo.
7. The ability of meningococci to invade tissue and produce septicemia is contrasted with the inability of gonococci to produce more than a superficial infection.
8. The infection of the embryo with gonococci reproduces all of the essential characteristics of the disease in man.
9. Gonococci were found within columnar epithelial cells in a case of acute human urethritis.

#### BIBLIOGRAPHY

1. Goodpasture, E. W., *Tr. College Physn.*, Philadelphia, 1941, **9**, 11.
2. Morrow, G., and Berry, G. P., *J. Bact.*, 1938, **36**, 280.
3. Hill, J., and Pitts, A., *J. Urol.*, 1939, **41**, 81.
4. Bang, F. B., and Bang, B., *Proc. Soc. Exp. Biol. and Med.*, 1941, **46**, 527.
5. Goodpasture, E. W., and Buddingh, J. G., *Am. J. Hyg.*, 1935, **21**, 319.
6. Polk, A. D., Buddingh, G. J., and Goodpasture, E. W., *Am. J. Path.*, 1938, **14**, 71.
7. Avery, R. C., unpublished observations.
8. Buddingh, G. J., and Polk, A. D., *J. Exp. Med.*, 1939, **70**, 485.
9. Bumm, *Der Mikroorganismus der gonorrhoeischen Schleimhautentzündung*, Wiesbaden, J. F. Bergmann, 1887.



10. Anfuso, cited by Finger *et al.*
11. Wertheim, E, *Arch. Gynäk*, 1892, **42**, 1.
12. Finger, E., Ghon, A., and Schlagenhauer, F., *Arch. Dermat. u. Syph.*, 1894, **28**, **277**.
13. Needham, J., *Chemical embryology*, London, Cambridge University Press, 1931.
14. Bradford, W. L., and Titsler, R., *Proc. Soc. Exp. Biol. and Med.*, 1936, **34**, 241.
15. Bang, F. B., unpublished observations on seven strains of meningococci.

## EXPLANATION OF PLATES

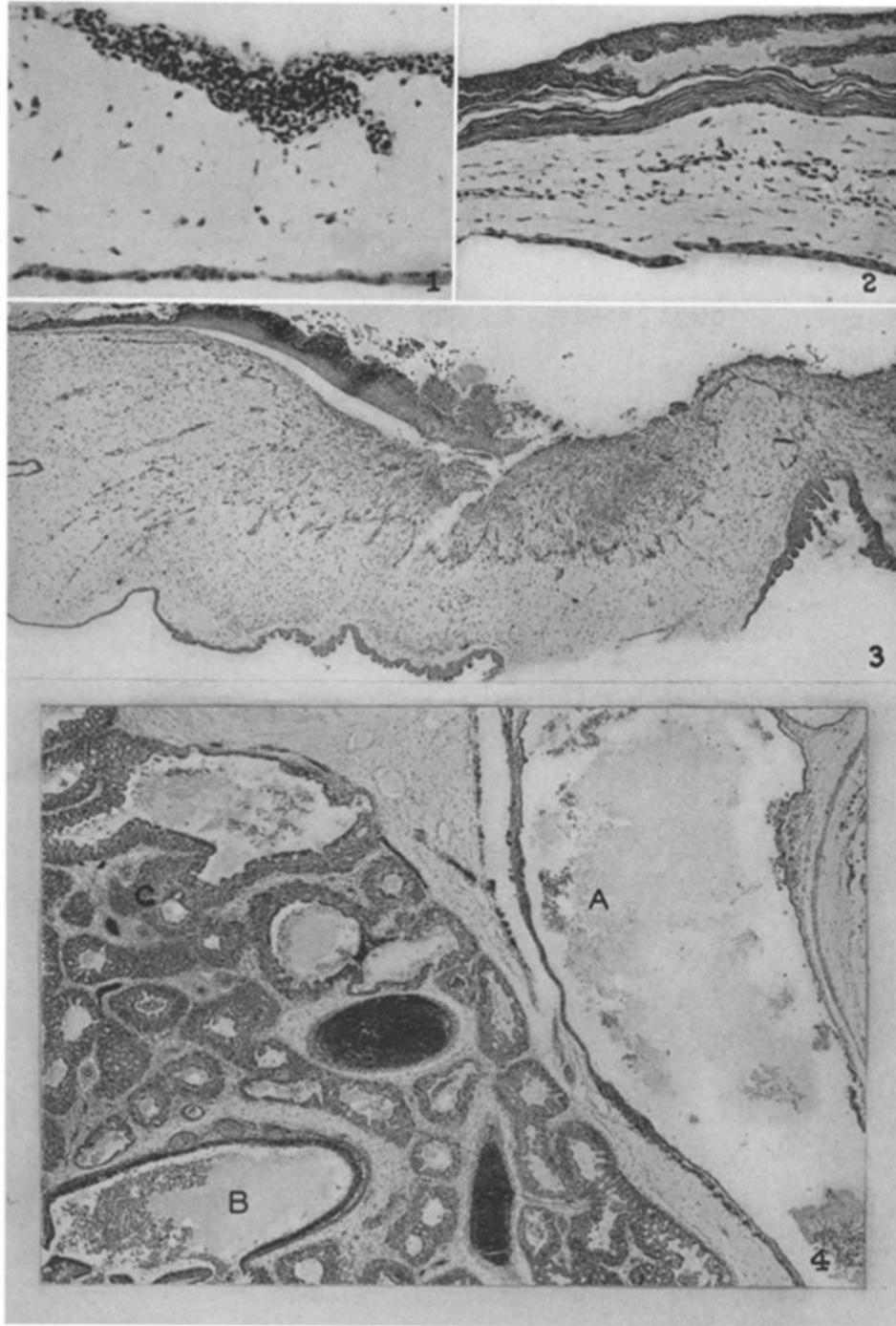
## PLATE 16

FIG. 1. 24 hour infection of chorio-allantoic membrane. Note slight ulceration. Hematoxylin and eosin.  $\times 225$ .

FIG. 2. Section from border of 5-day old infection of chorio-allantoic membrane. Note plastic exudate. Hematoxylin and eosin.  $\times 120$ .

FIG. 3. 48 hour infection of chorio-allantoic membrane. Ulcer followed inoculation with bacterial loop. Note hyperplasia of ectoderm. Hematoxylin and eosin.  $\times 36$ .

FIG. 4. Lung of 14 day chick embryo inoculated intra-amniotically. Infection is 72 hours old. Note exudate in air sac at *A*, in bronchus at *B*, and in alveoli at *C*. Wright's stain.  $\times 36$ .



(Bang: Gonococcus infection of chick embryo)

PLATE 17

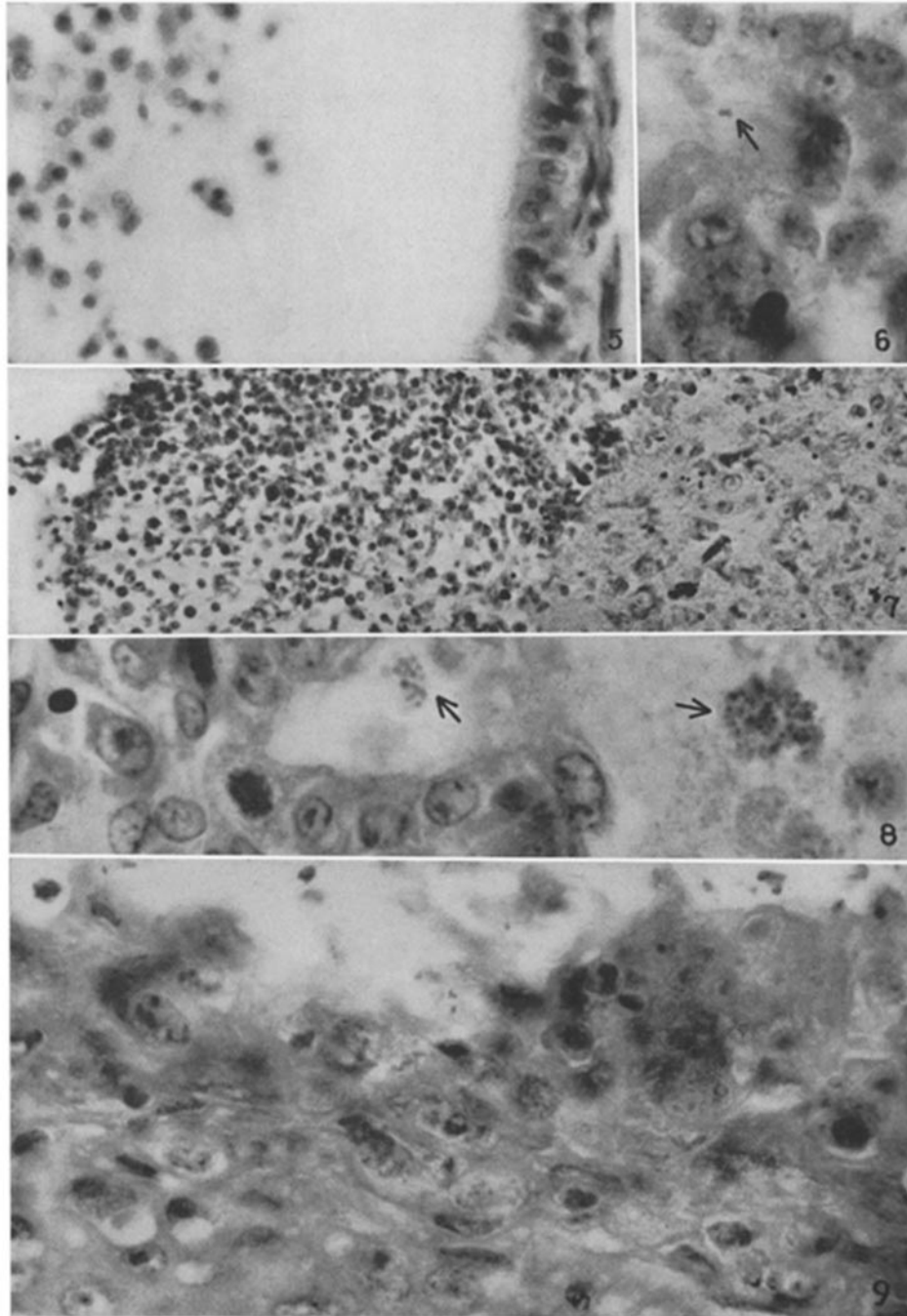
FIG. 5. Enlargement of Fig. 4. Exudate in air sac. Wright's stain.  $\times 600$ .

FIG. 6. Enlargement of Fig. 7. Arrow points to diplococci. Wright's stain.  $\times 2000$ .

FIG. 7. Meningitis in 14 day embryo infected intra-amniotically. Infection 72 hours old. Wright's stain.  $\times 250$ .

FIG. 8. 48 hour infection of 14-day old chick inoculated intra-amniotically. Arrows point to clumps of bacteria in alveoli. Wright's stain.  $\times 2000$ .

FIG. 9. Detail of Fig. 3. 48 hour infection of chorio-allantoic membrane. Note ulceration of thickened ectoderm. Polymorphonuclears are seen penetrating the ectoderm. Hematoxylin and eosin.  $\times 1600$ .



(Bang: Gonococcus infection of chick embryo)