

## ORAL PAPILLOMATOSIS OF RABBITS: A VIRUS DISEASE

BY ROBERT J. PARSONS, M.D., AND JOHN G. KIDD, M.D.

(From the Laboratories of The Rockefeller Institute for Medical Research)

PLATES 10 TO 12

(Received for publication, April 24, 1942)

Small benign papillomas were found several years ago on the tongue of a domestic rabbit with induced vitamin A deficiency (1), and investigation disclosed that similar growths are frequent on the oral mucous membranes of "normal" domestic rabbits. These naturally occurring growths have proved due to a filtrable virus, hitherto unrecognized, with which the lesions can be reproduced both in the domestic rabbit and in several species of wild hares (2). The natural and experimental growths are described in the present report, along with some of the properties of the virus responsible for them. Observations and experiments are also recorded which throw light on the transmission of the virus under natural conditions and upon certain factors that condition its effectiveness.

### *The Natural and Induced Growths*

Naturally occurring oral papillomas were found in 118 of 722 domestic rabbits examined. The incidence of the growths will be discussed in detail further on in relation to the age, breed, and provenance of the rabbits.

The papillomas are small, discrete, gray-white, sessile or pedunculated nodules, usually multiple and sometimes numerous, situated almost always on the under surface of the tongue, occasionally on the gums, rarely on the floor of the mouth (Figs. 1 to 6). The larger ones have rugose, cauliflower-like surfaces and sometimes attain a diameter of 5 mm. and an elevation of 4 mm. (Fig. 2), while the smaller, which predominate, are almost smooth and hassock- or dome-shaped (Fig. 6). The experimental growths are identical in morphology, but are usually more numerous and often confluent when multiple inoculations have been made over a considerable area with a tattoo machine (Figs. 7 to 10).

The fully developed growths are composed of folded and greatly thickened epithelium supported on delicate branching papillae (Figs. 4, 5). Little difference can be seen between the cells of the basal layer of the papillomas and the corresponding ones of the normal epithelium. As differentiation takes place, however, striking abnormalities occur in the virus-infected cells: small, irregular vacuoles appear in the cytoplasm and the fine cytoplasmic granules gradually disappear, and instead of becoming narrow and compressed, the cells continue to increase in size in the Malpighian layer and eventually assume an irregularly polyhedral shape (Fig. 15). Vacuoles of increasing size are seen as the surface is approached, and the basophilic granules become fewer and fewer until finally the cytoplasm almost disappears, leaving little more than a few large, clear vacuoles within a well defined cell wall. The

nuclei in the basal layer of cells are round or oval, and slightly vesicular, and mitotic figures are more numerous than in the normal epithelium (Fig. 11). In the prickle cell layer (stratum spinosum) the nuclei become more and more vesicular and increase greatly in size (Fig. 15), while at the surface of the lesions they become compressed, irregularly shrunken, and dense. The fenestrated layer of cells at the surface retains a basic dye (methylene blue) in contrast to the dense, acidophilic, slightly keratinized surface of the normal mucous membrane of the rabbit's tongue. Many of the vacuolated cells contain irregular masses of hyaline acidophilic material in their cytoplasm.

The basal layer of the papillomas is always sharply demarcated from the subjacent connective tissue. No sign has been seen of invasion, the connective tissue papillae being notably free from cellular infiltration (Figs. 4, 5, and 15). Serial sections of several papillomas stained with phloxin-methylene blue showed no foreign bodies or bacteria in or near the growths.

*Intranuclear inclusions* were found in about 10 per cent of the growths of domestic rabbits. They were seen in the outer six to ten layers of cells in naturally occurring growths and in experimentally induced growths from 42 to 107 days after inoculation. They vary greatly in size and shape (Fig. 12), some having an almost uniform hyaline appearance, while others show slight stippling. They stain with varying intensity with phloxin or less well with methylene blue in the phloxin-methylene blue stain. The nuclei show clumping and margination of the chromatin with result in halos about the inclusions. The latter were not found in the cells of the normal oral mucosa, nor in those of oral mucous membranes that were healing after injury with the tattoo machine; nor were they found in the cells of papillomas produced with the virus in wild cottontail rabbits.

#### *Experimental Transmission of Oral Papillomatosis*

Various other papillomata of man, dogs, cattle, and rabbits are known to be caused by filtrable viruses (3); hence it seemed reasonable to seek a causative virus in the growths under study. Towards this end, attempts were made to transmit them by inoculating crude suspensions or Berkefeld filtrates into the oral mucous membranes (usually on the under surface of the tongue) of "normal" domestic and wild rabbits. The experiments proved successful.

*General Method.*—Papillomas, freshly removed or preserved for varying periods in a solution consisting of glycerol (Kahlbaum's, C.P.) and Locke's in equal parts, were ground in a mortar with sterile sand, and Tyrode's solution was slowly added (proportions 1:10 to 1:100 or more). The sand and gross tissue debris were then removed by low-speed centrifugation and the clear or slightly opalescent supernatant liquid taken off for inoculation, either as such or after filtration through a Berkefeld candle.

A speculum was used to open the mouths of the rabbits for examination or inoculation. It was made of  $\frac{3}{8}$  by  $\frac{1}{8}$  inch flat strip stainless steel which had been bent to form an isosceles triangle with an acute angle between the long sides (Fig. 16). The speculum was introduced at one side of the mouth just behind the incisor teeth, with the rabbit held upside down on the table. With the mouth thus held open, the tongue was pulled out with forceps and inoculation was carried out by tattooing a few drops

of the Tyrode suspension or filtrate into the under surface of the tongue with an electric tattoo machine fitted specially with nine small sewing needles. In most cases the whole anterior part of the under surface of the tongue as far back as the frenulum was thus inoculated. Only one extract was used on the tongue of any animal.

*In the first experiment* a crude 1.7 per cent suspension of papillomas obtained from the under surface of the tongues of nine domestic rabbits was used. The papillomas had been preserved in glycerol-Locke's solution for from 24 to 59 days at approximately 4°C. The suspension was tattooed into the under surface of the tongue of six adult brown-gray rabbits and one such rabbit 7 weeks old. Multiple, small, gray-white nodules were present on the tongues of four of the adults and the young rabbit on the 25th day. The mother of the young rabbit and another of the adults failed to develop lesions. The growths rapidly increased in size to form small papillomas, some discrete, others crowded closely together; in the gross and on microscopic section they were precisely like the ones from which the extract had been made.

The tongues of 81 adult domestic rabbits in all (gray-brown agouti hybrids, Dutch belted, Havanas, and blue-crosses) have been inoculated in the manner described with suspensions or filtrates of the growths. Papillomas developed in all except fifteen. Wild rabbits also proved susceptible. Of 55 wild cottontail rabbits (genus *Sylvilagus*) trapped in Kansas, only one failed to develop lesions following inoculation with potent virus suspensions. The papillomas were also produced experimentally in wild jack rabbits (genus *Lepus californicus*) from Kansas and snowshoe hares (genus *Lepus americanus*) from Maine.

#### *Course of the Experimental Papillomas*

When an extract of the oral papillomas was tattooed into the under surface of the tongue of wild or domestic rabbits, tiny, dome-shaped, translucent, gray-white nodules appeared at the inoculation sites after periods ranging from 6 to 38 days (average 14 days), depending in large part on the concentration of the extract used. The small gray nodules rapidly increased in size and formed rugose, sessile or pedunculated papillomas like those occurring under natural conditions (Figs. 9, 10). The growths usually increased in size for about a month, occasionally for a much longer period. Many persisted thereafter as such, some for as long as 400 days, but more frequently they dwindled away more or less slowly and finally vanished.

Some of the growths lost substance after they had persisted for about 30 days, becoming perceptibly smaller during the 3 to 7 days between examinations, their surfaces meanwhile losing rugosity. In most instances the dwindling continued until no visible trace was left after a further month. Occasionally the regression took place more swiftly, sometimes more slowly; and rarely the growths dwindled for a time and later enlarged progressively for weeks or months, as happens now and then with the virus-induced cutaneous papillomas of rabbits (4). Regression occurred earliest and progressed most rapidly in the animals bearing large numbers of growths on their

tongues, a fact paralleling the observation that regression of discrete Shope papillomas begins earlier and takes place more swiftly in animals bearing many growths than in those with few (4).

Microscopic examinations of the regressing tongue papillomas of twenty domestic and cottontail rabbits revealed no characteristic cellular changes in the early stages of the process. Later, when a lesion had regressed to such an extent that only a smooth, gray-white, slightly elevated mound marked the site from which the papilloma had sprung, the granules in the basal layers of cells stained poorly with methylene blue and a few irregular, small, clear vacuoles were seen in the cytoplasm, and often there was a moderate infiltration of the supporting connective tissue with lymphocytes and mononuclear phagocytes.

#### *Characteristics of the Causative Agent*

*Filtrability through Berkefeld Candles.*—On each of the nine occasions that a suspension of oral papillomas was passed through Berkefeld V or N candles, large numbers of papillomas resulted from the inoculation of the bacteria-free filtrates into susceptible animals. The average incubation period after inoculation with crude suspensions was less than 15 days, with Berkefeld V filtrates 19 days, and with Berkefeld N filtrates 23 days.

A standard filtration procedure was used. To 5 or 10 cc. of clear suspensions of oral papillomas, prepared as already described, 0.5 cc. of a 24-hour broth culture of *B. prodigiosus* was added to test the filters. The infected suspensions were passed through Berkefeld V or N candles at a negative pressure of not more than 8 mm. of mercury. Cultures were made in broth and on agar and blood agar plates of the initial suspensions, the suspensions after addition of *B. prodigiosus*, and of the filtrates. Only the crude suspensions after the addition of *B. prodigiosus* consistently showed bacterial growth. In experiments hereinafter reported the filtrates proved bacteria free without exception.

In an experiment that may be considered typical, the glycerolated oral papillomas from eighteen domestic rabbits were pooled and made into a 2 per cent suspension which was passed through a Berkefeld V candle. The filtrate was tattooed into the under surface of the tongues of eight domestic and three cottontail rabbits. 19 days later all of the cottontails and all but two of the domestic rabbits had developed characteristic papillomas. For purposes of further passage, growths from two of the above cottontails and one of the domestic rabbits were removed 31 days after inoculation. A 6 per cent Tyrode extract of these was passed through a Berkefeld V candle. The filtrate was tattooed into the under surface of the tongues of five domestic rabbits. Typical growths resulted in all.

*Stability of the Causative Agent.*—Many experiments have shown that the agent causing oral papillomatosis is a very stable one. For stock material, the papillomas were stored in 50 per cent glycerol-Locke's solution in the refrigerator at about 4°C. In general the glycerolated papillomas yielded as much of the pathogenic agent as fresh ones, and very potent inocula were prepared from materials kept in glycerol for many months (377 days in one instance, 703 days in another). The agent withstands freezing for long periods: a Berkefeld N filtrate preserved at -22°C. for 40 days yielded very numerous papillomas upon inoculation into susceptible hosts. Suspensions prepared from papillomas dried while frozen have always proved effective.

*Resistance of the Agent to Heat.*—Pooled oral papillomas of a number of rabbits were used in each of three experiments, glycerolated materials in the first two, fresh ones in the third. Water-clear suspensions (1:100 in Tyrode, pH 7.4) were prepared in the usual manner and distributed in glass ampoules (0.8 cc. or less in each), which were then sealed. One ampoule was kept at room temperature as control; the others were submerged in water baths previously brought to temperatures of 55°, 60°, 65°, 70°, 75°, and 80°C. The temperatures were accurately maintained for 30 minutes, and then the tubes were rapidly cooled under running water. The various suspensions were tattooed into the under surface of the tongue of a number of normal animals. Whenever possible cottontails were used as test animals since these only rarely prove resistant to the virus. To avoid contaminations, the material heated to the highest temperature was inoculated first, the next highest next, and so on to the unheated control, which was always done last. The tattoo machine and other instruments were sterilized in boiling water for at least 3 minutes before each inoculation. The test animals were examined at intervals of 3 to 5 days from the 6th to the 60th days, always with sterilized instruments and in the same order in which they had been inoculated.

The results of the three experiments are summarized in Table I. From this it will be seen that heating at temperatures of 55°, 60°, and 65°C. for 30 minutes had no very noteworthy effect upon the pathogenic agent. Confluent or semiconfluent papillomas appeared promptly in all of the test rabbits inoculated with these materials, as also in those receiving the control inocula. Heating at 70°C., however, markedly reduced the effectiveness of the materials, no growths appearing in five of the ten test rabbits and only scattered discrete ones in the rest. The materials heated at 75°C. yielded no growths in five test rabbits, a few scattered papillomas which appeared late in one (D20) and confluent papillomas in another (D22). The material heated at 80°C. in Experiment 1 gave negative results upon inoculation into two cottontails.

The findings as a whole would appear to indicate that the agent was unaffected when the crude suspensions containing it were heated at 55°, 60°, or 65°C. for 30 minutes, but that it was partially inactivated at 70°C. and completely at 75° and 80°C. The results in two of the rabbits receiving 75°C. heated material (D20 and 22) are anomalous and will be discussed in detail further on.

The characteristics of the causative agent as given thus far would seem to indicate that it is a filtrable virus. Other findings, to be given further on, furnish additional evidence in this relation.

#### *The Oral Papilloma Virus as Distinct from the Skin Papilloma Virus (Shope)*

It was important at the outset to learn whether the virus responsible for the oral papillomas has any relation to another papilloma virus much used in this laboratory,—namely the Shope virus,—which is effective in the skin of several species of rabbits (12). In a first experiment towards this end, the Shope virus was inoculated into the skin and oral mucosa of “normal” domestic rabbits, and later the oral mucous membranes, which had proved refractory to the Shope virus, were tested for susceptibility to the oral papilloma virus.

A 10 per cent suspension in Tyrode of natural Shope papillomas (preserved in glycerol-Locke's) was tattooed into the dorsal and ventral surfaces of the tongue of four normal domestic rabbits, and also into the inside of the cheeks, across the hare lip from skin to skin, and in a continuous line from the gum outward over the lip and across the mucocutaneous junction onto the skin. Characteristic Shope papillomas appeared within 14 days in all of the rabbits wherever the skin had been inoculated, but none was found on any part of the mucous membranes. The Shope papillomas stopped

TABLE I  
*Resistance of Oral Papilloma Virus to Heat*

Heating (30 mins.)	Results of inoculations			Experiment No.
	Test rabbit	Papillomas	Incubation period <i>days</i>	
Unheated, controls	W17	++++	6	1
	W18	++++	11	1
	W58	++++	14	3
	W59	++++	14	3
	D31	++++	14	2
	D32	++++	14	2
55°C.	W19	++++	17	1
	W20	+++	11	1
60°C.	W21	++++	11	1
	W22	++++	8	1
	W61	++++	14	3
	D29	++++	14	2
	D30	++++	14	2
65°C.	W23	+++	11	1
	W24	++++	8	1
	W62	++++	14	3
	W63	++	14	3
	W64	++++	14	3
	W51	++++	14	2
	D27	+++	17	2
	D28	++++	14	2
70°C.	W25	-	-	1
	W26	++	19	1
	W65	+	20	3
	W66	++	14	3
	W67	++	14	3
	W50	-	-	2
	D23	+	22	2
	D24	-	-	2
	D25	-	-	2
	D26	-	-	2

TABLE I—*Concluded*

Heating (30 mins.)	Results of inoculations			Experiment No.
	Test rabbit	Papillomas	Incubation period <i>days</i>	
75°C.	W68	—	—	3
	W69	—	—	3
	W70	—	—	3
	W49	—	—	2
	D21	—	—	2
	D20	+	22	2
	D22	++++*	14	2
80°C.	W27	—	—	1
	W28	—	—	1

W = wild cottontail rabbit; D = domestic rabbit.

++++ = confluent papillomas.  
 +++ = semiconfluent papillomas.  
 ++ = many discrete papillomas.  
 + = few discrete papillomas.  
 — = negative.

\* For a discussion of the anomalous results, see text.

abruptly at the mucocutaneous junctions (Fig. 14, compare with Fig. 13). By the 25th day the cutaneous papillomas had increased greatly in size. A pooled suspension of oral papillomas was then tattooed into a small area on the under surface of the left side of the tongue of each of the four animals. Small oral papillomas of characteristic sort, sharply localized at the site of inoculation, were noted on the 7th day in three of the four animals. These gradually increased in size and later proved typical when examined under the microscope.

The experiment demonstrates the markedly specific tissue affinity of the Shope virus and shows that animals bearing growths due to it are susceptible to infection with the oral papilloma virus. The findings have been confirmed many times. In one experiment twelve domestic and eighteen cottontail rabbits in which Shope papillomas had long been present or had recently regressed were inoculated in the routine way with oral papilloma virus. Six of the domestic rabbits and all of the cottontails proved susceptible, as was shown by the appearance of characteristic oral papillomas at the inoculation sites on the under surfaces of their tongues. The existence of an effective immunity to the Shope virus was proved at the same time in four of the twelve domestic rabbits and in six of the eighteen cottontails by rubbing a suspension of Shope papilloma virus (shown to be potent in control animals) into the scarified skin. In none did any growths develop. Conversely, the presence or recent

regression of oral papillomas in domestic rabbits does not result in any perceptible resistance to the skin papilloma virus, as many experiments have shown.

*Tissue Affinity of the Oral Papilloma Virus*

As already stated, the naturally occurring growths are usually found on the under surface of the tongue of domestic rabbits, rarely on the dorsum of the tongue, the floor of the mouth, or the lips (Figs. 4, 13). In the experiments described thus far the virus "took" readily when inoculated into the under surface of the tongue of wild and domestic rabbits. The experiments now to be described were devised to test the susceptibility of other tissues and other species to the virus.

A potent Berkefeld V filtrate of the glycerolated growths of eighteen animals was tattooed into the following mucous surfaces of three wild cottontail and eight domestic rabbits: both sides of the raphe on the under surface of the tongue, upper surface of the tongue, inside of left cheek, right and left gum pads (floor of mouth), hare lip, just inside left nostril, left palpebral conjunctiva, and the external genitalia (male and female), and also into the shaved abdominal skin of each animal. The test rabbits were examined 19 days later and at intervals of a few days thereafter. Many papillomas appeared at the inoculation sites on the ventral surface of the tongue of all of the animals except two of the domestic rabbits. The animals were kept under observation for 31 to 287 days, but no papillomas developed at any of the other sites.

The same Berkefeld V filtrate was tattooed into the under surface of the tongue of six white mice, six albino rats, and five guinea pigs, and into the tongues and gums of three puppies (5 to 8 months old). No papillomas resulted.

In another experiment the susceptibility of the oral mucous membrane of wild snowshoe rabbits was tested. A crude suspension (cleared by centrifugation) of pooled glycerolated oral papillomas was tattooed into the under surface of the tongue of two such animals recently trapped in Maine. One died 9 days later, without papillomas. Confluent papillomas covered the under surface of the tongue of the other 17 days after inoculation.

The mucous membrane of the under surface of the tongue of five recently captured jack rabbits was tested in the same way but with a virus suspension made from the pooled glycerolated papillomas of four rabbits. No papillomas developed, although four domestic rabbits inoculated with the same suspension at the same time showed numerous papillomas 14 days later. Several weeks after the first inoculation the five jack rabbits were reinoculated with another virus suspension, shown by test on control animals to have a high potency. 14 days later three small lesions were present in the inoculated area on the tongue of one of them. These remained small until the animal was sacrificed on the 34th day, and then proved microscopically to be characteristic virus-induced tongue papillomas. The remaining jack rabbits failed to develop lesions.

Data obtained from several other experiments indicate that the oral mucosa of domestic rabbits is generally susceptible to the action of the virus. During the course of the tattoo inoculations the dorsal surface of the tongue was sometimes injured with the forceps and the floor of the mouth was now and then abraded with the speculum.



Papillomas developed on the dorsum of the tongue in six instances and on the floor of the mouth in eight of the 81 domestic rabbits inoculated. One of the 55 wild cottontails inoculated in the same way developed a papilloma on the top of the tongue. Dropping virus suspensions onto the lips of domestic rabbits with tarred ears often resulted in the development of many papillomas on the mucous membrane of the lips, as will be described further on.

Careful search failed to reveal papillomas in the bronchi, esophagus, stomach, or intestines of a number of rabbits carrying the natural and experimental growths.

The data indicate that the mucous membranes of the ventral surface of the tongue of domestic, wild cottontail, and wild snowshoe rabbits are highly susceptible to the virus. The mucous membrane of the floor of the mouth and the dorsal surface of the tongue of these species and that on the under surface of the tongue of wild jack rabbits show a lesser degree of susceptibility. The mucosa of the lips of domestic rabbits also proved susceptible. The inoculation of active virus into other mucous surfaces and the skin of rabbits and into the oral mucous membrane of dogs, rats, mice, and guinea pigs failed to give rise to papillomas.

#### *Resistance and Immunity to the Oral Papilloma Virus*

As already remarked, fifteen of the 81 "normal" domestic rabbits inoculated with virus suspensions of proved potency failed to develop lesions. Five of them bore naturally occurring papillomas at the time of inoculation; the others showed no evidence of previously existing lesions. Resistance to reinfection with the virus has been the rule after regression of experimentally induced papillomas. Virus suspensions of proved potency failed to engender lesions when inoculated into the tongues of five cottontails and nine domestic rabbits in which experimental papillomas had regressed (eleven rabbits) or were far along in this process (three rabbits).

#### *Natural Incidence of the Oral Papillomas*

During about two years a search was made for naturally occurring oral papillomas in every available wild and domestic rabbit. As already stated, they were found in 118 of 722 domestic rabbits; but none was seen in more than three hundred wild rabbits. Most of the domestic rabbits were young adults, market-bought from various dealers in the metropolitan area of New York, while some were Institute bred and many had been used for experimentation. In order to learn about the transmission of the virus under natural conditions, the incidence of the natural growths in various groups of rabbits was studied.

The rabbits were kept in individual cages though in several different rooms. They were cared for by various attendants, but all were fed the same diet, namely, purina pellets and hay; tarred rabbits and wild cottontails got fresh cabbage and carrots in addition. No striking difference was noted in the incidence of papillomas in rabbits situated in the various rooms.

Natural growths were present in 16.3 per cent of all of the domestic rabbits examined, and in 9.6 per cent of the 311 normal young adult rabbits, many of which were

bought outside the Institute (Table II). Only 3.6 per cent of 273 Institute bred rabbits less than 4 months of age bore papillomas. There was little difference in the incidence of the growths in adult agouti hybrids bought outside (18.4 per cent) and that in the Institute's inbred Dutch "show" rabbits (15.0 per cent). The growths were found also, and in roughly the same percentages, in market-bought chinchillas, Havanas, New Zealand reds, and albinos, and in Institute bred blue-cross hybrids, but the number of animals in each of these categories was deemed too small to warrant

TABLE II  
*Incidence of Naturally Occurring Oral Papillomas in Various Groups of Rabbits*

	Totals	Per cent with oral papillomas
All domestic rabbits.....	722	16.3
Normal young rabbits (less than 4 mos. old, raised in the Institute breeding rooms).....	273	3.7
Normal young adults (mostly agoutis, recently bought outside the Institute).....	311	9.6
Gray-brown agouti hybrids (market-bought, all ages).....	407	18.4
Pure bred Dutch "show" rabbits (Institute bred, all ages)...	80	15.0
Rabbits with Shope papillomas (adults, various breeds).....	158	23.4
Rabbits without Shope papillomas (adults, various breeds)...	62	24.2
Rabbits with tarred skin (adults, mostly gray-browns, kept long in the laboratory).....	63	42.8
All wild cottontails.....	312	0
Cottontails with Shope papillomas.....	16	0
Cottontails with tarred skin.....	80	0
Snowshoe rabbits.....	8	0
Jack rabbits.....	6	0

tabulation. The oral papillomas were present as often in rabbits with induced Shope papillomas (23.4 per cent) as in those used in other experiments (24.2 per cent). The highest incidence by far was in the rabbits with tarred skin (42.8 per cent), about which more will be said further on.

When viewed in the large, the results set down in Table II would seem to indicate that naturally occurring oral papillomas are widespread amongst domestic rabbits, that they are found more frequently in older rabbits kept some months in the laboratory than in young, newly bought ones, and that they are much more numerous in rabbits with tarred ears than in the generality. It seems doubtful, however, that effective amounts of the oral papilloma virus are spread from one adult rabbit to another in the animal rooms. For, as already mentioned, wild rabbits, though highly susceptible to experimental inoculation with the virus, failed to exhibit oral papillomas even after they had

been kept for many months in the same room with animals carrying the growths (Table II).

In seeking further for a clue to the mode of transmission of the virus under natural conditions, a striking difference was observed in the incidence of oral papillomas in various litters of young rabbits in the Institute breeding rooms. Occasionally, on examination 6 to 16 weeks after birth, two or three or more of the rabbits of a single litter would be found carrying the growths, whereas other litters were entirely free from them. The finding became strongly suggestive of transmission from mother to offspring when it was also observed that the dams of the high-incidence litters more often than not had naturally occurring oral papillomas (or proved resistant to the virus upon test, indicating previous contact with it), whereas the dams of the low-incidence litters seldom had papillomas. The figures are summarized in Table III.

TABLE III  
*Incidence of Oral Papillomas in Progeny of Dams (a) Carrying Oral Papillomas or Immune to the Causative Virus and (b) Free from Oral Papillomas*

Dams	No. of dams	Progeny		Incidence of oral papillomas in progeny	
		No. of litters	No. of rabbits	Litters	Rabbits
				<i>per cent</i>	<i>per cent</i>
(a) Carrying oral papillomas or immune to the causative virus.....	19*	21	76	28.6	11.8
(b) Free from oral papillomas (not tested for immunity to the virus).....	53	54	226	5.5	1.3

\* 14 carried oral papillomas; 5 were free from the growths but proved immune to the causative virus.

#### *Capacity of the Virus to Lie Latent*

The findings of Table III, just mentioned, suggested that the virus may somehow be passed from the mothers to the young during the period of suckling, and this in turn brought up the possibility that the virus might lie latent in the mouths of normal rabbits until favorable circumstances (injury or irritation to susceptible tissues) provided a nidus. In this relation it was recalled that characteristic oral papillomas developed in two domestic rabbits (D20 and D22 of Table I) inoculated with virus that had been heated at 75°C. Since this amount of heating ordinarily inactivates the virus, it seemed possible that the growths resulted from virus lying latent in the mouths of the rabbits at the time of inoculation. Hence an attempt was made to recover virus by washing out the mouths of various groups of rabbits, including normals.

Three groups of rabbits were used. Group (a) consisted of six agouti litter mates, 79 days old. Their mother on repeated examination was always free from oral papillomas. The young had been weaned 24 days earlier; none had papillomas then, nor

had they any at the time the washings were procured or 33 days thereafter. Group (b) was composed of four "normal" adult gray-browns, all of which had been kept in the "normal rabbit" room of the laboratory for at least 2 months. All had been examined when put into the room and some of them repeatedly afterwards. None had ever manifested oral papillomas, nor were these present on the day the mouth washings were procured. Two of the four animals, however, later developed characteristic growths, four small papillomas appearing in one animal on the 13th day after the washing and three tiny growths on the 27th day in the other. The third rabbit of the group had no growths when examined on the 13th and 33rd days; the fourth was killed by mistake 3 days after lavage. Group (c) consisted of five adult gray-brown domestic rabbits, three of which had exuberant confluent papillomas on the under surfaces of their tongues as result of the experimental inoculation of virus 18 days before, while each of the other two had several discrete naturally occurring oral papillomas.

TABLE IV  
*Tests for Oral Papilloma Virus in Mouth Washings from Various Groups of Domestic Rabbit*

Source of inocula* Mouth washings from	Test rabbits (cotton-tails)	Papillomas resulting from inoculations		
		15th day	25th day	37th day
(a) Six "normal" rabbits (litter mates), none of which had oral papillomas	1	0	0	0
	2	0	0	0
(b) Four "normal" rabbits, two of which later developed oral papillomas spontaneously	3	+	++	++
	4	+	+±	+±
(c) Five rabbits with oral papillomas	5	+++	++++	++++
	6	+++	++++	++++

\* The pooled mouth washings were dried while frozen and resuspended in a small volume of fluid (see text).

The rabbits were held head down over large sterile beakers and their mouths washed out with approximately 50 cc. of sterile distilled water, which was forced by gravity through a sterile glass pipette (bore, 1 mm.). The stream of water was directed especially at the floor of the mouth and the tongue. The washings from each group of rabbits were pooled, frozen in solid CO<sub>2</sub>, and dried under sulfuric acid in evacuated desiccators (8 days). The dried materials were then resuspended in 0.5 cc. of distilled water, yielding hazy, opalescent, greenish-gray, slightly viscid suspensions, which were tested for virus by tattooing them in the usual way into the under surfaces of the tongues of normal cottontails.

Table IV shows the outcome of the inoculations. No papillomas appeared in the test rabbits inoculated with the washing-concentrate derived from the six "normal" litter mates (group (a)). The material derived from the group (b) rabbits gave rise to scattered discrete papillomas, which increased greatly in number and size between the 15th and 25th days. The rabbits with oral papillomas (group (c)) provided a washing-concentrate which gave rise promptly to confluent papillomas in the test rabbits.

The results in Table IV show that large amounts of the oral papilloma virus can be washed out of the mouths of rabbits carrying the growths (group (c)), and they demonstrate that the virus is sometimes present in the mouths of apparently normal animals (group (b)). No virus was recovered from the mouth washings of six litter mates, 79 days old, whose mother on repeated examination had never shown growths (group (a)).

#### *Factors Conditioning Effectiveness of the Virus*

The findings given thus far would seem to indicate that the oral papilloma may be transmitted from mother to suckling young and may also be present in the mouths of apparently normal rabbits without causing growths. If this is so, under what conditions does the virus give rise to lesions? The findings of Table II show that the papillomas are more frequent in older rabbits than in young ones and that they are most prevalent in old rabbits with tarred skin. Can one suppose that comparatively trivial injuries to the under surface of the tongue (those incidental to chewing coarse hay, for example) provide the local conditions essential to the action of the virus, and that tar, which is invariably licked away from the skin or paws of tarred rabbits, renders the oral mucous membranes more susceptible? The results of several experiments throw light on these questions.

In a first experiment, virus was dropped repeatedly into the mouths of six gray-brown litter mates and tar was applied to both surfaces of the ears of three of them for many weeks thereafter, the other three serving as controls. The animals, all young adults weighing approximately 2 kilos, had been kept in separate cages since they were weaned. To avoid mechanical trauma their tongues were not examined prior to the beginning of the experiment.

A crude suspension of virus was used. It had been made by grinding the glycerolated oral papillomas of several domestic and cottontail rabbits and suspending the ground paste in Tyrode—approximately 1 part of glycerolated tissue to 50 of Tyrode—and clearing in the centrifuge. Two drops of the virus suspension were allowed to fall into the mouths of all six rabbits on 10 of the first 11 days of the experiment and twice weekly for the next 8 weeks. The mouths were not opened with the speculum for this procedure but the animals were held so that the virus drained downwards between the partially opened lips. At no time were the lips touched with instruments. The tar was that currently used in the laboratory to produce tumors in mice and rabbits, namely, the horizontal retort tar of the Ostergasfabrik of Amsterdam,—for which we thank Dr. Landsteiner. It was applied with a toothbrush to both surfaces of the ears of three of the rabbits, twice weekly for the first 9 weeks of the experiment and then, after a rest interval of 8 weeks, again twice weekly for a second period of 8 weeks. The three control litter mates were kept in adjacent cages in the same room and given the same diet throughout the experiment.

The mouths of the rabbits were examined on the 91st, 160th, and 224th days. Several small papillomas were present on the under surface of the tongue of two of the tarred rabbits (Nos. 1 and 2) at the first examination. Chart 1 shows the state of

affairs at the second examination (160th day). The growths of tarred rabbits 1 and 2 had enlarged and greatly increased in number and a solitary papilloma had appeared on the tongue of one of the untarred animals. There were four papillomas on the oral mucosa of the lips of rabbit 1 and one on a gum in addition to those charted. The growths were precisely the same on the 224th day, except that the solitary papilloma of rabbit 4 had disappeared. At this time rabbits 1 and 2 were killed, their growths

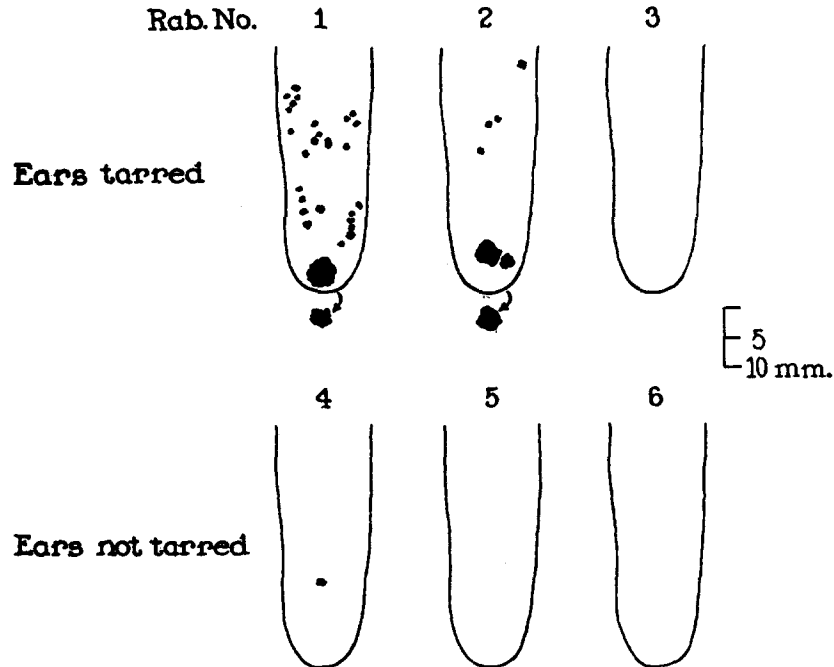


CHART 1. The incidence of tongue papillomas in rabbits of a single litter, some with tarred ears. Virus had been dropped into the mouths of all early in the experiment (see text). The silhouettes outline papillomas that developed on the ventral tongue surfaces in rabbits 1, 2, and 4, and the arrows point to solitary growths situated on the dorsal tongue surfaces in rabbits 1 and 2. An abundance of virus was recovered from the pooled papillomas of these two animals.

harvested, and an extract of these tested for virus. A 1 per cent saline suspension was tattooed into the tongues of three normal rabbits. 18 days later confluent and semi-confluent tongue papillomas of characteristic sort had arisen at the inoculated sites in all three test rabbits.

In a second experiment the tongues of nine domestic rabbits 3 to 4 months old were examined and found to show no papillomas. Tar was applied twice weekly to the ears of five of these animals, and a potent virus suspension, made as usual, was dropped twice weekly into the mouths of all of them. At the end of 13 weeks multiple papillomas were present on the tongues of three of the five tarred animals. The untarred rabbits remained negative except for one, which developed a solitary growth.

Attempts were also made to increase the susceptibility of the oral mucosa by injecting Scharlach R and 1:2:5:6 dibenzanthracene in olive oil repeatedly into and beneath it. In several animals injected twice weekly for a month with these materials, tattoo inoculation of the oral papilloma virus resulted in growths of the usual sort, if anything less numerous in the treated areas than in the normal. Several weeks after the virus inoculations, the growths were precisely like those deriving from normal mucosa. Microscopic examination revealed no change in the oral epithelium as result of the injections, nor any noteworthy cellular proliferation elsewhere. In the muscle and connective tissue of the tongues, large mononuclear macrophages had surrounded and partially taken up the oil droplets.

In other experiments of similar sort Scharlach R and dibenzanthracene respectively were injected into the base of oral papillomas repeatedly over long periods of time with a view to altering the character of the growths, but this did not happen. In one instance, Scharlach R was injected into oral papillomas once a week during several months. The growths persisted for 446 days; upon microscopic examination then they proved to be mere benign papillomas of the usual sort.

The facts just described leave little room for doubt that tar is effective in increasing the susceptibility of the oral mucous membrane to the action of the virus. It seems probable that the effect may be a local one, for tarred rabbits spend many hours licking tar from their skin and paws. No noteworthy gross or microscopic changes were noted in the oral mucosa of the tarred rabbits, and the papillomas that appeared in the tarred animals were no different from those in the untarred. None tended towards malignancy, and extracts of several of them yielded oral papilloma virus in abundance. In this relation it is worth noting that the same tar, applied repeatedly over long periods to the ears of wild cottontail rabbits and eliciting numerous cutaneous papillomas and carcinomas in them, never brought out oral papillomas as it did in the domestic rabbits (Table II): the wild animals presumably do not carry the causative virus, though highly susceptible to it.

#### DISCUSSION

The oral papillomatosis here described is worth attention from several points of view. Though prevalent in laboratory rabbits, it has hitherto gone unregarded except for brief mention by Brown and Pearce (5) and by Bonne who came upon them in tarred rabbits but did not inquire into their character (6). The growth adds one more to the list of papillomata due to viruses (3).

Most of the papillomas due to other viruses remain benign and some regularly regress. The Shope rabbit papilloma, however, frequently becomes cancerous, and the papillomatous growths due to the virus of condyloma acuminatum sometimes do so (9). The oral papillomas of rabbits show no such tendency but remain benign and often persist for several months, sometimes for a year or more, in which respect they resemble the virus-induced, cutaneous warts of human beings. Reference need scarcely be made to the fact that the viruses responsible for the papillomata of man, dogs, and cattle are all distinctly

different, both in pathogenic and antigenic properties, and repeated tests have shown that none of these will "take" in species other than those in which it occurs naturally (3, 7). The oral papilloma virus, however, and the Shope papilloma virus are effective in several species of rabbits, though each exhibits a markedly specific affinity for cells of a certain type. In contrast to these findings, Serra (3) and Findlay (3) have reported that the virus responsible for condyloma acuminatum in man will give rise to papillomas upon inoculation into the skin of human beings, and Ullman extracted from a boy's laryngeal papilloma a filtrable agent that produced papillomas upon inoculation into the skin of adult volunteers (3). The latter author claims to have produced a papilloma in the vagina of a bitch upon inoculation with an extract of a laryngeal papilloma of human origin, but Findlay (3) was unable to confirm this finding. Kumer reported the transmission to a rabbit of a papilloma of the oral mucosa of the chamois (8), but the photograph of the induced rabbit papillomas indicates that they were similar to the naturally occurring growths here described. It is possible that Kumer, traumatizing the oral mucosa while making inoculations, provided a nidus for oral papilloma virus already present in the mouth of his rabbit, as apparently happened in one of our experiments, in which papillomas appeared following the tattoo inoculation of material inactivated by heat (Table I).

In recent years pathologists have come to recognize more and more the existence of diseases that are transmitted in obscure ways,—herpes, lymphocytic choriomeningitis, virus III infections, swine influenza, to cite but a few.<sup>1</sup> A possible example of the sort is provided by the "milk influence," which passes from the female mouse to its offspring and exerts a determining influence on the occurrence of mammary cancer (10). It is in this connection that the virus of oral papillomatosis has greatest interest. Its method of transmission would appear to be relatively simple, by a direct handing along in the family, from mouth to mouth as one might say, by way probably of the teat, which the mother may lick between nursings. The virus can be handed on and yet cause no lesions, as is also true of the "milk influence;" but it will act directly on the traumatized mucosa, causing growths there, whereas the milk factor is not immediately pathogenic when directly inoculated, and causes cancer only after the females suckling it have become adults and the mammary glands have undergone development. The influence of tar to increase the effectiveness of the oral papilloma virus is noteworthy (Table II and Chart 1), not only because tar elicits tumors but also because it so influences tissues as to render them abnormally responsive to the action of several viruses, notably certain neoplastic ones (11). Whether the cutaneous papillomas elicited by tar may have viruses as their intrinsic cause is a question that has been discussed elsewhere (12).

<sup>1</sup> For a discussion of latent virus infections and their possible relevance to the cancer problem, see Andrewes, C. H., *Proc. Roy. Soc. Med.*, 1939, **33**, 75.



## SUMMARY AND COMMENT

Papillomas occur frequently on the oral mucosa of domestic rabbits procured in the metropolitan area of New York. They are small and benign, and are situated mostly on the under side of the tongue. A filtrable virus can be extracted from them with which growths can be reproduced in the oral mucosa of several species of rabbits and hares but which fails to cause lesions when inoculated into other rabbit tissues and into the oral mucosa of other species. The virus differs notably from the Shope virus, which causes cutaneous papillomas in rabbits but proves innocuous to oral mucosa: rabbits solidly immune to the oral papilloma virus are fully susceptible to the Shope virus and *vice versa*.

The oral papillomas are not highly contagious, for susceptible animals kept in individual cages in the same rooms with others carrying the growths, fed the same kind of food, and cared for by the same attendants, do not "catch" them. They are found much more frequently in the offspring of dams that carry the growths than in those of mothers free from them, and the causative virus can be recovered from the mouth washings of rabbits having no growths. The observations indicate that the virus may be spread by transfer from the mother to the young during the period of suckling, and that it may lie latent in the mouth, doing no harm unless the mucous membrane is injured. The slight trauma occurring now and then when coarse foods are chewed may furnish the required tissue nidus under natural conditions, for papillomas occasionally appear after virus has been dropped into the mouths of uninoculated rabbits; but the more extensive injury and healing resulting from experimental tattoo inoculations proves regularly effective in this respect. Tar can also act as an efficient adjuvant to the virus, the incidence of "spontaneous" oral papillomas being much higher in domestic rabbits that had had the opportunity to lick tar from their ears and paws during long periods than in normal control animals. The virus is recoverable in quantity from the oral papillomas of tarred domestic rabbits, and the findings indicate that it is their essential cause, the tar acting merely to prepare the tissue for the virus' action. For the same tar does not elicit oral papillomas in wild cottontail rabbits, which do not carry the causative virus though fully susceptible to it.

The implications of the findings are discussed.

## BIBLIOGRAPHY

1. Kidd, J. G., and Parsons, R. J., *Proc. Soc. Exp. Biol. and Med.*, 1936, **35**, 438.
2. Parsons, R. J., and Kidd, J. G., *Proc. Soc. Exp. Biol. and Med.*, 1936, **35**, 441.
3. Ciuffo, G., *Gior. ital. mal. ven.*, 1907, **42**, 12. Serra, A., *Gior. ital. mal. ven.*, 1908, **43**, 11; 1924, **65**, 1808. Magalhães, A., *Brazin-med.*, 1920, **34**, 431. Kingery, L. B., *J. Am. Med. Assn.*, 1921, **76**, 440. Ullmann, E. V., *Acta oto-laryngol.*, Stockholm, 1923, **5**, 317; *Dermat. Woch.*, 1930, **91**, 1864. Creech, G. T., *J. Agric. Research*, 1929, **39**, 723. Findlay, G. M., in *A system of bacteriology in relation to medicine*, Great Britain Medical Research Council, London,

- His Majesty's Stationery Office, 1930, **7**, 252. DeMonbreun, W. A., and Goodpasture, E. W., *Am. J. Path.*, 1932, **8**, 43. Shope, R. E., *J. Exp. Med.*, 1933, **58**, 607.
4. Kidd, J. G., *J. Exp. Med.*, 1938, **67**, 551.
  5. Brown, W. H., and Pearce, L., *J. Exp. Med.*, 1920, **32**, 497.
  6. Bonne, C., *Compt. rend. Soc. biol.*, 1925, **93**, 907; *Z. Krebsforsch.*, 1927, **25**, 1.
  7. Beard, J. W., and Kidd, J. G., *Proc. Soc. Exp. Biol. and Med.*, 1936, **34**, 451.
  8. Kumer, L., *Wien. klin. Woch.*, 1935, **48**, 890.
  9. Rous, P., and Beard, J. W., *J. Exp. Med.*, 1935, **62**, 523. Konjetzny, G. E., *Munch. med. Woch.*, 1914, **61**, 905. Buschke, A., and Loewenstein, L., *Klin. Woch.*, 1925, **4**, 1726; *Arch. Dermat. u. Syph.*, 1931, **163**, 30. Mühlpfordt, H., *Dermat. Woch.*, 1928, **87**, 1403. Israel, W., *Z. Urol.*, 1928, **22**, 395. Frei, W., *Arch. Dermat. u. Syph.*, 1930, **160**, 109.
  10. Bittner, J. J., *Science*, 1936, **84**, 162; 1941, **93**, 527.
  11. Teague, O., and Goodpasture, E. W., *J. Med. Research*, 1923-24, **44**, 185. Rous, P., and Kidd, J. G., *J. Exp. Med.*, 1938, **67**, 399; 1938, **68**, 529. Ahlström, C. G., and Andrewes, C. H., *J. Path. and Bact.*, 1938, **47**, 65, 87.
  12. Rous, P., and Kidd, J. G., *J. Exp. Med.*, 1939, **69**, 399.

#### EXPLANATION OF PLATES

The sections were stained with eosin and methylene blue except where otherwise noted.

These photographs were made by Mr. Joseph B. Haulenbeek.

#### PLATE 10

FIG. 1. Naturally occurring papillomas on the under surface of the tongue of a normal domestic rabbit (D305N).  $\times 4$ .

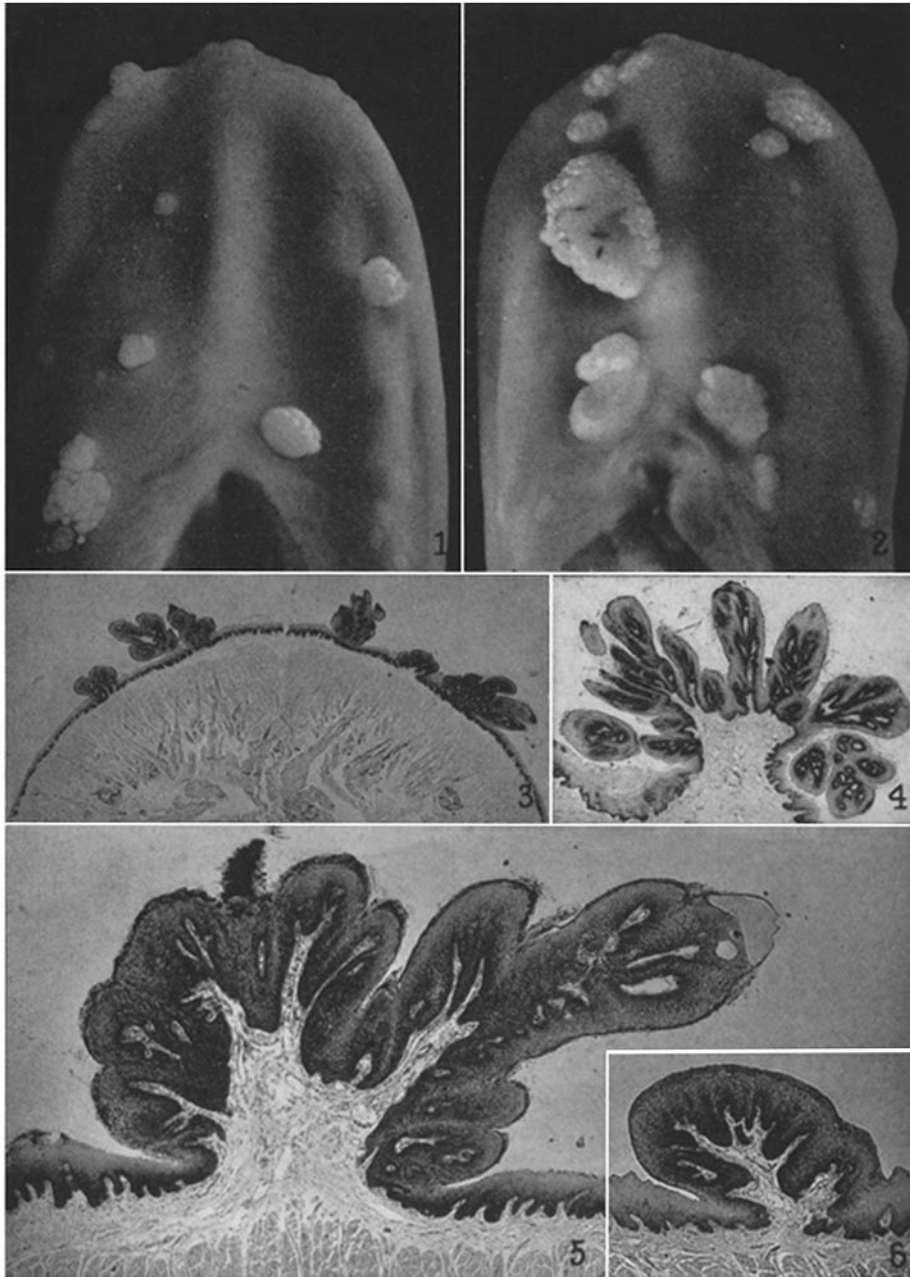
FIG. 2. Naturally occurring papillomas on the under surface of the tongue of a normal domestic rabbit (D500N). The large growth was constricted at the base and measured  $5 \times 4 \times 4$  mm.  $\times 4$ .

FIG. 3. Cross-section of six of the fifteen naturally occurring papillomas found on the under surface of the tongue of a domestic rabbit (A15N).  $\times 6$ .

FIG. 4. Cross-section of an unusually large papilloma found on the floor of the mouth of a domestic rabbit (D52).  $\times 13$ .

FIG. 5. Higher magnification of a papilloma occurring on the under surface of the tongue of a normal domestic rabbit (A15N). The folded hyperplastic epithelium is supported on delicate branching connective tissue papillae.  $\times 35$ .

FIG. 6. Small papilloma with a relatively regular surface. Section from D305N, Fig. 1. Hematoxylin and eosin stain.  $\times 35$ .



(Parsons and Kidd: Oral papillomatosis of rabbits: virus disease)

#### PLATE 11

FIG. 7. Discrete and semiconfluent papillomas 50 days after the tattoo inoculation of the under surface of the tongue of a normal domestic rabbit (D397N) with a Berkefeld N filtrate prepared from oral papillomas.  $\times 4$ .

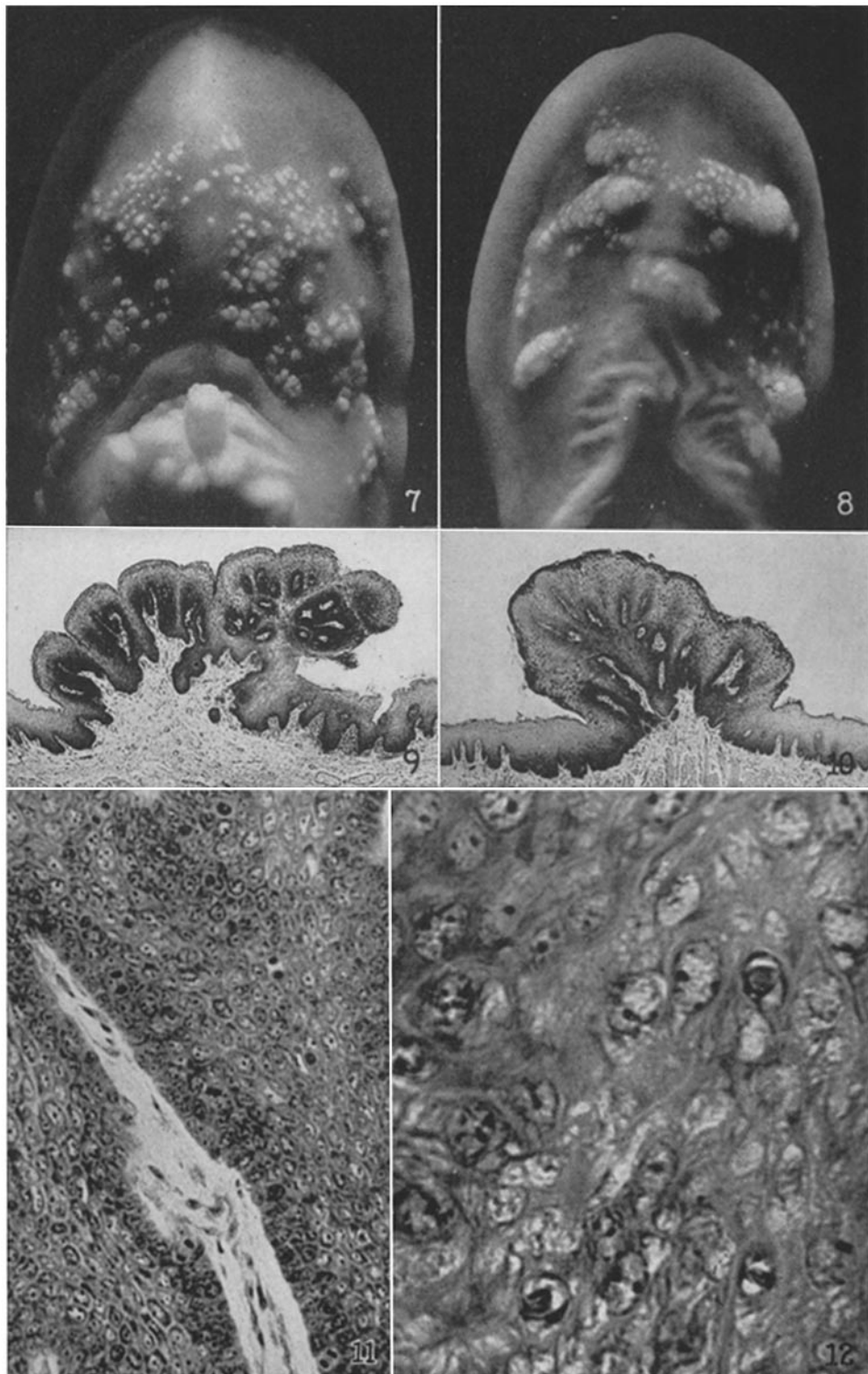
FIG. 8. Discrete and confluent papillomas 31 days after the tattoo inoculation of a Berkefeld V filtrate into the under surface of the tongue of a normal wild cottontail rabbit (W1).  $\times 4$ .

FIG. 9. Cross-section of a papilloma induced on the under surface of the tongue of a domestic rabbit (D280N). Virus had been inoculated 41 days previously. (Compare with Fig. 5.)  $\times 35$ .

FIG. 10. Cross-section of a papilloma induced on the under surface of the tongue of a wild cottontail rabbit (W7). Virus had been inoculated 241 days previously. The papilloma, which had been visible for 230 days, had been six times its present size, but gradual retrogression with consequent reduction in size had been going on for 4 months before the section was taken.  $\times 35$ .

FIG. 11. Mitotic figures in the hyperplastic epithelium of a naturally occurring papilloma from a normal domestic rabbit (A15N).  $\times 300$ .

FIG. 12. The large, irregular, dark bodies within the nuclei of three of the cells are acidophilic inclusion bodies such as are described in the text. The section was taken through a growth induced by the inoculation 49 days before of a Berkefeld V filtrate of oral papillomas into the tongue of a normal brown-gray rabbit (D1). Similar inclusion bodies are to be found in naturally occurring papillomas.  $\times 610$ .



(Parsons and Kidd: Oral papillomatosis of rabbits: virus disease)

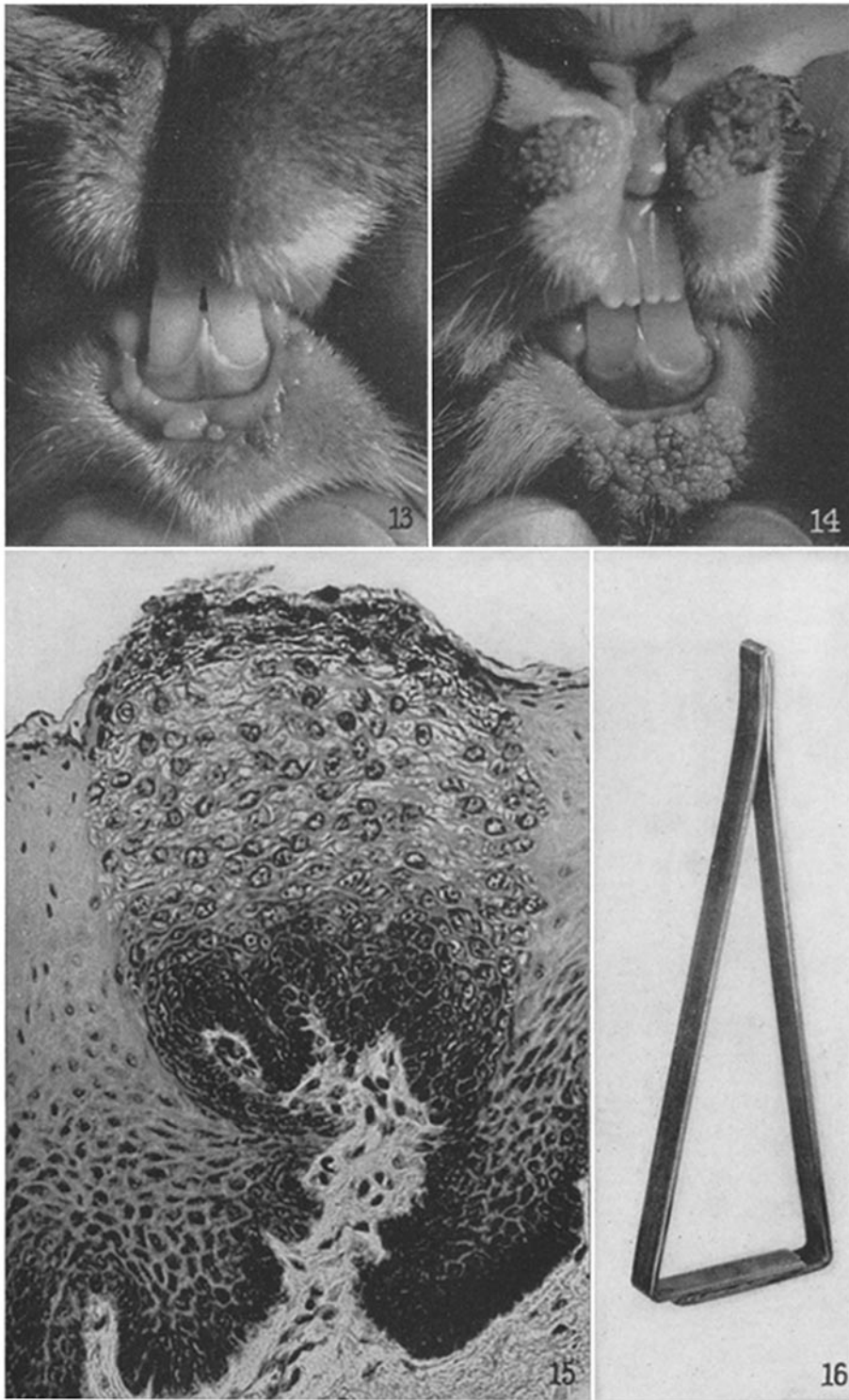
PLATE 12

FIG. 13. Papillomas occurring naturally near the mucocutaneous junction of the lower lip of a domestic rabbit (D123N). Tar had recently been applied on repeated occasions to the skin of the rabbit's ears.  $\times 2$ .

FIG. 14. Cutaneous papillomas resulting from inoculation of the Shope virus. They are situated next the mucocutaneous junction of the lower lip and hare lip. The virus had been tattooed over a straight line extending from left to right across the hare lip and starting on the gum of the lower incisor teeth downward and outward over the mucosa of the lower lip across the mucocutaneous junction and onto the skin. Growths appeared on the skin only. (Compare with Fig. 13.)  $\times 2$ .

FIG. 15. A small, discrete papilloma which was induced on the under surface of the tongue of a domestic rabbit (D1) by the inoculation of a Berkefeld V filtrate 49 days previously. Note the sharp line of demarcation between the normal and the virus-infected epithelium. The appearance and increase in size of the cytoplasmic vacuoles as the cells approach the surface of the lesion will be noted. Other characteristic findings are noted in the text.  $\times 300$ .

FIG. 16. The speculum used to open the mouths of rabbits for examination or inoculation.



(Parsons and Kidd: Oral papillomatosis of rabbits: virus disease)