

THE SUPERINFECTION OF THE RABBIT PAPILLOMA
(SHOPE) BY EXTRANEOUS VIRUSES*

By JEROME T. SYVERTON, M.D., AND GEORGE PACKER BERRY, M.D.

(From the Department of Bacteriology, The University of Rochester School of
Medicine and Dentistry, Rochester, New York)

PLATES 12 TO 14

(Received for publication, March 19, 1947)

A benign virus-induced tumor, the Shope rabbit papilloma (1), may undergo alterative changes in an expected and established sequence to become a malignant epidermoid carcinoma (2-6). The relation of the virus responsible for the initial growth to the final cancer, or to the cells of that cancer, is not known. At least four explanations for the relationship suggest themselves. Firstly, the papilloma and the ultimate cancer have the same etiological agent, the papilloma virus; secondly, the papilloma virus becomes modified during the papilloma-to-carcinoma sequence and is present in the cells of the cancer in a changed or disguised form functioning as its essential cause; thirdly, the papilloma virus by initiating and actuating a growth with the immediate characters of a benign tumor, namely the papilloma, which ultimately undergoes carcinomatous degeneration, serves as a provocative carcinogenic agent; or, fourthly, the papilloma virus, once the growth becomes carcinomatous, is carried as a passenger in the cells of the cancer. The last possibility appeared to offer the best approach to a study of the rôle of the papilloma virus in the papilloma-to-carcinoma sequence. To explore one phase of this problem, we undertook to determine whether the cells of the virus-induced papilloma, or the cells of the cancers derived therefrom, could be superinfected by extraneous viruses; *i.e.*, viruses that are extraneous in the sense that they have no etiologic relationship to the tumors under investigation. That cells integrant to the papilloma-to-carcinoma sequence adequately support the growth of extraneous viruses has been briefly recorded by Levaditi and Schoen (7) for the benign phase and by ourselves for both the benign and malignant phases (8). Moreover, multiple virus infection of individual host cells has been described (9, 10). The work on which our preliminary notes were based has been amplified by further experimentation and will be presented in detail in two papers.

The studies described in the present report were designed to establish the superinfection by extraneous viruses of the cells of virus-induced papilloma

* This investigation was aided by a grant from The Jane Coffin Childs Memorial Fund for Medical Research.

Reported in abstract before the American Association for the Advancement of Science, Rochester, New York, June 18, 1936. See *J. Bact.*, 1936, **32**, 356.

(cells that contain the Shope papilloma virus) and of an epidermoid carcinoma derived therefrom.

When we described our first studies (8), and when Levaditi and Schoen reported theirs (7), no evidence had been reported that cells containing a virus could be superinfected by unrelated viruses. Levaditi and Schoen described the superinfection of the epithelial cells of the virus papilloma (Shope) with vaccine virus, but they were unsuccessful when herpes virus was employed as the superinfecting agent.

In contrast to this limited use of virus tumors for infection by extraneous viruses, the thought of a virus being carried along in the cells of a cancer is not a new one. Levaditi and Nicolau (11) first reported that transplantable tumors of mice, rats, rabbits, and chickens supported the growth of viruses which had been introduced experimentally. Continuing these investigations, Levaditi and his associates (12, 13) successfully demonstrated the infection of a variety of tumors of unknown cause by many viruses (herpes, vaccinia, rabies, fowl pest, and lymphogranuloma venereum).

Further experimental work employing tumor cells for infection by viruses has been reported. Hallauer (14) found that tissue cultures of the cells of a mouse carcinoma would support fowl pest virus, whereas other mouse tissues would not. Mellanby (15) successfully infected tar- and dibenzanthracene-induced sarcomas of chickens with the Rous sarcoma agent by injecting the virus at a distant site. Although he was unable to demonstrate an alterative effect on the chemically-induced tumors, cell-free filtrates prepared from these tumors produced a Rous sarcoma. On the other hand, cells from these tumors on transplantation yielded tumors of homologous type from which virus was not recoverable. Findlay and MacCallum (16) found that yellow fever virus grew readily in the cells of a mouse carcinoma, and that certain strains of the virus could be carried for as many as 50 passages without any apparent change in their pathogenicity. The investigations of Rous and Kidd (17) have demonstrated the modifying influence of a virus on preexisting tumors of unknown cause. They describe remarkable effects as due to the infection of tar tumors of rabbits with the rabbit papilloma virus. The virus had an activating, transforming, and carcinogenic effect, whether the tar tumors were located superficially or followed implantation. Andrewes *et al.*, (18) reported single sarcomas originating in each of two rabbits after repeated intramuscular injections of tar and a single intravenous injection of fibroma virus (Shope). One of these sarcomas was transplanted serially, but repeated attempts to demonstrate fibroma virus either directly or by immunological tests were unsuccessful.

Histopathological evidence to suggest that a virus can be a superinfecting agent in tumors or even the responsible etiological agent has been presented occasionally. Thus, Russell (19) reported the presence of intranuclear inclusion bodies in 33 per cent of 192 human gliomata. Wolf and Orton (20) obtained similar results from a comparable study. Since the inclusion bodies that they described conformed in appearance to type B intranuclear inclusions, further work is needed to evaluate their findings.

Of significance to the present investigation is the well known discovery by Rivers and Pearce (21) that a transplantable malignant tumor of rabbits, the Brown-Pearce rabbit epithelioma, was spontaneously infected with a virus, virus III, and that this

virus was maintained and carried in successive tumor transplants even when the host was immune to reinfection with the same virus. Andrewes (22), moreover, found virus III occurring as a passenger in a transplantable sarcoma which originated at the site of intramuscular tar injections, and also as a superinfective agent in cells of the infectious fibroma of rabbits (Shope) (23). The extraneous virus, virus III, produced inclusion bodies in the fibroma cells, focal necroses of the tissues, and an accelerated regression of the growths. The presence of inclusion bodies in nearly all the cells of the passaged fibroma is natural evidence, supporting the experimental findings, that cells can support multiple infection by viruses (8-10). Andrewes observed further that complete suppression of the fibroma resulted when a mixture of fibroma virus and virus III was injected. This should not be interpreted as an "interference phenomenon," for the infection of the host cells by the virus of the shorter incubation period, virus III, would naturally destroy enough cells to make it difficult for the virus with the longer incubation period, fibroma virus, to propagate. This effect is similar to the suppressive or inhibitory effect which has been observed when a virus is injected at a site where the cells have been injured or destroyed as the result of exposure to Roentgen rays (24).

Materials and Methods

Viruses.—Papilloma virus and five extraneous viruses each capable of producing readily recognizable and diagnostically significant inclusion bodies were employed.

The papilloma virus (Shope) (1) was obtained from papillomas that were present on cottontail rabbits (genus, *Sylvilagus*) when they arrived from Kansas, where they had become infected under natural conditions.

The Brazilian strain of infectious myxomatosis of rabbits (Sanarelli) (25) was employed. It was obtained from Dr. T. M. Rivers in whose laboratory at the Rockefeller Institute it had been carried in rabbits for a number of years. This highly virulent strain gives rise to a rapidly progressive disease which is characterized by rapid proliferation of cells with extensive metastases and death of the host. When examined histologically, the gelatinous tissue is found to consist of vascularized myxomatous tissue with large stellate cells. The epithelial cells in epidermis overlying the myxomatous tissue contain readily recognizable cytoplasmic inclusion bodies. Metastatic lesions in the skin of domestic rabbits were used to provide source virus.

The strain of B virus (26) had been obtained from Dr. A. B. Sabin. Its parenteral injection gives rise to a uniformly fatal encephalomyelitis in rabbits. Although the virus is predominantly necrotizing, with edema, hemorrhage, and infiltration by polymorphonuclear and mononuclear cells as secondary phenomena, type A intranuclear inclusion bodies can be seen in infected cells of the epithelium at the site of injection and in the central nervous system. We used tissue from the brain and cord of rabbits recently dead or moribund to provide source virus.

The virus III employed was a testicular-passage strain obtained from Dr. Rivers (27). This strain gives rise to local erythema, edema, tumefaction, a variable cellular infiltration, and type A intranuclear inclusion bodies in from 3 to 5 days after inoculation. Testicular tissue infected 4 days previously provided source virus.

The strain of vaccine virus employed was that used by the New York City Board of Health. It was maintained in our laboratory by testicular passage in rabbits and by passage on the chorio-allantoic membrane of chicks according to the Goodpasture technique (28). The virus, when used either in tissue suspension or as washed elementary bodies, produces typical

lesions with moderate necrotization and the formation of numerous cytoplasmic inclusion (Guarnieri) bodies in epithelial cells.

The highly virulent HF strain of herpes virus, isolated in 1922 by Flexner and Amoss (29), was employed. Although essentially neurotropic, this strain will attack cells derived from all three embryonic layers to produce microscopic changes which include the production of type A intranuclear inclusion bodies. The immediate source of virus for the present experiments was brain tissue of rabbits or mice that had died following inoculation of the virus by either the intracerebral or corneal routes.

Animals.—Eighty-three (*Oryctolagus*) and cottontail (*Sylvilagus*) rabbits were used in the present study. Six were normal rabbits; twenty-six had preexisting papillomas initiated 10 to 150 days previously by rubbing 0.1 ml. of virus suspension on a prepared, lightly scarified cutaneous site (approximately 2 cm. in diameter); one had an epidermoid carcinoma; and fifty were either immune or non-immune animals that were used to confirm the specificity of virus superinfections.

Preparation of Virus Suspensions.—The suspension to serve as inoculum was prepared from virus-containing tissues immediately after their removal. Using aseptic precautions, the tissues were weighed, ground in a mortar to a fine paste with an abrasive¹ and Locke's solution to yield the concentration desired. This suspension was centrifuged horizontally at 3000 R.P.M. for 30 minutes and the supernatant fluid, or a decimal dilution thereof, was used as the inoculum. The amount of inoculum and the route of injection are given in each protocol.

Technique for Infecting Cells.—Two methods were utilized in superinfecting papilloma cells with viruses. The method most frequently employed was that of infiltrative inoculation. Infiltration of a suspension through a small gauge needle (22 to 27 gauge) brought a single virus, or a mixture of two or three viruses, into immediate contact with susceptible cells and usually resulted in their parasitization.

A second method was employed to determine the tropism of papilloma cells for extraneous viruses. The virus was introduced at a site as far removed from preexisting papillomas as was conveniently possible and after a suitable interval attempts were made to elicit evidence of its presence in the papilloma cells.

Fixation and Staining.—Representative blocks of all infected tissues were secured for histopathological study immediately after the rabbits had been killed by inhalation of chloroform. The pieces of tissue were fixed in Zenker's (5 per cent acetic acid) fixative fluid and embedded in paraffin. The sections were stained with hematoxylin and eosin and according to Giemsa's method. Exceptionally, these stains were supplemented by phloxin-methylene blue and eosin-methylene blue.

EXPERIMENTS

That the cells of a virus-induced growth have been superinfected by one or more extraneous viruses becomes apparent only when these cells show intracellular changes characteristic of the extraneous agent. When careful histopathological study reveals such changes, one is justified in inferring that the extraneous virus is within that particular cell. Complementary evidence to show that a second virus is present, or even a third virus, are recovery of each virus by suitable animal passage and its identification by suitable immunological procedures. These criteria were employed in the present studies.

¹ Alundum, procured from Norton Company, Worcester, Massachusetts.

Superinfection of the Cells of a Preexisting Virus Lesion by a Single Etiologically Distinct Virus

Four preliminary experiments were planned to learn whether the epithelial cells of the benign virus-induced papilloma (Shope) can be superinfected by single extraneous viruses. The data and findings that relate to these four experiments (Experiments 1, 2, 3, and 4) are summarized in Table I.

TABLE I
Results of Experiments 1, 2, 3, and 4
Proof that Cells of the Rabbit Papilloma Were Superinfected by a Single Extraneous Virus

Experiment No.	Animal host		Superinfecting virus				Results					Interpretation	
	Rabbit No.*	Papillomas		Name	Reciprocal of dilution	Duration of superinfection	Histologic examination		Confirmatory tests				Proof of superinfection by extraneous virus
		No. infected	Age				Inclusion bodies		No. of rabbits employed	Recovery of virus	Immunologic tests		
							Intranuclear	Cytoplasmic					
1	DR1-1	1	37	B virus	10	1	6	+	-	2	+	-	Yes
	DR1-2	"	"					"	"		0	-	"
2	CR2-1	2	70	Vaccinia	100	"	5	-	+	6	+	+	Yes
	DR2-2	"	"					"	"		-	+	"
3	DR3-1	"	163	Virus III	10	"	6	0	-	2	+	+	?
	DR3-2	"	"					"	"		0	-	"
4	CR4-1	"	125	Herpes	"	"	10	0	-	"	0	-	No
	CR4-2	"	"					"	"		0	-	"

* DR = domestic rabbit; CR = cottontail rabbit.

From the data summarized in Table I, it can be seen that the results of these first four experiments established the fact that epithelial cells of the virus-induced papilloma, cells that presumably contain papilloma virus, can be superinfected by a single extraneous virus (Figs. 1 to 4). Of the four viruses, B virus, vaccinia, virus III, and herpes virus, utilized for superinfection, B virus (Fig. 1) and vaccinia (Figs. 2 and 3) gave intracellular evidence of their presence. No specific evidence for superinfection by herpes virus or virus III resulted, on the other hand, when these viruses were used. Animal inoculation

and immunological tests verified the presence of virus III, but did not yield herpes virus in papillomatous tissue removed for examination 10 and 16 days, respectively, after such lesions had been infiltrated with herpes virus.

*Superinfection of the Cells of a Preexisting Virus Lesion by Two
Distinct Viruses*

When it was learned from the first four experiments that a single virus can superinfect the epithelial cells of the rabbit papilloma, a second group of experiments (Experiments 5, 6, and 7) was planned to find out whether two extraneous viruses could simultaneously superinfect the papilloma, and, if possible, single papilloma cells. The data relating to these three experiments are presented in Table II.

From the findings of Experiments 5, 6, and 7, it was evident that the tumor readily supported the growth of two extraneous viruses, and that microscopic examination of single papilloma cells showed evidence for simultaneous parasitization by both viruses. A different combination of two viruses was employed for each experiment.

It can be seen from the results of Experiment 5 that the rabbit papilloma can be superinfected by B virus and myxoma virus injected simultaneously. Four of the five rabbits yielded evidence for the presence of intranuclear and cytoplasmic inclusion bodies in papilloma cells (Figs. 4 to 8). Moreover, in papillomas on two of these animals, both types of inclusion body appeared to be present in single cells (Figs. 5 and 6).

The results of Experiment 6 gave further evidence that papilloma cells can be readily superinfected by vaccinia virus. Evidence for infection by both vaccinia virus and virus III, on the other hand, was found in but a single animal (Fig. 9), and none of five animals yielded cells that contained both an intranuclear and a cytoplasmic inclusion body.

Experiment 7 yielded cytological evidence for the presence of vaccinia and B viruses in the superinfected papillomas (Fig. 10), but satisfactory evidence for the presence of both viruses in a single cell was not found. It was noted that the necrotizing effect of the two viruses in combination was great.

A further and final attempt was made in an eighth experiment to elicit intracellular evidence for the presence of two viruses in papilloma cells. This experiment was designed to determine what effects would result from the simultaneous infiltration of three viruses into preexisting papillomas on hosts that were immune to one of the viruses. It was hoped that an accelerated or hyperimmune generalized tissue reaction might advantageously affect the host's response to yield better results than those obtained previously. Accordingly, a mixture of myxoma, vaccinia, and B viruses was inoculated into papillomas on two rabbits that had recovered from infectious myxomatosis.

Experiment 8. Superinfection with B Virus and Vaccine Virus in the Presence of an Immune or Accelerated Response to Virus.—Sixty-four-day-old papillomas on two domestic rabbits

TABLE II
Results of Experiments 5, 6, and 7
Proof that Cells of the Rabbit Papilloma Were Superinfected Simultaneously by Two Extraneous Viruses

Experiment No.	Animal host		Superinfecting virus					Results					Interpretation		
	Rabbit No. *	Papillomas	Name	Reciprocal of dilution	Amount	Duration of superinfection	Histologic examination		Confirmatory tests			Proof of superinfection by			
		No. infected					Age	Intranuclear	Cytoplasmic	No. of rabbits employed	Recovery of viruses				Immunologic tests
							One virus	Two viruses	Same cell						
5	DR5-1	4	147	B virus	See	1	5	+	+	-	-	-	Yes	Yes	Yes
	DR5-2	"	"	and	foot-	"	"	+	+	-	-	-	"	"	No
	DR5-3	"	50	myx-	note‡	"	"	+	+	-	-	-	"	"	Yes
	DR5-4	"	20	oma	below	"	"	0	0	-	-	-	No	No	No
	DR5-5	"	"	virus		"	6	+	+	-	-	-	Yes	Yes	"
6	DR6-1	"	137		See	"	4	+	+	-	-	-	"	"	"
	DR6-2	"	"	virus III	foot-	"	6	0	+	-	-	-	"	No	"
	DR6-3	"	50	and	note‡	"	3	0	+	-	-	-	"	"	"
	DR6-4	"	"	vac-	note§	"	3	0	+	-	-	-	"	"	"
	CR6-5	"	"	cinia	below	"	17	0	0	4	+	+	?	?	"
7	DR7-1	"	25	B virus	See	"	5	0	0	6	+	+	Yes	Yes	"
	DR7-2	"	"	and	foot-	"	6	0	0	"	+	+	"	"	"

* DR = domestic rabbit; CR = cottontail rabbit.

‡ Four papillomas on each rabbit were infiltrated with decimal dilutions, 10¹ through 10⁴, of a mixture consisting of equal parts of a 10 per cent suspension of B virus and 1 per cent suspension of the other virus employed.

§ The injection of virus III was followed in 10 days by the injection of vaccinia virus.

that had recovered from infectious myxomatosis were infiltrated with a mixture made up from equal parts of 10 per cent tissue suspensions of three viruses, B virus, vaccinia, and myxoma virus. Both rabbits were acutely ill 48 hours later.

When rabbit DR8-1 was killed on the 4th day after injection, each lesion had an erythematous areola but no other change. Microscopic examination showed numerous, minute, circumscribed abscesses with many mononuclear and a few polymorphonuclear cells in the neighboring tissues, and a few Guarnieri bodies. No intranuclear or cytoplasmic inclusion bodies of the myxoma type were seen.

When rabbit DR8-2 was killed 5 days after its papillomas had been injected with the mixture of viruses, a marked inflammatory areola outlined the superinfected lesions and degenerative changes were apparent in the lesions that had received the 10^2 and 10^3 dilutions. Microscopic examination revealed marked changes in the subcutaneous tissues, where edema, dilatation of the blood vessels with some extravasation, polymorphonuclear infiltration, and areas of necrosis were present. The epithelial cells of the overlying epidermis were undergoing degenerative changes and a few contained typical type A intranuclear inclusion bodies such as are formed by B virus.

The greatly heightened tissue response of both hosts, and the demonstration of intranuclear inclusion bodies of type A in the papilloma cells of one rabbit and cytoplasmic inclusion bodies of vaccinia virus in the cells of the other rabbit, made it clear that the three viruses employed were active. In no instance, however, were inclusion bodies of both types present in a single cell, or even in sections taken from a single papilloma.

*Superinfection of the Cells of the Virus Papilloma of Rabbits with Virus
III in an Effort to Establish Histological Evidence of Its Long
Persistence*

Although we had been unsuccessful in demonstrating intracellular evidence for the parasitization of papilloma cells by virus III, its known affinity for the epithelial cells of the Brown-Pearce epithelioma (21) made it seem probable that a similar relationship could be shown for virus III and the cells of the virus papilloma. Accordingly, a ninth experiment was designed to find out whether virus III would parasitize the cells of the virus papilloma and thereafter maintain its association with them.

Experiment 9. Superinfection of Papillomas with Virus III.—Papillomas from 83 to 175 days old on each of five rabbits (DR9-1, DR9-2, DR9-3, DR9-4, and DR9-5) were infiltrated with virus III and biopsied for microscopic study 6, 8, 20, 84, and 120 days later. Microscopically, no evidence for the presence of virus III was observed.

The results of the ninth experiment gave no evidence that virus III had superinfected the epithelial cells of the virus papilloma when histological sections taken at intervals over a period of 4 months were studied.

Tropism of Myxoma Virus for Epithelial Cells in Preexisting Papillomas

After we had established that the direct introduction of viruses into papillomas on domestic and cottontail rabbits can result in intracellular evidence of superinfection of single papilloma cells, it became desirable to determine

whether the actively growing epithelial cells of these tumors would exert a tropic effect on an extraneous virus when it was introduced into the normal skin at a site distantly removed from the papilloma. Accordingly, a tenth experiment was undertaken, employing myxoma virus as the extraneous agent.

Experiment 10. The Infection of Papilloma Cells by Introducing Myxoma Virus at a Site Removed from the Tumor.—Four rabbits carrying actively growing papillomas were infected with myxoma virus, two by introducing intracutaneously 0.25 ml. of a 10^8 dilution of myxomatous tissue suspension at a site distantly removed from the papillomas, and the other two animals by placing them in a cage with a case of infectious myxomatosis.

Both rabbit DR10-1 with 231-day-old papillomas and rabbit DR10-2 with 10-day-old papillomas died of infectious myxomatosis 10 days after the virus had been injected intracutaneously. Portions of the test papillomas were removed for study. Microscopically, almost every cell of the basal layers had been superinfected by myxoma virus, as shown by the presence of cytoplasmic inclusion bodies characteristic of myxoma infections.

Rabbit DR10-3 had 30-day-old papillomas when it contracted rapidly fulminating infectious myxomatosis as result of accidental infection. Microscopically, most of the epithelial cells contained the typical cytoplasmic inclusion bodies of myxoma.

Rabbit DR10-4 carried 35-day-old papillomas when it contracted infectious myxomatosis by contact with its cage mate, DR10-3. Its general course and the microscopic findings were essentially the same as described for DR10-3.

The results of the tenth experiment constituted good evidence for the tropism of the epithelial cells of actively growing rabbit papillomas for myxoma virus. It was found that histological sections prepared from lesions on each rabbit showed numerous cytoplasmic inclusion bodies in almost all the epithelial cells of the basal layers.

Virus Superinfection of the Cells of an Epidermoid Carcinoma Derived from a Virus Papilloma

The successful demonstration of the ability of extraneous viruses to superinfect epithelial cells of the rabbit papilloma led us to determine whether cells representing a terminal phase of the papilloma-to-carcinoma sequence, cells of an epidermoid carcinoma, could be parasitized by an experimentally introduced extraneous virus, B virus, and, if so, to learn whether histopathological evidence of B virus infection would be present in the cells of metastatic lesions in lymph nodes and lungs. Accordingly, an eleventh experiment was carried out.

Experiment 11. Superinfection with B Virus.—Rabbit DR11-1, which carried an epidermoid carcinoma with metastases to the lymph nodes and lungs, was used. The primary carcinomatous lesions were infiltrated with a B virus suspension through a needle in the usual way. When the animal died of encephalomyelitis 7 days later, portions of the primary and metastatic carcinomatous lesions were removed for study. Microscopic examination confirmed the diagnosis of epidermoid carcinoma (Fig. 11), and revealed type A intranuclear inclusion bodies in the cancer cells (Figs. 12, 13, and 14). Moreover, many of these cells had undergone amitotic nuclear division from stimulation by B virus, which resulted in from 2 to

8 inclusion bodies within single cells (Fig. 14). Microscopic study of the metastatic lesions in lymph nodes and lungs, however, gave no evidence for infection by B virus.

The results of Experiment 11 made it clear that the epithelial cells of an epidermoid carcinoma (representing a final phase of the virus papilloma-to-carcinoma sequence) can be readily infected by an extraneous virus, B virus.

DISCUSSION

The experiments described herein were undertaken to learn whether a virus-induced tumor, the rabbit papilloma (Shope), and single cells thereof, could be superinfected by one or more extraneous viruses.

Our criteria for parasitization included the histopathological finding of specific inclusion bodies, the recovery of each virus by suitable animal passage, and the identification of each virus by suitable immunological procedures. Although these criteria could not be rigidly fulfilled in every case, we believe the evidence presented is adequate to establish the fact that papillomas, and single cells integrant to these tumors, were experimentally parasitized by one virus in some of the experiments and by two viruses in other experiments. A similar study of control tumors from the same animals, on the other hand, gave no evidence for the presence of an extraneous virus. Furthermore, since the cells of the rabbit papilloma presumably contain the specific virus responsible for this growth, our experiments seem to indicate that the cells of these growths can support coexistent parasitization by three different viruses.

Though the results of the present experiments strongly suggest, they do not prove that a single cell was parasitized by three viruses. Even though cytoplasmic and intranuclear inclusion bodies characteristic of the viruses used for superinfection seem to be in the same cell, it is possible in a stratified epithelial structure such as the rabbit papilloma that immediately adjacent cells overlying each other appear as a single cell—make it appear that two inclusion bodies, one cytoplasmic and the other intranuclear, are in a single cell whereas in reality each is contained within a different cell.²

Intracellular changes have been observed in papilloma cells which suggest natural superinfection of papillomas by viruses. Rous, Beard, and Kidd, (30) reported the presence of intranuclear inclusion bodies, both types A and B, in virus-induced rabbit papillomas which showed gross histopathological differences from the papillomas usually seen. Their attempts to transmit the agent

² In an attempt to obviate the possibility of erroneously concluding that multiple virus infection of a single cell had occurred because of observing inclusion bodies in cells overlying one another, we undertook further studies in which normal epithelial cells of the cornea were parasitized by several viruses. The results of this second investigation (9) satisfactorily substantiate the findings of the present investigation that single cells can be parasitized by several viruses at the same time.

supposedly responsible for the type B inclusion bodies were without success. We (8) too, have noted type B intranuclear inclusion bodies in the cells of certain papillomas; our efforts to evaluate their significance have been unsuccessful. As an explanation for our failure to demonstrate an extraneous virus, it occurred to us that the remarkable difficulty associated with the demonstration of papilloma virus in papillomas on domestic rabbits was not peculiar to the agent, but might also apply to extraneous viruses. It is possible, of course, that the type B inclusion bodies, which are so irregularly present, are non-specific in nature. This explanation seems most probable in view of the ease with which we have found that papillomas can be experimentally superinfected.

The present findings show that virus tumors, *per se*, are vulnerable to further attacks by extraneous viruses, obviously a matter of importance in the virus-tumor problem. It must be emphasized that the recovery of a virus from a tumor, or the presence in a tumor of histopathological changes secondary to virus activity, cannot be accepted as evidence of a specific etiological agent. Thus, we may consider virus tumors to be similar to non-virus tumors in their receptivity to parasitization by extraneous viruses. The extent to which this relationship can go is illustrated by the natural parasitization of the Brown-Pearce epithelioma by virus III (21).

It is clear that the cells of tumors can be easily infected under both natural and experimental conditions by viruses of no direct etiological significance. Moreover, these viruses can apparently be carried indefinitely by the tumor cells. It is obvious, therefore, that cognizance of this fact is essential to the investigation of any non-virus tumor, particularly since the presence of a virus in a tumor can mask the characteristic clinical and histological picture.

CONCLUSIONS

1. The potentialities that viruses have for the superinfection of virus tumors have not been recognized nor has the fact that a single cell can harbor more than one virus.
2. Rabbit papillomas, induced by the papilloma virus (Shope), were superinfected by B virus, myxoma virus, vaccinia virus, and probably, virus III. Similar attempts at superinfection by herpes virus were without success. The criteria for parasitization included the histopathological finding of specific inclusion bodies, the recovery of each virus by suitable animal passage, and the immunological identification of each virus.
3. Papillomas and probably the individual cells thereof were readily infected simultaneously by two viruses when the combination of B virus and myxoma virus was used.
4. Cells of the Shope papilloma have a selective affinity for certain extraneous

viruses introduced at a site distant from the tumor growths. It was found that exceptionally few cells in the basal layers of the epidermis escaped when myxoma virus was used as the superinfecting agent.

5. The cells of an epidermoid carcinoma which terminated the rabbit papilloma-to-carcinoma sequence were readily infected by B virus with resultant multiple intranuclear inclusion bodies in single cells.

6. Attempts to establish a prolonged superinfection of cells of the Shope papilloma by virus III were unsuccessful. This rabbit tumor differs therein from the Brown-Pearce tumor, an epithelioma of rabbits, in its susceptibility to infection with virus III.

BIBLIOGRAPHY

1. Shope, R. E., *J. Exp. Med.*, 1933, **58**, 607.
2. Rous, P., and Beard, J. W., *J. Exp. Med.*, 1935, **62**, 523.
3. Syverton, J. T., and Berry, G. P., *Proc. Soc. Exp. Biol. and Med.*, 1935, **33**, 399.
4. Rous, P., Kidd, J. G., and Beard, J. W., *J. Exp. Med.*, 1936, **64**, 385.
5. Syverton, J. T., *Proc. 3rd Internat. Cong. Microbiol.*, New York, 1939, 341.
6. Kidd, J. G., and Rous, P., *J. Exp. Med.*, 1940, **71**, 469.
7. Levaditi, C., and Schoen, R., *Compt. rend. Soc. biol.*, 1936, **122**, 736.
8. Syverton, J. T., and Berry, G. P., *J. Bact.*, 1936, **32**, 356; *Science*, 1937, **86**, 411.
9. Syverton, J. T., and Berry, G. P., *Am. J. Path.*, 1938, **14**, 633; *J. Exp. Med.*, 1947, **86**, 145.
10. Anderson, K., *Am. J. Path.*, 1942, **18**, 577.
11. Levaditi, C., and Nicolau, S., *Compt. rend. Acad. Sc.*, 1922, **174**, 1649; *Compt. rend. Soc. biol.*, 1922, **87**, 498; *Ann. Inst. Pasteur*, 1923, **37**, 443.
12. Levaditi, C., and Haber, P., *Compt. rend. Acad. Sc.*, 1936, **202**, 2018. Levaditi C., and Schoen, R., *Compt. rend. Acad. Sc.*, 1936, **202**, 702; *Compt. rend. Soc. biol.*, 1937, **125**, 607. Levaditi, C., Schoen, R., and Reinié, L., *Compt. rend. Soc. biol.*, 1937, **124**, 711; *Ann. Inst. Pasteur*, 1937, **58**, 353.
13. Schoen, R., *Compt. rend. Soc. biol.*, 1938, **128**, 135; *Ann. Inst. Pasteur*, 1938, **60**, 499.
14. Hallauer, C., *Z. Hyg. u. Infektionskrankh.*, 1931, **113**, 61; 1935, **116**, 456.
15. Mellanby, E., *12th Ann. Rep. Brit. Emp. Cancer Campaign*, London, 1935, 99; *J. Path. and Bact.*, 1938, **46**, 447.
16. Findlay, G. M., and MacCallum, F. O., *Tr. Roy. Soc. Trop. Med. and Hyg.* 1937, **30**, 507.
17. Rous, P., and Kidd, J. G., *Science*, 1936, **83**, 468; *Proc. Soc. Exp. Biol. and Med.*, 1937, **37**, 518; *J. Exp. Med.*, 1938, **67**, 399; 1938, **68**, 529; 1940, **71**, 787.
18. Andrewes, C. H., Ahlström, C. G., Foulds, L., and Gye, W. E., *Lancet*, 1937, **2**, 893; Andrewes, C. H., and Ahlström, C. G., *J. Path. and Bact.*, 1938, **47**, 87.
19. Russell, D. S., *J. Path. and Bact.*, 1932, **35**, 625.
20. Wolf, A., and Orton, S. T., *Bull. Neurol. Inst.*, New York, 1933, **3**, 113.
21. Rivers, T. M., and Pearce, L., *J. Exp. Med.*, 1925, **42**, 523.

22. Andrewes, C. H., *J. Path. and Bact.*, 1940, **50**, 227.
23. Shope, R. E., *J. Exp. Med.*, 1932, **56**, 793.
24. Lacassagne, A., *Compt. rend. Soc. biol.*, 1937, **125**, 96.
25. Sanarelli, G., *Centr. Bakt., 1. Abt.*, 1898, **23**, 865.
26. Sabin, A. B., and Wright, A. M., *J. Exp. Med.*, 1934, **59**, 115.
27. Rivers, T. M., and Tillett, W. S., *J. Exp. Med.*, 1923, **38**, 673; 1924, **39**, 777.
28. Goodpasture, E. W., and Buddingh, G. J., *Am. J. Hyg.*, 1935, **21**, 319.
29. Flexner, S., and Amoss, H. L., *J. Exp. Med.*, 1925, **41**, 233.
30. Rous, P., Beard, J. W., and Kidd, J. G., *J. Exp. Med.*, 1936, **64**, 401.

EXPLANATION OF PLATES

The photographs were made by Mr. Merwyn C. Orser

PLATE 12

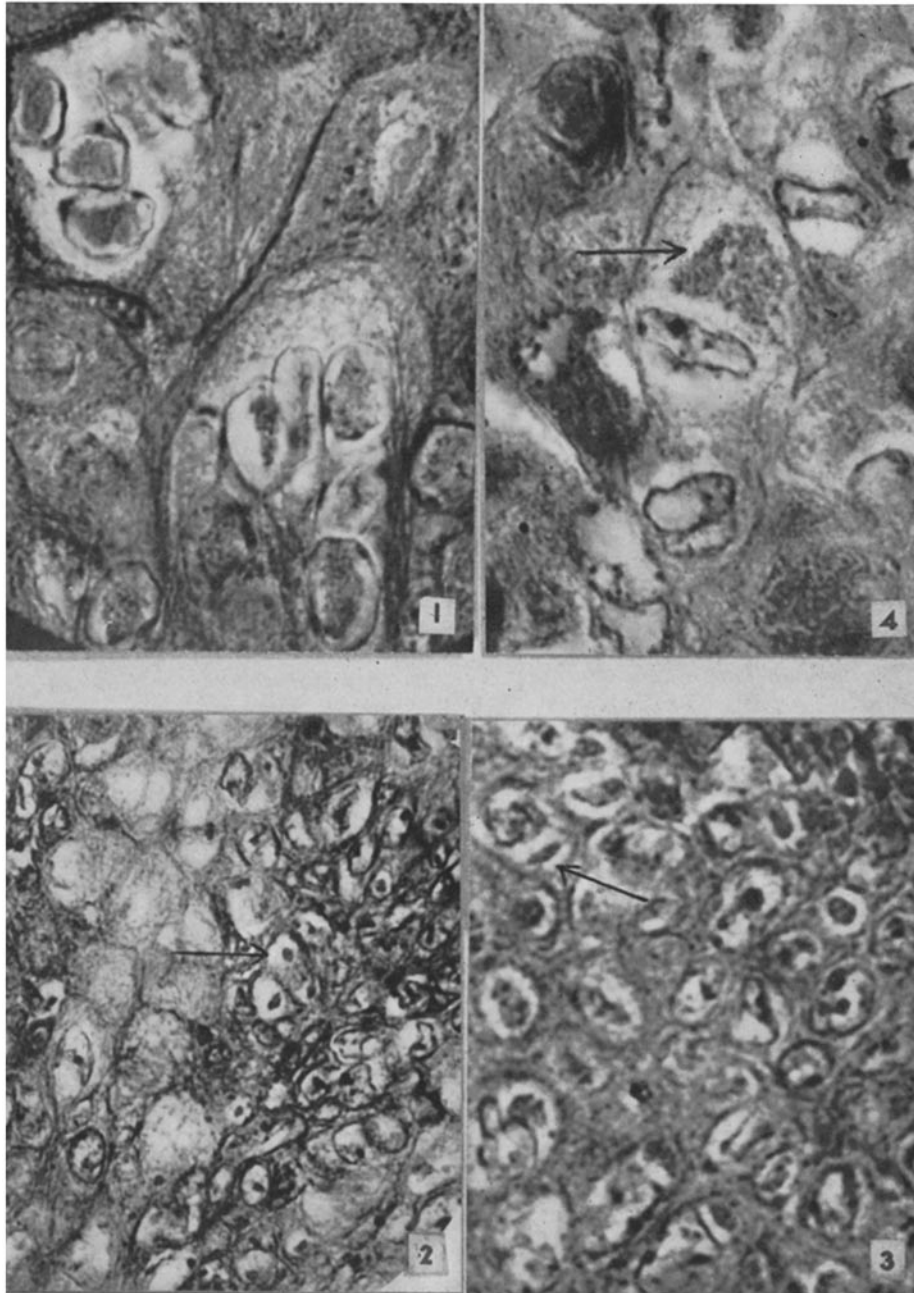
Superinfection of the Rabbit Papilloma by a Single Extraneous Virus (Table I)

FIG. 1. Section of a papilloma from rabbit DR1-1 removed 6 days after infiltration with B virus suspension. Multiple type A intranuclear inclusion bodies are present in cells that have undergone amitotic nuclear division. Giemsa's stain. $\times 1500$.

FIG. 2. Section of a papilloma from rabbit CR2-1 removed 5 days after infiltration with vaccinia virus suspension. Cytoplasmic inclusion bodies (Guarnieri bodies) are present in most of the cells (arrow). Hematoxylin and eosin. $\times 640$.

FIG. 3. Section of a papilloma from rabbit DR2-2 removed 5 days after infiltration with vaccinia virus suspension. Many cells contain Guarnieri bodies (arrow). Giemsa's stain. $\times 1500$.

FIG. 4. Section of a papilloma from DR5-2 removed 5 days after infiltration with myxoma virus and B virus. Most of the cells show cytoplasmic inclusion bodies produced by the myxoma virus (arrow). Giemsa's stain. $\times 1500$.



(Syverton and Berry: Virus superinfection of papilloma cells)

PLATE 13

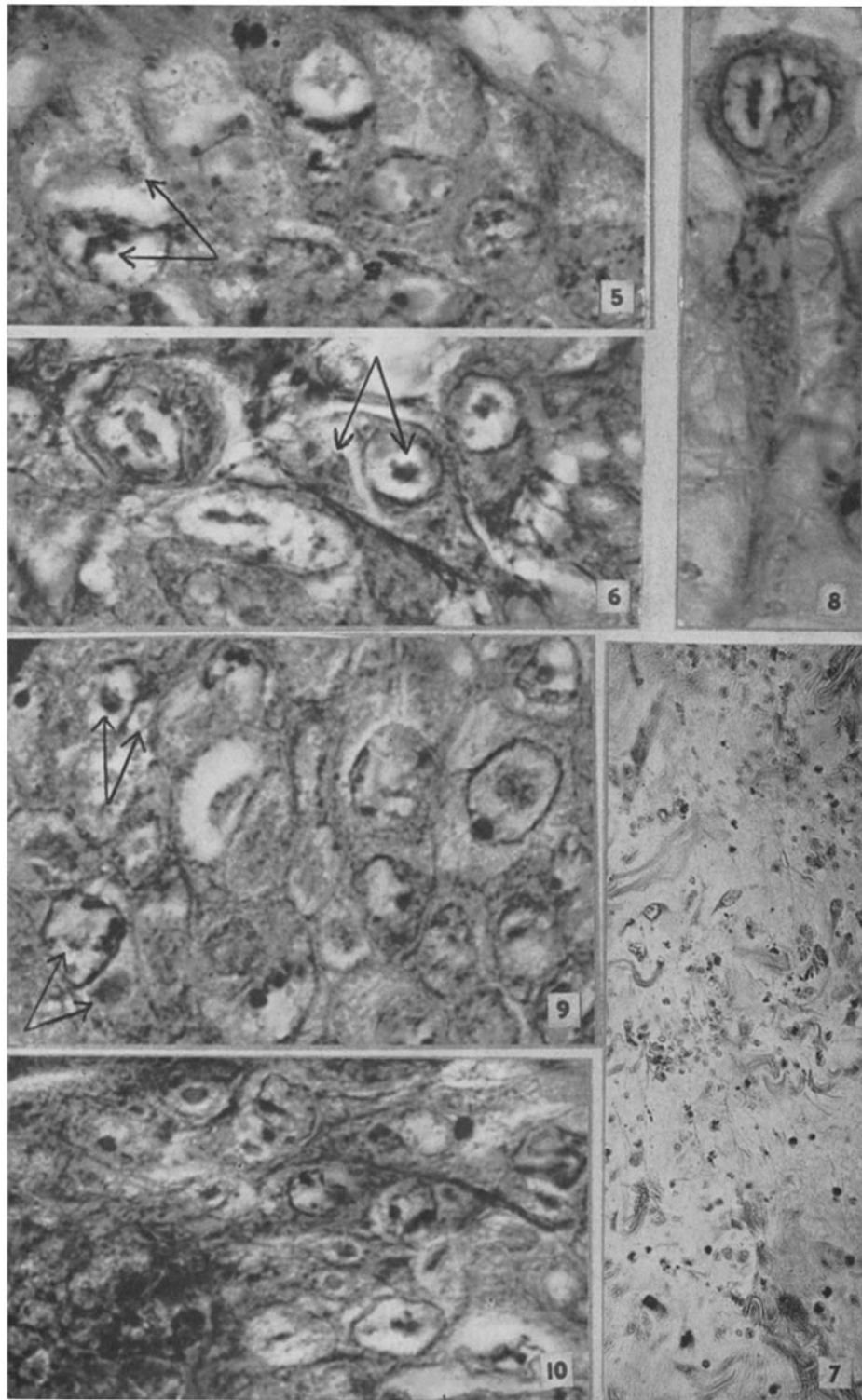
Superinfection of the Rabbit Papilloma by Two Extraneous Viruses (Table II)

FIGS. 5 and 6. Sections of papillomas removed from rabbits DR5-1 and DR5-3, respectively, 5 days after infiltration with a mixture of myxoma virus and B virus. Acidophilic intranuclear and cytoplasmic inclusion bodies are present in single cells (arrow). Giemsa's stain. $\times 1460$.

FIGS. 7 and 8. Sections of a papilloma removed from rabbit DR-5 six days after infiltration with a mixture of myxoma virus and B virus. Nearly every epithelial cell contains cytoplasmic inclusion bodies. Underlying the papilloma the myxomatous tissue (Fig. 7) shows many fibroblastic stellate cells containing type A intranuclear inclusion bodies. A single stellate cell with two intranuclear inclusion bodies is shown in Fig. 8. Giemsa's stain. Fig. 7, $\times 210$; Fig. 8, $\times 1460$.

FIG. 9. Section of papilloma removed from rabbit DR6-1 four days after infiltration with a suspension of virus III and vaccinia virus. Acidophilic intranuclear inclusions and Guarnieri bodies in the cytoplasm are present in single cells (arrows). Giemsa's stain. $\times 1460$.

FIG. 10. Section of a papilloma removed from rabbit DR7-1 five days after infiltration with a mixture of B virus and vaccinia virus. Both intranuclear inclusion bodies and Guarnieri bodies are present in cells, but in no instance are both an intranuclear inclusion body and a cytoplasmic inclusion body surely present within a single cell. Giemsa's stain. $\times 1460$.



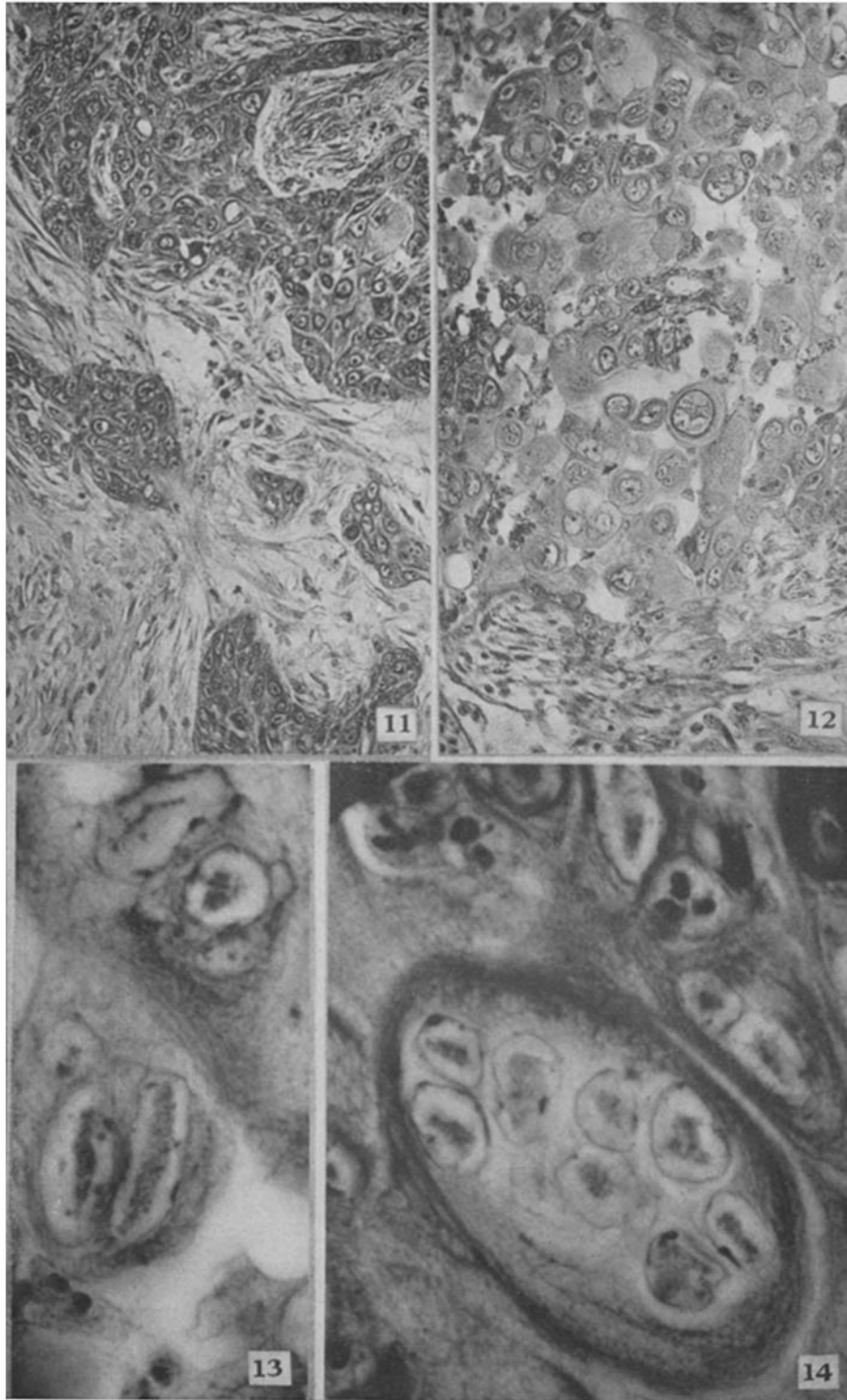
(Syverton and Berry: Virus superinfection of papilloma cells)

PLATE 14

*Superinfection by an Extraneous Virus of an Epidermoid Carcinoma That
Followed a Virus Papilloma*

FIGS. 11 and 12. Section of the primary carcinoma removed from rabbit DR11-1. Fig. 11 shows the cellular morphology of a portion of the cancer where there is no evidence of B virus infection and Fig. 12 shows hypertrophied cells most of which contain one or more intranuclear inclusion bodies. Hematoxylin and eosin. $\times 210$.

FIGS. 13 and 14. Cells from the section shown in Fig. 12 when viewed at a higher magnification. It can be seen that from one to eight intranuclear inclusion bodies are contained within a single nucleus. Giemsa's stain. $\times 1500$.



(Syverton and Berry: Virus superinfection of papilloma cells)