

STUDIES ON ACUTE DISSEMINATED ENCEPHALOMYELITIS
PRODUCED EXPERIMENTALLY IN RHESUS MONKEYS. III*

By ELVIN A. KABAT, Ph.D., ABNER WOLF, M.D., AND ADA E. BEZER

(From the Departments of Neurology, Bacteriology, and Pathology, College of Physicians
and Surgeons, Columbia University, and the Neurological Institute, New York)

PLATE 22

(Received for publication, July 6, 1948)

Earlier studies from this laboratory (1, 2) and by Morgan (3) have independently established that administration of homologous or heterologous brain tissue in an emulsion with paraffin oil, aquaphor, and killed tubercle bacilli as adjuvants (4) would induce an acute disseminated encephalomyelitis in *rhesus* monkeys more rapidly than had previously been accomplished without adjuvants (5, 6) and these findings have been confirmed by Ferraro and Cazzullo (7). Freund, Stern, and Pisani (8) and Morrison (9) have produced a similar disease in guinea pigs and in rabbits, but the pathological changes in these species were much less striking, notably with respect to the degree of demyelination. In the studies with rabbits (9, 10), however, there were sometimes animals which showed disease symptoms, but failed to show any pathological changes at necropsy, and conversely there were animals which remained completely free of symptoms but in which pathological changes were found; moreover in both guinea pigs (8) and rabbits (9) the total incidence of the disease was lower than in monkeys. Since in the monkey, there was almost always complete agreement between the symptoms and the pathological findings, except in those few animals in which the symptoms could be demonstrated by necropsy to have an entirely unrelated cause, or in an occasional animal which showed very few pathological changes without symptoms having been noted, it was decided to continue the study of the etiology of this disease in the monkey.

The work has been based on the hypothesis that the disease is the result of an immunological response to the injected brain tissue and that the lesions result from the interaction between the brain tissue of the host and antibrain antibody formed to the injected material (1-3) or, alternately, that the injections induced sensitization of the tuberculin type (8), which would be associated with cellular rather than with humoral antibodies. The present report summarizes data obtained on the distribution of the inciting antigen in the brains of various animal species, on the appearance of this antigen in the cerebrum and spinal cord of rabbits of varying ages after birth in relation to the degree of myelina-

* These studies were supported by grants from the National Multiple Sclerosis Society and the William J. Matheson Commission.

tion, and on the stability of the antigen in brain tissue. Data are also given concerning attempts to produce the disease by passive transfer with the serum as well as with cell exudates and suspensions of spleen and lymph nodes of monkeys with disseminated encephalomyelitis, and with the serum of rabbits immunized with emulsions of brain tissue with adjuvants. The mechanism of the rôle of tubercle bacilli in the induction of the disease in monkeys is also considered.

EXPERIMENTAL

Emulsions were prepared as described in (1) and were standardized on the basis of wet weight as follows: 7 gm. of brain or spinal cord was homogenized in a Waring blender in 10 ml. saline containing 1 per cent phenol, 10 ml. of molten aquaphor, and 20 ml. of paraffin oil containing 25 mg. of heat-killed tubercle bacilli (strain H37RV). The final emulsion was heated at 60°C. for 45 minutes (1). Each milliliter of emulsion contained 175 mg. of original tissue. When larger amounts of tissue were used, the volumes of all constituents were increased proportionately. In experiments involving extraction with alcohol or acetone, a given weight of tissue was extracted, the extract evaporated to dryness at room temperature and the residue dried and emulsions of each prepared based on the original weight of tissue extracted.

Injection of Animals.—Each monkey received an initial course of three 1 ml. intramuscular injections. Injections were spaced a week apart. The animals were then observed daily for 6 weeks to 2 months. Monkeys which had shown no symptoms were given a second course of three 1 ml. injections and observed for an additional 3 months after which all animals were sacrificed. Monkeys which showed symptoms were observed until it appeared unlikely that they would survive another day. They were then sacrificed by exsanguination and a complete necropsy performed (1, 2), including gross and microscopic examination. Animals listed in the table as positive showed symptoms as well as lesions typical of acute disseminated encephalomyelitis at necropsy. Animals listed as negative showed neither symptoms nor pathological findings of disseminated encephalomyelitis. In a few instances symptoms, usually generalized weakness, were recognized by necropsy to be the result of unrelated disease.

RESULTS

The capacity of various materials, when incorporated in emulsions with aquaphor, paraffin oil, and killed tubercle bacilli, to induce acute disseminated encephalomyelitis in *rhesus* monkeys is shown in Table I. Although chicken, monkey, and human brain were effective in inducing this disease, frog and fish brain gave negative results. With both human and monkey brain emulsions, negative results were obtained if the tubercle bacilli were omitted. Negative results were also obtained in groups of monkeys in which human or monkey brain emulsions containing aquaphor and paraffin oil but lacking tubercle bacilli were injected into one side of a group of animals and an emulsion of aquaphor, paraffin oil, and tubercle bacilli but containing no brain tissue was injected into the opposite side.

Data on the stability of the antigen in brain tissue are also included in Table I. It may be seen that the capacity of brain tissue to induce the lesions was not significantly affected by exposure to ultrasonic vibration at 600 kc. for two 10

TABLE I

Potency of Various Emulsions with Adjuvants in Producing Acute Disseminated Encephalomyelitis in Rhesus Monkeys

Material injected*	No. of monkeys used	First course No. of monkeys positive	Second course No. of additional monkeys positive	No. of monkeys positive No. of monkeys used
Chicken brain.....	3	2		2/3
Frog brain.....	4	0	0	0/4
Fish (carp) brain.....	3	0	0‡	0/3
Human brain.....	5	2	2	4/5
Human brain (without tubercle bacilli).....	3	0	0	0/3
Human brain, paraffin oil, aquaphor, without tubercle bacilli in right side; paraffin oil, tubercle bacilli, aquaphor in left side.....	4	0	0§	0/4
Human brain (ultrasonically treated).....	3	2¶	1	3/3
Human brain (alcoholic extract).....	3	0	0	0/3
Human brain (residue from alcoholic extraction).....	3	0	0	0/3
Monkey brain.....	5	4	0	4/5
Monkey brain (without tubercle bacilli).....	3	0	0	0/3
Monkey brain, paraffin oil, aquaphor, without tubercle bacilli in right side; paraffin oil, tubercle bacilli, and aquaphor in left side.....	4	0	0	0/4
Monkey brain (autolyzed**).....	3	1	0	1/3
Monkey brain (boiled‡‡).....	3	2	0	2/3
Monkey brain formalinized.....	4	4		4/4
Monkey brain (acetone extract).....	3	0	0	0/3
Monkey brain (residue from acetone extract).....	3	0	1	1/3
Monkey brain (alcohol extract).....	3	0	0	0/3
Monkey brain (residue from alcoholic extract).....	3	0	0	0/3
Monkey peripheral nerve§§.....	7	0	0	0/7

* All emulsions were from adult animals and were made up with aquaphor, paraffin oil, and tubercle bacilli except where otherwise noted.

‡ Animals received only two injections in second course.

§ Three animals did not receive a second course.

|| Saline suspension of brain exposed to ultrasonic vibration at 600 kc. for two 10 minute intervals.

¶ One of these animals died, was accidentally disposed of without being necropsied. The animal showed ataxia, ptosis of both eyelids, rotation of head and weakness of right hind leg, and was considered positive.

** The brain was homogenized in saline without phenol, 1 ml. of toluene was added, and the material allowed to stand at room temperature for 22 days, before adding adjuvants.

‡‡ Brain homogenate in saline heated in boiling water bath for 1 hour.

§§ One animal died before second course was begun, one animal received only one injection of second course, and three animals received only two injections of second course.

||| This animal showed very few lesions at necropsy and no symptoms were observed.

minute intervals, by heating in saline suspension in a boiling water bath for 1 hour, or by fixation in 10 per cent formalin as employed for routine pathological study. After extraction of brain tissue with alcohol or with acetone neither the extract nor the extracted residues showed any capacity to induce encephalomyelitis except for very mild lesions without symptoms discovered on histopathological examination in one animal injected with the acetone residue. One of three animals injected with an emulsion of autolyzed monkey brain developed encephalomyelitis; data are not yet sufficient to establish whether autolysis resulted in any loss of potency. In confirmation of the findings of

TABLE II

Development in Rabbit Brain and Spinal Cord of Antigen Inducing Acute Disseminated Encephalomyelitis

Material injected	No. of monkeys used	First course No. of monkeys positive	Second course No. of additional monkeys positive	No. of monkeys positive No. of monkeys used
Cerebrum from 3 mos. old rabbit. . . .	6	2	1	3/6
" " 2 " " "	7	3	1	4/7
" " 1 " " "	6	6	0	6/6
" " 12 day " " "	7	1	1	2/7
" " 6 " " "	7	0	0	0/7
" " 3 " " "	7	0	0	0/7
" " 1 " " "	3	0	0	0/3
Spinal cord from 12 day rabbit.	4	3	0	3/4
" " " 6 " "	4	3	0	3/4
" " " 3 " "	4	0	3	3/4

All materials incorporated into emulsions with adjuvants.

Morgan (3), negative results were obtained by inoculation of emulsions of monkey peripheral nerve.

Since it previously had been demonstrated (1) that the antigen was absent from fetal rabbit brain, its appearance during early life was investigated. The results of injection of emulsions with adjuvants of the cerebrums and spinal cords of groups of rabbits of varying ages are shown in Table II. It is evident that the substance inducing encephalomyelitis did not appear in the rabbit cerebrum until the animals were 12 days of age whereas it was present in the spinal cord of 3 day old rabbits.

Table III summarizes attempts to induce acute disseminated encephalomyelitis passively with the serum of monkeys suffering from the disease and with the serum of rabbits immunized with emulsions of brain tissue with adjuvants following the same schedule used to induce the disease in monkeys.

Completely negative results were obtained even in three monkeys which had received intravenous injections of 200 ml. of serum from seven to ten monkeys with encephalomyelitis, in two animals after giving 21 ml. of monkey serum

TABLE III
Attempts to Produce Acute Disseminated Encephalomyelitis by Passive Transfer with Serum

Material used	Monkey No.	No. of injections	No. of serum donors	Total volume injected	Time between 1st and last injections	Day of death	Symptoms and pathological findings
				ml.	days		
Injections intravenously							
Serum from monkeys with acute disseminated encephalomyelitis	2-3	8	3	40	54	86(S*)	Negative
	2-4	7	3	35	47	82(S)	"
	3-6	5	3	25	25	128(S)	"
	3-7	5	3	25	25	128(S)	"
	1-67	11	9	200	14	94(S)	"
	1-76	10	10	200	12	94(S)	"
	1-19	11	7	200	20	39	"
Injections intracisternally							
	9-1	21	4	21	130	140	Negative
	9-2	21	2	21	130	211(S)	"
Injections intravenously							
Serum from rabbits immunized with monkey brain tissue containing adjuvants‡	8-6	13	10	68	55	57	Negative
	8-7	13	4	68	55	58	Neurological symptoms shown at autopsy to be of serum sickness type
	1-08	30	15	147	58	151(S)	Negative
	1-09	32	13	160	62	96	"
	1-68	20	10	200	43	94(S)	"

* Sacrificed.

‡ Rabbits received schedules of injections similar to those used to induce encephalomyelitis in monkeys, and were bled 10 days and 1 month after each course.

intracisternally, and in five monkeys given 68 to 200 ml. of serum from rabbits immunized with emulsions of brain tissue.

Data on unsuccessful attempts to effect passive transfer of acute disseminated encephalomyelitis by the technic of cellular transfer which has been shown by Chase (11) to be effective in passive transfer of the tuberculin type of reaction are presented in Table IV. Peritoneal exudates produced as described by

Chase by intraperitoneal injection of 40 ml. of paraffin oil into monkeys suffering from encephalomyelitis and suspensions in Tyrode's solution containing monkey serum of spleen and lymphoid tissue obtained under aseptic precautions were employed. Negative results were obtained in all instances even

TABLE IV

Attempts to Produce Acute Disseminated Encephalomyelitis by Passive Transfer of Cells from Abdominal Exudates and from Splenic and Lymphoid Tissue

No. of recipient	Source of cell suspension	No. of injections	Days between 1st and last injection	No. of donor monkeys	Total volume of cell suspension injected	Day of death	Symptoms and pathological findings
1-39	Abdominal exudate	9 ip*	25	2	<i>ml.</i> 60	153(S)	No symptoms‡
		8 im*	25		59		
1-40	Abdominal exudate, spleen and lymph node	24 ip	147	4	218	204(S)	Negative for encephalomyelitis
		21 im	34		182		
1-44	Abdominal exudate, spleen and lymph node	3 ip	17	2	21	127(S)	" "
		3 im	17		21		
1-45	Abdominal exudate, spleen and lymph node	17 ip	139	4	168	222(S)	" "
		14 im	26		131		
1-74	Spleen and lymph node	7 ip	69	7	101	122(S)	" "
1-75	Spleen and lymph node	7 ip	69	7	101	122(S)	" "
2-23	Abdominal exudate, spleen and lymph node	2 ip	4	2	17	17(S)	" "

* ip = intraperitoneal, im = intramuscular.

‡ Not autopsied.

in two recipient monkeys each of which had received one-half of the spleen and lymph node suspensions of seven donor monkeys with encephalomyelitis.

The inoculation sites of all animals which received injections of brain emulsions with and without tubercle bacilli were sectioned and examined microscopically. When killed tubercle bacilli were omitted, the reaction at the inoculation site in striated muscle and subcutaneous tissue was quite mild

(Fig. 1 *a*). Narrow trabeculae of connective tissue about small lacunae containing amorphous material marked the area in which absorption of the brain emulsion occurred and this corresponded to fine fibrous veining in pale, poorly outlined areas of muscle in the gross specimen which were frequently quite inconspicuous. The connective tissue trabeculae contained small clusters of lymphocytes. This was in sharp contrast to the conspicuous lesions produced by the injection of an emulsion containing both brain and adjuvant materials (Fig. 1 *b*) which resulted in striking local lesions in the muscle and subcutaneous tissue. Masses of meaty, compact greyish white or white firm tissue containing varying sized pockets of yellowish or cream colored exudate were seen. Histologically these proved to be masses of epithelioid cells, usually poor in giant cells although occasionally containing moderate numbers of them. Spaces of various size in the granulation tissue contained amorphous material and polymorphonuclear leucocytes tended to cluster near these. Lymphocytes were usually abundant, both diffusely spread and in clusters. As these lesions grew older fibrosis occurred and plasma cells appeared while polymorphonuclear leucocytes diminished and disappeared. The adjuvant material without the brain tissue produced a lesion much like the complete mixture (Fig. 1 *c*).

DISCUSSION

The results obtained provide some additional information on the nature of the substance in brain tissue which, when injected with adjuvants, induces the appearance of acute disseminated encephalomyelitis in the monkey. The antigen is apparently organ-specific since brain from a species even as remote in zoological relationship as the chicken will induce the disease; however, brains from more distantly related animals like the frog and fish give negative results. The antigen is fairly stable since it withstood fixation in formalin, heating in a boiling water bath, and treatment with ultrasound. It is, however, destroyed by alcohol extraction, both the extract and the residue being inactive. An acetone extract was completely inactive and the residue showed slight residual activity. The finding in Table II that the antigen is present in the spinal cord of 3 day old rabbits, but does not appear in the cerebrum of rabbits until the 12th day of life indicates a close parallelism with the laying down of myelin which proceeds in the same sequence and suggests that myelin may be the antigen involved. This is of interest in relation to the findings of Schwentker and Rivers (10) that the organ-specific antigen in autolyzed brain as measured by complement fixation paralleled its myelin content. A final decision as to the nature of the antigen, however, must await its isolation from brain tissue in purified form and a study of its chemical and physical properties. In confirmation of the report by Morgan (3), monkey peripheral nerve emulsions were found not to induce the disease.

The unsuccessful attempts to effect passive transfer of the acute disseminated

encephalomyelitis either with serum or with cell exudates from affected monkeys or with the serum of rabbits injected with brain emulsions with adjuvants leave a serious gap in the chain of evidence supporting the hypothesis (1) that an antibody to the injected brain tissue reacts with the nervous system of the animal to produce the disease, since no positive evidence for such an antibody has yet been obtained. As previously noted (1) this does not necessarily contradict or weaken this hypothesis since the hypothetical antibody would be continuously removed from the circulation by the tissues of the central nervous system of the donor monkey and the amount present even in the 200 ml. of serum injected passively might be inadequate to produce the disease. Kolb and Bolton (12) were unable to produce lesions in the central nervous system of rats with rabbit antisera to rat and cat brain and Hurst (13) refers to the negative results of Hurst and Atkinson on injection of pigs with antiserum to pig brain produced in sheep and rabbits.

The experimental findings in Table I and the histological studies of the inoculation sites provide some indication of the mechanism of action of the tubercle bacilli and of the induction of the disease. As seen in Table I not only are the tubercle bacilli necessary for the development of acute disseminated encephalomyelitis with the injection schedule employed, but, indeed, they must be present at the site at which the brain emulsion is injected, since injection of emulsions of brain without tubercle bacilli into one side and of tubercle bacilli without brain into the other side yielded negative results. Histologically, the sites containing tubercle bacilli showed much more pronounced local reactions with large masses of epithelioid cells which were absent in sites without tubercle bacilli. Were the enhancing effect merely a systemic response to the injection of tubercle bacilli, positive results should have been obtained when emulsions with tubercle bacilli but without brain and of brain without tubercle bacilli were injected at different sites. It is very tempting to infer that the function of the tubercle bacilli in producing encephalomyelitis more rapidly than can be accomplished otherwise is to bring these epithelioid cells in close proximity to the antigen and that the formation of antibody to the brain antigen takes place locally at the inoculation site (for evidence on the local formation of antibodies compare references 14 and 15).

SUMMARY

The factor in brain tissue which induces acute disseminated encephalomyelitis, when injected into *rhesus* monkeys as an emulsion with adjuvants, has been found in human, monkey, rabbit, and chicken brain but is absent from frog and fish brain. It is unaffected by fixation of the brain in formalin, by boiling, and by treatment with ultrasound. It is present in the spinal cord of 3 day old rabbits but does not appear in the rabbit cerebrum until about the 12th day of life; in this respect it parallels the laying down of myelin. Attempts

to produce the encephalomyelitis passively with large quantities of serum or of cell exudates, and suspensions of cells from spleen and lymph node from monkeys with encephalomyelitis, were unsuccessful.

BIBLIOGRAPHY

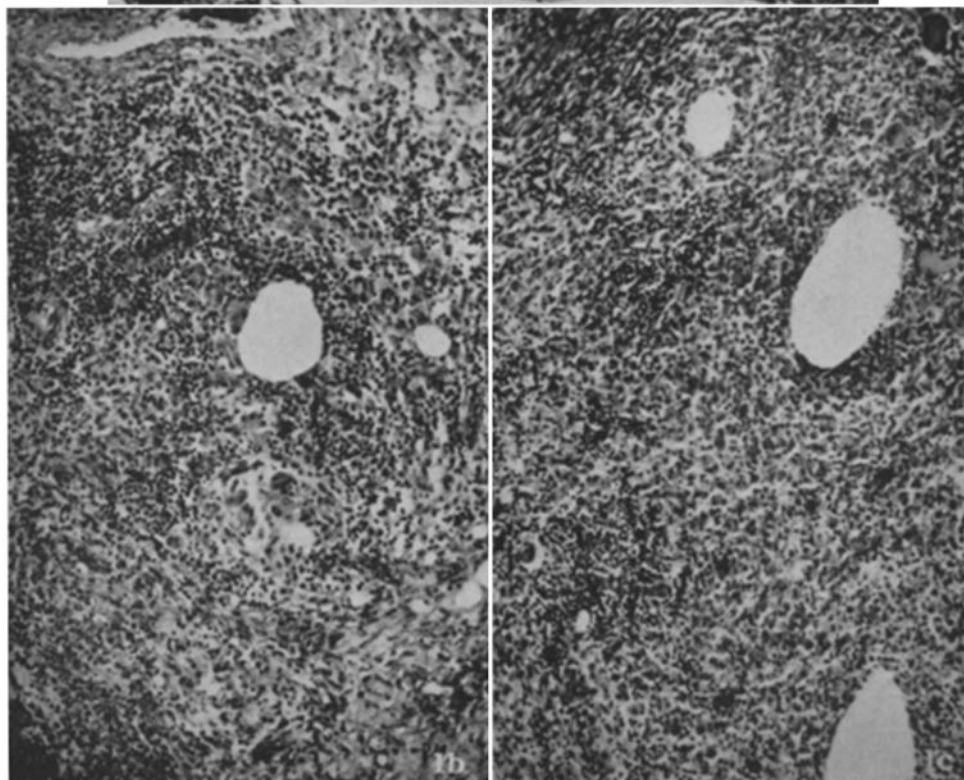
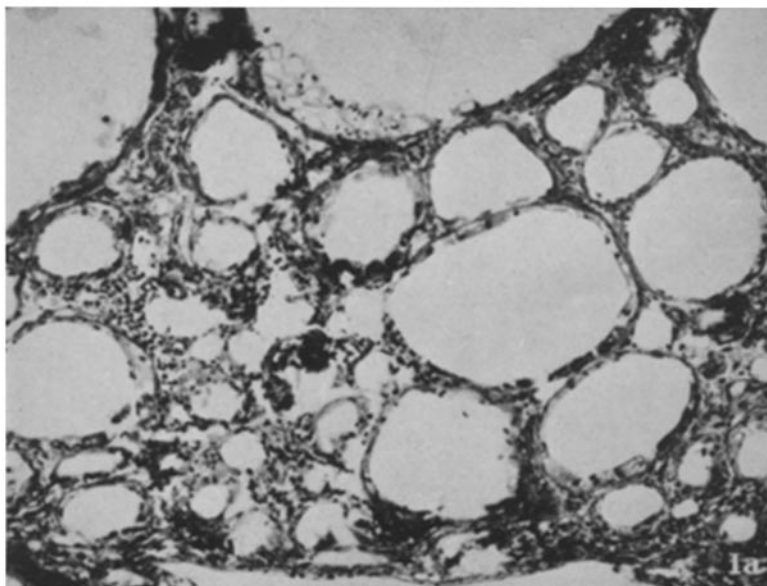
1. Kabat, E. A., Wolf, A., and Bezer, A. E., *Science*, 1946, **104**, 362; *J. Exp. Med.*, 1947, **85**, 117.
2. Wolf, A., Kabat, E. A., and Bezer, A. E., *J. Neuropath. and Exp. Neurol.*, 1947, **6**, 333.
3. Morgan, I. M., *J. Bact.*, 1946, **51**, 614; *J. Exp. Med.*, 1947, **85**, 131.
4. Freund, J., and McDermott, K., *Proc. Soc. Exp. Biol. and Med.*, 1942, **49**, 548.
5. Rivers, T. M., Sprunt, D., and Berry, G. P., *J. Exp. Med.*, 1933, **58**, 39; Rivers, T. M., and Schwentker, F. F., *J. Exp. Med.*, 1935, **61**, 689.
6. Ferraro, A., and Jervis, G. A., *Arch. Neurol. and Psychiat.*, 1940, **43**, 195.
7. Ferraro, A., and Cazzullo, C. L., Program abstract, American Association of Neuropathologists, June 14, 1948, p. 19; *J. Neuropath. and Exp. Neurol.* 1948, **7**, 235.
8. Freund, J., Stern, E. R., and Pisani, T. M., *J. Immunol.*, 1947, **57**, 179.
9. Morrison, L. R., *Arch. Neurol. and Psychiat.*, 1947, **58**, 391.
10. Schwentker, F. F., and Rivers, T. M., *J. Exp. Med.*, 1934, **60**, 559.
11. Chase, M. W., *Proc. Soc. Exp. Biol. and Med.*, 1945, **59**, 134.
12. Kolb, L. C., and Bolton, B., *J. Neurol. and Psychiat.*, 1940, **3**, 111.
13. Hurst, E. W., *Brain*, 1944, **67**, 103.
14. Seegal, B. C., in Gay, F. P., *Agents of Disease and Host Resistance*, Springfield, Illinois, Charles C. Thomas, 1935, chapter 6.
15. Freund, J., *Annual Review of Microbiology*, Stanford University Press, 1947, **1**, 291.

EXPLANATION OF PLATE 22

FIG. 1 *a*. Monkey 9-7. Inoculation site in right thigh. Mild infiltration by lymphocytes and occasional epithelioid cells about spaces in which inoculum lay. Inoculum composed of monkey brain, aquaphor, and paraffin oil without killed tubercle bacilli. Hematoxylin-eosin stain. $\times 75$.

FIG. 1 *b*. Monkey 9-9. Inoculation site in right thigh. Abundant granulation tissue containing a great many epithelioid cells, numerous lymphocytes, and occasional multinucleated giant cells. Inoculum composed of monkey brain, aquaphor, paraffin oil, and killed tubercle bacilli. Hematoxylin-eosin stain. $\times 75$.

FIG. 1 *c*. Monkey 1-54. Inoculation site in left thigh. Granulation tissue like that in Fig. 1 *b*. Inoculum composed of aquaphor, paraffin oil, and killed tubercle bacilli but lacking monkey brain. Hematoxylin-eosin stain. $\times 75$.



(Kabat *et al.*: Acute disseminated encephalomyelitis. III)