

## NEPHROTOXIC NEPHRITIS IN RATS

EVIDENCE FOR THE GLOMERULAR ORIGIN OF THE KIDNEY ANTIGEN\*

BY DAVID H. SOLOMON, M.D.,† JOSEPH W. GARDELLA, M.D.,§ HERBERT FANGER, M.D., FRANCES M. DETHIER, AND JOSEPH W. FERREBEE, M.D.

(From the Departments of Medicine and Pathology, Harvard Medical School, The Peter Bent Brigham Hospital, Boston, and the Mary Imogene Bassett Hospital, Cooperstown)

PLATES 24 AND 25

(Received for publication, June 1, 1949)

The so called nephrotoxic nephritis (1) produced in rats by the intravenous injection of rabbit anti-rat kidney serum has been extensively studied by Masugi (2, 3) and Smadel (4-7). In Smadel's experiments and in ours, rabbits were immunized by repeated intraperitoneal injections of blood-free rat kidney suspensions. The anti-kidney sera so prepared incite an acute and sometimes chronic glomerulonephritis when injected intravenously into rats. It has been our purpose to demonstrate that the primary reaction of the antisera is with the glomerulus and by inference that the glomerulus is therefore the source of the antigen essential for the production of this type of nephrotoxic sera.

### Methods

The following experimental approach was adopted. Pools of rabbit anti-rat kidney sera were partially freed of non-antibody protein by precipitation of a gamma globulin-containing fraction, designated according to the Cohn nomenclature (8) as fraction II + III. This fraction was redissolved in saline and used as a nephrotoxic solution in place of whole serum. A method for the crude separation of kidney into glomerular and tubular portions was devised, and the separate portions of kidney were then tested for their ability to adsorb nephrotoxin from the gamma globulin-containing fraction of nephrotoxic rabbit serum.

*Production of Nephrotoxic Sera.*—The kidneys of large albino rats of the Hisaw strain were perfused *via* the aorta with saline, ground in a mortar under aseptic conditions, bottled as a 10 to 20 per cent saline suspension, and injected intraperitoneally into rabbits, following the schedule of Smadel (7). The rabbits were bled to death 10 days after the last injection. The serum was obtained by centrifugation, bottled after Seitz filtration, and stored in solid CO<sub>2</sub>. The sera were assayed for their nephrotoxic effect by intravenous injection into 60 to 100 gm. rats of the same strain and of either sex. Doses ranging from 0.2 to 1.8 cc. per 100 gm. of

\* This work was aided by a grant from the John and Mary R. Markle Foundation.

† Aided by a grant from H.P. Hood and Sons, Boston.

§ Aided by a grant from The Robert Breck Brigham Hospital, Boston.

body weight were given, the total dose being divided into halves for injection on 2 consecutive days. Injected rats were examined daily for the characteristics of acute nephritis, and urine specimens were analyzed on alternate days. The rats were sacrificed at varying intervals by a blow on the head. The kidneys were fixed in Zenker's fluid and were stained with hematoxylin and eosin and with the Lee-Brown modification of Mallory's aniline blue stain.

*Fractionation of Antiserum.*—Five cc. of normal or immune rabbit serum was diluted with 20 cc. of distilled water and 15 cc. of isotonic saline. The pH was adjusted approximately to 6.8 (by indicators) with  $m/15$  monobasic and dibasic phosphate solutions, of which a maximum of 0.25 cc. was required to reach and maintain the desired pH. The solution was immersed in an alcohol bath at  $-5^{\circ}\text{C}$ . and allowed to cool below  $0^{\circ}\text{C}$ ., after which 40 cc. of 50 per cent alcohol was added by capillary drip with active stirring. Stirring was continued for 5 hours after the addition of alcohol was complete. The suspension was then centrifuged at  $-5^{\circ}\text{C}$ .<sup>1</sup> The supernatant was decanted and the precipitate, the immune gamma globulin, fraction II + III according to the Cohn nomenclature for human plasma (9), was redissolved in 5 cc. of chilled isotonic saline to restore its constituent proteins to their initial concentration.

*Separation of Rat Kidney into Glomerular and Tubular Portions.*—Large Hisaw rats were perfused with saline either through the left ventricle or the thoracic aorta. The hilar structures of the kidney were dissected away, and the capsule was stripped. The kidneys were then minced with scissors and placed in the barrel of a Potter-Elvehjem tissue homogenizer<sup>2</sup> (10). A *mismatched* plunger was used, such that the fit of the ground glass surfaces was considerably looser than that of the original model. By exerting downward pressure on the plunger, it was possible to press out glomeruli from the surrounding structures and to mash the tubular tissue into cellular and subcellular particles.

The whole kidney suspension thus obtained (Fig. 1) was centrifuged at 700 to 800 R.P.M. for 2 minutes and the upper four-fifths of the supernatant carefully decanted. This first supernatant was made up wholly of nuclear and cytoplasmic debris. It contained no recognizable glomerular remnants microscopically and was designated "tubular" material (Fig. 2).

The sediment was resuspended in saline and again centrifuged slowly for 1 minute. The resuspending and centrifuging were repeated 8 to 10 times, pouring off and discarding the supernatants until a fairly clear supernatant was obtained. The sediment during this procedure was made up of an increasing concentration of glomeruli, a scattering of nuclear and cytoplasmic particles, a small number of stringy bivalved elements resembling small blood vessels, and many large bits of inadequately ground renal tissue. These last were removed by suspending the entire sediment in ten to twenty volumes of saline and allowing the large pieces to settle to the bottom. The sediment was resuspended several times. The glomeruli remaining in suspension were decanted, pooled, and concentrated by a final centrifugation.

The final glomerular preparation (Figs. 3 and 4) was contaminated by a scattering of particulate matter of indeterminate nature and by the stringy structures mentioned above. The latter were usually blue-stained when Janus green had been used in the perfusate and hence were believed to be vascular. In no instance were the preparations considered to be entirely free of non-glomerular elements.

For most experiments the glomerular preparations were transferred to an ordinary tight-fitting Potter-Elvehjem homogenizer and ground for 20 to 30 minutes in an ice bath.

Calculations from the data of Vimtrup (12), Kunkel (13), and Moore (14) revealed an expected volume of 0.125 cc. of glomeruli per rat kidney. The volume of firmly packed finely ground glomeruli which we obtained was ordinarily 0.1 cc. for four kidneys, approximately 20 per cent of the calculated yield.

<sup>1</sup> Refrigerated centrifuge, Model PR-1, International Equipment Co., Boston, Massachusetts.

<sup>2</sup> The model used differed from the original in having no glass beads on the tip of the plunger. It was obtained from the Scientific Glass Apparatus Company, Bloomfield, New Jersey.

*Adsorption Experiments*

Adsorption of nephrotoxin from immune gamma globulin fractions was demonstrated as follows:—

0.05 cc. of packed finely ground glomeruli was added to 1 to 2 cc. of immune gamma globulin, the amount of gamma globulin used being somewhat more than twice that required to produce severe nephritis in a 60 to 80 gm. rat. The suspension was incubated at 37°C. with frequent gentle rocking. At the end of 2 hours another 0.05 cc. of glomeruli was added and the rocking and incubation continued 2 hours longer. The suspension was then centrifuged at 3000 R.P.M. for 30 minutes. The clear supernatant was assayed for nephrotoxin by intravenous injection into two 60 to 80 gm. rats, the volume injected into each rat being approximately equal to the volume of the gamma globulin fraction found necessary by previous assay to produce severe nephritis in a 60 to 80 gm. rat.

Tubular fraction of kidney, homogenized liver, minced rat tail tendon, and carcass connective tissue (11) prepared from perfused rats were used as adsorbents in control experiments. The volume of these tissues used per nephrotoxic dose of gamma globulin was in each instance considerably greater than that used in the experiments with glomeruli.

## RESULTS

*Production of Nephritis with the Gamma Globulin Fraction.*—Nephritis was produced in rats by the intravenous injection of the gamma globulin-containing fraction prepared from immune rabbit sera. The acute nephritis when severe was characterized by heavy proteinuria, edema, ascites, pleural effusion, diarrhea, anorexia, emaciation, elevation of blood urea nitrogen, and pallor. No hematuria was observed. We did not find cylindruria as consistently as did Smadel, although the pathologic sections frequently revealed coagulated albuminous fluid in the tubules. Few data were obtained on the chronic stage of nephritis, since our experiments were usually concerned only with the occurrence of the acute syndrome.

In four rats of the Hisaw strain that were not sacrificed in the acute stage, proteinuria disappeared from 1 to 5 months after the injections, and pathologic studies on these animals showed no evidence of active or even healed nephritis. However, two rats of the Long-Evans strain were observed for several months after injection, and these did exhibit persistent albuminuria and pathologic changes much like the subacute or chronic lesions described in this strain by Smadel.

The severity of acute nephritis was graded as follows:—

1+, slight transient proteinuria.

2+, moderate to heavy proteinuria, no edema.

3+, very heavy proteinuria, persistent for at least 2 weeks, and slight transient edema.

4+, very heavy and persistent proteinuria, generalized anasarca, and usually, though not always, death.

Histologic abnormalities were noted consistently only in those animals which had shown severe (+++ or ++++) acute nephritis while alive. In these animals, thickening of the basement membrane of the glomerular capillaries was the most frequently observed finding. The membrane appeared to be widened by a combination of edema and tissue proliferation. These changes were found

in thirty-five out of forty-five severely nephritic rats examined. Less frequently, the glomeruli exhibited increased cellularity and mild polymorphonuclear

TABLE I  
*Protocol of a Typical Adsorption Experiment*

Nephrotoxic serum fraction	Adsorbent	Test rat	Nephritis	Death
2.2 cc.	0	S-5	++++	day
		S-6	++++	10th
2.3 cc.	0.20 cc. whole glomeruli	S-7	++	Survived
		S-8	++	"
2.3 cc.	0.15 cc. ground glomeruli	S-9	0	"
		S-10	0	"
2.3 cc.	0.50 cc. tubular material	S-11	++++	"
		S-12	++++	9th
2.0 cc.	0.40 cc. carcass connective tissue	S-13	++++	Survived
		S-14	++++	10th

TABLE II  
*The Effect on Nephrotoxicity of Adsorption with Various Tissue Preparations*

Adsorbent	Nephrotoxicity	
0	11 rats	++++ Nephritis
Ground glomeruli	10 "	0 "
	1 rat	+ "
	2 rats	++++ " *
Liver	4 "	++++ "
Connective tissue	3 "	++++ "
Tubular material	7 "	++++ "
	1 rat	++ "

\* Adsorption failure from an early experiment, for which we have no explanation.

infiltration of the tuft, exudation of albuminous fluid into the capsular space, or early crescent formation. Colloid droplets were seen on occasion in the epithelium of the proximal convoluted tubules. Coagulated albuminous fluid and granular debris were frequently found in the tubular lumen. The arteries and interstitial tissues were invariably normal.

Normal rabbit serum and fraction II + III from such serum were injected

into 15 rats in doses ranging from 0.2 cc. to 1.5 cc. per 100 gm. In none of these were obvious or histologic changes noted.

*Results of the Adsorption Experiments.*—Adsorption with glomerular tissue was regularly effective in rendering the immune serum fractions no longer nephrotoxic (Tables I and II).<sup>3</sup> This ability of the glomerular material to adsorb or destroy nephrotoxin was quantitatively limited. As a rule, 0.05 cc. of packed finely ground glomeruli was sufficient to remove an amount of nephrotoxin equivalent to that required for the production of severe nephritis in one rat. Considerably greater quantities of tubular material and other tissues were entirely ineffective in reducing nephrotoxicity. A sample protocol of the adsorption test is shown in Table I, and a summary of the results of similar experiments is given in Table II.

#### SUMMARY

Nephrotoxic anti-rat kidney sera were produced in rabbits by intraperitoneal injection of suspensions of blood-free rat kidney. The nephrotoxin of these sera could be removed by adsorption with saline suspensions of finely ground rat glomeruli, but not by adsorption with other portions of rat kidney or by adsorption with several other rat tissues. It was concluded that nephrotoxic sera of this type react primarily with glomerular tissue and, by inference, that the antigen essential for the production of these anti-kidney sera was of glomerular origin.

The observations are consistent with Pressman's (15, 16) demonstration that anti-mouse kidney sera labeled with radioiodine localize primarily in glomeruli.

#### BIBLIOGRAPHY

1. Lindemann, W., *Ann. Inst. Pasteur.* 1900, **14**, 49.
2. Masugi, M., *Beitr. path. Anat. u. allg. Path.*, 1933, **91**, 82.
3. Masugi, M., *Beitr. path. Anat. u. allg. Path.*, 1933-34, **92**, 429.
4. Smadel, J. E., *J. Exp. Med.*, 1936, **64**, 921.
5. Smadel, J. E., and Farr, L. E., *J. Exp. Med.*, 1937, **65**, 527.
6. Smadel, J. E., *J. Exp. Med.*, 1937, **65**, 541.
7. Swift, H. F., and Smadel, J. E., *J. Exp. Med.*, 1937, **65**, 557.
8. Cohn, E. J., Oncley, J. L., Strong, L. E., Hughes, W. L., Jr., and Armstrong, S. H., *J. Clin. Inv.*, 1944, **23**, 417.
9. Cohn, E. J., Strong, L. E., Hughes, W. L., Jr., Mulford, D. J., Ashworth, J. N., Melin, M., and Taylor, H. L., *J. Am. Chem. Soc.*, 1946, **68**, 459.
10. Potter, V. R., and Elvehjem, C. A., *J. Biol. Chem.*, 1936, **114**, 495.
11. Cavelti, P. A., *Arch. Path.*, 1947, **44**, 1.
12. Vimtrup, B. J., *Am. J. Anat.*, 1928, **41**, 123.
13. Kunkel, P. A., Jr., *Bull. Johns Hopkins Hosp.*, 1930, **47**, 285.
14. Moore, R. A., *Anat. Rec.*, 1931, **48**, 153.
15. Pressman, D., and Keighley, G., *J. Immunol.*, 1948, **59**, 141.
16. Pressman, D., Hill, R. F., and Foote, F. W., *Science*, 1949, **109**, 65.

<sup>3</sup> The animals included in Table I are also included in Table II.

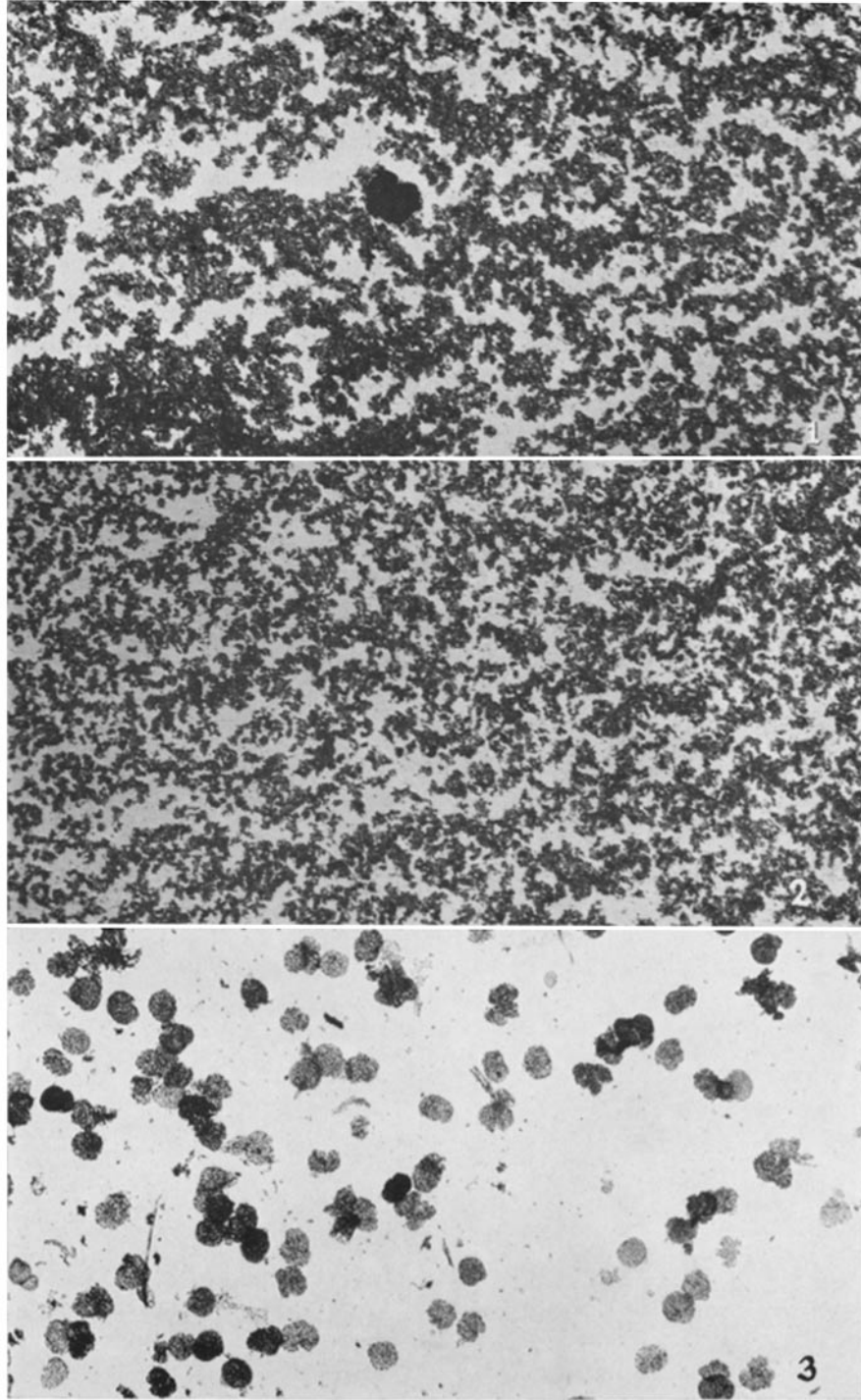
## EXPLANATION OF PLATES

## PLATE 24

FIG. 1. Whole kidney. Minced rat kidney was ground in a loose fitting glass homogenizer, and the resulting brei was concentrated by centrifugation for this photograph. Note the single densely stained glomerulus in the center of the field. Giemsa stain.  $\times 35$ .

FIG. 2. "Tubular" preparation. The upper supernatant from very slow centrifugation of the material shown in Fig. 1 has been concentrated by centrifugation for this photograph. Note the absence of glomeruli. Giemsa stain.  $\times 35$ .

FIG. 3. Glomerular preparation. The whole kidney preparation of Fig. 1 has been subjected to repeated low-speed centrifugations and separations by settling. The final product shows a preponderance of intact glomeruli, with an admixture of cellular bits (possibly tubular) and of stringy elements (presumably vascular). Giemsa stain.  $\times 25$ .

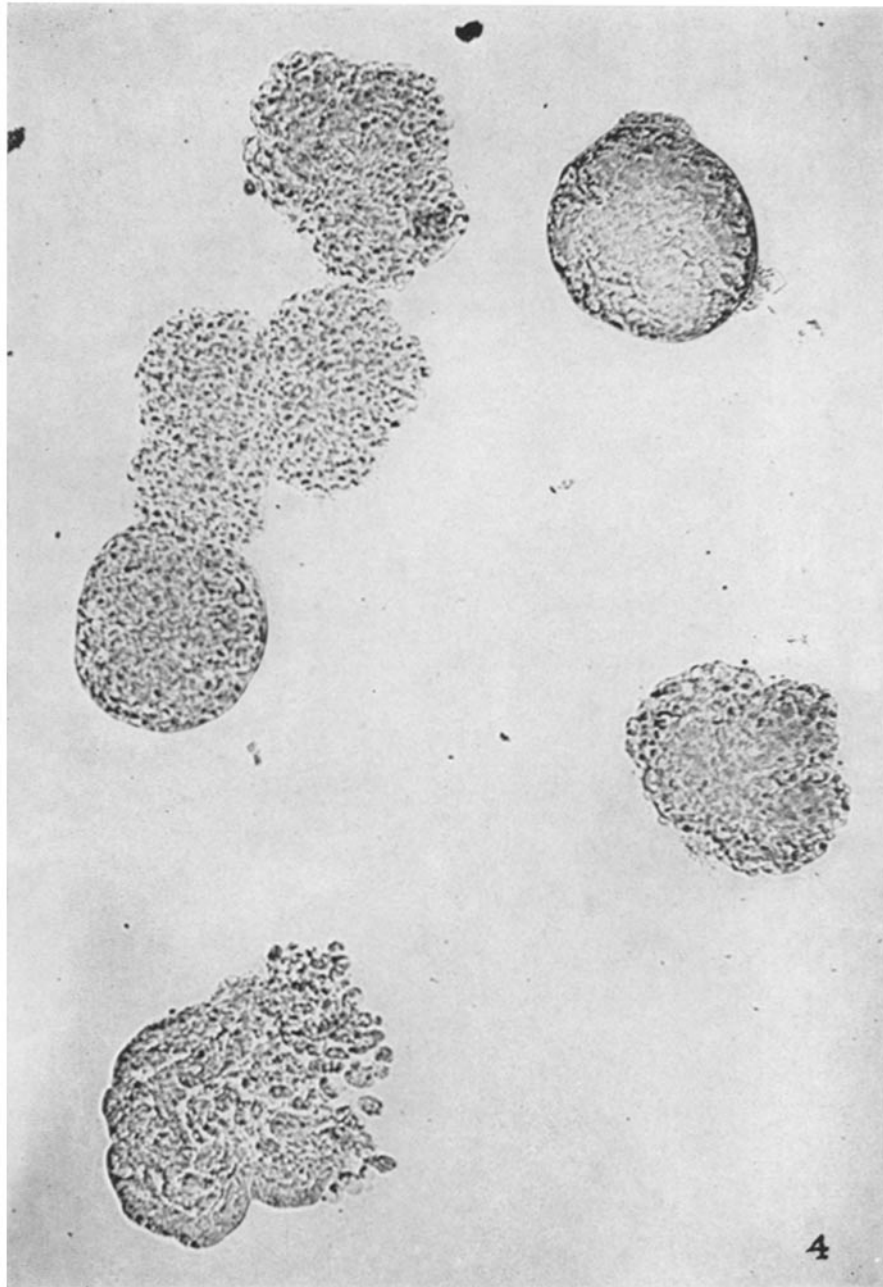


(Solomon *et al.*: Nephrotic nephritis in rats)

PLATE 25

FIG. 4. Glomerular preparation. A high power view of a field similar to that shown in Fig. 3.





(Solomon *et al.*: Nephrotoxic nephritis in rats)