

ASPERMATOGENESIS, ANAPHYLAXIS, AND CUTANEOUS
SENSITIZATION INDUCED IN THE GUINEA PIG BY
HOMOLOGOUS TESTICULAR EXTRACT*

BY JULES FREUND, M.D., GEORGE E. THOMPSON, AND MURRAY M.
LIPTON, Ph.D.

*(From the Division of Applied Immunology, The Public Health Research Institute of
The City of New York, Inc.)*

PLATE 43

(Received for publication, January 14, 1955)

It has been shown that a single intracutaneous injection of autologous or homologous spermia, or testicular suspension incorporated in a water-in-oil emulsion containing killed mycobacteria, induces aspermatogenesis in the guinea pig (1). This process results in the degeneration, necrobiosis, and elimination of most of the germinal cells without injury to the Leydig cells or accessory genital organs, such as the seminal vesicles and the prostate. The purpose of the present paper is to give an account of an effort to purify the antigenic material, and of observations on anaphylactic systemic and cutaneous sensitizations to homologous testicular extracts.

Interest in the antigenic properties of animal tissues has never been lacking. Many studies have dealt with the nature of the specificity of cellular antigens—namely, whether they are species-, intraspecies-, or “organ”-specific. These observations led to inquiries as to the specific cytotoxic action of antibodies, to problems in oncology, blood groups, and serological changes which occur in connection with certain infectious diseases (Wassermann reaction, cold agglutinins, etc.) (2).

Although their mechanisms have not been entirely elucidated, certain experimental diseases may be related to this subject—namely, sterile, disseminated encephalomyelitis (3), neuritis (4), uveitis (5), and aspermatogenesis (1). These diseases can be induced by cutaneous injections of suspensions of the respective organs combined with complete adjuvants. From the standpoint of specificity, all the antigens involved are organ-specific. Encephalomyelitis, neuritis, and uveitis can be evoked by organ suspensions of homologous or heterologous species. It is noteworthy that aspermatogenesis in the guinea pig is not only an organ-specific but also a species-specific process. It cannot be induced in this species by bull spermia or testicular suspension combined with complete adjuvants from the rabbit, the hamster, or the sheep. In the induction of these experimental diseases the potentiating effect of killed mycobacteria suspended in paraffin oil is conspicuous if not essential. These

* Supported in part by a grant-in-aid from the American Cancer Society, Inc., upon recommendation of the Committee on Growth of the National Research Council.

maladies have not been produced by "passive transfer"; *i.e.*, by injecting serum or white cells from sensitized animals. The diseases under discussion nevertheless are probably allergic in nature.

There are other diseases and experimental conditions that are mediated by an immune process involving organ-specific and species-specific antigens. Examples are: erythroblastosis fetalis, "Masugi nephritis," and reverse passive anaphylaxis in the guinea pig following the intravenous injection of rabbit serum bearing Forssman antibodies. In this group of pathological conditions, active sensitization does not occur. The antigen is introduced into an animal whose tissues do not possess the antigen, and the resulting serum antibody is transferred into the target animal.

Materials and Methods

Suspensions of testicles from guinea pigs, rabbits, and sheep were prepared in similar fashion. The testicles, freed from the tunica albuginea, were minced and suspended with the aid of Ten Broeck grinders in an equal amount (*V/W*) of distilled water containing 0.25 per cent phenol. Bull spermia were washed repeatedly in 0.85 per cent salt solution.¹

As a rule the antigen or control material was administered in combination with complete adjuvants—namely, emulsified in paraffin oil containing killed tubercle bacilli or *Mycobacterium butyricum*. Arlacel A (an emulsifying agent) and paraffin oil were mixed in the proportion of 1.5 to 8.5. A weighed amount of killed and dried mycobacteria (usually *butyricum*) was suspended in the mixture (4 mg. per ml.). The antigen in aqueous suspension was emulsified in the oily phase, yielding a water-in-oil emulsion (for details of technique *cf.* reference 1).

The guinea pigs used weighed from 350 to 500 gm. The preparations to be tested were injected into the skin (0.6 or 0.7 ml. per animal) in six or seven sites (0.1 ml. per site) on both sides and about 2 cm. from the spine, in the scapular region. The first simultaneous injections were not repeated. The pigs were weighed weekly and observed often for signs of possible intercurrent diseases. The animals were killed at varying intervals of time after injection by exsanguination under anesthesia. All animals killed or found dead were autopsied. The testes were weighed and placed in Bouin's fixative; other organs, including seminal vesicles, prostate, lungs, spleen, liver, and kidneys, were saved in formalin for histological examination.

EXPERIMENTAL

1. The Antigenic Material

In an attempt to obtain purified material the logical approach would seem to be to use as a source material a single type of cell, namely, isolated spermia. Mammalian spermia however are notorious for their resistance to solvents and mechanical disintegration. (Sonic vibration breaks up spermia but is known to alter certain antigens.)

It was recalled that following the injection of washed spermia plus complete adjuvants, not only the mature spermia but germinal cells of all evolutive stages, *i.e.* immature spermia, spermatids, spermatocytes, and spermatogonia,

¹ A large number of guinea pig testicles were obtained through the courtesy of Carworth Farms, New City, New York, and Sharp & Dohme, Inc., West Point, Pennsylvania. We are indebted to the Ortho Research Foundation, Rahway, New Jersey, for supplying bull spermia.

undergo degeneration and necrobiosis. This observation suggested that antigenic material may be shared by all these germinal cells; thus the whole testis may be a satisfactory source for obtaining antigenic material. In addition, we found (1) that a suspension of testis from sexually immature guinea pigs containing germinal cells but lacking spermia induces aspermatogenesis in adult guinea pigs. For these reasons, whole testes of mature guinea pigs were used as a source of antigen.

I. Ammonium Sulfate-Precipitable Material (ASPM)².—A large number of decapsulated testicles of exsanguinated guinea pigs were mixed with an equal (*V/W*) amount of 0.1 *N* acetic acid, homogenized in Waring blender, and kept overnight at 5°C. The centrifuged sediment was washed with 0.1 *N* acetic acid, and the wash fluid combined with the supernate. Solid ammonium sulfate was added to the pool, kept at ice bath temperature, to reach 30 per cent saturation. 3 or more hours later the mixture was centrifuged and the sediment washed with 30 per cent saturated ammonium sulfate solution. To the combined wash fluid and supernate in the ice bath, further solid ammonium sulfate was added to reach 70 per cent saturation. The mixture was centrifuged after storage overnight at 5°C. The sediment was dissolved in distilled water and dialyzed, either against distilled water at 5°C. or against running tap water at 15 to 20°C. The contents of the bag were freed from a small amount of undissolved material by centrifugation and then lyophilized. The procedure thus far followed the technique often used to obtain crude hyaluronidase from testis (6).

II. Trichloroacetic Acid-Soluble Material (TAASM)³.—Since the ASPM was highly effective in producing aspermatogenesis (even after its activity as hyaluronidase was destroyed by heating) it was further purified by the addition of trichloroacetic acid. To 100 mg. of ASPM in 20 ml. distilled water in an ice bath 16 ml. of 20 per cent trichloroacetic acid was added. The resulting precipitate (after washing) and the supernate (after dialysis) were tested for aspermatogenic activity. Contrary to expectation, the main activity was found in the supernate.

III. Chloroform-Purified Material (CPM)⁴.—The trichloroacetic acid-soluble material was adjusted to pH 4.5 by the addition of hydrochloric acid, and further purified by repeated mechanical shaking with a mixture of chloroform and butyl alcohol. It was then filtered through moist filter paper. Another portion of the filtrate was brought to pH 11 by the addition of sodium hydroxide and similarly treated (7). Both filtrates were found to be aspermatogenic.

The results of testing the antigenic potency of the suspension of whole testis and its fractions are assembled in Table I. *Whole testis suspension* in amounts of 11.25 or 5.62 mg. (dry weight of testis⁵) caused maximal or considerable testicular injury in all guinea pigs. Various degrees of injury were seen in all animals receiving 2.81 or 1.40 or 0.70 mg. With 0.35 mg. in two of eight guinea pigs the testes were normal and in six pigs there was impairment of spermatogenesis. The smallest dose, 0.175 mg., was without effect in five animals in-

² ASPM, ammonium sulfate-precipitable material.

³ TAASM, trichloroacetic acid-soluble material.

⁴ CPM, chloroform-purified material.

⁵ The testicles, freed from the tunica albuginea, were stored at -15°C. Some fluid oozes out before freezing. The solid content of the stored testicles was 15 per cent.

TABLE I
The Degree of Impairment of Spermatogenesis after the Cutaneous Injection of a Suspension of Whole Testes or Its Fractions

Sensitizing Material	Amount of Material	Days after injection																		
		7	9	10	11	13	14	16	17	18	19	21-24	25-30	31-40	41-50	51-75	75-100	101-130	181-235	
Whole testes	11.25												3, † 4, 4, 4							
"	5.62												3/±, 4, 4, 4, 4 †							
"	2.81										2		±/2	4	±, 3					
"	1.40												2, 4 †	1, 2, 4						
"	0.70												2, 3, 4	2, 2, 3						
"	0.35											±	1, 2	0, 0, 2	±, ±, 2, 3					
"	0.175											0 †	0	0, 0, 0						
ASPM§	27									4	4	4		4	4	4	2, 4			
"	20					2				2				4	4, 4, 4	4, 4	3, 4			4
"	15												±, 4	4, 3	4, 4	2	4, 4			
"	2												3, 4	4	3, 4	3				
"	1	0, 0		1, 4	0	4, 4	4					4, 4/3	±	0, ±	±/4					
"	0.2												±	±	±	0, ±/4,				
"	0.04												±	±	±	4				
ASPM	27										0, 0	0	0	0						
"	20											0	0	0, 0,				0, 0, 0		
"	15													0, 0						
"	12.5												0, 0	0, 0						
"	6												0, 0	0 †						
TAASM¶	20										4		4	4	4					4
"	10										4								4	
"	2		4								4	2		2				4		1, 2, 2
CPM**	1.0										4	4	4							
"	0.2										4	4	4, 4							
"	0.04							0, 4			1 † 4	4	4, 4, 4,							
"	0.008										3, 1 †	0, 0, 0,								
"	0.0016										2	0, ±, 2, 3								

The guinea pigs were given multiple, simultaneous, cutaneous injections of 0.1 ml. of an emulsion comprised of 0.0⁵ ml. of antigen, 0.05 ml. of a mixture of arlacel A (emulsifying agent) and bayol F (paraffin oil), and 0.2 mg. (dry weight) of killed mycobacteria.

Each figure refers to the degree of testicular injury in one guinea pig. Fractions indicate different degrees of injury in the two testes of one pig.

Damage was graded as follows:—0, no damage; ±, slight inhibition of spermatogenesis; 1+, very few mature spermia present, immature spermia in the lumen, swelling and vacuolization of a few of the spermatogenic cells (some of these being exfoliated); 2+, may or may not show a few mature spermia: swelling, vacuolization, and exfoliation of fairly large number of spermatogenic cells; 3+, no mature spermia present: swelling, vacuolization, and exfoliation of a large number of spermatogenic cells; 4+, damage ranging from partial to complete devastation of the tubules, with only Sertoli cells and the basement membrane remaining.

* Dry weight.

† Found dead.

§ ASPM, ammonium sulfate-precipitated material.

|| ASPM+, mycobacteria omitted.

¶ TAASM, trichloroacetic acid soluble material; equivalent to X milligrams ASPM.

** CPM, chloroform-purified material.

jected. The *ammonium sulfate precipitated material* was more potent. 1 mg. caused maximal or almost maximal damage in ten pigs killed 14 days after injection, and damage in two of four animals sacrificed between 7 and 11 days after injection. Various degrees of impairment in five of six guinea pigs were evoked by 0.2 mg. Even the smallest dose tested, 0.04 mg., had some biological activity. The fraction obtained from ASPM *soluble in trichloroacetic acid* was not available in sufficient amount to be weighed in lyophilized state. Amounts derived from 2 mg. or more of ASPM caused injury in all animals tested. Smaller amounts were not injected. The *chloroform-purified fraction* was the most active: 0.04 mg. induced 4+ injury in all of five pigs examined from 24 to 27 days after injection, and (1+ and 4+) damage in two of three pigs in 16 to 18 days after injection. The two smallest amounts tested, 8 μ g. and 1.6 μ g., produced various degrees of damage in some of the animals injected.

A comparison of the potency of whole testis and that of the chloroform-purified preparation shows that a considerable purification was achieved. The results may be summarized as follows:—

	Aspermato- genesis	Impairment of spermatogenesis	No effect
	<i>mg.</i>		<i>mg.</i>
Whole testis suspension	5.62	2.81 to 0.75 mg.	0.35 mg.
ASPM	1	<0.04 "	—
CPM	0.04	<1.6 μ g.	—

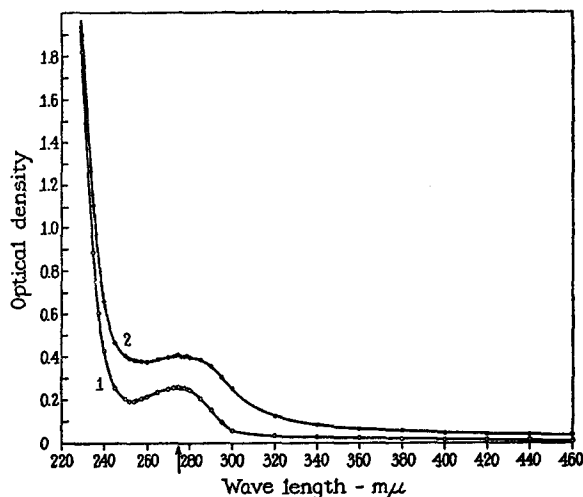
While the observations do not afford an exact determination of the purification accomplished, it appears that, per milligram dry weight, the chloroform-purified fraction is at least one hundred times more potent than the original material, namely, the suspension of whole testis.

From the standpoint of the evaluation of the significance of the relatively slight injury observed in a proportion of the animals, it is noteworthy that in control guinea pigs \pm degree of injury was infrequent, and 1+ damage was exceptional. For example, in nineteen pigs receiving ASPM emulsified in paraffin oil without mycobacteria, the testes were normal. Three animals were given 27 mg.; five, 20 mg.; four, 15 mg.; four, 12.5 mg.; and three, 6 mg. ASPM. They were examined from 20 to 40 days after injection. Other groups of guinea pigs given suspensions of homologous kidney or liver or pancreas in water-in-oil emulsion containing killed mycobacteria were found free of impairment of spermatogenesis.

Since heating of suspensions of spermia, testicular suspension, or ASPM, at 99°C. for 30 minutes did not destroy their aspermatogenic activities, and since the trichloroacetic acid-soluble material on acid hydrolysis yielded about 10 per cent reducing material, expressed as glucose, it appeared that activity

may be associated with a polysaccharide; hence the effects of formamide and proteolytic enzymes on the antigenic material were tested.

Formamide is known to denature proteins and dissolve polysaccharides. Following the technique of Fuller (8) for isolating specific carbohydrates from streptococci, a suspension of testis (prepared with the aid of a mechanical homogenizer) was dried and then heated in an oil bath at 140°C. for 30 minutes in the presence of formamide. The material in solution was dialyzed and found to be aspermatogenic. Likewise, lyophilized chloroform-purified material (CPM) remained aspermatogenic following treatment with formamide.



TEXT-FIG. 1. Absorption spectra. (1) trichloroacetic acid-soluble material (1 mg./1 ml.); (2) chloroform-purified material (1 mg./1 ml.).

The resistance of the biological activities of ASPM and CPM to proteolytic enzymes was tested, using pepsin or a combination of trypsin and chymotrypsin under appropriate conditions (9). The preparations did not lose their activities.

Since the aspermatogenic material does not seem to be a protein, it may be expected that it would resist autoclaving. A suspension of testes was autoclaved at 15 pounds' pressure for 20 minutes and administered with complete adjuvants to three groups of guinea pigs. They received 22.5, 11.25, and 5.62 mg. (dry weight) respectively of autoclaved testicular suspension. Maximal injury was found in the testes of all guinea pigs from 21 to 29 days after injection.

The following additional information on CPM is available: it was non-dialyzable; on acid hydrolysis reducing material was found, accounting for 10 per cent of the dry weight, expressed as glucose; it contained from 3.5 to 4 per cent nitrogen; positive ninhydrin and biuret tests were obtained; its ultraviolet ray absorption curve indicated the presence of aromatic amino acid (see Text-fig. 1).

2. Histological Changes in the Testis and Epididymis

The cellular injury that develops in the guinea pig following the cutaneous injection of a suspension of homologous or autologous testis combined with complete adjuvants has been described in the preceding paper (1). It is characterized by selective damage to the germinal cells. The exfoliated and degenerated or dead cells and the "mucoïd" material that can be seen in the seminiferous tubules may appear in the epididymis. Considerable injury to the germinal cells may be present without inflammatory reaction. Accumulation of large mononuclear cells and fibroblasts, however, may be found in the intertubular spaces in some of the testes with aspermatogenesis. This cellular reaction seems to follow rather than introduce the impairment of spermatogenesis.

During the course of the present experiments using solutions of purified antigens and larger amounts of active material, very intense focal or widespread inflammatory reactions were often seen about seminiferous tubules that were highly damaged. The inflammatory cells included large mononuclear cells, plasma cells, lymphocytes, and fibroblasts. Neutrophilic leucocytes were conspicuously absent. Particularly when large numbers of exfoliated and fragmented germinal cells were seen in the tubules of the epididymis, the intertubular spaces of the epididymis and the connective tissue covering it were edematous and contained large mononuclear cells and lymphocytes. Polymorphonuclear leucocytes were not found.

As in the previous experiments, the Leydig cells were not visibly damaged, and occasionally appeared hyperplastic. The accessory genital organs, namely the seminal vesicles and prostate, showed no abnormalities. Their secretions were abundant.

It was noted that when the testicular injury was minimal or moderate, the seminiferous tubules at the upper pole (which is distant from the head of epididymis) of the testis showed more advanced damage than other parts of the testis.

3. Anaphylaxis and Cutaneous Reaction to Antigenic Material

When antigenic material became available in clear solution and in fairly concentrated form it became possible to test for systemic anaphylaxis and local cutaneous reactivity.

One group of guinea pigs receiving ASPM plus complete adjuvants was later given intravenous injections of either ASPM or CPM; another group of animals was sensitized with formamide-treated material plus complete adjuvants and later challenged with intravenous injections of ASPM (Table II). Controls included groups of two or three normal guinea pigs injected intravenously with amounts of ASPM or CPM used in the anaphylactic experiments, and guinea pigs that received first cutaneous injections of guinea pig kidney suspensions plus complete adjuvants followed 5 to 9 weeks later by ASPM or CPM intravenously.

Table II shows that a considerable number of the guinea pigs sensitized with homologous testicular antigen became anaphylactic. Not only were the symptoms characteristic of anaphylaxis, but the gross and microscopic examination

TABLE II
Anaphylaxis in Guinea Pigs Sensitized with Testicular Material with or without Mycobacteria

Sensitizing material	Interval of time	Challenging material	Anaphylactic shock	Testicular damage
<i>mg.</i>	<i>days</i>	<i>mg.</i>		
ASPM		ASPM		
20	97	40	Shock † 14 min.	4+
20	97	20	Shock † 3 hrs.	4+
15	32	40	Shock	Not done
15	32	40	Shock † 30 min.	4+
15	32	40	Shock † 4 min.	4+
ASPM		CPM		
15	42	10	Shock	4+
15	47	10	Shock † 6 min.	4+
15	47	10	Shock † 5 min.	4+
15	51	10	Mild shock	3+
15	51	10	0	3+
15	55	10	Mild shock	4+
15	47	6	Shock	Not done
15	47	4	Shock	2+
CPM treated with formamide		ASPM		
Equivalent to 6 mg. CPM	18	40	Shock † 5 min.	4+
	18	40	Shock † 2 min.	4+
	13	40	Shock	4+
	13	40	0	4+
	19	20	Shock † 4 min.	4+
	19	20	Shock † 4 min.	4+
ASPM		ASPM		
15	22	40	Shock † 5 min.	±
No mycobacterium	22	40	Shock † 3 min.	±
	22	40	Shock † 5 min.	+
	22	40	Mild shock	±

† Death.

of the lungs showed extreme emphysema. Anaphylactic shock was not observed in any of the control animals.

Since, in the guinea pig, anaphylactic sensitization to most antigens can be induced without employing mycobacteria, four animals were given intracutaneous injections of 15 mg. ASPM

emulsified in paraffin oil without mycobacteria to determine whether the same results would occur with homologous testicular antigen. 4 weeks later they received an intravenous injection of 40 mg. ASPM. Three died of anaphylactic shock, and one had mild symptoms and recovered. The pathological changes in the testes of these animals were negligible.

TABLE III
Summary of Skin Tests

Sensitization material	Amount of material	ASPM	Skin test material		Sheep ASPM
			ASPM + trypsin	CPM	
ASPM	<i>mg.</i>				
	15	7/7*	3/3	2/2	0/2
	2	2/2			
	1	0/1			0/1
	0.2	0/1			0/1
	0.04	0/1			0/1
ASPM, no mycobacteria	15			1/3	
ASPM, heated	20	1/1		3/3	
	2	1/1			
CPM, formamide	Approximately 1	3/3		3/3	
None		0/4		0/3	
Kidney suspension	50	0/6	0/1	0/3	
Sheep ASPM	125	1/5‡	0/3	1/5‡	

The guinea pigs were given seven simultaneous cutaneous injections including complete adjuvants. All animals were skin-tested from 4 to 6 weeks later, except three sensitized with 15 mg. ASPM. These were tested 4 months after sensitization.

The controls did not react to 3 mg. test material except for pink or purplish evanescent discoloration. As a rule, 1 mg. of the test material caused redness and swelling at least 20 mm. in diameter and raised 4 mm., and lasting for more than 1 day.

* No. positive/number tested.

‡ Doubtful reaction.

Local cutaneous reactivity was tested in guinea pigs sensitized by the injection of the following antigenic preparations plus complete adjuvants: (a) ASPM, (b) heated ASPM, (c) CPM treated with formamide, (d) ASPM from sheep. In addition, three pigs were given ASPM in water-in-oil emulsion without mycobacteria. Skin tests were made with (a) ASPM, (b) ASPM digested with trypsin plus chymotrypsin, (c) CPM, and (d) ASPM from sheep. The toxicity of the skin test material was tested in normal pigs. To test the specificity of the skin reactions, skin tests were made in animals previously injected with ASPM from sheep or guinea pig kidney suspension (plus complete adjuvants). All animals were skin-tested by three

simultaneous injections of 0.1 ml. of antigenic solutions containing 2, 1, and 0.2 mg. of antigenic material.

Table III illustrates that ASPM, heated ASPM, and CPM treated with formamide (all combined with complete adjuvants) caused cutaneous sensitization to ASPM, ASPM subjected to proteolytic enzymes, and to CPM. Of three guinea pigs receiving 15 mg. ASPM in oil but without mycobacteria, one showed a cutaneous reaction to CPM. The control tests for toxicity and specificity were negative.

The skin reactions were rather similar in appearance and duration. As a rule reactions to 2 mg. were slightly stronger than to 1 mg. of antigen; and 0.2 mg. did not cause clear-cut reactions.

One characteristic reaction may be described in detail:—

At 15 Minutes.—ill defined faint redness and ill defined soft swelling, 25 by 20 mm., slightly raised; center purple, 10 by 10 mm.

At 4 Hours.—well defined redness and well defined soft swelling, 45 by 35 mm., raised 8 mm.; center purple, 10 by 10 mm.

At 24 Hours.—well defined redness and well defined soft swelling, 35 by 35 mm., raised 4 mm.; center pale, 3 by 3 mm.

At 48 Hours.—ill defined redness and ill defined soft swelling, 30 by 20 mm., raised 3 mm.; center white, 3 by 3 mm.

At 72 Hours.—ill defined faint redness, 8 by 8 mm., no swelling; center white, 3 by 3 mm.

DISCUSSION

The observations presented show that an aqueous solution obtained from testicles was highly potent in inducing impairment of spermatogenesis. During its preparation most of the proteins were removed by consecutive precipitations with ammonium sulfate (30 per cent saturated), trichloroacetic acid, and chloroform. Autoclaving at 15 pounds' pressure for 20 minutes, formamide and proteolytic enzymes did not destroy its aspermatogenic activity. On acid hydrolysis it yielded reducing material. The purified solution gave ninhydrin and biuret tests. The ultraviolet absorption curve suggested the presence of an aromatic ring. It contained from 3.5 to 4 per cent nitrogen. The material induced systemic anaphylaxis in the homologous animal even when injected in water-in-oil emulsion that contained no mycobacteria. Skin reaction was elicited in guinea pigs previously injected with the antigenic material plus complete adjuvants.

It was pointed out in a preceding paper (1) that the injection of homologous or autologous spermia with or without paraffin oil evokes the formation of specific agglutinins, immobilizing and also complement-fixing antibodies. However, under the conditions of the experiments, the presence of mycobacteria at the site of injection is a requisite for aspermatogenesis. The effect of mycobacteria—in conjunction with observations on the role of mycobacteria on immune responses to other antigens—points to the allergic nature of the testicu-

lar injury. Numerous attempts were made to produce aspermatogenesis by intravenous or intratesticular injection of sera from sensitized pigs into normal pigs. The results were negative. Impairment of spermatogenesis has been produced in the albino rat only by repeated intracutaneous injections of homologous testicular suspensions combined with complete adjuvants (10(a)). Again the addition of mycobacteria to the water-in-oil emulsion of testis is essential (10(b)). The testicular injury may be tentatively included in the category of tuberculin type of allergy.

In addition, manifestations of presumably another type of sensitization, namely of the anaphylactic type, were revealed in the present experiments. Systemic anaphylaxis or skin reaction was not demonstrable using spermia or testicular suspensions in the previous study. With an aqueous solution of more concentrated antigenic material, anaphylactic systemic and skin reactions were readily elicited. The inflammatory reaction of the skin appeared within a few minutes after injection and persisted for 2 days; the swelling was soft and necrosis did not develop. The character of the skin reaction suggests anaphylactic rather than tuberculin type of sensitization. In this connection it seems significant that a single injection of antigenic material in water-in-oil emulsion without mycobacteria incited anaphylactic sensitization but not impairment of spermatogenesis. The few attempts made to transfer anaphylaxis with the sera of sensitized animals failed. It is known however that a requisite for successful transfer of anaphylaxis with sera of actively sensitized guinea pigs is the presence of sufficient amount of antibody in the sera, and this condition may not have been met in the trials that were made.

Aspermatogenesis and anaphylactic (systemic and local) sensitization well may be immune responses to the very same antigen. These processes differ in relation to the effect of mycobacteria in initiating aspermatogenesis and anaphylactic sensitization. Also, from the standpoint of the injury itself, aspermatogenesis and anaphylactic "sensitization" seem to be quite different. In aspermatogenesis the germinal cells are subjected to the action of an agent (antibody) that has specific relationship to antigen present in the germinal cells resulting in degeneration and necrobiosis. However, anaphylactic "sensitization," systemic or local, seems to be a reaction to the union of antigen and antibody that takes place in any of the tissues, most likely in the intercellular spaces (11).⁶

Another instance of anaphylactic sensitization to homologous antigen or antigens has been found with reference to proteins from the lens. These proteins

⁶ Anaphylaxis does not need to imply sensitization of tissues to an antigen. This is shown in the reverse passive anaphylaxis, systemic or local: first the antigen is injected and a few hours later the antibody. The reaction that promptly follows cannot be interpreted as sensitization of the animal or its skin to either the antigen or the antibody. The reaction may be an effect of the union of antibody and antigen in the tissues.

(there are at least four proteins in the lens) are organ-specific with very limited species specificity. Markin and Kyes, as well as others (12), found that guinea pigs react with systemic anaphylaxis to repeated injections of homologous lens proteins. These antigens can be regarded as secretion products rather than cellular antigens. When proteins from guinea pig lens plus complete adjuvants were injected into guinea pigs, precipitins against these proteins are produced in abundance; but inflammatory or other cellular changes were not detectable by histological observation (13). Ophthalmoscopic examinations were not made.

Henle *et al.* (14) studied the antigenic composition of bull spermia. The cells were disintegrated by sonic vibration. The antigenic fractions injected into rabbits led to the formation of antibodies which agglutinated spermia, fixed complement in the presence of these fractions, and could be absorbed from the serum with the respective antigenic fractions. Species specificity was tested with bull, human, rabbit, and rat spermia.

With the aid of absorption experiments it was shown that there is one antigen present exclusively in the heads and another one exclusively in the tails of bull spermia. These antigens are not species-specific and are thermolabile. Another antigen present in both the heads and tails induces the formation of antibodies which cross-react to some extent with antigens from human and canine spermia. However, when this antigen is heated at 100°C. for 20 minutes, only species-specific reaction is obtained.

It is possible that if the guinea pig received a larger amount of cross-reacting antigen from a heterologous species in excess of the amount injected in the form of spermia or testicular suspension it would develop aspermatogenesis. The capacity of the homologous or autologous spermia to incite immune response may be explained by assuming that the germinal cells contain antigenic substances absent in the somatic cells, for the germinal cells transmit certain characteristics not necessarily present in the somatic cells of the individual. This thought led us to administer repeated injections of homologous ovarian suspensions combined with complete adjuvants to young adult female guinea pigs. In the histological sections of their ovaries no abnormalities were visible. The negative results might be due to the insufficient number of ova injected or to the absence of true ovogenesis in postembryonic life.

SUMMARY

Guinea pig testicles were extracted with acetic acid; the extract was purified by removing material in consecutive precipitations with 30 per cent saturated ammonium-sulfate, trichloroacetic acid, and chloroform. The solution so purified, when administered with complete adjuvants, was highly active in inducing impairment of spermatogenesis in guinea pigs. The activity resisted autoclaving at 15 pounds' pressure for 20 minutes, proteolytic enzymes, and formamide.

Anaphylactic shock and cutaneous reaction to the purified homologous extract occurred in guinea pigs sensitized by the extract combined with adjuvants.

For the production of aspermatogenesis it was essential to incorporate killed mycobacteria into the water-in-oil emulsion containing the antigen; but anaphylactic sensitization did not require the presence of mycobacteria.

BIBLIOGRAPHY

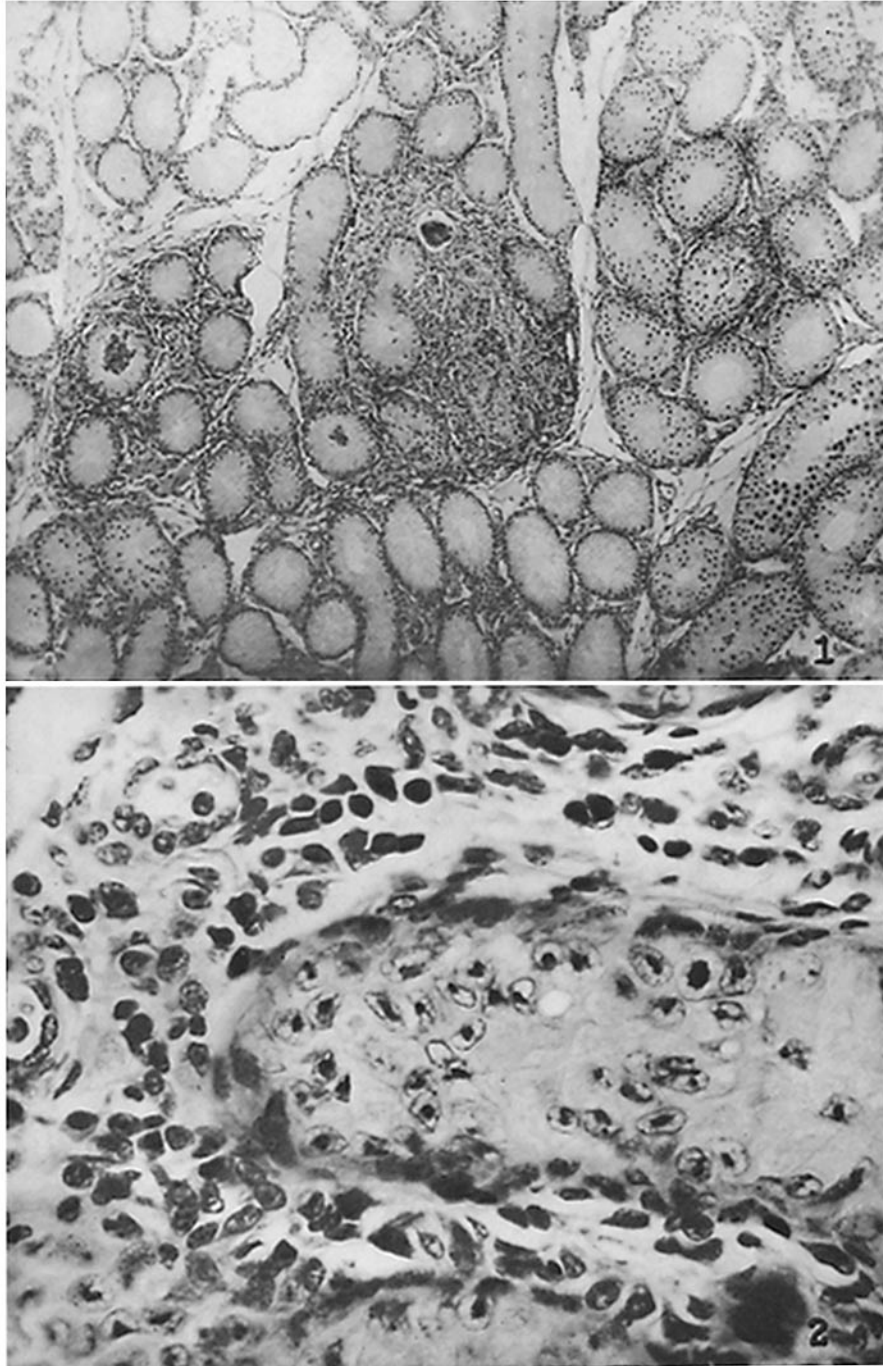
1. Freund, J. Lipton, M. M., and Thompson, G. E., *J. Exp. Med.*, 1953, **97**, 711.
2. Landsteiner, K., *The Specificity of Serological Reactions*, Cambridge, Harvard University Press, revised edition, 1945.
3. Rivers, T. M., Sprunt, D. H., and Berry, G. P., *J. Exp. Med.*, 1933, **58**, 39. Morgan, I. M., *J. Exp. Med.*, 1947, **85**, 131. Kabat, E. A., Wolf, A., and Bezer, A. E., *J. Exp. Med.*, 1947, **85**, 117. Freund, J., Stern, E. R., and Pisani, T. M., *J. Immunol.*, 1947, **57**, 179.
4. Waksman, B. H., and Adams, R. D., *Fed. Proc.*, 1954, **13**, 516.
5. Collins, R. C., *Am. J. Ophthalm.*, St. Louis, 1949, **32**, 1687; 1953, **36**, 150.
6. Freeman, M. E., Anderson, P., Oberg, M., and Dorfman, A., *J. Biol. Chem.*, 1949, **180**, 655.
7. Sevag, M. G., *Biochem. Z.*, 1934, **272**, 419.
8. Fuller, A. T., *Brit. J. Exp. Path.*, 1938, **19**, 130.
9. Hawk, P. B., Oser, B. L., Summerson, W. H., *Practical Physiological Chemistry*, New York, The Blakiston Company, Inc., 13th edition, 1954.
- 10 (a). Freund, J., Lipton, M. M., and Thompson, G. E., *Proc. Soc. Exp. Biol. and Med.*, 1954, **87**, 408; (b) Unpublished observations.
11. Freund, J., and Whitney, C. E., *J. Immunol.*, 1928, **15**, 369; 1929, **16**, 109. Freund, J., *J. Exp. Med.*, 1930, **51**, 889.
12. Markin, L., and Kyes, P., *J. Infect. Dis.*, 1939, **65**, 156.
13. Freund, J., unpublished observations, 1950.
14. Henle, W., Henle, G., and Chambers, L. A., *J. Exp. Med.*, 1938, **68**, 335.

EXPLANATION OF PLATE 43

FIG. 1. Testis of guinea pig after intracutaneous injection of 20 mg. ammonium sulfate-precipitated material of testicular extract combined with complete adjuvants, showing focal accumulation of mononuclear cells about damaged seminiferous tubules. $\times 66$.

FIG. 2. The same $\times 400$.

Illustrations of other characteristic sections are shown in a previous paper (1).



(Freund *et al.*: Sensitization induced by testicular extract)