

STUDIES ON ANTIBODY PRODUCTION

I. A METHOD FOR THE HISTOCHEMICAL DEMONSTRATION OF SPECIFIC ANTIBODY AND ITS APPLICATION TO A STUDY OF THE HYPERIMMUNE RABBIT*, †

BY ALBERT H. COONS, M.D., ELIZABETH H. LEDUC, § PH.D., AND
JEANNE M. CONNOLLY

*(From the Department of Bacteriology and Immunology and the Department of Anatomy,
Harvard Medical School, Boston)*

PLATES 9 AND 10

(Received for publication, March 3, 1955)

This paper and those which accompany it describe a method for the specific histochemical demonstration of antibody, and present data gleaned by its use concerning the response to antigenic stimulation. These data indicate that the major site of antibody formation is a family of cells which first appear as a response to the stimulus. The response consists of cell multiplication, cell differentiation, and the concurrent synthesis of a specific protein, antibody. The mature member of this cell family is the plasma cell.

The introduction of visible labels into the study of immunological reactions by Heidelberger, Kendall, and Soo Hoo (2) led directly to an experiment by Marrack (3) in which he demonstrated that an antibody molecule could be coupled with a dye molecule without loss of capacity for specific reaction with antigen. Subsequently it was demonstrated that fluorescent compounds like anthracene and fluorescein could be conjugated with antibody molecules, also without loss of activity (4-6). When tissue sections containing antigen specific for the antibody solution were flooded with such fluorescein-antibody conjugate and the excess of this reagent later rinsed away, the specifically precipitated antibody was visible under the fluorescence microscope by virtue of the brilliantly fluorescent yellow-green label, and hence served as a specific histochemical stain or fluorochrome. This procedure has been successfully applied to the study of an increasing number of antigens, and appears to have wide applicability.

A consideration of the possibility of a similar approach to the localization of antibody leads at once to the thought that labelled antigen might be similarly deposited over an area containing antibody. However, the chemical

* A preliminary account was presented before a meeting of the American Association of Immunologists, April 7, 1953 (1).

† This work was supported by a grant-in-aid from the Helen Hay Whitney Foundation.

§ Present address: Department of Biology, Brown University, Providence.

diversity of antigens limits this plan, or at least greatly increases the technical problem. Further, the larger number of immunologically reactive groups on an antigen as compared with an antibody molecule would probably have the effect of making the detection of antibody less sensitive than the detection of antigen. On the other hand, if a section containing antibody were allowed to react with antigen, and the deposited antigen then revealed by a subsequent reaction with labelled antibody, both these limitations would have been overcome. The distinction between antigen present from the beginning as a consequence of injection, and antigen gained by reaction *in vitro* would of course have to be drawn by use of a control section in which the antigen step in the staining procedure had been omitted.

Since there were evident advantages in such a two-step procedure, and since no new reagents were necessary, this alternative was tried first; it has become our routine procedure. Compared with direct staining of antibody with labelled antigen, it is more sensitive, although the same results were obtained in a few experiments. Somewhat brighter staining is achieved when both reagents are fluorescent, but this modification has not been exploited.

Materials and Methods

Reiss, Mertens, and Ehrich (7) were the first workers to demonstrate the presence of antibody in individual cells. They injected typhoid or *Brucella* antigen into the hind foot-pad of rabbits. At intervals thereafter they sacrificed the animals, removed the popliteal lymph nodes draining the site of injection, and made cell suspensions from them. After washing in saline, the cell suspensions were placed on slides and mixed with a dilute suspension of washed homologous organisms. They observed that the bacteria adhered to certain cells in the suspensions, which they identified as members of the plasma cell series. Later, Hayes, Dougherty, and Gebhardt (8) applied a similar technique to subcutaneous connective tissue taken from a site of prior antigen deposition, and reported the adherence of the organisms to the surface of some of the cells present. The cells which showed this phenomenon were larger than small lymphocytes, and these authors identified them as large lymphocytes. Finally, Moeschlin and Demiral (9), studying the spleens of repeatedly stimulated animals by a similar method, found that the cells which agglutinated the organisms contained in their cytoplasm granules, visible under the phase microscope, which they had previously described in the cytoplasm of developing plasma cells (10).

Animals.—The rabbits used for immunization were albino males purchased from local dealers, and weighed about 2.5 kg. at the time of acquisition. They were given intravenous injections of alum-precipitated human γ -globulin or crystalline hens' ovalbumin in 10 mg. doses on 3 successive days each week; alum precipitation was carried out by the method of Heidelberger and Kendall (11). Rabbits 6-39 and 6-41 had received six such courses of human γ -globulin during the winter of 1950-51 as part of a group for the production of antiserum. In August, 1951, they received five additional injections (two of them intraperitoneal). They were bled and killed with chloroform on the 5th day after the last injection. Rabbits 6-40 and 6-42 had similar histories except that the antigen used was crystalline ovalbumin. An

additional series of five rabbits received four courses of ovalbumin as described above in August, 1951, and one intravenous dose on October 21, 1951. (One of the five was not injected at this time, and served as an "unboosted" control. They were bled and killed with chloroform on the 2nd, 4th, 6th, and 13th day respectively after this injection.

The serum from the last group of animals was stored frozen, and subsequently antibody nitrogen determinations were carried out (12), nitrogen being determined by the method of Koch and McMeekin (13).

The organs of these animals were preserved for histological examination by placing small pieces against the inner wall of test tubes and plunging the stoppered tubes into alcohol cooled to -70°C . with solid carbon dioxide. They were then stored at -20°C . until use.

Frozen sections of these unfixed tissues were cut at $4\ \mu$ in a cryostat by the method of Linderstrøm-Lang and Mogensen (14), somewhat modified (15).

Fluorescent antibody solutions against human γ -globulin and ovalbumin were prepared as previously described by coupling to fluorescein isocyanate (5, 6, 15).

"Buffered saline".—0.8 per cent (*w/v*) sodium chloride containing 0.01 *M* phosphate at pH 7.0.

Fluorescence microscopy was carried out using the equipment previously described (5), modified by the use of a darkfield condenser (16, 17).

Preparation of acetone-dried tissue powders for absorption of conjugates.—This procedure, to remove "non-specific staining" (6), was carried out as follows: Place 25 to 50 gm. of fresh or frozen tissue in a Waring blender with an equal volume of 0.15 *M* NaCl solution. Homogenize the tissue with short repeated activations of the propeller, avoiding heating. Pour the homogenate into a beaker and add 4 volumes of acetone with stirring. After allowing the mixture to stand for a few minutes, decant and discard the supernatant. Pack the precipitate by centrifugation, and wash it in the centrifuge with several changes of saline solution until the supernatant is free of hemoglobin. Suspend the washed precipitate in an amount of saline about equal to the volume of the precipitate, and to this suspension add 4 volumes of acetone with stirring. After allowing the suspension to settle for a few minutes, decant and discard the supernatant, add 4 more volumes of acetone, harvest with suction on a Buchner funnel, wash the precipitate with acetone, and allow it to dry on the funnel. Finally, dry the powder overnight at 37°C ., and store it stoppered in a refrigerator at 4°C . The object of the procedure is to obtain dry, saline-insoluble material.

For use, such a powder is stirred into an aliquot of a fluorescein-antibody solution (usually 5 ml.) in the amount of 100 mg./ml. It is our practice to do this in a 25 ml. lusteroid tube. After standing for about an hour at room temperature with occasional stirring, the supernatant is harvested by centrifugation in the cold at 18,000 R.P.M. in an angle head. The absorption is then repeated with an appropriate amount of powder (in this case about 300 mg.). The yield of conjugate is about 30 per cent. The use of the high speed centrifuge packs the powder more tightly and increases the yield, but the procedure may be carried out at 3000 R.P.M. with larger mechanical losses.

Aliquots of conjugate absorbed in this manner do not always keep well, and hence it is better to absorb small amounts as needed. At the end of the absorption procedure, 1/10,000 merthiolate is added, even though there is already some present in the stock conjugate solution.

The data reported in this paper were collected with the aid of conjugates absorbed twice with mouse liver powder. It has subsequently developed (see below) that rabbit tissue is best studied by means of conjugates absorbed once with mouse liver and once with rabbit bone marrow powder.

"Staining" for Antibody.—Frozen sections of various tissues were fixed in 95 per cent ethanol (*v/v*) in Coplin jars for 15 minutes at 37°C . in a water bath. They were then placed in an upright position in an incubator at 37°C . for 30 minutes. For the demonstration of antibody, each section was rinsed with buffered saline and covered with a drop of solution con-

taining antigen in a concentration of 1/2000 (*w/v*) in buffered saline. The slides were kept in a small moist chamber to prevent evaporation for 30 minutes, then rinsed off with buffered saline and washed in buffered saline with gentle motion for 10 minutes. They were then wiped dry except for the area of the section, covered with a drop of absorbed fluorescein-antibody conjugate, and again allowed to stand at room temperature in a moist chamber for 30 minutes. They were then washed as before and mounted in buffered glycerol. (Reagent glycerol 9 parts, buffered saline 1 part.)

Control slides were prepared by omitting the exposure to antigen, or sometimes with a heterologous antigen solution; such controls allowed the recognition of non-specific reactions, and of antigen persisting from injection. Actually no antigen was found in these animals. More elaborate controls were also employed during the course of acquiring more experience with the recognition of antibody. For example, the spleens from two animals immunized with different antigens were studied in parallel with both antigen-antibody systems. Such experiments established that the tissues from immune rabbits have no appreciable affinity for human γ -globulin or for ovalbumin in the absence of specific antibody. They do, however, have an affinity for labelled antisera, which has been referred to (6) as "non-specific staining," and which is described in the next section.

RESULTS

"Non-Specific Staining".—Conjugates prepared from antisera made in rabbits and horses were found, after two absorptions with mouse liver powder, to stain masses of material in the red pulp of the rabbit spleen, scattered cells in lymph nodes, Kupffer cells in the liver, and scattered cells in the stroma of other organs (Figs. 9 to 12). The staining in the spleen was particularly inconvenient in these studies because it was so extensive in some rabbits that it seriously impaired the observation of antibody content, even though the morphological features of the two phenomena differ. White (18) had noted that labelled antibody solutions stained polymorphonuclear leucocytes and eosinophiles in the rabbit. Meantime, Sheldon (19) had made the same observation, and had further found that this staining could be abolished by absorbing the solutions with rabbit bone marrow powder. We have confirmed this observation as noted above.

The observations reported in the present paper, however, were made before this expedient was known, and therefore our observations could only be made on rabbits in which there was little non-specific staining and substantial numbers of antibody-containing cells.

Because of its importance as a complicating factor and because of its perhaps important but unknown intrinsic significance, it is desirable to describe this "non-specific" staining in detail.

In the *spleen* it consisted of rather large amorphous aggregates of brightly fluorescent material dotted with the shadows of small non-fluorescent objects (Fig. 9); or of isolated cells or clusters of cells with brightly fluorescent cytoplasm. On comparison with Giemsa-stained sections these appearances were seen to represent groups of degenerating polymorphonuclear leucocytes, or macrophages with pale blue cytoplasm in which eosinophilic fragments and vacuoles were found. In *lymph nodes*, there were small clusters of cells within the nodules,

or occasional cells in the medullary areas with oval nuclei and abundant cytoplasm, or occasional or frequent cells with faintly fluorescent cytoplasm and lobulated nuclei, or a line of indistinctly outlined cells corresponding to the cells lining a lymph sinus (Fig. 12).

Conventional Staining of Sections for Identification of Cells Containing Antibody.—Attempts to stain the same field first to reveal antibody and then by conventional histological methods failed except in a few instances. The cells after having been carried through the manipulations described above for the demonstration of antibody were almost invariably unrecognizable when stained afterward with Giemsa. The cytoplasm usually failed to stain at all, although it was still apparent under the fluorescence microscope. Moreover, the use of methyl green-pyronine was unsatisfactory on frozen sections for reasons still unclear, as has also been found for frozen-dried material by Brachet (20) and others.

Recourse therefore was had to the use of adjacent sections, one stained for antibody, the other by Giemsa's method for histological study. As will be emphasized in the second paper of this series, the identification of the cell type responsible for the bulk of antibody production depends on the circumstance that during the secondary response, or in animals a few days after the last of a series of repeated injections, antibody-containing cells are present in large groups in the red pulp of the spleen. These large groups are easily seen also in adjacent sections, and there is no doubt that under these circumstances the cells can be unequivocally recognized.

Antibody-Containing Cells in Various Organs of the Hyperimmune Rabbit

In 1898 Pfeiffer and Marx (21) conducted an elegant series of experiments which established unequivocally that the spleen was a major site of protective antibody formation against cholera, and that the bone marrow, the lymph nodes, and perhaps the lungs made contributions. Using carefully weighed amounts of spleen, blood, and serum, and careful neutralization tests with death as the end point, they found that there was a higher concentration of antibody in the spleen than in the blood as early as the 2nd day after a subcutaneous injection of cholera vaccine, that this persisted until about the 5th day, and that thereafter the concentration in the serum became higher. Although assays of other organs were carried out with the tissues of one rabbit only, on the 5th day after antigenic stimulation, the findings concerning the spleen involved 12 immunized animals and 4 normal controls. They also reported that circulating leukocytes and the cells in inflammatory exudates contained less antibody than the serum. These early findings have been repeatedly confirmed. An excellent and exhaustive review has recently been published by McMaster (22).

Those investigators who during the past 15 years have studied the cellular changes in the rabbit following *prolonged* immunization have unanimously been impressed by the large numbers of plasma cells which appeared, and they have all concluded that the plasma cell was a site of antibody formation. Bing and Plum (23) stimulated a growing body of experimental work when they pointed out in 1937 the association in human pathology between elevated serum globulin levels and large numbers of

plasma cells. Bjørneboe and Gormsen (24) set out to test this experimentally by the prolonged immunization of rabbits with mixtures of as many as eight different antigens injected simultaneously, which had previously been found (25) to produce marked elevation of serum globulin. During the first 2 weeks of intravenous injections on alternate days massive infiltrations of plasma cells developed in the red pulp of the spleen, and smaller collections in the medullary areas of lymph nodes, the portal connective tissue of the liver, the perivascular and peribronchial connective tissue of the lungs, the interstitial tissue of the kidney, and in the fat underlying the renal pelvis. There were moderate increases of plasma cells in the bone marrow, and in the sinusoids of the adrenal. These changes followed multiple dosage with pneumococci, with salmonellae, and to a considerably lesser extent with a mixture of three foreign sera administered in a total dosage of 0.5 to 1 gm. over a period of 2 months. The degree of plasma cell infiltration corresponded in individual animals with the concentration of antibody in the serum. Fagraeus (26, 27) found that surviving tissue from splenic red pulp containing such infiltrations produced antibody *in vitro* while similar explants from white pulp produced less or none, a finding which has been confirmed by Keuning and van der Slikke (28) and by Thorbeke and Keuning (29) although in the latter's experiments there was some antibody production in explants of white pulp. Similar cultures from other organs yielded evidence of synthesis of antibody by the bone marrow and lymph nodes, not by thymus or liver. Bjørneboe and Gormsen (24) could find no plasma cells in the thymus of their animals. Bjørneboe, Gormsen, and Lindquist (30) later studied the antibody content of the fat around the renal pelvis in animals where there was a plasma cell infiltration, and found values 20 per cent those of the serum, whereas fat from nearby sites containing few plasma cells contained little or no antibody.

Summarizing this evidence on hyperimmune animals, then, masses of plasma cells develop following vigorous antigenic stimulation; tissue containing them relatively free from the other cell types of reticular tissue contains more antibody than does similar tissue without plasma cells, and tissue containing plasma cells continues to synthesize antibody *in vitro*, whereas tissue without them does not. The literature concerning lymph nodes after one injection of antigen, and the cellular changes and antibody formation resulting, will be summarized and discussed in an accompanying paper (31).

The descriptions which follow are based on the appearance under the fluorescence microscope after carrying out the reaction for antibody, compared with that of the control, of sections of various organs from the four rabbits killed on the 5th or 6th day after the last injection of a series. Serum antibody levels were not determined on these rabbits.

Spleen.—Antibody was demonstrable in the cytoplasm of cells around the periphery of the lymphoid follicles, in the red pulp, and in a cuff around some of the small arteries (Figs. 1 to 3). For the most part these cells lay in clusters of several up to about a dozen. The cuffs around the arteries, lying in the adventitia and just outside it, were from two to three up to five to six cells thick. There were occasional single antibody-containing cells. Under higher power, the antibody-containing cells showed abundant cytoplasm, which was brightly fluorescent, and in some of them there was a faint fluorescent network in the nucleus. In the lymphoid

follicles there were very faint traces of greenish fluorescence in the cytoplasm of larger more angular cells, with larger nuclei than the cells in the red pulp. (Such cells have a grayish autofluorescence in unstained material, and this makes any faint greenish tinge brighter than would a similar amount of green fluorescence in cells with fainter autofluorescence.)

In one of these four spleens the middle third of some of the follicles showed faint but definite fluorescence not present in the control slide (Fig. 8).

Liver.—There was faint green fluorescence of the plasma in some of the larger blood vessels, but not in the sinusoids. Here and there in the connective tissue in the portal areas there were groups of two to five cells which gave a bright reaction for antibody (Fig. 4). They had abundant cytoplasm and usually eccentric nuclei. The total number of cells in a section (0.5 to 1 sq.cm.) was about ten. Occasional polymorphonuclear and Kupffer cells were stained non-specifically (Fig. 10).

Popliteal Lymph Node.—There were scattered bright green-yellow cells lying singly and in small groups throughout the medullary portions of the node (Fig. 6). These cells were often angular in outline, extending between neighboring cells. Sometimes there was a bright cell with fainter satellites. There was a rare very bright cell of irregular shape with a bright plasma membrane, a bright nuclear membrane, bright granules in its cytoplasm, and bright

TABLE I*
Antibody Levels of Chronically Immune Rabbits at Time of Autopsy

| Rabbit No. | Time after single intravenous booster | Antibody nitrogen |
|------------|---------------------------------------|----------------------|
| | <i>days</i> | <i>μg./ml. serum</i> |
| 7-22 | None | <30 |
| 7-24 | 2 | <30 |
| 7-25 | 4 | 112 |
| 7-28 | 6 | <30 |
| 7-35 | 13 | 68 |

* We are grateful to Mr. Philip Isenberg for carrying out these determinations.

rod-like structures in the nucleus. There were also seen in a section from one node seven spider-like aggregations of brilliant staining containing four to six cells (Fig. 7).

Lung.—The blood was faintly fluorescent in some of the larger vessels. An occasional cell, which had the size and outlines of a macrophage, was stained, likewise in the control (non-specific staining). Otherwise there was antibody found only in one section which showed a few bright cells in a small lymph node.

Kidney, heart, and muscle were negative for antibody. The renal peripelvic fat in our animals contained no plasma cells and no antibody-containing cells.

Bone Marrow.—Because of extensive non-specific staining, observation of the bone marrow was not very fruitful. In one section, there were brightly stained cells apparently not present in the control slides.

The second series of rabbits received egg albumin as a single booster injection intravenously after a 6 week rest period, except one, which did not receive this last injection, and served as a control. The others were sacrificed on the 2nd, 4th, 6th, and 13th day following the intravenous injection. The antibody levels are recorded in Table I.

In the animal examined after a 6 week rest (No. 7-22), the spleen showed extensive non-specific staining. A few persisting antibody-containing cells could not be excluded. In a section of the left popliteal lymph node, there were a few cells with a brightly fluorescent rim of cytoplasm, and rather large nuclei, younger than mature plasma cells. And in a section of an

iliac lymph node there was "one old, distorted cell, probably a plasma cell." No other organs were examined from this animal.

In the *spleen* of the animal (7-24) sacrificed on the 2nd day after the intravenous booster injection there were isolated, fairly bright cells with a thin rim of cytoplasm and a large round nucleus, and usually small, scattered fluorescent areas in the nucleus. In a popliteal lymph node there were single large cells with large nuclei and a thin rim of brightly stained cytoplasm, usually with a network of green fluorescence in the nuclei. These cells were located in the medullary areas. The follicles were free of antibody-containing cells. In an axillary lymph node there were hundreds of single cells scattered throughout the medullary portions of the node, but not in the follicles. Some of these were large stellate cells with very faintly stained cytoplasm which was rather abundant in amount and extended in process-like formations between adjacent cells. Other slightly brighter cells were without processes and a thin rim of cytoplasm. There were a few smaller, very bright cells of the size and shape of mature plasma cells. The kidney, liver, lung, heart, and ileum were uninformative. The bone marrow was very bright with "non-specific" staining, and no increase could be detected in the slide stained for antibody.

On the 4th day after stimulation (No. 7-25), the spleen showed extensive non-specific staining: groups of cells or objects, brightly fluorescent, with irregular outlines and with small irregular non-fluorescent objects imbedded in them. These were probably masses of disintegrating polymorphonuclear cells with nuclear fragments. In addition to the above, there were small groups of cells with more cytoplasm and smaller nuclei than those described in the 2 day animal which were brightly fluorescent. In the popliteal lymph node there were large groups of cells containing more than 20 cells in cross-section, scattered throughout the lymph node around but not in the follicles, and to a lesser extent throughout the medullary areas, which had brightly fluorescent cytoplasm. These cells were smaller and brighter than those seen at 2 days.

The livers of these animals showed no evidence of antibody.

In the section of the ileum there were numerous, brightly stained, small cells, lying singly and in groups in the submucosa, and extending up into stroma of the villi (Fig. 5). There was faint staining of the connective tissue under the basement membrane, especially in the adventitia of vessels. The whole was in marked contrast to the 2 day ileum mentioned above. The lung contained a few cells of the configuration of immature plasma cells. The liver, kidney, and heart showed evidence of antibody in the circulating plasma, but were otherwise unremarkable.

The 6 day animal (No. 7-28) showed very extensive non-specific staining in the spleen and scattered non-specifically stained polymorphonuclear leucocytes scattered throughout the medulla. In the lymph node there was a rare brightly stained cell not present in the control slide. The liver showed frequent polymorphonuclear leucocytes. It was predicted after this histological examination that this animal would have little antibody in his serum.

The 13 day animal (No. 7-35) was similar.

Comparison with Giemsa-stained sections.—

In rabbit 6-39, serial frozen sections of the spleen were cut, and alternate sections stained for antibody (anti-human gamma globulin), or stained with Giemsa after fixation of the section for 20 minutes with Bouin's fluid. One of us counted the antibody-containing cells in 80 consecutive fields (0.0025 sq. mm. per field). Another counted the members of the plasma-cell series in the adjacent section. Neither, of course, knew the results of the other's count until both had finished. The criteria for identification of the plasma cell series for this purpose were as follows: deeply basophilic cytoplasm, with or without a central apparatus, and small, hyperchromatic nuclei, or a few with large, less hyperchromatic nuclei, and proportionately

less cytoplasm. The totals were as follows: antibody-containing cells 3,193; cells fulfilling the criteria stated above: 3,181. A group of these cells is shown in Fig. 3. These are regarded by us as immature plasma cells. This close agreement is no doubt due to the fact that the normal rabbit spleen contains few plasma cells (32); a similar experiment with lymph node would probably fail.

Cells with the same appearance were found in the periportal connective tissue of the liver in those areas where antibody-containing cells were demonstrated, and groups of immature and mature plasma cells were also found in the lamina propria and submucosa of the ileum, a place where plasma cells are normally present in appreciable numbers.

DISCUSSION

The method employed for the histological demonstration of antibody is clearly specific, despite the confusion caused at times by the occurrence of non-specific reactions. It depends on the use of two layers, the antigen fixed to the section *in vitro* serving as a bridge between the antibody sought in the tissue and the labelled antibody employed as a histochemical reagent. It is evident that to serve successfully this antigen must be fixed in space and not be free in solution, and there is evidence (to be described elsewhere) from a diphtheria toxoid-labelled antitoxin system, in which the antitoxin is non-precipitating, that this must be the case, since when the toxoid is not fixed in space, no staining of the tissue section occurs.

There is unfortunately no information as to the amounts of antibody detected by such manipulations, although it is evidently high in concentration and very small in absolute amount. In these animals, for example, there was no indication of any antibody except in the cells which had presumably formed it and in which it was present in high concentration; other cells, into which it may have diffused or by which it was probably engulfed, such as macrophages (33), gave no indication of any specific staining. An exception to this statement will be presented in another paper (34), in which antibody titers were much higher than in these animals.

The evidence is unequivocal that the islands of cells which appear in the spleen and in other organs in hyperimmune animals, and which all workers who have examined them have identified as plasma cells, do in fact contain high concentrations of antibody. Earlier work has already established a clear correlation between the presence of these cells and active *in vitro* synthesis (26-29). The demonstration that they individually contain antibody confirms these observations. Additional reasons for concluding that they contain it because they have been engaged in synthesizing it rather than storing it will be described and discussed in an accompanying paper (31).

The absence of antibody in detectable concentrations in hepatic cells or Kupffer cells is consistent with the finding by Miller and Bale (35) that the perfused rat liver fails to incorporate C¹⁴-labelled lysine into γ -globulin, and by Thorbecke and Keuning (29) that there is no antibody production *in vitro*

by the liver of rabbits which had received several injections of bacillary antigens. The observation by Ranney and London (36) of small but definite incorporation of C¹⁴-labelled glycine into antibody by the liver of hyperimmune rabbits is explained by the finding of Bjørneboe and Gormsen (24) of groups of plasma cells in the portal connective tissue, and by the observation reported here that such cells in this location contain antibody.

SUMMARY

A method for the specific histochemical demonstration of antibody in cells and parts of cells is described. It consists of carrying out a two stage immunological reaction on frozen sections of tissues: (a) allowing reaction between antibody in the tissue and dilute antigen applied *in vitro*, and (b) the detection of those areas where this antigen has been specifically absorbed by means of a precipitin reaction carried out with fluorescein-labelled antibody. Examination under the fluorescence microscope reveals the yellow-green fluorescence of fluorescein over those areas where a precipitate has formed.

A study of the hyperimmune rabbit on the first few days after the last of a series of intravenous antigen injections reveals that antibody against human γ -globulin or ovalbumin is present in groups of plasma cells in the red pulp of the spleen, the medullary areas of lymph nodes, the submucosa of the ileum, and the portal connective tissue of the liver. Because of extensive non-specific reactions, the bone marrow could not be examined. Small amounts of antibody were occasionally visible in cells in the lymphoid follicles of the spleen and lymph nodes, so that a minor contribution by lymphocytes to antibody synthesis cannot be excluded.

BIBLIOGRAPHY

1. Coons, A. H., Leduc, E. H., and Connolly, J. M., *Fed. Proc.*, 1953, **12**, 439.
2. Heidelberger, M., Kendall, F. E., and Soo Hoo, C. M., *J. Exp. Med.*, 1933, **58**, 137.
3. Marrack, J., *Nature*, 1934, **133**, 292.
4. Coons, A. H., Creech, H. J., and Jones, R. N., *Proc. Soc. Exp. Biol. and Med.*, 1941, **47**, 200.
5. Coons, A. H., Creech, H. J., Jones, R. N., and Berliner, E., *J. Immunol.*, 1942, **45**, 159.
6. Coons, A. H., and Kaplan, M. H., *J. Exp. Med.*, 1950, **91**, 1.
7. Reiss, E., Mertens, E., and Ehrlich, W. E., *Proc. Soc. Exp. Biol. and Med.*, 1950, **74**, 732.
8. Hayes, S. P., Dougherty, T. F., and Gebhardt, L. P., *Proc. Soc. Exp. Biol. and Med.*, 1951, **76**, 460.
9. Moeschlin, S., and Demiral, B., *Klin. Woch.*, 1952, **30**, 827.
10. Moeschlin, S., Pelaez, J. R., and Hugentobler, F., *Schweiz. med. Woch.*, 1951, **81**, 1247.
11. Heidelberger, M., and Kendall, F. E., *J. Exp. Med.*, 1935, **62**, 697.

12. Kabat, E. A., and Mayer, M. M., *Experimental Immunochemistry*, Springfield, Illinois, C. C. Thomas, 1948.
13. Koch, F. C., and McMeekin, T. L., *J. Am. Chem. Soc.*, 1924, **46**, 2066.
14. Linderstrøm-Lang, K., and Mogensen, K. R., *Compt.-rend. Trav. Lab. Carlsberg, Sér. chim.* 1938, **23**, No. 4, 27.
15. Coons, A. H., Leduc, E. H., and Kaplan, M. H., *J. Exp. Med.*, 1951, **93**, 173.
16. Marshall, J. M., *J. Exp. Med.*, 1951, **94**, 21.
17. Coffin, D. L., Coons, A. H., and Cabasso, V. J., *J. Exp. Med.*, 1953, **98**, 13.
18. White, R. G., personal communication.
19. Sheldon, W. H., *Proc. Soc. Exp. Biol. and Med.*, 1953, **84**, 165.
20. Brachet, J., *Quart. J. Micr. Sc.*, 1953, **94**, 1.
21. Pfeiffer, R., and Marx, Z. *Hyg.*, 1898, **27**, 272.
22. McMaster, P. D., in *The Nature and Significance of the Antibody Response*, (A. M. Pappenheimer, Jr., editor), New York, Columbia University Press, 1953, 227.
23. Bing, J., and Plum, P., *Acta Med. Scand.*, 1937, **92**, 415.
24. Bjørneboe, M., and Gormsen, H., *Acta Path. et Microbiol. Scand.*, 1943, **20**, 649.
25. Bjørneboe, M., *Z. Immunitätsforsch.*, 1941, **99**, 245.
26. Fagraeus, A., *Acta Med. Scand.*, 1948, suppl. 204.
27. Fagraeus, A., *J. Immunol.*, 1948, **58**, 1.
28. Keuning, F. J., and van der Slikke, L. B., *J. Clin. and Lab. Med.*, 1950, **36**, 167.
29. Thorbecke, G. J., and Keuning, F. J., *J. Immunol.*, 1953, **70**, 129.
30. Bjørneboe, M., Gormsen, H., and Lindquist, F., *J. Immunol.*, 1947, **55**, 121.
31. Leduc, E. H., Coons, A. H., and Connolly, J. M., *J. Exp. Med.*, 1955, **102**, 61.
32. Marshall, A. H. E., and White, R. G., *Brit. J. Exp. Path.*, 1950, **31**, 157.
33. Girard, K. F., and Murray, E. G. D., *Canad. J. Biochem. and Physiol.*, 1954, **32**, 14.
34. White, R. G., Coons, A. H., and Connolly, J. M., *J. Exp. Med.*, 1955, **102**, 83.
35. Miller, L. L., and Bale, W. F., *J. Exp. Med.*, 1954, **99**, 125.
36. Ranney, H. M., and London, I. M., *Fed. Proc.*, 1951, **10**, 562.

EXPLANATION OF PLATES

All photomicrographs of the frozen tissue sections were taken under the fluorescence microscope. The lightest areas are those emitting the yellow-green light of fluorescein and indicate sites of antibody present in the tissue sections; in a few instances they represent whitish or reddish light from naturally occurring fluorescent aggregates normally present in rabbit tissue. The darker areas indicate the less intense blue-gray autofluorescence of other tissue elements.

PLATE 9

FIG. 1. Rabbit 6-39. Spleen. Stained for anti-human γ -globulin. Islands of cells containing antibody in the red pulp. The peripheries of two lymphoid follicles are visible at the right upper and lower corners. $\times 140$.

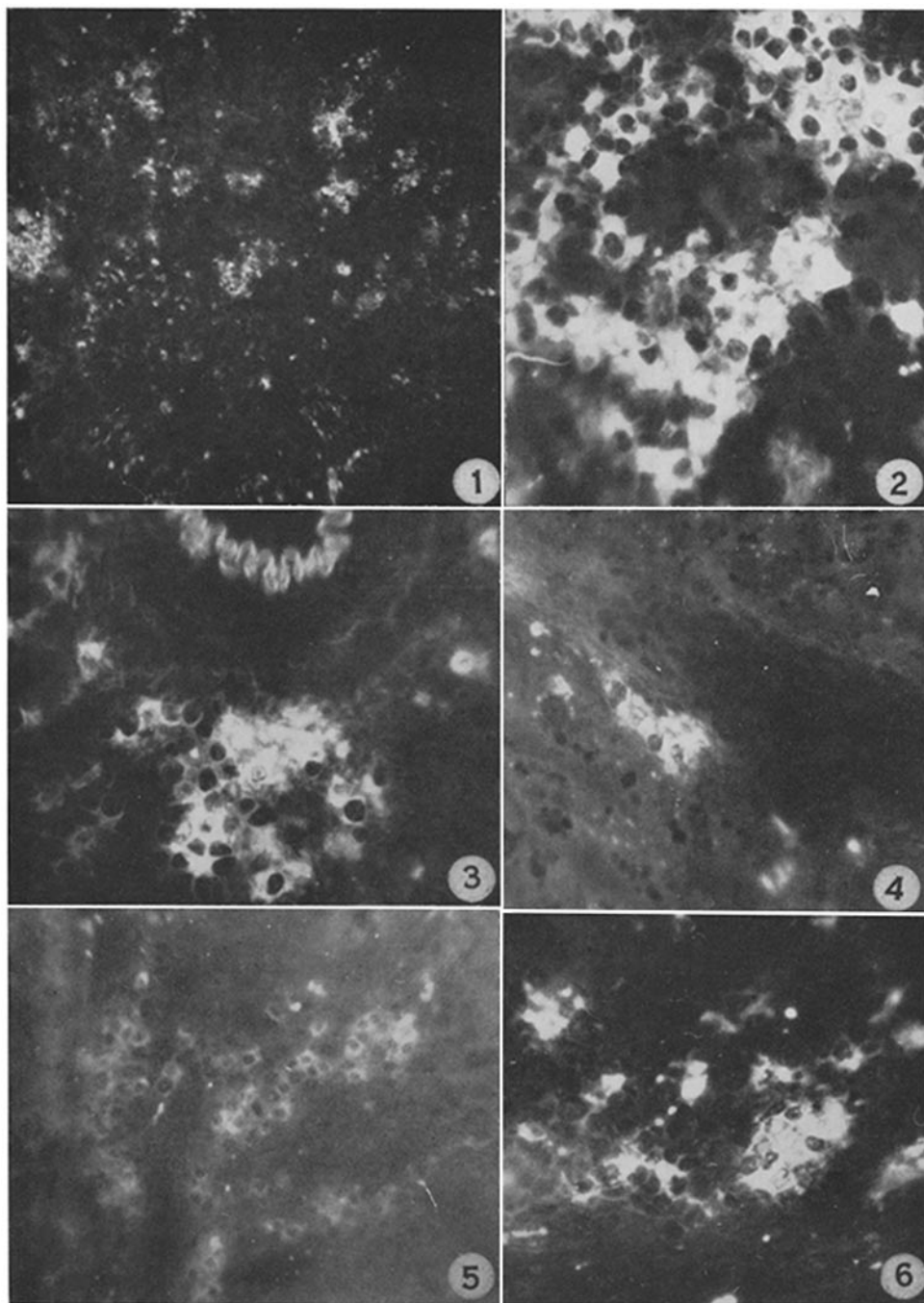
FIG. 2. Rabbit 6-41. Spleen. Stained for anti-human γ -globulin. Higher power of similar islands of cells in the red pulp. $\times 560$.

FIG. 3. Rabbit 6-39. Spleen. Stained for anti-human γ -globulin. A similar clump of cells in the adventitia of an arteriole. The antibody is for the most part in the cytoplasm, the nuclei of the cells standing out as negative shadows. The serrated white object at the top of the figure is the internal elastic membrane, which has a brilliant blue autofluorescence, and does not contain antibody. $\times 560$.

FIG. 4. Rabbit 6-41. Liver. Stained for anti-human γ -globulin. A small clump of antibody-containing cells is visible in the periportal connective tissue. The small scattered white dots are reddish pigment, not antibody.

FIG. 5. Rabbit 7-25. Ileum. 4th day after the last of a series of injections of ovalbumin. Stained for anti-ovalbumin. The basement membrane runs vertically at the left of the figure, the mucosa is at the right. Clumps of antibody-containing cells are visible along the basement membrane and in the stroma of the villi. $\times 280$.

FIG. 6. Rabbit 6-41. Popliteal lymph node. Stained for anti-human γ -globulin. Similar clumps of cells lying near the capsule, but not in a lymphoid follicle. The amorphous large white area near the center, and the several small white spots are red-fluorescing pigment. $\times 560$.



(Coons *et al.*: Studies on antibody production. I)

PLATE 10

FIG. 7. Two large aggregates of antibody in the same lymph node as Fig. 6, involving several cells. An unusual appearance. $\times 560$.

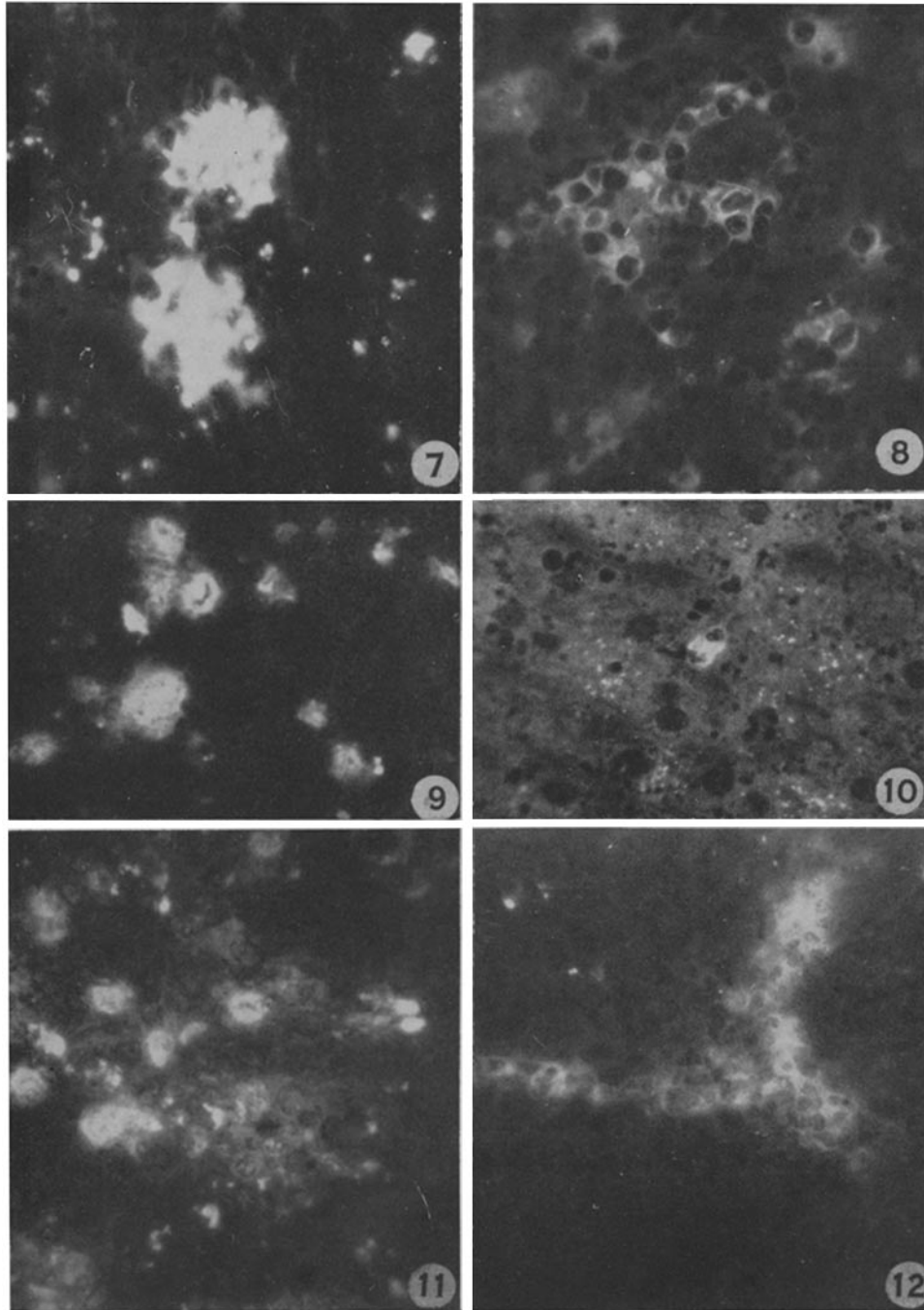
FIG. 8. Rabbit 6-39. Spleen. Stained for anti-human γ -globulin. A few cells in a lymphoid follicle. $\times 560$.

FIG. 9. Rabbit 6-39. Spleen (producing anti-human γ -globulin). Stained for anti-ovalbumin. Non-specific staining, illustrating the bright masses of cytoplasm containing fragments of nuclear material described in the text. $\times 560$.

FIG. 10. Rabbit liver. Non-specific staining, probably of a small group of polymorphonuclear cells. The scattered white dots are red pigment. $\times 560$.

FIG. 11. Rabbit 6-39. Spleen. Stained for anti-human γ -globulin, and showing a confusing picture of a probable mixture of specific and non-specific staining. Compare with Fig. 9. $\times 560$.

FIG. 12. Rabbit 4-77. Popliteal lymph node. Non-specific staining, demonstrated by staining for antigen, and by failure of the inhibition test. $\times 560$.



(Coons *et al.*: Studies on antibody production. I)