

## ACUTE HEPATITIS ASSOCIATED WITH MOUSE LEUKEMIA

### V. THE NEUROTROPIC PROPERTIES OF THE CAUSAL VIRUS

By JOHN B. NELSON, PH.D.

(From The Rockefeller Institute for Medical Research)

PLATE 67

(Received for publication, June 27, 1955)

The causal virus of hepatitis in mice of the Princeton strain was originally isolated in 1952 (1). Since then it has been maintained for experimental purposes by the intraperitoneal injection of liver suspensions in weanling mice. During the long series of passages, which now number 130, the behavior of the virus in the abdominal organs was well explored. In this laboratory, however, little attention had been paid to its activity in the central nervous system. As a supplement to the earlier observations, the neurotropic properties of this virus and of a closely related one from Balb C mice were studied in detail. In the present discussion of this work the abbreviation MHV (Pr) will be used for the causal virus of hepatitis in Princeton mice and MHV (C) for that in Balb C.

In the 1952 report (2) a few observations were presented on the activity of MHV (Pr) in cranially injected Princeton mice. The virus passed from the brain to the liver and ultimately resulted in the usual hepatic reaction. Brain sections showed no apparent pathology.

Gledhill, Dick, and Niven (3), in 1953, described a fatal nervous syndrome with their N type of MHV. Injected mice gave little evidence of liver involvement, except in the presence of *Eperythrozoon coccoides*. They also found that the JHM virus of Cheever, Daniels, Pappenheimer, and Bailey produced a diffuse necrosis of the liver on combination with the eperythrozoon. Intraperitoneal injection of JHM reduced its neurotropism but increased its hepatotropism. JHM and MHV were seemingly related by the possession of common antigens, indicated by neutralization tests.

JHM was isolated by Cheever *et al.* (4) in 1949. It produced disseminated encephalomyelitis with demyelination in mice and also focal necrosis of the liver. Paralysis of the hind legs was a frequent manifestation of the disease.

In 1954 Morris and Aulisio (5) isolated a murine virus, termed H747. On cranial injection in suckling mice it produced a fatal disseminated encephalitis. Neutralization tests indicated a close relationship with MHV of Gledhill *et al.* and with JHM. Morris and Aulisio recognize a group of related viruses causing hepatitis or central nervous system disease and refer to it as the hepatoencephalitis group.

Braunsteiner and Friend (6), in 1954, recovered a new type of MHV from F1 hybrids of C58 × Bagg albino crosses carrying line 1 leukemia. The hepatic disease was brought out during the administration of urethane and methylformamide. F1 hybrid weanlings, pure Bagg albinos, and Princeton mice were equally susceptible to the acute disease. A personal communication from Dr. Charlotte Friend indicated that cranial injection of the virus was followed by signs of nervous disorder.

*Carriage of MHV (Pr) to the Brain on Intraperitoneal Injection in  
Princeton and Swiss Mice*

In the first experiment of the present series blood and brain suspensions from Princeton and Swiss weanlings were tested for the presence of MHV (Pr) at various intervals after intraperitoneal injection.

The 2 strains of mice were from colonies maintained at The Rockefeller Institute. Weanlings, weighing 10 to 13 gm., were injected intraperitoneally with 0.1 ml. of a recently prepared 10 per cent liver suspension in saline. This was the standard inoculum and was used throughout in the testing of livers. The virus suspensions employed in this experiment and the following ones were from passages 120 to 130. Two injected mice were killed with ether at daily intervals and autopsied. In the Princeton series only 1 mouse survived through the 4th day. In the Swiss series no deaths occurred and it was continued through the 7th day. Approximately 0.25 ml. of blood was drawn from the heart and added to 0.5 ml. of saline containing 0.1 ml. of a 27 mg. per cent solution of heparin. The blood suspensions from each pair of mice were pooled. The livers were removed to a Petri dish and examined with a dissecting microscope. Each pair of brains, on aseptic removal, was minced with scissors and ground with saline in a TenBroeck tissue grinder. The final tissue concentration was about 10 per cent.

Since Princeton weanlings are nearly 100 per cent susceptible to MHV (Pr) on intraperitoneal injection, they were used throughout as the ultimate test animal. The various suspensions were injected in 0.1 ml. amounts in each of 5 mice. All mice that survived through the 7th day were killed and autopsied.

The results of this experiment are summarized in Table I. Five of the 12 Princeton mice died. By the 2nd day, the survivors showed signs of illness. The livers of the mice killed on the 1st day were normal. At this time sufficient virus was present in the blood to kill 4 out of 5 test mice. It was also demonstrable in the brain, but in reduced amount as only 1 of the test mice died. The livers of the mice killed on the 2nd through the 4th day showed characteristic necrotic lesions. MHV (Pr) was regularly recovered from the blood and brains of these mice. The activity of the several suspensions was essentially the same.

All of the 14 Swiss mice survived and were consistently free from signs of illness. Five mice killed on the 3rd through the 5th day showed a slight liver reaction with scattered foci and petechial hemorrhages. MHV (Pr) was demonstrable in the blood on the 1st day (in low titer) and persisted there through the 5th day. The virus was recovered from the brain only on the 4th and 5th days.

*Survival of MHV (Pr) in the Brain and Its Carriage to the Liver  
in Cranially Injected Mice*

Brain suspensions from Princeton and Swiss weanlings injected intracerebrally were tested at intervals to determine the survival time of MHV (Pr). Supplementary tests were made of the blood and liver to indicate its outward carriage from the brain.

In these and the following intracerebral injections recently weaned mice, commonly 10 gm. in weight, were used. They were anesthetized with ether and injected into the brain with 0.02 to 0.03 ml. of a liver suspension. An attempt was made to kill 2 mice of each strain at daily intervals, but none of the Princeton mice were alive after the 3rd day. All the Swiss mice survived and this series was continued through the 7th day.

Immediately after the mice were killed blood was drawn from the heart to heparin and pooled from each pair. Ten per cent suspensions were prepared in saline from the paired livers and brains. All the suspensions were tested for activity by intraperitoneal injection in 5 Princeton mice. The survivors were killed after 7 days.

The Princeton mice killed on the 1st day after cranial injection were normal in appearance and their livers were unaffected. The mice killed on the 2nd day were also normal outwardly but focal lesions were present in their livers.

TABLE I  
*Detection of MHV (Pr) in the Blood and the Brains of Princeton and Swiss Mice after Intra-peritoneal Injection*

Strain of mouse	Time to autopsy <i>days</i>	No. of deaths in each group of 5 test mice	
		Injected with blood	Injected with brain
Princeton	1	4	1
	2	4	5
	3	5	5
	4	5	5
Swiss	1	1	0
	2	5	0
	3	4	0
	4	4	2
	5	5	5
	6	0	0
	7	0	0

Those examined in the 3rd day showed the usual signs of illness, but no indication of nervous disorder. In these mice and the ones that died the livers were diffusely necrotic. MHV (Pr) was demonstrable in the brain, blood, and liver from each pair of Princeton weanlings killed on the 1st through the 3rd day. Forty-four of the 45 test mice died and at autopsy showed typical signs of hepatitis.

All the Swiss mice were normal in appearance when killed. No deaths occurred in this series. At autopsy the livers were unaffected. Virus was demonstrable in the paired brain suspensions prepared on the 1st through the 4th day after cranial injection. Nineteen of the 20 Princeton mice used in testing these suspensions died. The brain suspensions prepared on the 5th through the 7th day were innocuous. The blood and liver preparations were tested only through the 4th day and were uniformly inactive.

*Intracerebral Passage of MHV (Pr) in Princeton Mice*

The results of the preceding experiment were indicative of survival but they failed to offer proof that MHV (Pr) actually multiplied in the brains of cranially injected mice. Serial passage by intracerebral injection was then begun in an attempt to obtain this evidence.

In the passage series with Princeton mice the initial inoculum was a freshly prepared liver suspension of MHV (Pr) and 5 mice were employed. Thereafter, brain suspensions were used and 6 or 7 mice injected.

In most instances 2 mice from each passage were killed on the 3rd or 4th day. At autopsy the livers were examined and the brains removed to a Petri dish. At this time a small amount of tissue was aspirated from each brain with a capillary pipette and a Gram-stained film prepared for direct microscopic examination. These films served as a guide to the presence of bacterial contaminants and also leukocytes, in the event of abscess formation. One brain of each pair was placed in Zenker's solution for sectioning and the other prepared for the next passage. In the early tests the suspensions were cultured on plain agar. With the later finding that pleuropneumonia-like organisms (PPLO) were sometimes present in the brain 20 per cent horse serum-heart infusion agar was substituted. These plates were sealed with scotch tape and incubated at 37°C. for 7 days.

Gram-positive micrococci and Gram-negative bacilli were occasionally observed in films. The addition of 0.1 ml. of a penicillin solution (1000 units) to 0.9 ml. of suspension generally inhibited subsequent multiplication of the bacteria. The suspensions were usually stored in the refrigerator for several hours before use. On injection the supernatant fluid was commonly employed.

MHV (Pr) was established in the brains of Princeton mice and successfully maintained for 15 cranial passages. The series was then discontinued. Many of the 97 mice, used in the combined passages, showed the usual signs of illness as roughness of the fur, loss in weight, and a tendency to rest in a hunched position. Yellowing of the hair in the rectal area was the only outward indication of jaundice. Signs suggestive of cerebral involvement, as trembling and late convulsions, were uncommon and frank paralysis was never observed.

The livers of the 27 mice that were killed showed characteristic focal lesions. Seventy mice died between the 2nd and the 7th day after injection. As indicated in Table II the period of survival was somewhat prolonged in comparison with mice injected intraperitoneally. At autopsy, which was done as routine unless postmortem changes were far advanced, the livers showed either diffuse coalescing necrosis or innumerable focal lesions. In many mice that died after intracerebral injection the hind legs were extended backwards and rigid. This condition occurs as commonly in mice that die after intraperitoneal injection and also from other causes, and is not exclusively pathognomonic of cerebral disorder.

*Intracerebral Passage of MHV (Pr) in Swiss Mice*

An attempt was also made to maintain MHV (Pr) in Swiss mice by cranial passage. This series provided evidence for the multiplication of the virus in the brain and also furnished information on the effect of passage on its patho-

genicity. In an earlier report (7) it was noted that the activity of MHV (Pr) in Swiss weanlings was markedly enhanced by intraperitoneal transfer.

The methods in this experiment were essentially the same as those in the preceding one. Passages were made at intervals of 2 to 3 days but more commonly on the 3rd day. The activity of each brain suspension was tested by intraperitoneal injection in 5 Princeton mice. All animals that were alive on the 7th day were killed and autopsied.

Four separate passage series were made with MHV (Pr) in Swiss mice. The first three attempts to maintain the virus in the brain were largely unsuccessful and provided little or no evidence of multiplication. In the first series the initial inoculum was a brain suspension from infected Princeton mice. The virus was not demonstrable in the brain after the 2nd passage. The three subsequent series were begun with liver suspensions. In two of them MHV (Pr) was present in the brain only on initial injection. None of the cranially injected Swiss mice showed outward signs of illness and when killed their livers were uniformly normal.

TABLE II  
*Mortality Incidence by Days in Princeton Mice on Intracerebral and Intraperitoneal Injection with MHV (Pr)*

No. of mice	Route of injection	No. of deaths per day						
		1	2	3	4	5	6	7
70	Intracerebral	0	1	15	42	8	3	1
70	Intraperitoneal	0	35	34	1	0	0	0

On the 4th attempt MHV (Pr) was established in the brain and maintained for ten successive cranial transfers. The continued cerebral multiplication of the virus was attended by a noticeable but limited increase in its pathogenicity.

Sixty Swiss mice were used in this experiment. Two deaths occurred but neither could be attributed to hepatitis. There were no outward signs of illness in any of the cranially injected mice. At autopsy, however, 23 of them showed a few discrete lesions in the liver. The progressive type of reaction, characteristic of hepatitis in Princeton mice, was never observed. Thirty-eight of the 50 Princeton mice, used in testing the activity of the brain suspensions, died on the 3rd to the 5th day. Nine of the survivors showed liver lesions, when killed, and 3 were normal. Intraperitoneal injection of the brain suspension from the 10th passage resulted in the death of 3 out of 5 Swiss mice. On injection with the liver suspension from the same passage 4 out of 5 mice died. Only 1 of the 10 animals failed to show liver lesions at autopsy.

*Cranial Passage of MHV (Pr) together with Eperythrozoon coccoides in Swiss Mice*

This experiment was based on the synergistic reaction of MHV (VS)<sup>1</sup> and *E. coccoides* reported by Niven, Gledhill, Dick, and Andrewes (8), in 1952.

<sup>1</sup> This virus was isolated by Gledhill and Andrewes (10), in 1951, from Webster's BSVS mice injected with suspensions from mice of the Parkes strain.

They found that the activity of a weakly virulent hepatitis virus was markedly enhanced by the eperythrozoon. Concurrently, the number of parasites in the blood was greatly increased by the presence of the virus. A similar reaction was later observed in this laboratory with MHV (Pr) and a local strain of *E. coccoides* injected intraperitoneally in Swiss weanlings (9). The present series was carried out to determine the effect of dual cranial injection on the activity of MHV (Pr) in these mice.

The strain of *E. coccoides*, isolated in 1952, has been maintained to date by intraperitoneal passage in unsplenectomized Princeton mice. This series was carried out in order to preserve the organism, which has not been grown, and as a guide to the natural occurrence of MHV (Pr) in non-leukemic Princeton mice. Passages were made at intervals of 2 to 3 weeks by the injection of 0.1 ml. of pooled heparinized blood drawn from the heart of the 5 preceding mice. Blood films were made from the tail on the 3rd day and stained with Giemsa. Eperythrozoa, chiefly ring forms, were regularly found on microscopic examination. At autopsy the spleens of the injected mice were commonly enlarged and dark in color. This finding was the only apparent manifestation of infection. *E. coccoides* has now been passaged 60 times in 300 Princeton mice with no indication of mouse hepatitis.

In a preliminary experiment it was found that *E. coccoides* could be established in unsplenectomized Swiss mice by the intracerebral injection of parasitized blood. The appearance of the organisms in the circulating blood was commonly delayed until the 4th or 5th day. The initial combined passage was made with a mixture of blood containing *E. coccoides* and the supernatant of a freshly prepared liver suspension of MHV (Pr.) Brain suspensions alone were used in the subsequent cranial passages. These suspensions were also tested in either Princeton or Swiss mice or in both by intraperitoneal injection. In the early passages blood films were made from the tail on the 3rd to the 5th day but in later tests only on the 7th day.

The results of this experiment, which are summarized in Table III, were quite unexpected. The mice of the 1st combined passage showed eperythrozoa in blood films but no signs of illness. At autopsy their livers were normal. The brain suspension prepared for the 2nd passage was inactive on intraperitoneal injection in Princeton mice. It was presumed that MHV (Pr) had failed to survive in the brain. A 2nd passage was made, however, and 1 mouse of this group showed focal lesions in the liver in autopsy on the 7th day. The subsequent passages indicated the transfer of a virus with particular affinity for the liver but different in behavior from MHV (Pr) with which the series was started. *E. coccoides* was regularly present in blood films though its appearance was usually delayed and there was no consistent numerical increase.

Unlike MHV (Pr) the second virus showed little or no activity in Princeton weanlings on intraperitoneal injection. In Swiss mice, however, it was more active than MHV (Pr) whether injected into the peritoneal cavity or the brain. Seven of the 40 cranially injected Swiss mice died on the 4th to the 7th day. All the survivors gained weight normally and showed no outward signs of illness. At autopsy, whether death occurred naturally or by design, the liver was the only organ involved. Twenty-two of the mice showed lesions which

varied from focal to diffuse necrosis. The cranial series was discontinued after the 7th passage but the virus is being maintained by intraperitoneal injection for further study.

*Behavior of MHV (C) in Cranially Injected Mice*

In September, 1953, MHV (C) was isolated in this laboratory from Balb C mice. This virus resembled MHV (Pr) in its special affinity for the liver and

TABLE III  
*Results of Combined Cranial Injection with E. coccoides and MHV (Pr) in Swiss Mice*

No. of passage	Source of inoculum	No. of mice injected	No. of days to autopsy	No. of mice with liver lesions	No. of the 5 test mice with liver lesions	
					Princeton	Swiss
1	Liver and blood	6	1/4* 5/10	0	0	
2	Brain	6	6/7	1	0	
3	"	5	2/6 3/7	5	0	
4	"	5	2/7 (d)‡ 3/7	4		3
5	"	6	1/7 (d) 5/7	3		3
6	"	6	2/7 4/9	5		5
7	"	6	2/4 (d) 2/6 (d) 2/7	4	2	5
Totals.....		40	7 (d)	22	2 of 20	16 of 20

\* The number of mice is given in the numerator and the days to death in the denominator.

‡ Natural deaths are indicated by (d).

in its initial association with lymphocytic leukemia. The two viruses showed well marked host specificity, however, and could not be exchanged with equal activity in the two mouse strains. The neurotropic properties of MHV (C) were studied in cranially injected Balb C, Princeton, and Swiss mice.

Balb C weanlings from The Rockefeller Institute and from the Roscoe B. Jackson Memorial Laboratory in Bar Harbor, Maine, were used in the early experiments. F1 hybrids of Balb C

females  $\times$  A males, obtained from the second colony, were later employed. Since the behavior of MHV (C) was essentially the same in the three lots of mice, the source will be disregarded in the following experiments.

The leukemic Balb C mice, with which the work was begun, were obtained through the courtesy of Dr. Stanfield Rogers of the Duke University School of Medicine, Durham. The leukemia was characterized by marked enlargement of the spleen and mesenteric lymph node. The other regional lymph nodes were generally not involved. In females, there was an extensive periovarian reaction. The disease was readily reproduced in its new environment by the intraperitoneal injection of 0.1 ml. of a spleen suspension. The injected mice showed typical leukemic lesions when killed on about the 10th day. In the 4th passage, all the 5 injected mice died on the 4th to the 7th day and at autopsy numerous focal lesions were present in their livers. On subsequent transfer with mixed liver and spleen suspensions, irregular results were obtained through the 9th passage. Some mice showed only hepatitis and others hepatitis together with incipient leukemia. A more uniform outcome began with the 10th passage and continued through the 21st when the series was discontinued. In these mice only hepatic lesions were observed at autopsy. Manifestations of leukemia were lacking and failed to appear even in survivors which were held for 4 weeks.

Twenty-five out of 30 mice used in the last 6 passages died on the 3rd to the 6th day. The hepatic reaction at autopsy and its outward signs closely resembled the reaction produced by MHV (Pr) in Princeton mice. Discoloration of the liver with bile pigments, petechial hemorrhages in the liver, and the presence of blood in the gall bladder were somewhat more conspicuous in mice injected with MHV (C). Princeton weanlings were much more resistant to the virus. They showed no signs of illness and none of them died. Scattered focal lesions and hemorrhages were observed, however, in some of the livers from mice that were killed.

At this time a single filtration experiment was made with MHV (C). The Berkefeld V filtrate of a liver suspension in pH 7.4 bouillon, cleared of tissue debris by low speed centrifugation, killed 5 out of 5 Balb C mice on the 4th to the 7th day.

A liver suspension of MHV (C) stored in a frozen state at  $-20^{\circ}\text{C}$ . for 5 months was tested for activity in November, 1954. The virus was still viable but noticeably reduced in titer. After 3 additional passages, making a total of 25 since it was first isolated, the virus regained its former virulence. Intracerebral injections were then begun in the 3 strains of mice. The methods used were similar to those in the preceding experiments. Normal survivors were held somewhat longer and often were not killed until the 10th to the 14th day.

*Balb C Mice.*—MHV (C) was established in the central nervous system of Balb C mice by cranial injection and maintained there through 4 successive brain passages. Twenty-six of the 30 mice used in this series died and 4 were killed. The daily distribution of natural deaths was as follows: 3rd day, 14; 4th day, 9; 5th and 6th days, 2 each. Many of the injected mice showed generalized signs of illness prior to death. Definite evidence of paralysis, observed locally for the first time in association with mouse hepatitis, was noted in 5 of these mice. During life the hind legs were spread outward to either side and were largely functionless. Blood from the mice of only one passage was tested for virus activity. A pooled suspension, drawn from the hearts of 2 mice on the 3rd day, killed 3 out of 5 Balb C weanlings on intraperitoneal injection.

At autopsy the liver was the only organ of the cranially injected mice that regularly showed macroscopic injury. The characteristic lesion was a small



white area of fecal necrosis which stood out sharply against the red background of normal liver tissue. These foci varied markedly in number and were sometimes accompanied by petechial hemorrhages which resulted in a dappled appearance. A few livers, removed after the 4th day, showed evidence of early cirrhosis. The brains of these mice were consistently normal in the gross and all cultures from them were sterile.

*Princeton Mice.*—MHV (C) was not demonstrable in Princeton weanlings on initial cranial injection. The 10 mice, used in this experiment, gained weight consistently and showed no outward signs of illness. At autopsy on the 10th day their livers were uniformly normal in appearance. Brain passages were not attempted.

*Swiss Mice.*—Five intracerebral passages were made in Swiss weanlings. There was no doubt that the virus multiplied in the brains of these mice and was carried thence to the liver. At autopsy 14 of the 30 animals showed characteristic hepatic involvement. The liver lesions were commonly focal and in some mice, too few in number to account for their sickly appearance. Signs of paralysis were observed in 9 mice on the 6th to the 9th day. The hind legs were either spread outwards or extended backwards in a rigid state. In the latter mice the affected limbs were functionless and dragged on movement. Fourteen mice died on the 5th to the 10th day.

By the 3rd passage it was evident that an additional agent was being transferred with the virus. At this time direct films from the brain showed leukocytes in varying numbers but no bacteria. Through the 4th passage brain cultures had been made only on plain agar, with negative findings. In the 5th passage 20 per cent horse serum-heart infusion agar was substituted and a pure growth of PPLO colonies obtained. The passage series was then discontinued but additional work on the interrelationship of the two agents is in progress.

A second cranial passage series was begun in Swiss mice with a Coors (No. 3) filtrate which contained active virus but was free from PPLO. Six successive transfers were then made with brain suspensions. The virus titers of the filtrate and the first brain suspension were evidently low. The 10 injected mice survived and 4 were normal when killed on the 10th day. The 4 following suspensions regularly produced signs of hepatitis on cranial injection.

Fifteen of the 42 mice used in the combined passages died. At autopsy 38 of them showed liver damage. The lesions were usually diffuse in the mice that died and focal in those that were killed. The brains were regularly normal in the gross. Stained films showed no leukocytes and all cultures were sterile. Twenty-seven mice were killed on the 4th to the 10th day. Fifteen showed signs of paralysis. Rigidity and dragging of the hind legs was the most common manifestation but a rolling tendency was also noted.

### *Histopathology of the Brain*

The microscopic examination of brain sections from Princeton mice injected intracerebrally with MHV (Pr) revealed a slight leptomeningitis but gave little or no indication of encephalitis. In the sections from Balb C and Swiss mice injected with MHV (C) a more extensive meningeal reaction accompanied by well defined encephalitis was observed.

*Princeton Mice Injected with MHV (Pr).*—In these and the following mice, transverse sections were made through three cerebral levels which included portions of the fore-, mid-, and hindbrain. They were stained with eosin-methylene blue for examination.<sup>2</sup>

Small portions of the pia in all three levels of the brain showed a lymphocytic infiltration which was commonly inconspicuous. The blood vessels of the brain proper were not involved and only rarely was there any suggestion of neuronal injury. The multinuclear giant cells described by Gledhill, Dick, and Niven (3) in venous channels were not observed. In the earlier examination of brain sections (1) the meningeal reaction was probably overlooked.

*Balb C and Swiss Mice Injected with MHV (C).*—In these mice the leptomeningitis was more extensive than in Princeton but was also patchy. In restricted areas of the pia there was a marked infiltration of lymphocytes which extended downward into the fissures. The blood vessels were often extended and there was evidence of fluid. The meningeal inflammation, which occurred at all levels, is illustrated in Fig. 1.

Most of the sections showed a cuffing of lymphocytes around some of the cerebral blood vessels, as indicated in Fig. 2. Hemorrhages were sometimes observed but were not characteristic. There was also a profound, though restricted, injury to nerve cells. Foci of cellular damage were most noticeable in semicircular areas around ganglia. The neurons within the ganglia were not affected. Within these focal areas nerve cells were found in all stages of degeneration. Phagocytic cells and lymphocytes were present in considerable numbers and newly formed capillaries were observed. In some sections the ground substance had a thinned-out and ragged appearance and large foamy Gitter cells had invaded the area. This reaction was presumed to be indicative of demyelination. A focus of neuron destruction and replacement is shown in Fig. 3. The encephalitic lesions were observed at all levels but were less conspicuous in the cerebellum. The intensity of the reaction was somewhat greater in Swiss than in Balb C mice.

The only apparent difference in the histopathology of the liver, in comparison with the usual reaction attendant on intraperitoneal injection of either MHV (Pr) or MHV (C), was the prevalence of focal lesions. A section showing discrete areas of liver necrosis is presented in Fig. 4.

Polymorphonuclear leucocytes were not characteristic of the cerebral reaction in either Princeton, Swiss, or Balb C mice. A leukocytic response was observed only in Swiss mice on cranial injection with MHV (C) and PPLO. The brains from those mice were abscessed.

### DISCUSSION

The outstanding biological characteristic of MHV (Pr) is its marked hepatotropism in a susceptible host. By whatever route the virus is introduced in Princeton mice, it ultimately reaches the liver and develops there at the

<sup>2</sup> The assistance of Dr. Raymond C. Allen in examining the brain sections is gratefully acknowledged.

expense of the parenchymal cells. The present findings provide evidence that MHV (Pr) also displays a limited degree of neurotropism. Multiplication of the virus in the brain was clearly demonstrated by cranial passage in Princeton weanlings. There was no indication, however, that it became either less hepatotropic or more neurotropic as the result of continued cerebral residence. Carriage of the virus from the brain to the liver regularly occurred and was attended by the usual hepatic syndrome without paralysis.

The Princeton mouse is known to be refractory to certain viruses that effect the central nervous system of other murine hosts. Sabin (11), in 1954, gave proof that the resistance of 1 to 2 months old mice was genetically controlled and attributable to a dominant autosomal gene that depressed the level of viral multiplication. There was no evidence, however, that this factor influenced the cerebral development of MHV (Pr) in Princeton weanlings.

MHV (Pr) multiplies in the liver of the Swiss mouse on primary intraperitoneal injection but is relatively inactive. As the result of continued passage the virus undergoes some adaptive change and its pathogenicity is significantly increased. Multiplication was also demonstrated in the brains of Swiss mice, though the virus was established there with difficulty. Cerebral growth was irregularly attended by a subacute hepatitis which was manifested only at autopsy. A limited degree of adaptation in the direction of increased pathogenicity occurred on continued cranial passage.

The outcome of the combined cranial series with MHV (Pr) and *E. coccoides* was of particular interest. In the presence of the eperythrozoon the expected increase in viral activity did not occur but instead a virus with distinctly different properties emerged. The source of this virus is conjectural but the view that it represents a mutant of MHV (Pr) selected through the agency of *E. coccoides* is favored.

It is of interest that MHV (Pr), MHV (C), and the hepatitis virus of Braunsteiner and Friend (6) were initially isolated from mice during the passage of leukemia. It may be restated here that all attempts to demonstrate MHV (Pr) in normal, non-leukemic, Princeton mice have met with failure. The negative findings with the 300 weanlings that were infected with *E. coccoides* are of particular significance.

The pathologic activity of MHV (C) in the brains of cranially injected mice was considerably greater than that of MHV (Pr). The maximum response was characterized by leptomeningitis, encephalitis, and paralysis. Swiss mice were somewhat more reactive than Balb C, from which the virus was first isolated. The pleuropneumonia-like organism that appeared during the first cranial series in Swiss mice was probably a chance contaminant acquired from the brain of a supposedly normal animal. It was distinctly different from the murine strains of PPLO which are regularly under observation in this

laboratory. The possibility of cerebral contamination with these organisms might well be considered in the routine cranial injection of mice.

As pointed out by Morris and Aulisio (5) a family of murine viruses with hepatotropic and neurotropic properties is clearly indicated. The variable pathogenicity of these agents is well brought out by the special affinity of MHV (Pr) for the liver and of JHM for the brain. In the allocation of viruses to this group, it should be borne in mind that seemingly unrelated ones, as the virus of lymphocytic choriomeningitis, may possess similar tissue affinities. The current nomenclature is obviously unsatisfactory but it seems preferable to any attempt at a formal classification until these viruses are better known.

#### SUMMARY

Observations on the behavior of MHV (Pr) in the cerebral tissue of Princeton and Swiss weanling mice indicated a limited neurotropism. The virus migrated to the brain on intraperitoneal injection and was established there by cranial passage, though with difficulty in Swiss mice. Intracerebral multiplication was rarely followed by outward signs of nervous disorder. A slight pathologic reaction occurred in the brains of intracerebrally injected Princeton mice, but it was negligible compared with that of the ensuing hepatitis. In Swiss mice, injected intracerebrally with a mixture of MHV (Pr) and *Eperythrozoon coccoides*, a related virus with restricted pathogenicity and host range, possibly a mutant, was isolated from the liver and brain.

MHV (C), an actively hepatotropic virus recovered from leukemic Balb C mice, was much more neurotropic than MHV (Pr). Intracerebral injection of Balb C and Swiss weanling mice was attended by marked leptomenigeal and encephalitic lesions. Paralysis of the extremities occurred in some of the animals. The virus was essentially inactive in Princeton mice. During the intracerebral passage of MHV (C) in Swiss mice a pleuropneumonia-like organism was isolated from the brain. In conjunction with the virus this organism produced a vigorous leukocytic reaction.

#### BIBLIOGRAPHY

1. Nelson, J. B., *J. Exp. Med.*, 1952, **96**, 293.
2. Nelson, J. B., *J. Exp. Med.*, 1952, **96**, 303.
3. Gledhill, A. W., Dick, G. W. A., and Niven, J. S. F., *6th Internaz. Congr. Microbiol.*, Rome, September 6 to 12, 1953, **2**, 46.
4. Cheever, F. S., Daniels, J. B., Pappenheimer, A. M., and Bailey, O. T., *J. Exp. Med.*, 1949, **90**, 181.
5. Morris, J. A., and Aulisio, C. G., *Fed. Proc.*, 1954, **13**, 506.
6. Braunsteiner, H., and Friend, C., *J. Exp. Med.*, 1954, **100**, 665.
7. Nelson, J. B., *J. Exp. Med.*, 1953, **98**, 433.

8. Niven, J. S. F., Gledhill, A. W., Dick, G. W. A., and Andrewes, C. H., *Lancet*, 1952, **2**, 1061.
9. Nelson, J. B., *J. Exp. Med.*, 1953, **98**, 441.
10. Gledhill, A. W., and Andrewes, C. H., *Brit. J. Exp. Path.*, 1951, **32**, 559.
11. Sabin, A. B., *Research Pub., Assn. Research Nerv. and Mental Dis.*, 1954, **33**, 57.

## EXPLANATION OF PLATE 67

The following sections were fixed in Zenker's solution and stained with eosin-methylene blue.

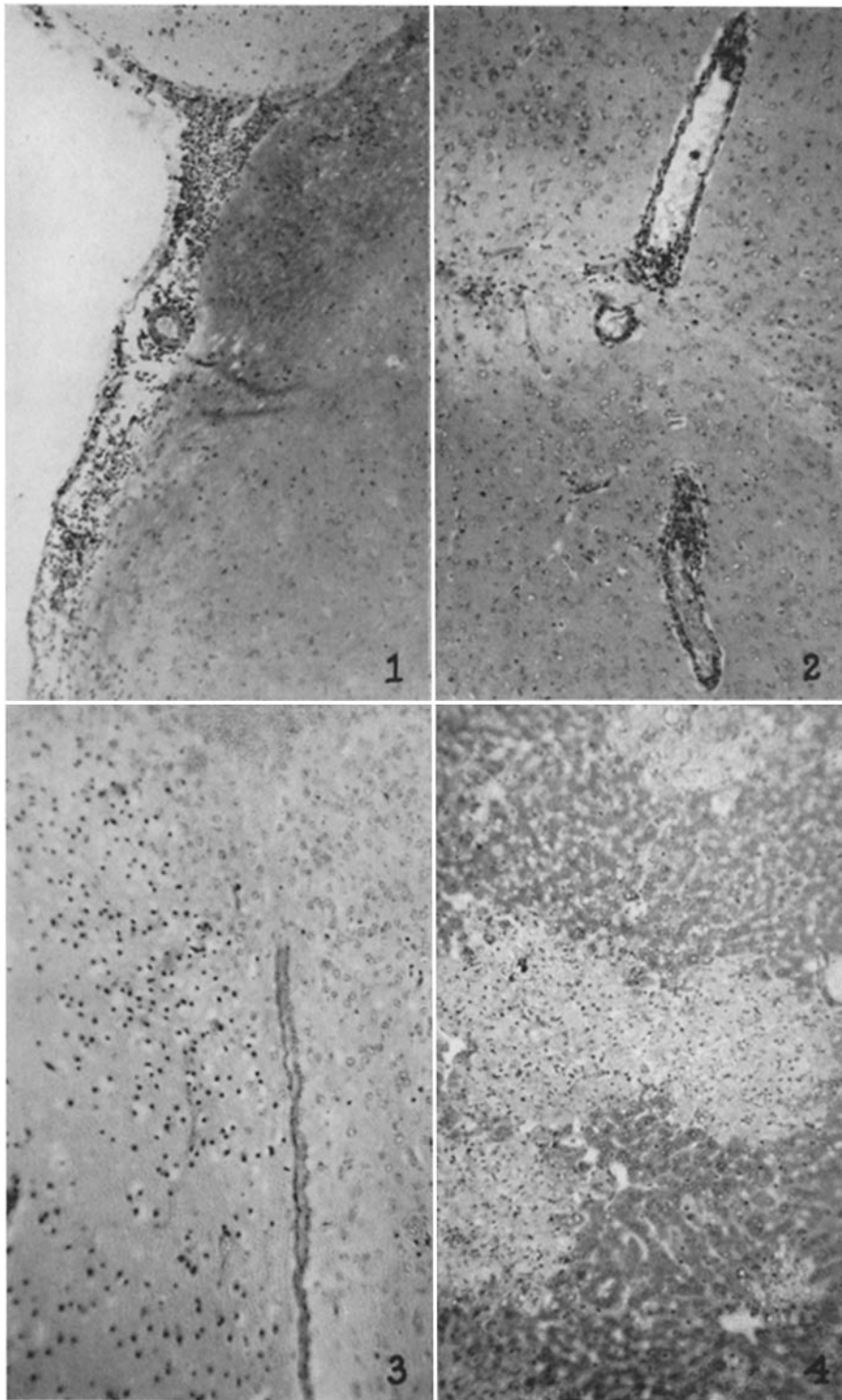
FIG. 1. Area of leptomeningitis in midbrain of a Balb C mouse killed on the 6th day after intracerebral injection with MHV (C).  $\times 100$ .

FIG. 2. Perivascular infiltration and focus of nerve cell destruction in midbrain of a Swiss mouse killed on the 6th day after intracerebral injection with MHV (C).  $\times 100$ .

FIG. 3. Focus of encephalitis with destruction and replacement of nerve cells in midbrain of a Balb C mouse killed on the 6th day after intracerebral injection with MHV (C).  $\times 152$ .

FIG. 4. Discrete areas of necrosis surrounded by normal parenchymal cells in liver of a Princeton mouse killed on the 3rd day after intracerebral injection with MHV (Pr).  $\times 124$ .

Photographed by Mr. J. A. Carlile.



(Nelson: Acute hepatitis associated with mouse leukemia)