

IMMUNOFLUORESCENT STUDIES OF THE HISTOPATHOGENESIS
OF LYMPHOCYTIC CHORIOMENINGITIS VIRUS
INFECTION

BY ROGER E. WILSNACK, D.V.M., AND WALLACE P. ROWE, M.D.

(From the Baltimore Biological Laboratory, Research Department, Baltimore, and the
Department of Health, Education, and Welfare, Public Health Service, National
Institutes of Health, National Institute of Allergy and Infectious Diseases,
Laboratory of Infectious Diseases, Bethesda)

PLATE 80

(Received for publication, July 15, 1964)

The pathogenesis of lymphocytic choriomeningitis (LCM) virus infection of mice has been subjected to intensive study by virus titration and histopathologic techniques (1-5). There are a number of unresolved questions relating to the pathogenesis of the various types of infection which require study of the distribution of virus at the cellular, rather than at the whole organ level. This report describes a direct immunofluorescent antibody test for LCM antigen, and its application to study of cellular distribution of infection in acutely and congenitally infected mice.

Materials and Methods

Mice.—Weanling mice of the HA/ICR strain were purchased from Charles River Mouse Farms, Brookline, Massachusetts. Latent LCM infection was not detected in these mice.

LCM Virus.—The CA 1371 (mouse brain-passaged) and WCP (viscerotropic) strains of LCM virus, and the procedures for preparation of virus stocks have been described previously (6). Swiss mice congenitally infected with LCM virus were from the colony of carrier mice initiated by Haas (7); these mice were in approximately the 41st generation as carriers.

Virus Titrations.—Virus suspensions (clarified by centrifugation at 1800 rpm for 10 minutes) and serial 10-fold dilutions were made in medium 199 with 3 per cent inactivated calf serum. Materials were held in an ice bath, and inoculations made as soon as possible after preparation of suspensions. Weanling mice were inoculated intracerebrally with 0.03 ml, using 6 mice per dilution. Survivors were rechallenged at 14 days postinoculation with approximately 1000 LD₅₀ of strain CA 1371 LCM virus, and held an additional 14 days. Infectivity titers, based on typical death or immunity to challenge as the endpoint, were calculated according to the method of Reed and Muench, and are expressed as the log₁₀ of the number of ID₅₀ per 0.03 ml of 10 per cent suspension. Because of the high degree of pathogenicity of the CA 1371 strain following intracerebral inoculation, immunity tests were not considered necessary to evaluate infectivity titration endpoints with this strain.

Tissue Cultures.—Primary cultures of trypsinized kidney cells of monkey (rhesus and *Cercopithecus*), rabbit, and Syrian hamster were used, as well as WI-26 cells and primary cultures of HA/ICR mouse embryo. All cells were grown on 9 x 35 mm coverslips in Leighton tubes.

Cultures were carried to the point of monolayer on medium 199 (Hanks' base, pH 7.6) and 10 per cent inactivated calf serum, with penicillin and streptomycin. At the time of virus inoculation, the calf serum was reduced to 3 per cent. All media were changed approximately 24 hours postinoculation and at 72 hour intervals thereafter.

Conjugate Preparation.—LCM immune serum¹ was produced in guinea pigs by hyperimmunization with LCM-infected guinea pig spleen suspension. The immune serum demonstrated complement-fixing antibodies to a titer of 1:512 but failed to demonstrate serum-neutralizing antibodies by the intracerebral mouse test; however, there appeared to be slight neutralizing activity by the mouse foot-pad test (8, 9), undiluted serum reducing virus titer by $1.4 \log_{10}$. The serum was fractionated by 50 per cent saturation with ammonium sulfate, and the resulting globulin fraction was labeled with crystalline fluorescein isothiocyanate, isomer I² (10, 11) at pH 9.0. The conjugate was then sorbed with acetone-dried tissue powder (12) prepared from LCM-free mouse brain and liver. Finished conjugate was stored at -80°C . Storage periods in excess of 3 months resulted in a marked diminution of staining titer.

Tissue Sectioning.—Tissue sections (approximately 4 microns) were cut on an International minot rotary microtome. The microtome was housed in a Harris model M-40-C cryostat with an average interior temperature of -18°C . The cryostat was modified for working with infectious material by gas-tight sealing and lateral connection to a class III Blickman modular safety cabinet; both units were maintained under a negative pressure. Fresh tissue blocks were mounted on object discs set in an aluminum block, the aluminum block having been previously imbedded in dry ice. Sections were removed from the microtome knife and placed on 1 x 3 inch microscope slides which had been warmed to approximately 25°C .

Fixation.—All tissue sections and cell cultures were fixed in spectro grade acetone for 4 to 18 hours at -25°C . After removal from the acetone, slides were stored at -80°C until the time of staining. Acetone-fixed LCM antigen was stable for at least 9 months at -80°C .

Immunofluorescent Staining Procedure.—Slides were overlaid with anti-LCM conjugate diluted 1:40 in LCM-free mouse brain and/or liver suspension (10 per cent w/v) and incubated for 30 minutes at 35°C . The slides were then washed (room temperature) in 0.01 M phosphate-buffered saline (pH 7.4) on a rotating apparatus for 20 minutes. Finally, the slides were rinsed with distilled water, and coverslips (Corning, No. 1, 22 x 40 mm) were mounted with 0.066 M phosphate-buffered glycerine (pH 8.5).

Immunofluorescent Staining Controls.—Four staining controls were employed to evaluate the specificity of the conjugates. (a) Staining was not observed in normal (LCM-free) mouse tissue sections which had been incubated with anti-LCM conjugate. (b) Staining was effectively inhibited when the anti-LCM conjugate was diluted (1:40) in homologous *unlabeled* LCM immune serum (1:2). (c) Staining was not observed when LCM-infected cells were treated with a conjugate prepared with serum obtained from guinea pigs immunized with normal guinea pig tissues (brain and spleen). (d) Staining was inhibited when anti-LCM conjugate was diluted 1:40 in an uncentrifuged liver-spleen suspension (10 per cent w/v) prepared from mice infected with WCP strain LCM virus; this suspension had been inactivated by exposure to formalin (1:2000) for 72 hours at 4°C .

Microscope and Light Source.—A Reichert "biozet" binocular microscope was used in conjunction with a Reichert fluorex light source (Osram HBO-200 mercury vapor burner) with an ultraviolet light intensity, distal to the exciter filter, of at least 25 microwatts per cm^2 , as measured with a Westinghouse SM600 meter. The filter system consisted of a No. 8079 exciter filter ($\frac{1}{2}$ thickness) and a Wratten 2A barrier filter. A Bausch & Lomb 40 X fluorite oil immersion objective was used for all observations.

¹ Produced by Microbiological Associates, Inc., Bethesda, on NIH Contract SA-43-ph-4356.

² Baltimore Biological Laboratory, Baltimore.

RESULTS

Immunofluorescent Staining of LCM in Tissue Culture.—Preliminary staining was done in cell culture systems since antigen formation and distribution could be more easily observed within single cells, fixation procedures could be more conveniently assessed, and effective staining titer could be established in the presence of a very minimal background.

Tissue cultures were inoculated with approximately 10^5 mouse LD₅₀ of CA 1371 strain LCM virus, and at various intervals coverslips were stained for antigen and culture fluids were tested for infectivity by intracerebral inoculation into mice. The greatest amount of antigen, and of virus, was found in the rhesus and *Cercopithecus* monkey kidney cultures, with infectivity titers often reaching 10^6 LD₅₀/0.03 ml of culture fluid; this finding is in agreement with the

TABLE I
Growth Curve of CA 1371 Strain LCM Virus in Cercopithecus Monkey Kidney Cell Cultures

After inoculation	Proportion of cells showing fluorescent staining (approximate)	Infectivity titer of culture fluid log ₁₀ LD ₅₀ /0.03 ml
<i>days</i>	<i>per cent</i>	
1	5	
2	15	Neg.
3	30	0.3
4	60	3.5
5	60	
6	70	
7	70	5.8

results of tissue culture studies reported by Benda and Cinatl (13). Table I shows the development of antigen and virus; appearance of antigen preceded release of detectable virus by 2 days, and both reached maximal levels after the 4th day. The maximal virus titers produced in WI-26, mouse embryo, and rabbit kidney cultures were $10^{4.0}$, $10^{3.7}$, and $10^{1.5}$ LD₅₀/0.03 ml, respectively, and the frequency of fluorescent-stainable cells was low. Hamster kidney cultures released no virus, and no antigen was detected by fluorescent antibody staining.

In all instances, antigen was localized to the cytoplasm; in early stages of infection it appeared as finely dispersed granules, while in later stages it appeared as larger inclusion-like masses (Fig. 1).

Distribution of Antigen in Brains of Intracerebrally Infected Mice.—Weanling mice were inoculated intracerebrally with 10^6 LD₅₀ of CA 1371 strain LCM. Three to 5 mouse brains were harvested at hourly intervals during the first 9 hours and daily thereafter through 168 hours. Twelve pairs of sections were

cut from each brain beginning with the cerebellum and working cranial. Each member of a pair was serial to the other member but not to other pairs. One member of each pair was subjected to immunofluorescent staining while the other was stained with hematoxylin and eosin.

LCM antigen was detected in brain sections of some mice as early as 24 hours after inoculation (Table II); after the 2nd day, all brains were positive. In all cases there was striking localization of antigen in leptomeninges, ependyma, and usually choroid plexus. Brain parenchyma was completely negative except for infrequent perivascular cells. There was widespread involvement of meninges at all levels of the brain, even in the earliest positive animals. All antigen was localized to the cytoplasm, appearing as multiple brilliant yellow granules.

TABLE II
Development of LCM Virus and Fluorescent-Stainable Antigen in Mouse Brain

Time after inoculation	Infectivity titer*	Presence of fluorescent antigen†
<i>hrs.</i>		
0-9		0/28
<i>days</i>		
1	4.4	2/5
2	6.2	4/5
3	6.0	4/4
4	6.1	5/5
5		3/3
6		3/3
7		3/3

* Log_{10} LD₅₀/0.03 ml of 10 per cent brain suspension.

† Number of brains showing fluorescent staining of meninges/number examined.

Inflammatory infiltration of the meninges, as observed in hematoxylin and eosin sections, developed at 120 hours postinoculation. It would have been of interest to determine if the inflammatory cells contained antigen, but it was not possible to identify them definitively in the immunofluorescent-stained preparations.

No attempt was made to detect the antigen of CA 1371 LCM virus in any tissue other than brain.

Distribution of Antigen in Mice Infected with Viscerotropic LCM.—The WCP strain of LCM was inoculated intraperitoneally into weanling mice, using 0.1 ml of a 10 per cent mouse tissue (liver, spleen, and lung) suspension. Five mice were sacrificed at daily intervals from the 1st through 7th day. Brain, liver, spleen, kidney, and lung were studied; a minimum of 6 sections per organ were stained by the immunofluorescent method. Lung proved to be very difficult to section in the frozen state, and in most instances fewer sections of lung were cut than of the other organs.

Antigen was first detected at 72 hours postinoculation in the liver and spleen (Table III). Antigen in the liver was largely confined to the parenchymal cells, with rare instances of localization in perivascular connective tissue cells and Kupffer cells. Involved liver cells were usually found in foci or cords of 10 to 20 cells, and infrequently as single infected cells. The distribution of involved cells could not be described as being either periportal or lobular. Hematoxylin and eosin-stained liver sections exhibited lymphoid infiltration beginning on the 5th day postinoculation; necrosis of parenchymal cells was not observed at any time.

The spleen manifested antigen largely in the reticular cells of the red pulp, although a few connective tissue cells and lymphocytes of the white pulp exhibited antigen. The capsule and trabeculae were devoid of antigen.

TABLE III
Time of Appearance of WCP LCM Antigen in Mouse Tissues as Detected by Immunofluorescence

Tissue	Days postinoculation						
	1	2	3	4	5	6	7
Brain	0*	0	0	0	0	0	0
Liver.....	0	0	0 - +	+ - + + +	+ + - + + +	+ + - + + +	+ + - + + +
Lung.....	0	0	ND †	± - +	+ - + +	+ - + + +	ND
Spleen.....	0	0	0 - +	± - + +	+ - + + +	+ - + +	+ + +
Kidney.....	0	0	0	0 - ±	0	± - +	+ - + +

* Degree of involvement: 0, antigen not observed; ±, few cells involved (less than 1 per cent); +, slight (1 to 10 per cent); ++, moderate (10 to 25 per cent); + + +, heavy (25 per cent or more). The symbols denote the range of 5 mice per time point.

† ND = not done.

Antigen formation in the lung was manifested largely by the progressive appearance of antigen in bronchial epithelium, alveolar cells, and an occasional macrophage. Pleural effusion was first noted on the 6th day, but pleural cells could not be evaluated for fluorescence because of the poor quality of the lung sections.

The initial manifestation of LCM antigen in the kidney occurred at 4 days after inoculation, with minimal involvement of convoluted tubules, glomeruli, and connective tissue cells. Kidney involvement with WCP LCM virus was very erratic as evidenced by the absence of antigen in all kidneys sampled on the 5th day. At the last sampling interval, 7 days, renal involvement remained minimal.

The brain, in contrast to other tissues, failed to exhibit antigen in any of the sampling intervals.

Distribution of LCM Antigen in Congenitally Infected Mice.—Six young

adult, congenitally infected mice were studied; all were viremic at time of sacrifice. Tissue samples from 3 of the mice were subjected to concurrent virus quantitation by intracerebral inoculation of mice. A minimum of 8 sections were stained (immunofluorescent) from each organ. The infectivity and fluorescent antibody studies are summarized in Table IV. The description of the findings is of necessity an oversimplification due chiefly to the variation in pattern between mice and, to a far lesser extent, due to intraorgan variation.

As in the case of WCP strain infection, liver was the most extensively involved organ, and the pattern of staining in liver was indistinguishable from

TABLE IV
Infectivity Titers and Immunofluorescent Staining Reactions of Tissues of Congenitally Infected Mice

Mouse No.	Brain			Liver		Spleen		Kidney		Lung		In-testine		Heart		Ovary and uterus	Blood		
	Titer*	FA† Pa- ren- chy- ma	FA Lepto- men- inges, choroid plexus, epen- dyma	Titer	FA	Titer	FA	Titer	FA	Titer	FA	Titer	FA	Titer	FA	FA	Infectivity‡	FA	
RV-149		0	0		++		±		±									+	0
RV-150		0	+		+++		++		++		±							+	0
RV-151		0	0		++		+++		+		++		±		±			+	++
RV-174	2.5	0	+	4.0	+++	3.4	+		+++		+++					+++		+	0
RV-175	4.4	++	+++	4.7	+++	4.4	+	5.3	+++	4.2	+							+	
RV-176	3.5	0	++	3.5	++	3.4	++	5.0	+	4.5	+	4.4	±	3.1	±			+	

* Log₁₀ of ID₅₀ per 0.03 ml of 10 per cent suspension.

† FA, Immunofluorescent-staining results.

‡ +, presence of virus in undiluted blood.

|| Degree of involvement: 0, antigen not observed; ±, <1 per cent cells involved; +, 1 to 10 per cent cells involved; ++, 10 to 25 per cent cells involved; +++, >25 per cent cells involved. Blank space indicates not tested.

that in the acute infection. Liver sections varied in the amount and distribution of antigen, but every section examined demonstrated some staining. Most of the antigen was located in liver parenchymal cells and appeared as fine granules scattered throughout the cytoplasm (Fig. 2). Usually antigen-containing cells were situated in foci or cords, not lobular in distribution or confined to any particular area of the lobule. Antigen was noted infrequently in columnar epithelium of the bile ducts, perivascular connective tissue, and only rarely in Kupffer cells and arterial endothelium.

Viral antigen was detected in the spleens of all the mice examined, but not necessarily in all sections. The majority of the demonstrable antigen was localized in reticular and other connective tissue of the red pulp. Only rarely was antigen noted in lymphocytes of the malpighian corpuscles. Frequently,

antigen-containing cells were evenly distributed throughout the section, as opposed to the focal distribution in the liver. The capsule and trabeculae were invariably negative.

The kidney was of particular interest, since in contrast to acute infection of adult mice by viscerotropic LCM, congenitally infected mice void significant amounts of virus in the urine (14). In agreement with this, the congenital carriers generally showed much more antigen in kidneys than the WCP infected mice. Antigen was observed in the proximal and distal convoluted tubules, both intracellular and free in the lumen, in glomeruli, parietal layer of Bowman's capsule, uriniferous tubules, papillary ducts, and connective tissue cells. Usually, the antigen in the glomerulus was coalesced into inclusion-like masses, while other antigen in the tubules was evident as fine, granular cytoplasmic particles. There was extreme variation between mice in amount and distribution of antigen; in some animals antigen was localized primarily to glomeruli (Fig. 3), while in others it was chiefly in tubules (Fig. 4). There was also variation as to the extent of involvement in different areas of the same kidney, some sections or large areas within a section being negative. A sub-acute glomerular nephritis, similar to that described by Hotchin *et al.* (15) was noted in hematoxylin and eosin-stained sections of the kidneys of all 6 mice, but there was no interstitial nephritis of the type described by Traub (16).

Viral antigen was demonstrated in the brains of 4 of the 6 mice. With one exception, the intracytoplasmic antigen was limited to a small percentage of cells of the leptomeninges, choroid plexus, arterial endothelium, perivascular connective tissue, and rarely astrocytes and neuroglia. Mouse RV-175 (Table IV) proved a notable exception, in that the majority of the neurons in the thalamus and temporal lobe of one hemisphere exhibited intracytoplasmic antigen; in the contralateral region, however, none of the neurons demonstrated antigen. This animal also showed antigen in cells of the leptomeninges, choroid plexus, and ependyma. The brain and meninges manifested a degree of localization of antigen greater than any of the other organs examined; many of the sections examined, including some from RV-175, demonstrated no antigen.

Lung was difficult to interpret since few acceptable sections were obtained. However, intracytoplasmic antigen was seen in the bronchial epithelium, macrophages, and alveoli. All of the lungs examined exhibited some antigen; however, some sections were negative. In some bronchi, about 75 per cent of the epithelial cells contained the fine, particulate cytoplasmic antigen.

Intestine (duodenum) and heart were examined in 2 mice (Table IV). Antigen was sparsely distributed in both tissues. Antigen-containing cells of the intestine were located in the submucosa and muscularis, while the few positive connective tissue cells in the heart were scattered through the myocardium. No antigen was seen in cardiac muscle.

Ovary and uterus were sectioned in mouse RV-174 (Table IV). The uterus was gravid with an early pregnancy of unknown duration. The virus content of ovarian and uterine tissue was not determined, since it was felt that the small amount of available tissue could best be utilized by immunofluorescent and histologic staining of sections. Intracytoplasmic antigen was demonstrated in about 25 per cent of the epithelial cells in the uterine mucosa and trophoblastic epithelium of the embryonic tissue. In addition, antigen-containing connective tissue cells were noted in the uterine submucosa and myometrium, and scattered staining was noted in cells of the arterial intima and perivascular connective tissue. Viral antigen in the ovary was confined to the cytoplasm of connective tissue cells, and was not demonstrated in follicular cells or ova. Ovarian connective tissue cells that demonstrated antigen were located in randomly distributed foci.

Attempts to stain LCM antigen in acetone-fixed blood smears from the congenitally infected mice gave generally erratic and unreliable results. However, blood smears of mouse RV-151 (Table IV) showed definite fluorescent-stainable antigen as fine granules on or in roughly 10 per cent of the erythrocytes. This observation is in agreement with the reported association of LCM virus with erythrocytes (17).

Tests for Antigen in Wild Mice.—Eleven livers from wild house mice were sectioned and stained for LCM antigen; at the same time the spleens were tested for infectivity. Nine of these livers had been stored at -60°C for approximately a year, while the other 2 had been stored at the same temperature for a month. Immunofluorescent LCM antigen was demonstrable in the liver of one mouse (part of the series stored at -60°C for 1 year), and virus was recovered from the spleen. The quantity and distribution of LCM antigen observed in this liver was indistinguishable from that seen in livers of the congenitally infected laboratory mice.

The remaining livers were negative to immunofluorescent LCM stain, although 2 had been harvested from mice that yielded viable LCM virus from their spleens.

DISCUSSION

The immunofluorescent staining described in this report probably represents staining of soluble antigen (18). This theory is supported by several salient points: (a) The immune serum used in the preparation of the conjugate, had a complement-fixing antibody titer of 1:512, but only minimal virus-neutralizing capacity. (b) The percentage of antigen-containing cells within an organ could not be correlated with the infectious virus titer of that organ (Table IV), and in tissue cultures antigen appeared 2 days before infectious virus was detected. (c) Immunofluorescent staining could be inhibited only by dilution in preparations of LCM antigen which included soluble antigen.

The present observations provide additional insight into several problems concerning the pathogenesis of mouse LCM virus infection. Much indirect evidence has indicated that the mechanism of disease production in intracerebrally infected mice is associated with meningeal inflammation (3, 19); however, it has not been possible previously to evaluate the alternative hypotheses that involvement of brain parenchyma or vascular tissue, though unaccompanied by cytologic damage or inflammatory response, may initiate the convulsions. The present studies provide more direct evidence that infection is almost completely restricted to meninges, choroid plexus, and ependyma without multiplication of virus in brain parenchyma. Although antigen was present in perivascular areas, it was minimal in extent, and the time of its appearance did not correlate with onset of disease.

The observations on the viscerotropic virus infection essentially confirm the distribution of infection indicated by previous histological and infectivity studies. Interstitial inflammatory infiltration of liver and lung are the characteristic pathologic reaction, while the spleen is known to contain virus in relatively high titer. The limited involvement of the kidney is also in accord with the observation that acutely infected mice do not excrete significant amounts of virus in the urine (14). A noteworthy finding was the lack of viral antigen in lymphocytes.

In the congenitally infected mice the most striking observation was the relatively low proportion of cells exhibiting antigen. A wide variety of cell types was infected, including connective tissue cells in many organs; hepatic parenchyma and Kupffer cells; bronchial, uterine, and bile duct epithelium; renal glomeruli and tubular cells; neurons, choroid plexus, meninges, and ependyma; trophoblast; and rarely, lymphocytes. However, in most instances the great majority of cells were negative, and infection was often restricted to focal areas. In the brain and spleen, the focal areas of infection could possibly be related to vascular branching, but this was clearly not the case in the liver. The restricted extent of infection indicates that the congenital carrier mice are not devoid of mechanisms for inhibiting growth of LCM virus.

The observations on the pregnant uterus and ovaries of a congenitally infected mouse are of possible importance in defining the time of transfer of infection to the fetuses. The abundance of viral antigen in uterine epithelium, in contrast to its absence in follicles and ova, suggests that the infection may not be transovarial, but acquired *in utero*. However, absence of antigen cannot be equated with absence of virus or viral genetic material, and further studies will be necessary for a definitive answer.

Since LCM antigen was consistently detected in the liver, this organ would appear to be the logical sentinel organ in the immunofluorescent diagnosis of mouse LCM infection. Simple acetone-fixed liver tissue impressions proved as sensitive as frozen sections in the detection of LCM antigen by immunofluores-

cent staining, but the tissue impressions were of course of little value in the establishment of cytological and morphological relationships.

SUMMARY

LCM virus antigen was visualized in infected tissue cultures and mouse tissues by the direct immunofluorescent procedure. In all instances, antigen was localized to the cytoplasm.

In intracerebrally infected mice, antigen was almost completely restricted to meninges, choroid plexus, and ependyma; at no time were neurons involved. Mice infected by intraperitoneal inoculation of a viscerotropic strain demonstrated antigen chiefly in liver parenchyma, splenic reticulum, bronchi, and alveolar cells.

Congenitally infected mice showed antigen in almost all cell types observed, but generally in only a minority of cells; infection was often focal in distribution. Liver, kidney, pregnant uterus, and trophoblast were most extensively involved. No antigen was observable in ova of a pregnant mouse.

BIBLIOGRAPHY

1. Traub, E., Factors influencing the persistence of choriomeningitis virus in the blood of mice after clinical recovery, *J. Exp. Med.*, 1938, **68**, 229.
2. Lillie, R. D., and Armstrong, C., Pathology of lymphocytic choriomeningitis in mice, *Arch. Path.*, 1945, **40**, 141.
3. Rowe, W. P., Studies on pathogenesis and immunity in lymphocytic choriomeningitis infection of the mouse, *Naval Med. Research Inst. Rep.*, 1954, **12**, 167.
4. Haas, V. H., Some relationships between lymphocytic choriomeningitis (LCM) virus and mice, *J. Infect. Dis.*, 1954, **94**, 187.
5. Hotchin, J., The biology of lymphocytic choriomeningitis infection: Virus-induced immune disease, *Cold Spring Harbor Symp. Quant. Biol.*, 1962, **27**, 479.
6. Rowe, W. P., Black, P. H., and Levey, R. H., Protective effect of neonatal thymectomy on mouse LCM infection, *Proc. Soc. Exp. Biol. and Med.*, 1963, **114**, 248.
7. Haas, V. H., Studies on the natural history of the virus of lymphocytic choriomeningitis in mice, *Public Health Rep., U.S.P.H.S.*, 1941, **56**, 285.
8. Hotchin, J., The foot pad reaction of mice to lymphocytic choriomeningitis virus, *Virology*, 1962, **17**, 214.
9. Roger, F., and Roger, A., Etudes sur le pouvoir pathogène expérimental du virus de la choriomeningite lymphocytaire. IV. Niveau de mortalité des souris après inoculation sous-cutanée plantaire, *Ann. Inst. Pasteur*, 1963, **105**, 476.
10. Felton, L. C., and McMillion, C. R., Chromatographically pure fluorescein and tetramethylrhodamine isothiocyanates, *Anal. Biochem.*, 1961, **2**, 178.
11. Marshall, J. D., Eveland, W. C., and Smith, C. W., Superiority of fluorescein isothiocyanate (Riggs) for fluorescent antibody technique with a modification of its application, *Proc. Soc. Exp. Biol. and Med.*, 1958, **98**, 898.
12. Coons, A. H., and Kaplan, M. H., Localization of antigen in tissue cells. II. Improvements in a method for the detection by means of fluorescent antibody, *J. Exp. Med.*, 1950, **81**, 1.

13. Benda, R., and Cinatl, J., Multiplication of lymphocytic choriomeningitis virus in bottle cell cultures. Experimental data for the preparation of highly infectious fluids, *Acta Virol.*, 1962, **5**, 159.
14. Traub, E., The epidemiology of lymphocytic choriomeningitis in white mice, *J. Exp. Med.*, 1936, **64**, 183.
15. Hotchin, J., Benson, L. M., and Collins, D. N., Late-onset kidney disease of mice with persistent tolerant infection with lymphocytic choriomeningitis virus, *Fed. Proc.*, 1963, **22**, No. 2, pt. 1, 441, abstract 1676.
16. Traub, E., Persistence of lymphocytic choriomeningitis virus in immune animals and its relation to immunity, *J. Exp. Med.*, 1936, **63**, 847.
17. Shwartzman, G., Recovery of the virus of lymphocytic choriomeningitis from the erythrocytes of infected animals, *J. Immunol.*, 1944, **48**, 111.
18. Smadel, J. E., and Wall, M. J., A soluble antigen of lymphocytic choriomeningitis. III. Independence of anti-soluble substance antibodies and neutralizing antibodies and the role of soluble antigen and inactive virus in immunity to infection, *J. Exp. Med.*, 1940, **72**, 389.
19. Rowe, W. P., Protective effect of pre-irradiation on lymphocytic choriomeningitis infection in mice, *Proc. Soc. Exp. Biol. and Med.*, 1956, **92**, 194.

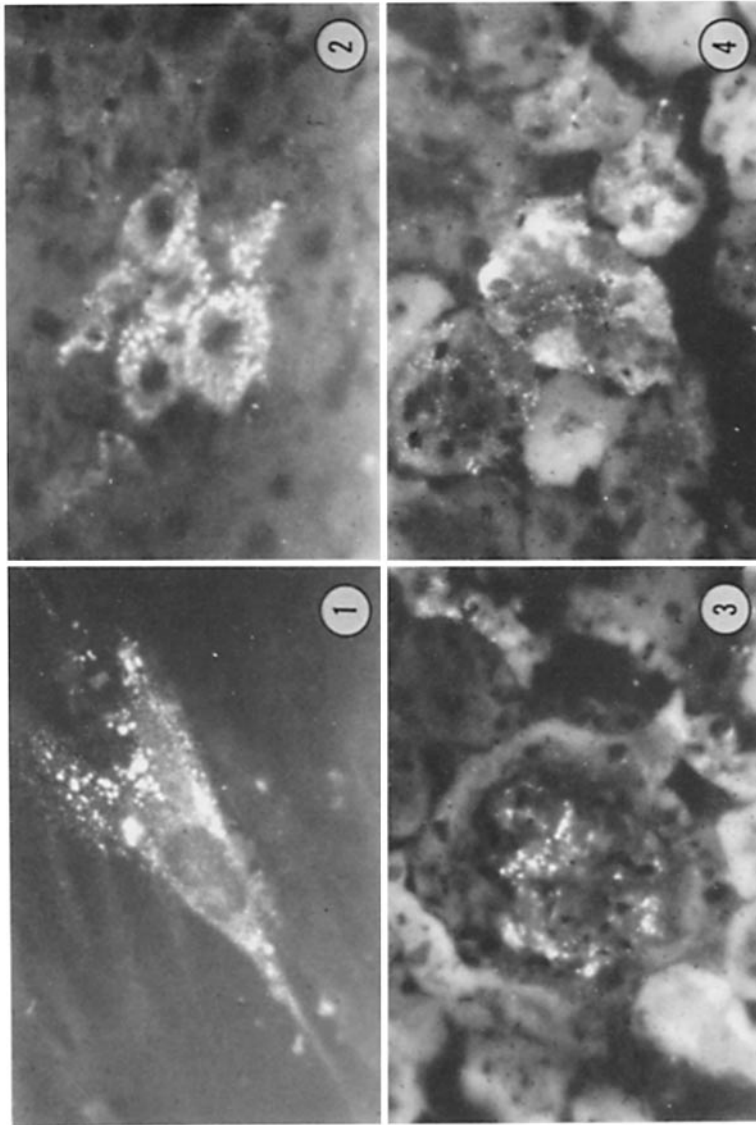
EXPLANATION OF PLATE 80

FIG. 1. WI-26 cell 5 days postinoculation with CA 1371 LCM virus. Cytoplasmic antigen demonstrated by immunofluorescent stain. $\times 800$.

FIG. 2. Liver section from mouse (RV-175) congenitally infected with LCM virus. Antigen in cytoplasm of liver parenchyma cells demonstrated by immunofluorescent stain. $\times 800$.

FIG. 3. Kidney section from mouse (RV-174) congenitally infected with LCM virus. Antigen in glomerulus demonstrated by immunofluorescent stain. $\times 800$.

FIG. 4. Kidney section from mouse (RV-175) congenitally infected with LCM virus. Antigen deposits in convoluted tubules demonstrated by immunofluorescent stain. $\times 800$.



(Wilsnack and Rowe: Lymphocytic choriomeningitis virus infection)