

ENDOTOXEMIA AND ADRENAL HEMORRHAGE

A MECHANISM FOR THE WATERHOUSE-FRIDERICHSEN SYNDROME*

By JACK LEVIN, M.D., AND LEIGHTON E. CLUFF, M.D.

(From the Department of Medicine, The Johns Hopkins University School of Medicine, Baltimore)

PLATES 19 TO 21

(Received for publication, September 8, 1964)

Endotoxin causes hemorrhage and necrosis in several tissues, tumors (1), placenta (2), gastrointestinal tract (3), skin (4), and kidney (5), but destruction of the adrenal has been rarely reported as a manifestation of endotoxemia (6). Adrenal cortical hormone can protect against the lethal effects of endotoxin (7, 8), and under appropriate conditions may inhibit the Shwartzman reaction in skin (9). Prevention of the Shwartzman reaction and other toxic effects of endotoxin by adrenal corticosteroids might explain the failure to demonstrate adrenal cortical hemorrhage by an intravenous injection of endotoxin. The steroidal content of the adrenal cortex could protect this organ from tissue injury induced by the toxin. Nevertheless, cortisone does not prevent endotoxin induced abortion (2), and has been shown under certain conditions to prepare animals for the local and generalized Shwartzman reaction following a single injection of toxin (10).

Vascular alterations caused by endotoxin may be mediated by a variety of vasoactive substances (8) and endotoxin sensitizes blood vessels to the action of epinephrine (11). Cortisone does not completely prevent the vascular changes caused by endotoxin (12). Since endotoxin stimulates both the adrenal cortex and adrenal medulla (13), both augmentation of and protection from the injurious effects of endotoxin might be expected under different circumstances from the stimulation of this gland during endotoxemia.

The Waterhouse-Friderichsen syndrome, characterized by the association of adrenal hemorrhage with sepsis, is most often seen in meningococcemia (14). However, a variety of other infections, particularly by bacteria possessing endotoxins, have been implicated in this syndrome (15). Although described by Voelcker 70 years ago (16), the pathogenesis of adrenal hemorrhage during sepsis is not known.

The studies reported here demonstrate that endotoxin injected intravenously

* This work was supported by grants from the National Institutes of Health and by contracts with the Army Biological Laboratory and Atomic Energy Commission.

into rabbits, prepared with thorotrast or endotoxin, produced bilateral adrenal cortical hemorrhage, particularly when endotoxin was administered less than 10 hours after preparation of the animals with thorotrast or a prior injection of endotoxin. Stimulation of the adrenal cortex by adrenocorticotropin similarly predisposed the adrenal cortex to hemorrhage during endotoxemia. Hyperactivity of the adrenal cortex appears to be an important factor predisposing the adrenal gland to cortical hemorrhage during endotoxemia.

Materials and Methods

Animals.—Albino New Zealand rabbits, weighing approximately 5 pounds, and fed standard laboratory food and water *ad lib* were used in all of the studies.

All materials given intravenously were dissolved and diluted in sterile, pyrogen-free, 0.85 per cent NaCl immediately prior to injection.

Thorotrast.—A sterile, stabilized, colloidal suspension of thorium dioxide, (24 to 26 per cent by volume), obtained from Fellows-Testagar Co., Inc., Detroit, was given intravenously in a dose of 10 ml per animal.

Cortisone.—Cortisone acetate (Merck, Sharp, and Dohme, West Point, Pa.) was administered subcutaneously, in a dose of 25 mg every day for 7 days.

Hydrocortisone.—Hydrocortisone sodium succinate (The Upjohn Co., Kalamazoo, Michigan) was administered intravenously in a dose of 50 mg twice daily for 2 days.

Endotoxin.—Lyophilized lipopolysaccharide of *Escherichia coli* 026:B6 was obtained from Difco Laboratories, Inc., Detroit.

Heparin.—Heparin sodium (Lederle Laboratories Div., American Cyanamid Co., Pearl River, New York), in a concentration of 100 mg/ml was diluted in 0.85 per cent NaCl to give a final concentration of 5 mg per ml.

Phenoxybenzamine HCl (Smith, Kline, and French Laboratories, Philadelphia) was administered in a dose of 3 mg per animal. This compound blocks the alpha receptors of the adrenergic system.

1 (3', 4'-Dichlorophenyl)-2-Isopropylaminoethanol HCl (DCI) and Alderlin (AY-6204).—Both these beta adrenergic blockers were administered in a dose of 200 mg per animal. (These were kindly supplied by Dr. Charles W. Fishel, University of Colorado Medical Center, Boulder).

Nitrogen Mustard (Merck, Sharp, and Dohme).—Nitrogen mustard as mechlorethamine HCl was administered intravenously to animals in a dose of 5 mg per animal.

Thyrotropin (Armour and Company, Chicago).—Thyrotropin was administered intravenously in a dose of 10 U.S.P. units per animal.

Corticotropin (Armour and Company) was administered intravenously in a dose of 20 U.S.P. units per animal.

Pathologic Studies.—Animals were killed for pathological examination by the intravenous injection of lethal doses of sodium pentobarbital. Autopsies were performed immediately following sacrifice and the abdominal organs examined. Tissues were fixed in 10 per cent formalin, and sections were stained with hematoxylin-eosin.

Blood Cortisol.—Blood cortisol levels were measured according to the method of De Moor *et al.* (17) by Dr. David Seligson, Director of Laboratories, Yale-New Haven Medical Center.

Clotting Time.—Clotting times were carried out in non-siliconized glass test tubes at 37°C according to the method of Jackson *et al.* (18) with the modification that two tubes, rather than three, were used.

RESULTS

Previous studies (19, 20) have failed to show significant hemorrhage in the adrenal gland following an intravenous injection of endotoxin. During the course of experiments on the generalized Shwartzman phenomenon, however, it was found that intravenous injection of endotoxin, under certain conditions, induced massive adrenal hemorrhage in rabbits injected some hours before with thorotrast.

Rabbits were injected intravenously with 10 ml of thorotrast, and given 40 μ g of endotoxin intravenously at intervals of time thereafter. Similar experi-

TABLE I
Effect of Time Interval Between the Administration of Thorotrast and Endotoxin or ACTH and Endotoxin on Adrenal Hemorrhage

Hrs.	Thorotrast followed by endotoxin		ACTH followed by endotoxin	
	Incidence	Severe	Incidence	Severe
$\frac{1}{2}$	4/5*	0/5‡	3/6	1/6
1	3/4	1/4	3/6	2/6
2	4/5	1/5	6/9	3/9
4	8/8	7/8	7/9	6/9
6	4/4	2/4	3/8	0/8
8	3/5	3/5	2/6	0/6
10	2/4	2/4	1/3	1/3
18	3/4	2/4	0/3	0/3

* Number of animals with bilateral adrenal hemorrhage/total number of animals.

‡ Animals with hemorrhage involving more than $\frac{1}{2}$ of the adrenal cortex.

ments were done with varying doses of endotoxin given 4 hours after preparation of animals with thorotrast. At death or within 24 hours after the endotoxin injection animals were sacrificed, autopsied, and the adrenal glands and kidneys were removed for gross and histopathological study.

Bilateral adrenal cortical hemorrhage (Figs. 1 *a* and 3 *b*) was observed in more than 50 per cent of animals, particularly when endotoxin was injected intravenously approximately 4 hours after preparation of the animals with thorotrast (Table I). When endotoxin was injected earlier or later than 4 hours after administration of thorotrast the frequency and severity of the adrenal cortical hemorrhage was less. Severe hemorrhage was not seen when the interval between the thorotrast and endotoxin injection was less than 1 hour. Adrenal hemorrhage and necrosis was most intense in the midcortical or fascicular zone of the gland, but when severe involved the entire adrenal cortex (Fig. 1 *b*). Granulocytes were often seen in the area of cortical involvement. The adrenal

medulla was always free of hemorrhage or other significant change. When the dose of endotoxin given 4 hours after thorotrast was reduced from 40 to 2 μg adrenal hemorrhage still was induced in 50 per cent of animals. "Fibrinoid" deposits in the renal glomeruli and renal cortical necrosis was occasionally observed when endotoxin was injected later than 10 hours after administration of thorotrast. Intravenous injection alone of the dose of thorotrast employed in these experiments into separate groups of rabbits would rarely produce adrenal hemorrhage. Larger doses, however, occasionally produced adrenal hemorrhage even without subsequent injection of endotoxin. Endotoxin alone injected into separate groups of rabbits did not produce adrenal hemorrhage or renal glomerular lesions.

To determine if thorotrast was essential in the development of adrenal hemorrhage induced by a subsequent injection of endotoxin the following experiment was performed.

A group of rabbits was given 40 μg of endotoxin and 4 hours later 100 μg of endotoxin was similarly injected. At death or within 24 hours after the second endotoxin injection, the animals were sacrificed, autopsied, and the adrenal glands and kidneys were removed for gross and histopathological examination, as before.

Adrenal cortical hemorrhage was observed in rabbits given two separate injections of endotoxin 4 hours apart, resembling that produced by endotoxin given 4 hours after preparation of rabbits with thorotrast (Fig. 3 *c*).

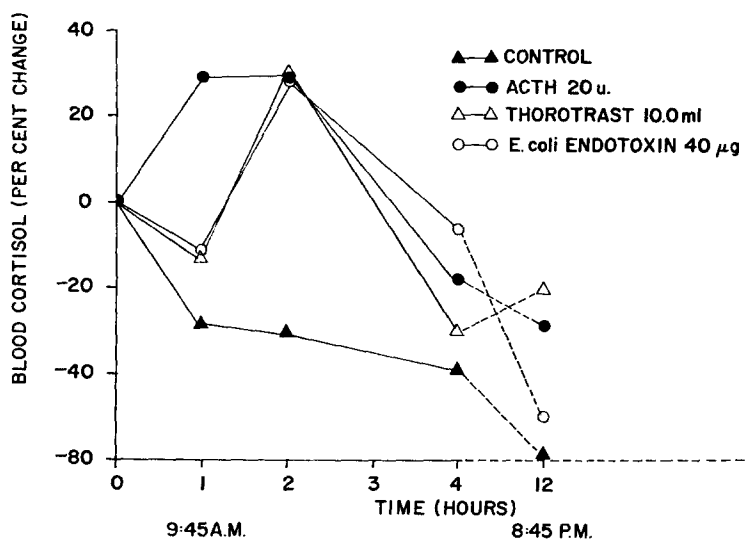
Relation of Adrenal Hemorrhage to Cortical Function.—In the preceding experiments hemorrhagic lesions were observed occasionally in lung and spleen as well as the adrenal, and in those few instances where renal cortical necrosis was produced. Renal cortical necrosis was observed, however only when endotoxin was injected intravenously greater than 10 hours after preparation of rabbits with thorotrast or a primary injection of endotoxin. No reason was readily apparent to explain why a preparatory injection of thorotrast or endotoxin sensitized the adrenal cortex to hemorrhage following an intravenous injection of endotoxin some 4 hours later. Specific localization of endotoxin or thorotrast in the adrenal cortex has not been demonstrated. It seemed possible that stimulation of the adrenal cortex to elaborate corticosteroid might explain the localization of hemorrhage to the adrenal during endotoxemia. To examine this possibility the following experiment was done.

Adrenocorticotropin (ACTH) was injected intravenously in a dose of 20 U., and 40 μg of endotoxin was injected intravenously at varying intervals of time thereafter. After death or within 24 hours the rabbits were sacrificed and examined as in previous experiments.

Over 50 per cent of rabbits given ACTH 4 hours prior to endotoxin developed bilateral adrenal cortical hemorrhage (Figs. 2 *a*, 2 *b*, and 3 *d*). The most severe and frequent adrenal hemorrhage was observed when the interval between

injection of ACTH and endotoxin was 4 hours or less (Table I). In contrast to thorotrast pretreated rabbits, severe hemorrhage was noted when endotoxin was administered 30 minutes after injection of ACTH. The adrenal hemorrhage and necrosis was confined largely to the midcortical or fascicular zone of the adrenal gland. No renal cortical lesions were observed in any of the animals and injection of ACTH alone did not cause adrenal hemorrhage although it did induce enlargement of the adrenal cortex.

The previous experiment suggested strongly that activation of the adrenal



TEXT-FIG. 1. Changes in blood cortisol levels in normal rabbits and in rabbits given 40 µg endotoxin, 20 u ACTH or 10 ml thorotrast intravenously. Progressive decline in blood cortisol in normal rabbits attributable to diurnal variation.

cortex was important in predisposing the gland to hemorrhagic necrosis during endotoxemia, and that endotoxemia induced adrenal hemorrhage during only a critical period of adrenal cortical stimulation. To evaluate the relationship of adrenal cortical activity to susceptibility of the gland to the injurious effects of endotoxin blood cortisol levels were determined in separate groups of rabbits at intervals of time after intravenous injection of 10 ml thorotrast, 40 µg endotoxin or 20 u. ACTH.

Blood cortisol levels rose significantly following injection of ACTH, endotoxin or thorotrast, reaching similar concentrations at 2 hours, and declining progressively thereafter in the same way (Text-fig. 1). The only difference in adrenal cortical secretion following injection of the three substances was the more rapid rise after administration of ACTH. These elevations of the blood

cortisol level correspond to the period of time during which the adrenal cortex is maximally susceptible to hemorrhagic necrosis after injection of endotoxin.

To further establish the importance of adrenal cortical elaboration of corticosteroid in increasing the gland's susceptibility to hemorrhage during endotoxemia the following experiments were done.

Groups of rabbits were given 25 mg of cortisone acetate intramuscularly every day for 7 days, followed by 50 mg of hydrocortisone intravenously twice daily for the next 2 days. Twenty-four hours after the last injection of hydrocortisone the animals were given thorostrast or ACTH intravenously. Four hours later 40 μ g of endotoxin was given intravenously to the ACTH treated animals and 20 μ g endotoxin was given similarly to the thorostrast treated animals. At death or following sacrifice within 24 hours the rabbits were autopsied for study.

Pretreatment of rabbits with corticosteroid to suppress adrenal cortical activity resulted in marked suppression of adrenal hemorrhage when endotoxin was administered to thorostrast or ACTH prepared animals, as contrasted with that found in rabbits not pretreated with corticosteroid. These findings indicate further that functional activation of the adrenal cortex is important in predisposing the gland to hemorrhagic-necrosis during endotoxemia.

In view of the suppressive effect of corticosteroid pretreatment upon adrenal hemorrhage induced by endotoxin it was important to determine if administration of corticosteroid after preparation of rabbits with thorostrast or ACTH, but before endotoxin administration, would similarly suppress the adrenal cortical hemorrhagic reaction.

Fifty mg of hydrocortisone was given intravenously to a group of rabbits 30 and 60 minutes after injection of ACTH or thorostrast, and prior to injection of endotoxin. In addition, 100 mg hydrocortisone was given 3 hours after administration of ACTH and thorostrast, or 1 hour prior to injection of endotoxin. Animals were autopsied and studied as before.

Some reduction in frequency and severity of adrenal hemorrhage was demonstrated by administration of hydrocortisone before injection of endotoxin but after preparation of rabbits with ACTH or thorostrast, when compared with that of animals not given hydrocortisone. The suppression of the adrenal-cortical hemorrhage was not as great as that observed when corticosteroid was administered for several days prior to study.

Relation of Adrenal Hemorrhage to Adrenergic Function.—Although the hemorrhagic-necrosis demonstrated in the adrenal gland in all of the preceding experiments was confined to the cortex, the possibility that adrenal medullary function might be involved in the reaction was investigated in the following experiments.

Phenoxybenzamine, alderlin, or 1(3',4'-dichlorophenyl)-2-(isopropylamino) ethanol was injected intravenously into rabbits prior to study in doses described in Materials and Methods. Phenoxybenzamine was given 1 hour prior

to injection of thorotrast or ACTH, and the other two compounds were injected 6 hours prior to injection of thorotrast or ACTH, in separate groups of rabbits. Four hours after administration of thorotrast or ACTH the rabbits were given endotoxin intravenously as described before. Animals were autopsied and studied as in previous experiments.

These inhibitors of the alpha and beta receptors of the adrenergic system slightly decreased the frequency and moderately decreased the severity of adrenal hemorrhage induced by endotoxin, when compared with that observed in animals not given the inhibitors. The decrease in severity of adrenal hemorrhage was more marked in animals that had received ACTH prior to endotoxin than in those that had received thorotrast. The suppression of the hemorrhagic cortical reaction, however, was not impressive, suggesting further that adrenal cortical activity was primarily involved in predisposing the gland to hemorrhagic-necrosis during endotoxemia.

Relation of Adrenal Hemorrhage to the Schwartzman Reaction.—The hemorrhagic reaction in the adrenal cortex to endotoxin might have a pathogenesis similar to that of the local or generalized Schwartzman phenomenon. Previously, it has been shown that the cutaneous and generalized Schwartzman reactions involve coagulation processes (21, 22) and leucocyte activity, as indicated by inhibition of these reactions by anticoagulation or agranulocytosis. No vascular thromboses were ever seen in the adrenal gland associated with hemorrhagic necrosis of the cortex. Granulocytes commonly but not regularly were seen in the adrenal cortex during the hemorrhagic adrenal reaction induced by endotoxin. To evaluate possible similarities between the Schwartzman phenomenon and the adrenal cortical hemorrhage during endotoxemia, therefore, the following experiments were performed.

Heparin was injected intravenously in doses of 5 mg given 30 minutes prior to, and 60, 90, and 180 minutes after administration of endotoxin to a group of rabbits injected with thorotrast or ACTH 4 hours prior to giving the toxin. The whole blood clotting time in these heparinized rabbits was maintained at greater than 2 hours (normal 6 to 10 minutes) following administration of the anticoagulant. Animals were sacrificed and studied as before.

There was no suppression of the adrenal cortical hemorrhage by heparin anticoagulation comparable to that reported to inhibit completely the local and generalized Schwartzman reaction (21, 22).

Nitrogen mustard in a dose of 5 mg was injected intravenously into a group of rabbits and their peripheral leucocytes were counted thereafter. Granulocytopenia was demonstrable in most animals within 3 to 4 days and at that time the rabbits were given thorotrast or ACTH followed by endotoxin 4 hours later as in previous experiments. Animals were sacrificed and studied as before.

Adrenal cortical hemorrhagic necrosis was not demonstrable in animals who were severely granulocytopenic with total leucocyte counts less than 2000 per

mm³. Most of these animals had minimally reduced or normal platelet counts (Table II). When the total leucocyte count exceeded 2000 per mm³ some hemorrhage was occasionally seen in the adrenal cortex. These findings demonstrate that nitrogen mustard-induced granulocytopenia is associated with suppression of the injurious effects of endotoxin upon the stimulated adrenal cortex, and resemble the effect of granulocytopenia upon the Shwartzman phenomenon (23, 24).

TABLE II
Effect of Nitrogen Mustard Induced Leucopenia on the Production of Adrenal Hemorrhage

Total WBC/mm ³	Platelets, mm ³	Adrenal hemorrhage	
		ACTH-endotoxin*	Thorotrast-endotoxin†
1000	381,000	0	
1100	413,000	0	
1200	199,000	0	
1627	1,064,000	0	
1800	501,000	0	
2500	454,000	+	
575	201,000		0
700	97,000		0
1015	162,000		0
1797	236,000		0
2000	343,000		0
2300	526,000		+

* 20 u. ACTH intravenously followed 4 hours later by 40 µg endotoxin intravenously.

† 10 ml thorotrast followed 4 hours later by 20 µg endotoxin intravenously.

DISCUSSION

Specific localization of hemorrhagic necrosis to the adrenal gland during endotoxemia has not been previously described. Reasons for the selective induction of a hemorrhagic reaction in the adrenal cortex by endotoxin are partly provided by the experiments reported here.

Corticosteroid and adrenergic substances elaborated by the adrenal gland undoubtedly affect the biological action of endotoxin (6, 12). Various adrenergic and catechol amine-like substances as well as cortisol are increased in the blood following injection of endotoxin (8, 13, 25, 26). The importance of these adrenal substances in the pathogenesis of the injurious action of endotoxin, however, has not been clearly defined (27). In addition, the protective action of these products of the adrenal gland in endotoxemia is not understood, but adrenalectomy increases markedly the susceptibility of experimental animals to death from endotoxin (28). Administration of adrenergic substances or corticosteroids,

however, have variable but interesting effects upon endotoxin action (7, 10, 29-31).

The peripheral blood vessels are sensitized to the vasoactive effects of epinephrine (32), and epinephrine can prepare the skin locally for development of hemorrhagic necrosis, following intravenous inoculation of endotoxin (11). Active production of catechol amines in the adrenal medulla, therefore, might result in injury to the adrenal gland following injection of endotoxin. No significant lesions have been observed in the adrenal medulla, however, in association with endotoxemia and none were seen in the studies reported here. It seems unlikely, therefore, that the elaboration of adrenergic vasoactive substances played a significant role in the adrenal cortical hemorrhagic-necrosis. This conclusion was further supported by the relative ineffectiveness of alpha and beta adrenergic inhibitors in suppressing the hemorrhagic adrenal cortical reaction. Nevertheless, it is important to indicate that adrenergic blockers do not always inhibit the effects of endotoxin (27), and the role of vascular injury produced by endotoxin in the development of adrenal hemorrhage is not known.

Corticosteroids in large doses given at the appropriate time before or simultaneous with endotoxin may prevent death (31). On the other hand, corticosteroid may enable a single intravenous injection of endotoxin to induce bilateral renal cortical necrosis (10). Similarly, corticosteroid variably affects the pyrogenic effects of endotoxin (30). It is evident, therefore, that adrenal cortical hormone may enhance or suppress the injurious effects of endotoxin, depending upon the effect under study, the dose of the corticosteroid, and the time of its injection. For example, adrenal cortical hormone may affect a single action of endotoxin differently, depending upon the timing of injection of hormone and toxin, as in the local Shwartzman reaction (9, 10).

It is not surprising, therefore, that the adrenal cortical hemorrhage produced during endotoxemia depends upon the phase of adrenocortical activity. In each of the models employed, whether thorotrast, ACTH, or endotoxin was used to stimulate the adrenal cortex, endotoxin induced hemorrhage in the gland only if administered when there was evidence of active corticosteroid production. The specific function of the adrenal cortex in elaborating corticosteroid may be responsible for sensitization of the gland to hemorrhage during endotoxemia. It is also possible, however, that the hypermetabolic state of the organ, rather than its specific relationship to corticosteroid production, is of greatest importance in this reaction. If the latter suggestion were correct hemorrhagic necrosis of other hypermetabolic tissues might also be expected in the presence of endotoxemia. Preliminary experiments in which the thyroid gland of rabbits was stimulated with thyrotropin and endotoxin was subsequently injected intravenously, however, did not show thyroid hemorrhage. Although this experiment failed to demonstrate an increased susceptibility of the stimulated thyroid to hemorrhage by endotoxemia, further studies are required to explore the possibility

that hypermetabolic tissues may be hypersusceptible to the injurious effects of endotoxin. The placenta and sarcomata, both hypermetabolic tissues, also are susceptible to hemorrhagic reactions caused by endotoxin (1, 2). The findings presented, however, are consistent with the interpretation that localization of hemorrhagic necrosis to the adrenal cortex during endotoxemia is attributable to production of corticosteroid by the adrenal gland. Corticosteroid may sensitize tissues at the site of synthesis to the injurious effects of endotoxin as it also enables preparation of rabbits for the local and generalized Shwartzman reaction (10). Preliminary experiments, however, have shown that injection of cortisone into the skin does not prepare for local hemorrhage.

The cortisol levels of blood were the same after administration of thorostrast, endotoxin, or ACTH, but the hemorrhagic cortical reaction to endotoxin was often most intense after preparation with thorostrast. Thorostrast may have this effect because it not only stimulates the adrenal cortex but increases the injurious effects of endotoxin by interference with reticuloendothelial function (24).

There are similarities between localization of hemorrhagic necrosis to the adrenal during endotoxemia and the Shwartzman reaction. Both are characterized by hemorrhage and granulocytic infiltration. The inability to demonstrate vascular thrombosis in the adrenals, and the failure of heparin to prevent hemorrhage in the adrenal, however, illustrate certain differences from the Shwartzman reaction (22, 33). Clotting may or may not be involved in the adrenal hemorrhagic reaction. If coagulation is involved it may not be specifically prevented by heparin as an anticoagulant.

Preparation of rabbits with thorostrast followed by endotoxin injection resulted not only in adrenal hemorrhage, but when the interval between the thorostrast and endotoxin administration was greater than 10 hours, renal cortical lesions typical of the generalized Shwartzman reaction were also produced. Renal cortical lesions were not observed, however, when ACTH was given as the preparative material followed by administration of endotoxin irrespective of the interval between injections. These findings further suggest that the pathogenesis of the adrenal hemorrhagic necrosis differs from that of the Shwartzman reaction. Alterations in blood platelets and the coagulation mechanism after administration of endotoxin to ACTH prepared animals, did not resemble the profound changes in animals prepared with thorostrast or prior endotoxin inoculation (34). These observations, to be described in detail in a subsequent report, further indicate a difference in the pathogenesis of adrenal hemorrhage and the Shwartzman reaction produced by endotoxin.

Neither the Shwartzman reaction (23, 24) nor adrenal hemorrhagic necrosis develop in agranulocytic animals. There is increasing evidence implicating leucocytes in the tissue damaging effects of endotoxin, mediated in part by lysosomes of the granulocytes (35). Granulocytes were often seen in the adrenals of animals developing cortical hemorrhage during endotoxemia, and the sup-

pressive effect of granulocytopenia on the reaction may further indicate the importance of these cells in mediation of the biological activity of endotoxin.

Many of the effects of endotoxin are now considered to be attributable to immunological reactions (36), and the Shwartzman phenomenon can be provoked by antigen-antibody reactions as well as with endotoxin (37). It is possible, therefore, that the adrenal hemorrhage is also mediated by an immunological reaction. Studies to be reported separately have shown that specific immunological reactions in rabbits prepared with thorotrast can induce adrenal cortical hemorrhage comparable to that shown with endotoxin.

It has been previously suspected but not shown that endotoxin may be responsible for the Waterhouse-Friderichsen syndrome seen occasionally during sepsis and characterized by adrenal cortical hemorrhage and shock (4). Clinically, adrenal hemorrhage during sepsis has been described principally in young patients dying fulminantly with meningococemia (38, 39). It is almost axiomatic that if the Waterhouse-Friderichsen syndrome does not develop during the first few hours of sepsis it will not develop at all. This critical importance of the interval between onset of infection and onset of adrenal hemorrhage during sepsis corresponds closely to the interval required between stimulation of the adrenal cortex and administration of endotoxin to demonstrate adrenal hemorrhage experimentally.

Adrenal hemorrhage in the Waterhouse-Friderichsen syndrome is often confined to the cortex, particularly to the fascicular or midzone (40, 41), the area stimulated by adrenocorticotrophic hormone. This corresponds to the location of the hemorrhagic reaction induced with endotoxin described in these experiments. It might be presumed, therefore, that when significant clinical sepsis develops within a few hours after stimulation of the adrenal cortex by the onset of infection, adrenal cortical hemorrhage might ensue. The ability to suppress somewhat the adrenal hemorrhagic reaction by treatment of rabbits with large doses of corticosteroids after preparation of the animals with ACTH or thorotrast, but before injection of endotoxin, suggests that corticosteroids might be useful in preventing progressive development of the adrenal hemorrhage in patients with sepsis. This possibility should be reexamined.

Adrenal cortical insufficiency has not been described following recovery from meningococemia. In view of the findings reported, it seems likely that adrenal hemorrhage may develop during fulminant sepsis more commonly than is appreciated. In most instances, however, the adrenal hemorrhage is probably focal and sufficient functional adrenal cortex remains to prevent the development of adrenal insufficiency.

SUMMARY AND CONCLUSIONS

An experimental model that produces adrenal cortical hemorrhage with endotoxin has been described. When stimulated by thorotrast, endotoxin, or its tropic hormone (ACTH), the adrenal cortex is susceptible to the development

of a hemorrhagic reaction during endotoxemia. The hemorrhagic reaction resembles that described in the Waterhouse-Friderichsen syndrome.

A pathophysiologic mechanism for the occurrence of adrenal hemorrhage occurring during acute sepsis is presented. Increased metabolic activity associated with the production of corticosteroids seems to make the adrenal cortex susceptible to endotoxin-induced hemorrhage. Adrenal hemorrhage observed during sepsis, as in the Waterhouse-Friderichsen syndrome, may be attributable to endotoxemia occurring during or shortly after stimulation of the adrenal cortex by infection.

Significant differences between adrenal cortical hemorrhage and the Schwartzman phenomenon are described.

The authors wish to express their appreciation to Dr. David Seligson, Director of Laboratories, Yale-New Haven Medical Center, for carrying out the blood cortisol determinations, and to Miss Carol Ross for her excellent technical assistance.

BIBLIOGRAPHY

1. Nauts, H. C., Swift, W. E., and Coley, B. L. The treatment of malignant tumors by bacterial toxins as developed by the late William B. Coley, M.D., Reviewed in the light of modern research, *Cancer Research* 1946, **6**, 205.
2. Rieder, R. F., and Thomas, L., Studies on the mechanisms involved in the production of abortion by endotoxin, *J. Immunol.*, 1960, **84**, 189.
3. Hardaway, R. M., and Johnson, D., Clotting mechanism in endotoxin shock, *Arch. Int. Med.*, 1963, **112**, 775.
4. Schwartzman, G., Phenomenon of Local Tissue Reactivity, New York, Paul B. Hoeber, Inc., 1937.
5. Thomas, L., The physiological disturbances produced by endotoxin, *Ann. Rev. Physiol.*, 1954, **16**, 467.
6. Spink, W. W., Endotoxin shock, *Ann. Int. Med.*, 1962, **57**, 538.
7. Thomas, L., Physiologic and pathologic alterations produced by the endotoxins of Gram-negative bacteria, *Arch. Int. Med.*, 1958, **101**, 452.
8. Raskova, H., and Vanecek, J., Pharmacology of bacterial toxins, *Pharmacol. Rev.*, 1964, **16**, 1.
9. Schwartzman, G., Schneierman, S. S., and Soffer, L. J., Suppression of the phenomenon of local tissue reactivity by ACTH, cortisone, and sodium salicylate, *Proc. Soc. Exp. Biol. and Med.*, 1950, **75**, 175.
10. Thomas, L., and Good, R. A., The effect of cortisone on the Schwartzman reaction. The production of lesions resembling the dermal and generalized Schwartzman reactions by a single injection of bacterial toxin in cortisone-treated rabbits, *J. Exp. Med.*, 1952, **95**, 409.
11. Thomas, L., The role of epinephrine in the reactions produced by the endotoxins of Gram-negative bacteria. I. Hemorrhagic necrosis produced by epinephrine in the skin of endotoxin-treated rabbits, *J. Exp. Med.*, 1956, **104**, 865.
12. Zweifach, B. W., Functional Behavior of the Microcirculation, Springfield, Illinois, Charles C. Thomas, 1961.

13. Egdahl, R. H., The differential response of the adrenal cortex and medulla to bacterial endotoxin, *J. Clin. Inv.*, 1959, **38**, 1120.
14. Thorn, G. W. Adrenal cortex, in *Textbook of Medicine (Cecil-Loeb)*, P. B. Beeson, and W. McDermott, editors, Philadelphia, W. B. Saunders Co., 1963, 1393.
15. Mitchell, N., and Angrist, A., Focal necrosis of the adrenal cortex, *Am. J. Med. Sc.*, 1943, **205**, 549.
16. Voelcker, A. F., Report of the pathologists, in *Reports of the Registrars, The Middlesex Hospital*, 1894, 246.
17. De Moor, P., Steeno O., Raskin, M., and Hendrix, A., Fluorimetric determination of free plasma 11-hydroxycorticosteroids in man, *Acta Endocrinol.* 1960, **33**, 297.
18. Jackson, D. P., Hartmann, R. C., and Busby, T., Fibrinogenopenia complicating pregnancy, *Obstet. and Gynecol.*, **5**, 233 1955.
19. Black-Shaffer, B., Hiebert, T. G., and Kerby, G. P., Experimental study of purpuric meningococcemia in relation to the Shwartzman phenomenon, *Arch. Path.* 1947, **43**, 28.
20. Gerber, I. E., The Shwartzman phenomenon in the kidneys of rabbits, *Arch. Path.* 1936, **21**, 776.
21. Cluff, L. E., and Berthrong, M., The inhibition of the local Shwartzman reaction by heparin, *Bull. Johns Hopkins Hosp.*, 1953, **92**, 353.
22. Good, R. A., and Thomas, L. Studies on the generalized Shwartzman reaction. IV. Prevention of the local and generalized Shwartzman reactions with heparin, *J. Exp. Med.* 1953, **97**, 871.
23. Stetson, C. A., and Good, R. A., Studies on the mechanism of the Shwartzman phenomenon. Evidence for the participation of polymorphonuclear leucocytes the phenomenon, *J. Exp. Med.*, 1951, **93**, 49.
24. Good, R. A., and Thomas, L., Studies on the generalized Shwartzman reaction. II. The production of bilateral cortical necrosis of the kidneys by a single injection of bacterial toxin in rabbits previously treated with thorotrast or trypan blue, *J. Exp. Med.*, 1952, **96**, 625.
25. Weil, M. H., and Spink, W. W., A comparison of shock due to endotoxin with anaphylactic shock, *J. Lab. and Clin. Med.*, 1957, **50**, 501.
26. Davis, R. B., Meeker, W. R., Jr., and Bailey, W. L., Serotonin release by bacterial endotoxin, *Proc. Soc. Exp. Biol. and Med.*, 1961, **108**, 774.
27. Zweifach, B. W., Vascular effects of bacterial endotoxin, in *Bacterial Endotoxins*, (M. Landy and W. Braun, editors), New Brunswick, Rutgers University Press, 1964.
28. Hartmann, F. A., and Scott, W. J. M. The protection of adrenalectomized animals against bacterial endotoxin by extract of adrenal cortex, *J. Exp. Med.* 1932, **55**, 63.
29. Borden, C. W., Hall, W. H., and Gold, D., A study of experimental shock produced by meningococcus toxin, *J. Lab. and Clin. Med.*, 1953, **42**, 787.
30. Bennett, I. L., Jr., and Beeson, P. B., The effect of cortisone upon reactions of

- rabbits to bacterial endotoxins with particular reference to acquired resistance, *Bull. Johns Hopkins Hosp.*, 1953, **93**, 290.
31. Spink, W. W., and Anderson, D., Experimental studies on the significance of endotoxin in the pathogenesis of brucellosis, *J. Clin. Inv.*, 1954, **33**, 540.
 32. Zweifach, B. W., Nagler, A. L., and Thomas, L., The role of epinephrine in the reactions produced by the endotoxins of Gram-negative bacteria. II. The changes produced by endotoxin in the vascular reactivity to epinephrine, in the rat mesoappendix and the isolated, perfused rabbit ear, *J. Exp. Med.*, 1956, **104**, 881.
 33. Thomas, L., and Good, R. A., Studies on the generalized Shwartzman reaction. I. General observations concerning the phenomenon, *J. Exp. Med.*, 1952, **96**, 605.
 34. Levin, J., and Beck, E., A reappraisal of the role of blood coagulation and platelets in the generalized Shwartzman phenomenon, in preparation.
 35. Thomas, L., *Ciba Found. Symp. Lysosomes*, 1963, 382.
 36. Watson, D. W., and Kim, Y. B., Modification of host responses to bacterial endotoxins. I. Specificity of pyrogenic tolerance and the role of hypersensitivity in pyrogenicity, lethality, and skin reactivity, *J. Exp. Med.* 1964, **118**, 425.
 37. Lee, L. Antigen-antibody reaction in the pathogenesis of bilateral renal cortical necrosis, *J. Exp. Med.*, 1963, **117**, 365.
 38. Friderichsen, C., Nebennierenapoplexie bei kleinen Kindern, *Jahrb. Kinderheilk.*, 1918, **87**, 109.
 39. Lindsay, J. W., Rice, E. C., Selinger, M. A., and Robins, L., The Waterhouse-Friderichsen syndrome. Acute bilateral suprarenal hemorrhage. *Am. J. Med. Sc.*, 1941, **201**, 263.
 40. Aegerter, E. E., The Waterhouse-Friderichsen syndrome, *J. Am. Med. Assn.*, 1936, **106**, 1715.
 41. Mitchell, N., and Angrist, A. Focal necrosis of the adrenal cortex, *Am. J. Med. Sc.*, 1943, **205**, 549.

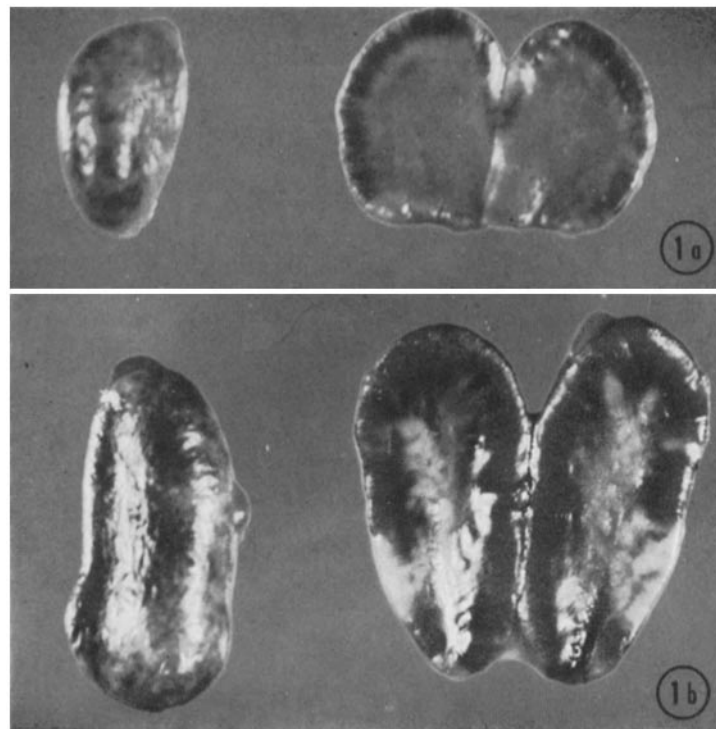
EXPLANATION OF PLATES

PLATE 19

FIGS. 1 *a* and 1 *b*. Hemorrhagic reaction in adrenal cortex of rabbits given 10 ml thorotrast intravenously followed 4 hours later by 40 μ g endotoxin intravenously.

FIG. 1 *a*. Hemorrhage involving midzone of adrenal cortex. \times 5.

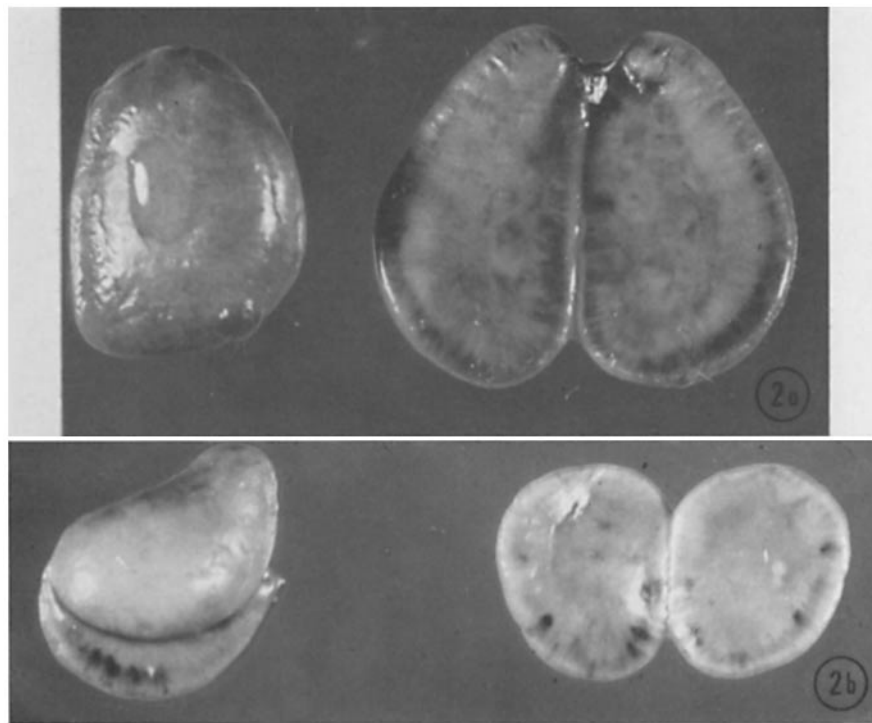
FIG. 1 *b*. Massive hemorrhage involving entire adrenal cortex. \times 7.



(Levin and Cluff: Endotoxemia and adrenal hemorrhage)

PLATE 20

FIGS. 2 *a* and 2 *b*. Hemorrhagic reaction in adrenal cortex of rabbits given 20 u.
ACTH intravenously followed 4 hours later by 40 μ g endotoxin intravenously.
FIG. 2 *a*. Hemorrhage involving midzone of adrenal cortex. \times 7.
FIG. 2 *b*. Focal hemorrhage involving midzone of adrenal cortex. \times 5.



(Levin and Cluff: Endotoxemia and adrenal hemorrhage)

PLATE 21

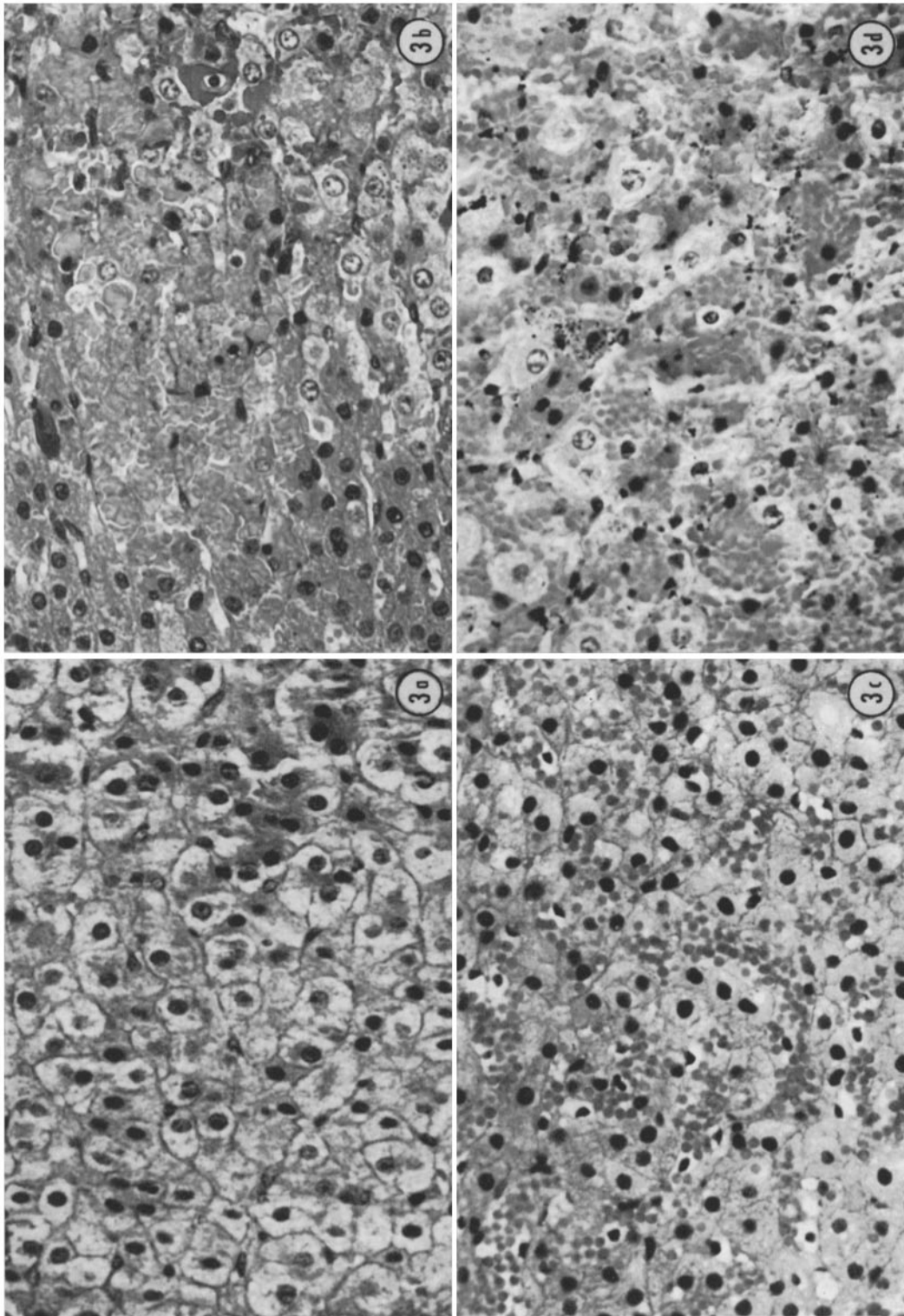
FIGS. 3 *a* to 3 *d*. Histopathologic lesions in adrenal cortex. \times 400.

FIG. 3 *a*. Normal adrenal—fascicular zone.

FIG. 3 *b*. Hemorrhagic necrosis of fascicular zone in rabbit given 10 ml thorotrast intravenously followed 4 hours later by 40 μ g endotoxin intravenously.

FIG. 3 *c*. Hemorrhage of fascicular zone in rabbit given 40 μ g endotoxin intravenously followed 4 hours later by 100 μ g endotoxin intravenously.

FIG. 3 *d*. Hemorrhagic necrosis of fascicular zone in rabbit given 20 u. ACTH intravenously followed 4 hours later by 40 μ g endotoxin intravenously.



(Levin and Cluff: Endotoxemia and adrenal hemorrhage)