

## HOMOLOGOUS DISEASE IN THE ADULT RAT, A MODEL FOR AUTOIMMUNE DISEASE

### II. FINDINGS IN THE JOINTS, HEART, AND OTHER TISSUES\*,†

BY PETER STASTNY,§ M.D., VERNIE A. STEMBRIDGE, M.D.,  
THOMAS VISCHER,§ M.D., AND MORRIS ZIFF, M.D.

(From the Department of Internal Medicine, Rheumatic Diseases Unit, and the  
Department of Pathology, The University of Texas Southwestern  
Medical School, Dallas)

PLATES 43 TO 51

(Received for publication, May 10, 1965)

In previous reports, homologous disease in the adult rat has been presented as a model for autoimmune disease in man. In preliminary reports, (1, 2) the polyarthritis, cardiac lesions, and changes in the skin observed in this condition have been reported. The cutaneous lesions (3) have been described in detail and evidence presented that they have an immunologic basis. The present paper deals with the findings in the joints, heart, kidney, and reticuloendothelial system. In the joints, an acute migratory polyarthritis and in the heart a high incidence of valvular and myocardial inflammatory lesions have been observed. In view of the fact that the animal with homologous disease contains lymphoid cells capable of reacting with host antigens, and therefore resembles a host with abnormally reactive lymphoid cells, these changes together with the skin lesions observed appear to be of particular significance.

That homologous disease may be a model for human autoimmune disease has been previously postulated by Oliner, Schwartz, and Dameshek (4). These authors have investigated the hematologic changes in this condition.

#### *Method*

*Production of Homologous Disease.*—As previously described (3), homologous disease was produced in tolerant adult rats of the Sprague-Dawley strain (George Holtzman and Sons, Houston, Texas; Charles River Breeding Laboratories, Inc., Wilmington, Massachusetts) and an inbred Fischer strain (Charles River) by 3 intravenous injections of lymphoid cells from the inbred Fischer strain or an inbred strain of Lewis rats (Microbiological Associates, Bethesda, Maryland).

\* This work was supported by Grants AM-02071 and AM-05154 from the National Institute of Arthritis and Metabolic Diseases.

† Presented in part at the Annual Meeting of the American Rheumatism Association, San Francisco, California; June 19, 1964.

§ Trainee in Arthritis, National Institute of Arthritis and Metabolic Diseases.

*Histologic Studies.*—Autopsies were performed at various times following the third injection of lymphoid cells. In some cases, this was done shortly after the first appearance of joint symptoms, and in others when severe skin lesions or marked wasting had occurred.

All tissues were fixed in neutral-buffered formalin, imbedded in paraplast, sectioned at  $5\mu$  and stained with hematoxylin and eosin. Joints were formalin-fixed, and decalcified prior to processing. Hearts were transversely sectioned in serial fashion; the entire myocardium and valvular structures were examined. Kidney sections were stained with PAS and alcian blue in addition to hematoxylin-eosin.

*Cultural Studies.*—Routine cultures for pyogens were taken in thioglycollate broth, sheep blood agar, trypticase soy agar, and trypticase soy broth. Cultures of joints and hearts for pleuropneumonia-like organisms (PPLO) were carried out by Dr. John R. Ward of the University of Utah College of Medicine. Most cultures were made on specimens frozen with dry ice, and processed in Dr. Ward's laboratory within 24 to 48 hours after autopsy. In these cultures, the entire joint was usually homogenized and inoculated in the culture medium. In some cases, the joints were opened immediately following sacrifice of the animal and the intra-articular tissues excised, minced, and added to liquid culture medium. When the hearts were cultured, they were divided into left and right portions, each of which was cut into three parts: one for culture, one for routine histologic examination of serial sections of the cultured tissue, and one frozen for future investigation. For culture a sample for each heart was placed directly in broth, and another frozen prior to inoculation into the culture medium.

Six different media for PPLO were used: (a) bacto-PPLO agar with 20 per cent human ascitic fluid; (b) bacto-PPLO agar with 1 per cent bacto-PPLO seum fraction; (c) bacto-PPLO agar with 5 per cent human blood and 20 per cent human ascitic fluid; (d) bacto-PPLO enrichment broth with 20 per cent human ascitic fluid; (e) Kleiueberger-Nobel PPLO agar (bacto-agar with 0.5 per cent yeast extract,  $20\mu\text{g}/\text{ml}$ ; thymus nucleic acid and 20 per cent human ascitic fluid; (f) Kleiueberger-Nobel PPLO broth [small layer of PPLO agar with 20 per cent human ascitic fluid overlaid with difco PPLO broth containing yeast extract, nucleic acid, and ascitic fluid in same proportions as in (e)]. In addition, egg embryos were inoculated in the yolk sac, amniotic cavity, allantoic cavity, and chlorioallantoic membrane.

## RESULTS

*Polyarthritis.*—This was observed in 39 of 70 animals with homologous disease (Table I), the incidence varying in different experimental groups. Polyarthritis was not noted in any of 43 controls, consisting of 11 non-tolerant recipients of live cells, 8 tolerant recipients of frozen and thawed cells, and 24 tolerant recipients who had received no subsequent injections of lymphoid cells. The joint involvement was transient and migratory, and was characterized clinically by overt swelling and erythema.

The time of onset of arthritis varied from 12 to 40 days after the first injection of lymphoid cells. The acute symptoms in any given joint lasted from 2 to 4 days. Following disappearance of the erythema and swelling, there often remained slight residual thickening of the periarticular soft tissue, although there appeared to be no obvious disability or limitation of joint motion. The duration of the entire episode of polyarthritis in any given animal varied between 4 and 15 days; as few as 1, but as many as 9 joints were observed in a single animal. Certain clinical features of the arthritis, such as duration and number of joints involved, are based on observations in 14 animals who were not sacrificed. The

remaining 25 (Table I) were sacrificed to carry out histologic and microbiologic examinations of actively involved joints.

Histologically, the arthritis was characterized at its peak by an intense mononuclear inflammatory reaction involving the synovial membrane and adjacent connective tissues. The earliest detectable change was a dilatation and congestion of blood vessels, especially capillaries, in the soft tissues of the joint. This was accompanied by edema and often by a joint effusion. There followed an increasing mononuclear infiltration of the soft tissues around the joint, including the capsule, consisting of histiocytes, lymphocytes and plasma-like cells<sup>1</sup> (Fig. 1). These changes were accompanied in many instances by a prominent fibrinoid degeneration (Fig. 2). Rarely, the inflammatory reaction was of sufficient intensity to include adjacent muscle, and in few instances involved

TABLE I  
*Polyarthritis in Adult Rat with Homologous Disease*

Group	Recipient strain	Tolerant of	No. of recipients	Incidence of arthritis
1	sD	L	29	16
2	SD	L	6	2
3	F	L	8	3
4	L	F	9	4
5	F	L	18	14
Total . . . . .			70	39

Abbreviations: D, Sprague-Dawley; F, Fischer; L, Lewis.

thick walled blood vessels. Associated with the inflammatory infiltrate, there occurred a proliferation of synovial cells (Fig. 3). This was followed by an increase in capillary and fibroblastic proliferation. Occasionally the proliferating tissue protruded into the joint cavity. Mild to moderate erosion of cartilage was often present, and most animals showed a mild periosteal reaction along the shaft of the bone. Regression was characterized by a decrease in the numbers of mononuclear cells, and eventually by replacement with dense fibrocollagenous tissue (Fig. 4). In some instances, complete resolution of the entire process occurred. It is of interest that when lesions were present simultaneously in both joints and skin in some animals, tissue infiltrates in the synovium and dermis were comparable in histologic appearance.

Culture of 25 joints in 17 animals (Table III) for pyogens and PPLO were carried out by Dr. John Ward. The cultures for PPLO, as described above, in-

<sup>1</sup>The term plasma-like cells has been used in this paper to designate cells resembling plasma cells but often differing from the typical mature plasma cell in respect to the amount of cytoplasm or the density of the nuclear chromatin. The nomenclature and identification of such cells has been discussed by several authors (5, 6).

cluded inoculation of 6 different media and inoculation of egg embryos. These yielded no growth.

*Findings in the Heart.*—Histologic changes were noted in all of 21 hearts which were serially sectioned *in toto*. (Table II).

Changes were seen in the valves, myocardium, and epicardium. Myocardial changes were observed in all animals examined, and valvulitis was seen in 15 of 21 (Table II). Most commonly involved was the mitral valve, but changes were also seen in the aortic, pulmonary, and tricuspid valves. The earliest lesion in the valves was focal edema which became progressively more diffuse, eventually to be supplanted by a chronic inflammatory reaction (Fig. 5). The in-

TABLE II  
*Valvulitis and Myocarditis in Homologous Disease*

Lesion	None	Mild	Moderate to severe
Myocarditis.....	0	7	14
Valvulitis.....	6	5	10

TABLE III  
*Results of Culture of Joint and Heart Tissue for Pyogens and PPLO*

Tissue	No. cultures	No. rats	No. positive for bacteria	No. positive for PPLO
Joint.....	25	17	0/22	0/25
Heart.....	22	17	1/22*	0/22

\* Staphylococcus, presumably contaminant.

flammatory cells were chiefly lymphocytes, macrophages, and plasma cells. Ultimately, fibrosis was observed.

The myocardium was involved principally at the root of the mitral and aortic valves. The inflammation was mononuclear in type, tending to be relatively uniform in character, some infiltrates being composed mainly of plasma-like cells and histiocytes (Fig. 6), while others consisted mainly of lymphocytes. Later, edema and/or capillary and fibroblastic proliferation with subsequent fibrosis were present (Fig. 7). In an occasional instance, a modest number of polymorphonuclear cells was observed. In a few hearts, the chronic inflammatory infiltrate was generalized in the myocardium (Fig. 8), but this was always of lesser intensity than the focal lesions. In these cases, edema of the myocardium and mild degeneration of muscle fibers was present. Atria and auricular appendages were also the site of inflammation and edema (Fig. 9). The epicardium, especially at the root of the major vessels, demonstrated edema, inflammation and serous atrophy of the fat. In 2 hearts, vasculitis was

present in this region, while in a third, a pronounced necrotizing arteritis with fibrinoid change was seen in a coronary artery (Fig. 10).

Culture of 22 samples of heart tissue from 17 animals for pyogens yielded growth of a staphylococcus in one sample (Table III). This may have been a contaminant. Cultures for PPLO were negative in all cases.

*Histologic Changes in the Lymph Nodes.*—In control animals injected with frozen and thawed homologous lymphoid cells, the architecture of the lymph nodes was preserved, showing a definite follicular and sinusoidal pattern. The follicles contained proliferating reticulum cells and lymphoblasts maturing to lymphocytes. Sinusoids were lined by endothelial cells and reticulum cells. There were abundant lymphocytes with occasional plasma cells and reticulum cells within the stroma.

In the animals with homologous disease, the changes could be divided into three stages. These appeared to be related to the duration of the homologous disease and its intensity, especially the time of death or sacrifice. They were also correlated with the presence or absence of polyarthritis, although no correlation could be made with the presence of cardiac involvement, because this change occurred to a greater or lesser degree in all animals in which the hearts were examined microscopically. In a first group, consisting of 6 animals dying or sacrificed between 1 and 21 days after the third injection, the lymph nodes were characterized by a diminution in the size and number of the follicles and an increased prominence of the sinusoidal architecture and its associated cells. Arthritis was present in only 1 of 6 of this group. In the most severely ill animals, there was complete loss of follicular pattern, and the nodal architecture was replaced by a large number of histiocytes and lymphocytes with occasional plasma cells (Fig. 11).

In a second group, sacrificed between 16 and 21 days after the third injection, the nodes were enlarged, nodal architecture was absent, and there was almost complete replacement by plasma-like cells with varying numbers of histiocytes (Fig. 12). Animals in this group had florid disease characterized by dermatitis, arthritis, and cardiac involvement. Arthritis, demonstrated both clinically and histologically, was present in 7 of 8 animals examined.

In the third group, dying between 24 and 27 days, the nodes were decreased in size with absence of the usual architecture, and the sinusoidal areas showed an increase in fibrous tissue with moderate numbers of lymphocytes and histiocytes, and decreased numbers of plasma cells. One of 4 of this group had arthritis at the time of autopsy.

*Histologic Changes in the Spleen.*—In the spleen, the histologic changes were similar to those seen in the lymph nodes. Both the follicular and sinusoidal systems were affected. When the follicles were involved, there was progressive loss of lymphocytes, progressing to complete disappearance of the follicle. Simultaneous with these changes, there was a relative increase in reticulum

cells, which on occasion reached such proportions as to replace the follicles completely (Fig. 13). Within the sinusoids, similar reticulum cell proliferation was observed with some of the cells showing an eosinophilic cytoplasm and in most instances, there was an associated increase in plasma-like cells (Fig. 14). On occasion large hemosiderin deposits were seen. In many instances, there was a partial to complete loss of megakaryocytes. In more advanced stages, fibrosis was observed, which sometimes completely obliterated the sinusoidal architecture (Fig. 15). Focal areas of necrosis were present in a few animals, which on occasion had the appearance of amyloid (Fig. 16).

*Thymus.*—Both cortex and medulla were involved. Initially the medulla showed a prominent increase in vacuolated, eosinophilic reticular cells. Numerous, scattered smaller cells including thymocytes and plasma-like cells were also present (Fig. 17). Later the cortex was in most cases markedly involuted. The capsule ordinarily demonstrated numerous granular cells, and on occasion both eosinophils and mast cells were present. Rarely, loose to dense fibroblastic proliferation was seen within the medulla.

*Liver.*—In the gross, the livers showed no significant change. Microscopically, some were normal, but others had a mild periportal mononuclear infiltration. In a few instances, Kupffer cells were prominent and a diffuse lymphocytosis was present. Occasionally, central lobular congestion leading to degeneration and atrophy, was seen which, rarely, progressed to focal central necrosis.

*Kidney.*—The most consistent change was an interstitial inflammatory reaction observed in 19 of 56 animals. The infiltrate was composed of lymphocytes, histiocytes, and occasional plasma cells, and was usually perivascular in location (Fig. 18). It was most commonly seen in the medulla, although the cortex was also occasionally involved. Less frequently encountered was a mild focal nodular thickening of the glomerular basement membrane, sometimes unassociated with the perivascular inflammatory reaction. Rarely, a glomerulus demonstrated an alterative glomerulitis similar to the non-specific glomerular reactions observed in humans having a systemic disease. Non-specific tubular degeneration was also present.

#### DISCUSSION

In previous reports, involvement of a number of organ systems has been demonstrated in homologous disease (1-3, 7-12). These have included the blood, skin, lymphatic system, liver, intestine, and pancreas. In the case of the blood (7, 11, 12) and skin (3, 9) it has been demonstrated that these alterations are the consequence of an immunologic reaction of the graft against the host. In addition to the organ involvement listed, striking changes in the joints and heart have been observed (1, 2, 13). These are described here in detail. Myocardial and joint lesions have also been noted recently in rats with homologous disease by Aisenberg, Wilkes, and Waksman (14).

The arthritis noted in the present experiments was migratory and transient in nature, and tended to be moderate in severity. Only mild residual changes remained in affected joints. The possibility that the arthritis was produced by PPLO organisms has been rendered unlikely by the negative cultural studies reported. Also different from the arthritis produced by PPLO (15), was the clinical course and the histologic appearance of the changes noted. In contrast to the long duration of PPLO arthritis and the residual deformity, including destructive changes and frequently ankylosis, the transient arthritis of homologous disease produced only occasional mild erosion of cartilage. The mononuclear reaction seen in homologous disease contrasted strongly with the acute, polymorphonuclear type of synovitis, often accompanied by microabscesses, usually seen in PPLO arthritis. Where predominantly mononuclear infiltration has been observed in PPLO arthritis (16), this occurred only after a period of several weeks, when the initial suppurative phase of the infection had subsided (17).

It was not possible to estimate the time of onset of the cardiac lesions in relation to the other changes of homologous disease because most animals were autopsied at the time the arthritis became manifest. Impressive, however, was the finding that all animals autopsied had cardiac lesions. These too, were mononuclear in character. Changes were more frequent in the myocardium than in the valves, and were frequently noted at the root of a valve when the valve itself was not involved. It is of interest that a number of animals showed vascular inflammatory reactions in the heart.

The changes in the lymphoid tissue could be divided into 3 stages. In the first, there was a progressive loss of follicular architecture with increased prominence of the sinusoids. The second stage was characterized by the presence of increased numbers of plasma-like cells and histiocytes. The latter changes were manifested grossly by enlargement of the lymph nodes and spleen. The time at which the response of the plasma-like cells was at its maximum, *i.e.* 2 to 3 weeks after the last injection of lymphoid cells, corresponded with the development of the most florid phase of the disease when cardiac involvement, dermatitis and arthritis were usually present. The last stage was characterized by atrophy and fibrosis; arthritis was infrequent and skin lesions tended to be chronic at this time.

Evidence has been previously presented for an immunologic basis for the skin lesions present in these animals (3). It appears reasonable to assume that the striking abnormalities in the joints and heart may also have an immunologic basis. They appeared at approximately the same time as the skin lesions in those animals in whom both were present. At this time, also, the lymph nodes and spleen showed their maximal cellular response. Histologically, the lesions in joints and heart were mononuclear in character, and resembled those seen in the skin. No other basis, such as infection with known agents, has been demon-

strated. Thus, there appears to be considerable evidence to suggest that the joint and cardiac changes are immunologically determined, and may depend on histoincompatibility differences of the type involved in the skin response.

Recently, the participation of factors other than the graft-*versus*-host reaction in the wasting of homologous disease has come under consideration. Marked wasting has occurred in a high percentage of neonatally thymectomized animals (18-21) and in young mice treated with steroids (22), and sterile bacterial vaccines (23). This has been attributed to a reduction in critical mass of lymphoid cells, as observed after thymectomy (24) and following administration of steroid (22) or bacterial vaccine (23). Wasting has also been observed in neonatal mice following injection of spleen cells contaminated with *Salmonella* (25).

Recently, Wilson, Sjodin, and Bealmear (26) have noted the absence of wasting in thymectomized germ free animals. This observation has focused attention on the role of infection in the wasting seen in homologous disease. The recent observation of McIntire, Sell, and Miller (27) that wasting occurs with the graft-*versus*-host reaction even in the germ-free animal indicates, however, that bacterial infection need not be present in order to develop the wasting seen in this condition.

Although homologous disease has been reproduced in the germ-free animal, one cannot rule out the possibility that the joint and heart lesions here reported are the result of a process other than the graft-*versus*-host reaction. Though available evidence indicates that transplantation antigens are probably responsible for the skin lesions in this condition (3), hypersensitivity to an infectious agent must for the following reasons be considered as a possible alternative mechanism for development of the joint and cardiac lesions. The animal with homologous disease is known to have a reduced immune response (28) and may, therefore, be subject to infection, although surprisingly, this has so far not been demonstrated in a number of bacteriological studies (29, 30) as well as in the cultures of the joints and hearts here reported. Nevertheless, the role of antigens related to infection elsewhere in the body must be considered, since joint (31, 32) and heart lesions (33) resulting from hypersensitivity to bacterial antigens have been described in the past. The possibility of hypersensitivity to a virus related antigen must also be taken into account. It is of interest, in this regard, that a diffuse mononuclear inflammatory disease, involving many organs, has been described in the mouse following viral infection with lymphocytic choriomeningitis virus (34) and that a chronic arthritis has been described in the lamb with psittacosis lymphogranuloma venereum virus (35).

In considering the role of antigens related to possible infectious agents in the development of the joint and cardiac lesions, it is necessary to assume that, although the occurrence of such antigens might be a consequence of decreased



ability on the part of the host to resist infection, sufficient immunologic responsiveness would have to be retained by the host to react to an offending antigen with a local inflammatory response. This would assume that the animal with homologous disease retains the capacity for cellular hypersensitivity at a time when its ability to produce protective serum antibody is diminished. This situation prevails, as is well known, in patients with agammaglobulinemia who commonly display connective tissue inflammatory lesions (36).

A striking demonstration of the graft-*versus*-host reaction is seen in the changes in the lymphoid organs. Similar findings have been described by others (8, 37). The marked progressive changes observed are, presumably, a consequence of the "homing" of the donor cells to the reticuloendothelial system, leading there, more than elsewhere in the body, to close contact between host and donor cells. The disappearance of lymphocytes and loss of architecture observed would appear to be a consequence of immunologic attack by the donor cells, while the appearance of the plasma-like cells described is most likely a result of immunization of the donor cells by host antigens (38). An additional effect of extrinsic antigens cannot, however, be ruled out. It is of interest that the plasmacytosis seen in the lymph nodes and spleen in homologous disease resembles those reported in these organs in animals receiving x-irradiation following antigen (39) and in animals receiving antilymphocyte serum (40). In both these experimental groups, destruction of lymphocytes occurs concomitantly with the development of an immune response, a combination of immunologic events which also occurs in homologous disease. The fibrosis of the lymphoid organs which eventually develops in homologous disease is very likely a consequence of the inflammatory reaction accompanying the graft-*versus*-host response.

The mild interstitial lesions in the kidney, without glomerular involvement, appear to be an expression of the graft-*versus*-host reaction. In their interstitial localization, they resemble the lesions which have been produced by homologous cells injected beneath capsule of the kidney (41). Similar infiltrates are also seen in kidney homografts undergoing rejection (29, 42). The absence of glomerular lesions suggests that serum antibody does not play a significant pathogenic role in the homologous disease studied in the present investigation. This would apply not only to nephrotoxic antibody (43, 44) but also to circulating antigen-antibody complexes of the type described by a number of investigators (45, 46).

#### SUMMARY

Polyarthritides and cardiac lesions have been observed in the adult rat with homologous disease. Changes in the lymphoid tissue and kidney have also been noted.

A migratory polyarthritides occurred in over half of the affected animals, and

cardiac involvement of varying intensity was present in all. Histologically, the arthritis was characterized by a mononuclear synovial inflammatory reaction. In the heart, the valves and myocardium demonstrated a similar type of response. Cultures of involved joints and hearts for pyogens and pleuropneumonia-like organisms were negative.

The lymphoid tissues showed progressive changes in three stages: (a) disappearance of follicles; (b) increase in plasma-like cells and histiocytes; and (c) fibrosis. The second stage tended to coincide with the development of the polyarthritis. The kidney showed mild interstitial mononuclear infiltration.

The pathologic changes described appear to be a consequence of reaction between foreign immunologically competent cells and host antigens, but the possibility that these lesions represent a response to antigens derived from unknown infectious agents is, however, not ruled out.

#### BIBLIOGRAPHY

1. Stastny, P., and Ziff, M., Homologous disease in the adult rat, a model for autoimmune disease, *Fed. Proc.*, 1962, **21**, 42.
2. Stastny, P., and Ziff, M., Homologous disease in the adult rat, a model for autoimmune disease, *Arthritis and Rheumat.*, 1963, **6**, 64.
3. Stastny, P., Stembridge, V. A., and Ziff, M., Homologous disease in the adult rat, a model for autoimmune disease. I. General features and cutaneous lesions, *J. Exp. Med.*, 1963, **118**, 635.
4. Oliner, H., Schwartz, R., and Dameshek, W., Studies in experimental autoimmune disorders. I. Clinical and laboratory features of autoimmunization (runt disease) in the mouse, *Blood*, 1961, **17**, 20.
5. Holub, M., Report of the symposium committee concerning the nomenclature of cells responsible for the immune reactions, in *Mechanisms of Antibody Formation*, New York, Academic Press, Inc., 1960, 23.
6. Berman, L., The immunologically competent cell ("Immunocyte") system—an attempt at a delineation of cellular relationships, *Blood*, 1963, **21**, 246.
7. Simonsen, M., The impact on the developing embryo and newborn animals of adult homologous cells, *Acta Pathol. and Microbiol. Scand.*, 1957, **4**, 480.
8. Billingham, R. E., and Brent, L., A simple method for inducing tolerance to skin homografts in mice, *Transplant. Bull.* 1957, **4**, 67.
9. Billingham, R. E., Defendi, V., Silvers, W. K., and Steinmuller, D., Quantitative studies on the induction of tolerance of skin homografts and on runt disease in neonatal rats, *J. Nat. Cancer Inst.* 1962, **28**, 365.
10. DeVries, M. J., Crouch, B. G., van Putten, L. M., and van Bekkum, D. W., Pathologic changes in irradiated monkeys treated with bone marrow, *J. Nat. Cancer Inst.*, 1961, **27**, 67.
11. Oliner, H., Schwartz, R., and Dameshek, W., Studies in experimental autoimmune disorder. I. Clinical and laboratory features of autoimmunization (runt disease) in the mouse, *Blood*, 1961, **17**, 20.
12. Porter, K. A., Immune hemolysis: A feature of secondary disease and runt disease in the rabbit, *Ann. New York Acad. Sc.*, 1960, **87**, 391.

13. Stastny, P., and Ziff, M., Homologous disease in the adult rat, a model for auto-immune disease, *Ann. New York Acad. Sc.*, 1962, **99**, 663.
14. Eisenberg, A. C., Wilkes, B., and Waksman, B. H., The production of runt disease in rats thymectomized at birth, *J. Exp. Med.*, 1962, **116**, 759.
15. Ward, J. R., and Jones, R. S., The pathogenesis of mycoplasmal (PPLO) arthritis in rats, *Arthritis and Rheumat.*, 1962, **5**, 163.
16. Jasmin, G., Experimental polyarthritis in rats injected with a tumor exudate, *Ann. Rheumatic Diseases*, 1957, **16**, 365.
17. Jasmin, G., personal communication.
18. Good, R. A., Dalmasso, A. P., Martinez, C., Archer, O. K., Pierce, J. C., and Papermaster, B. W., The role of the thymus in development of immunologic capacity in rabbits and mice, *J. Exp. Med.*, 1962, **116**, 773.
19. Miller, J. F. A. P., Immunologic functions of the thymus, *Lancet*, 1961, **2**, 748.
20. Jankovic, B. D., Waksman, B. H., Arnason, B. G., Role of the thymus in immune reactions in rats. I. The immunologic response to bovine serum albumin (antibody formation, arthus reactivity, and delayed hypersensitivity) in rats thymectomized or splenectomized at various times after birth, *J. Exp. Med.*, 1962, **116**, 159.
21. Sherman, J. D., Adner, M. M., and Dameshek, W., Effect of thymectomy on the golden hamster (*mesocricetus auratus*). I. Wasting disease, *Blood*, 1963, **22**, 252.
22. Schlesinger, M., and Mark, R., Wasting disease induced in young mice by administration of cortisol acetate, *Science*, 1964, **143**, 965.
23. Ekstedt, R. D., and Nishimura, E. T., Runt disease induced in neonatal mice by sterile bacterial vaccines, *J. Exp. Med.*, 1964, **120**, 795.
24. Parrot, D. M. V., and East, J., Role of the thymus in neonatal life, *Nature*, 1962, **195**, 347.
25. Brooke, M. F., Experimental runt disease in mice caused by *Salmonella thypi-murium*, Var. *copenhagen*, *J. Exp. Med.*, 1964, **120**, 375.
26. Wilson, R., Sjodin, K., and Bealmear, M., The absence of wasting in thymectomized germfree (axenic) mice, *Proc. Soc. Exp. Biol. and Med.*, 1964, **117**, 237.
27. McIntire, K. R., Sell, S., and Miller, J. F. A. P., Pathogenesis of the post-neonatal thymectomy wasting syndrome, *Nature* 1964, **204**, 151.
28. Blaese, R. M., Martinez, C., and Good, R. A., Immunologic incompetence of immunologically runted animals, *J. Exp. Med.*, 1964, **119**, 211.
29. Simonsen, M. Graft versus host reactions. Their natural history, and applicability as tools of research, *Progr. Allergy*, 1962, **6**, 349.
30. Isacson, P., Cellular transfer of antibody production from adult to embryo in domestic fowls, *Yale J. Biol. and Med.*, 1959, **32**, 209.
31. Sikes, D., A rheumatoid like arthritis in swine, *Lab. Invest.*, 1959, **8**, 1406.
32. McCluskey, R. T., Gell, P. G., and Felix-Davies, D., Experimental allergic arthritis, *Fed. Proc.*, 1961, **20**, 17.
33. Murphy, G. E., and Swift, H. F., The induction of rheumatic-like cardiac lesions in rabbits with repeated focal injections with group K streptococci, *J. Exp. Med.* 1949, **89**, 485.
34. Hotchin, J., The biology of lymphocytic choriomeningitis infection: virus induced immune disease. *Cold Spring Harbor Symp. Quant. Biol.*, 1962, **27**, 479.

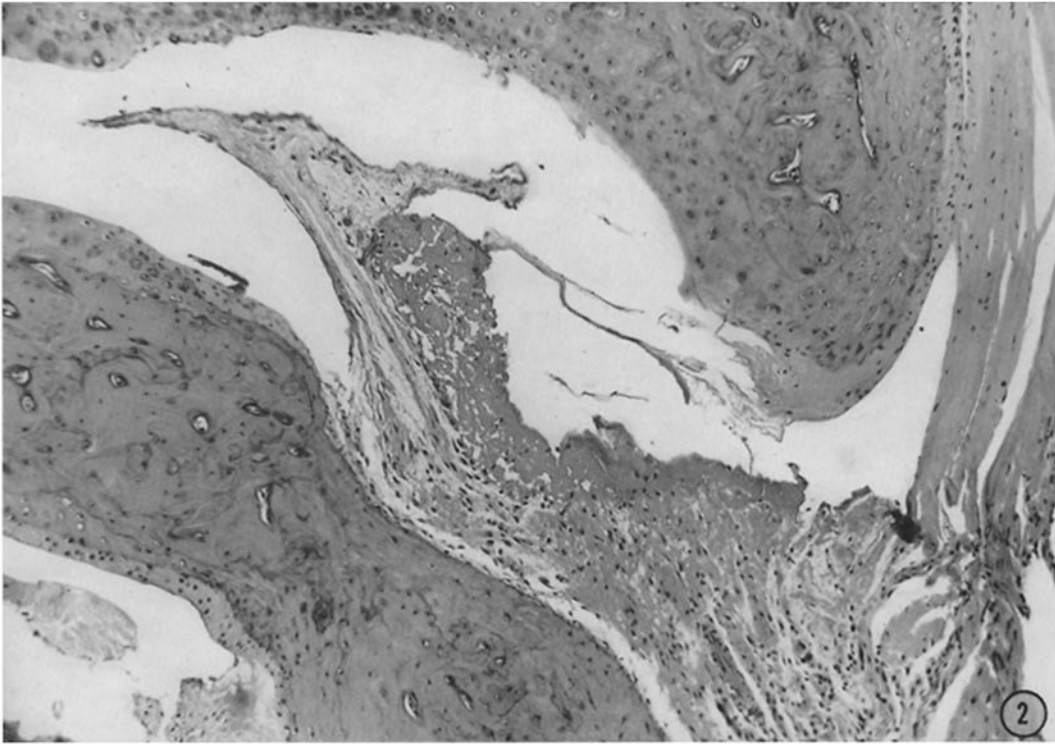
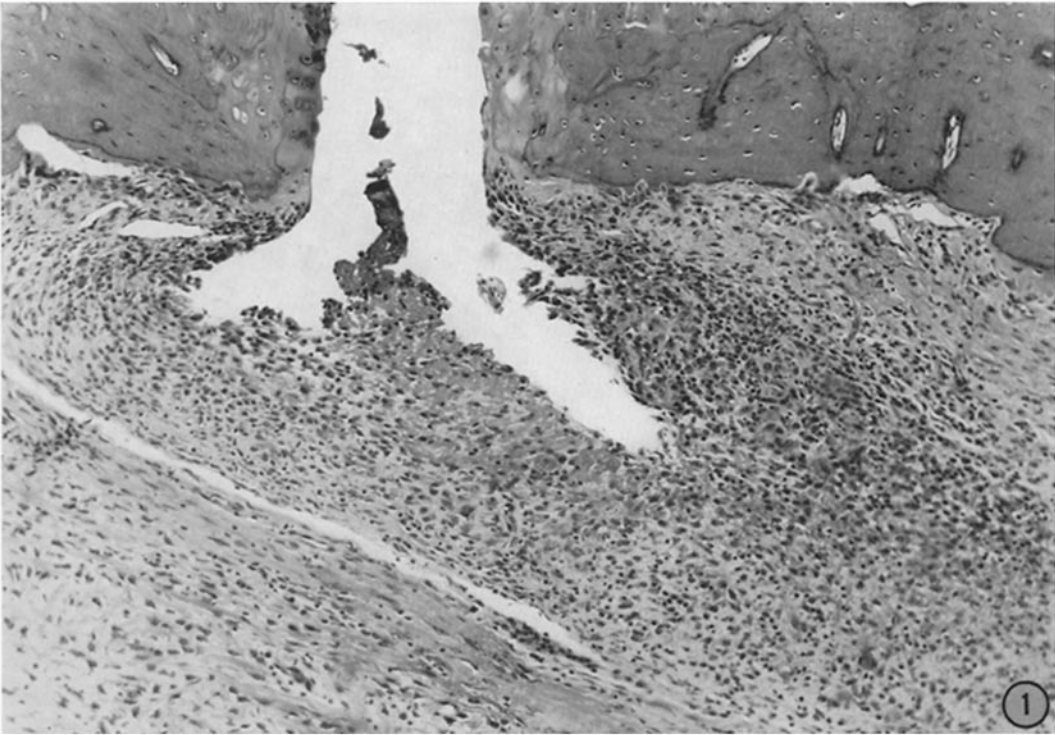
35. Shupe, J. L., and Storz, J., Pathologic study of psittacosislymphogranuloma polyarthritides of lambs, *Am. J. Vet. Research* 1964, **25**, 943.
36. Good, R. A., Kelly, W. D., Rotstein, J., and Varco, R. L., Immunological deficiency diseases, *Progr. Allergy*, 1962, **6**, 187.
37. Howard, J. G., Changes in the activity of reticulo-endothelial system following the injection of parental spleen cells into F<sub>1</sub> hybrid mice, *Brit. J. Exp. Pathol.*, 1961, **42**, 72.
38. Gowans, J. L., The fate of parental strain small lymphocytes in F<sub>1</sub> hybrid rats, *Ann. New York Acad. Sc.*, 1962, **99**, 432.
39. Dixon, F. J., and McConahey, P. J., Enhancement of antibody formation by whole body x-radiation, *J. Exp. Med.*, 1963, **117**, 833.
40. Denman, A. M., and Ziff, M., Effect of prolonged administration of anti-lymphocyte serum in the rat, *Arthritis and Rheumat.*, 1964, **7**, 731.
41. Elkins, W. L., Invasion and destruction of homologous kidney by locally inoculated lymphoid cells, *J. Exp. Med.*, 1964, **120**, 329.
42. Porter, K. A., Calve, R. Y., and Zukoski, C. F., Vascular and other changes in 200 canine renal homotransplants treated with immunosuppressive drugs, *Lab. Inv.*, 1964, **13**, 809.
43. Masugi, M., Uber die experimentelle glomerulonephritis durch das spezifische antinieren serum, *Beitr. Path. Anat. u. Allgem. Path.*, 1933-34, **92**, 439.
44. Hamman, D. K., and Dixon, F. J., Experimental glomerulonephritis. II. Immunologic events in the pathogenesis of nephrotoxic serum nephritis in the rat, *J. Exp. Med.*, 1963, **117**, 1019.
45. Benacerraf, B., Porter, J. L., McCluskey, R. T., and Miller, F., The pathologic effects of intravenously administered soluble antigen-antibody complexes. II Acute glomerulonephritis in rats, *J. Exp. Med.*, 1960, **111**, 195.
46. Dixon, F. J., Feldman, J. D., and Vazquez, J. J., Experimental glomerulonephritis. The pathogenesis of a laboratory model resembling the spectrum of human glomerulonephritis, *J. Exp. Med.*, 1961, **113**, 899.

#### EXPLANATION OF PLATES

##### PLATE 43

FIG. 1. Joint of rat with homologous disease demonstrating marked inflammatory response characterized by innumerable mononuclear cells, principally histiocytes, plasma-like cells and lymphocytes. Much of the para-articular tissue is involved by the inflammatory response. Fibrinoid change is present.  $\times 102$ .

FIG. 2. Joint of rat with homologous disease demonstrating prominent fibrinoid deposition within the synovial membrane. The inflammatory infiltrate is modest.  $\times 90$ .

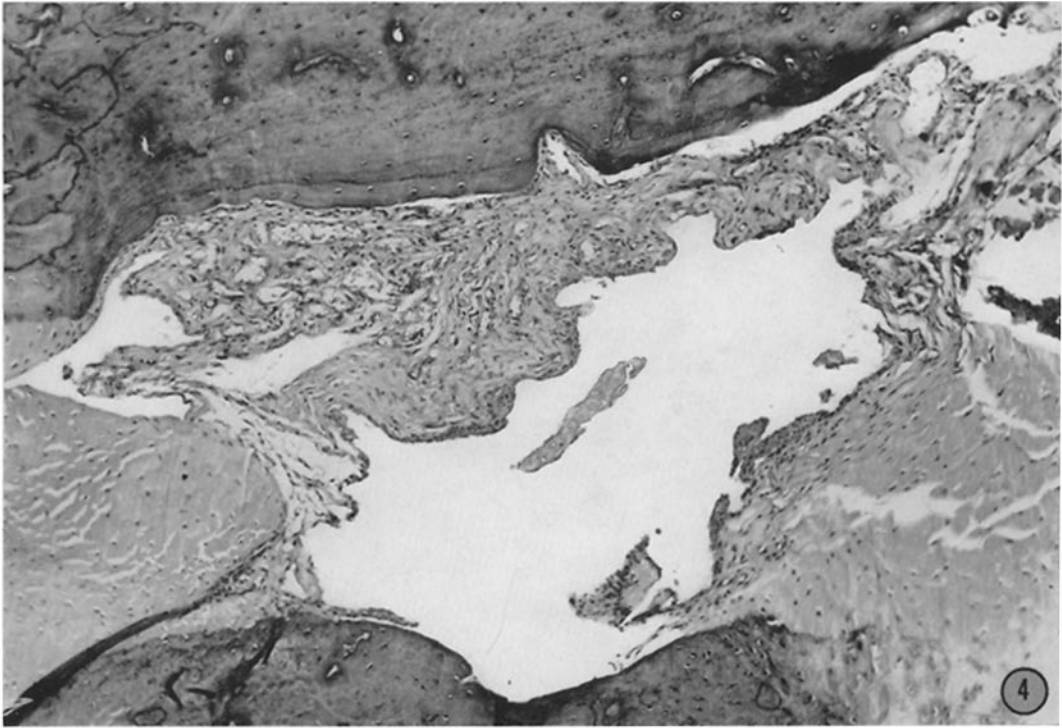
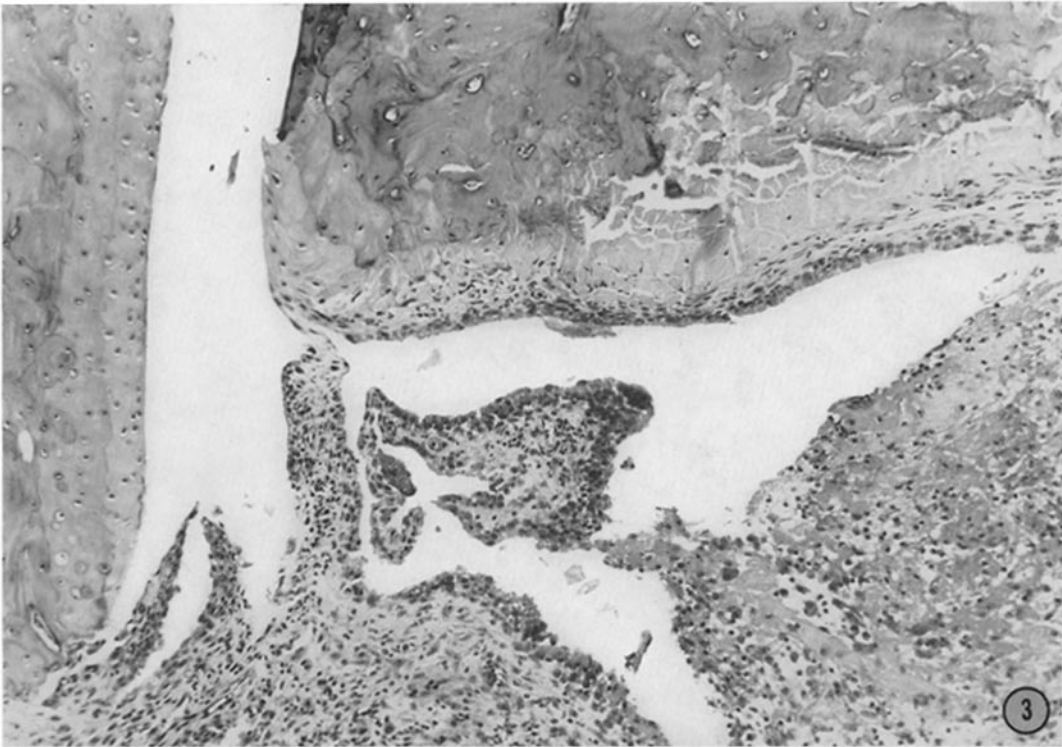


(Stastny *et al.*: Homologous disease in the adult rat)

PLATE 44

FIG. 3. Joint of rat with homologous disease demonstrating synovial cell proliferation, edema, and mononuclear cell infiltrate. Beginning fibroblastic and blood vascular proliferation is also observed.  $\times 115$ .

FIG. 4. Joint of a rat with homologous disease demonstrating early fibrosis replacing the capillaries. Almost complete subsidence of the inflammatory reaction is noted.  $\times 110$ .



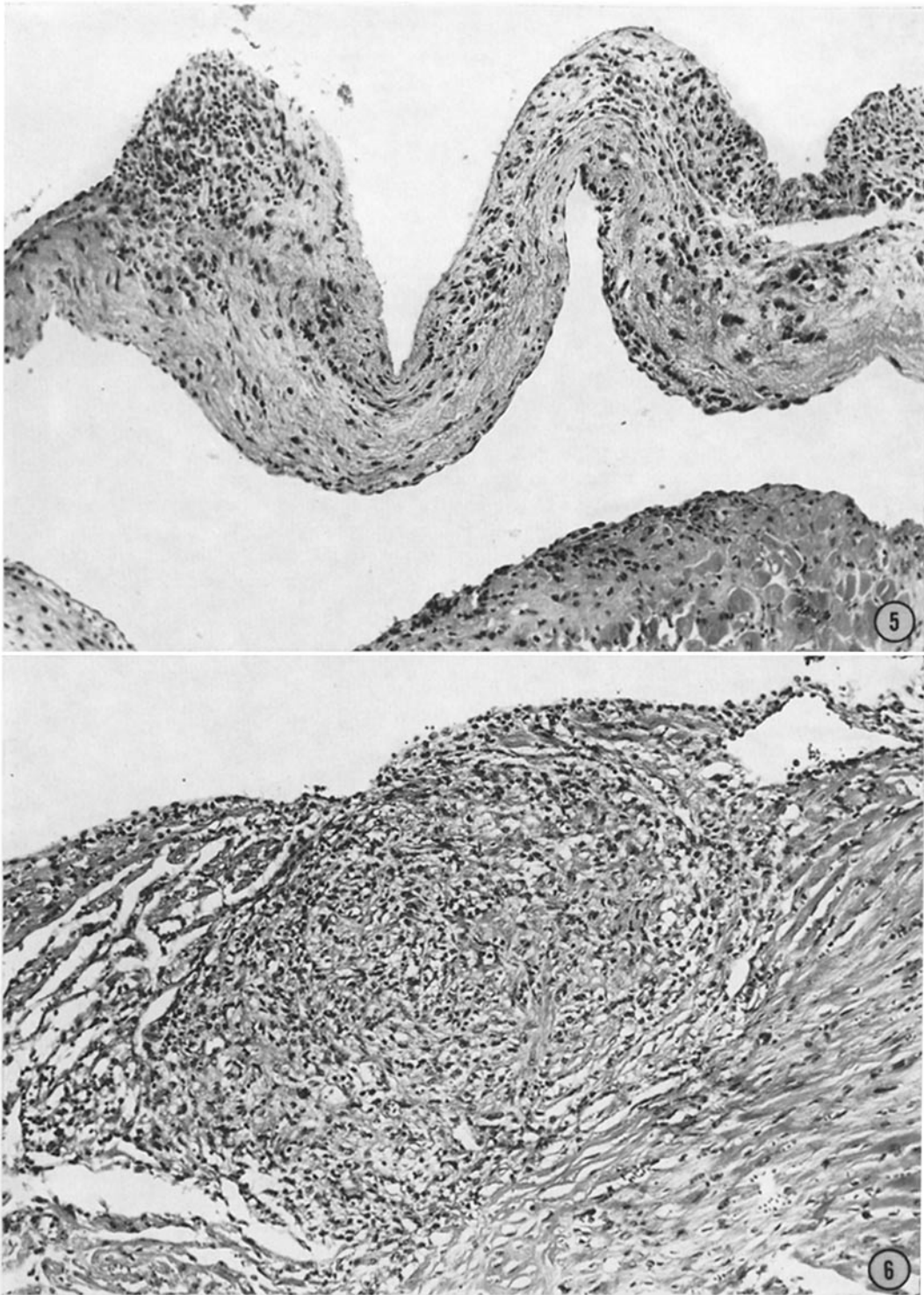
(Stastny *et al.*: Homologous disease in the adult rat)

PLATE 45

FIG. 5. Valvulitis in a rat with homologous disease. Valve leaflet shows nodular infiltrates of mononuclear cells and beginning fibrosis.  $\times 152$ .

FIG. 6. Myocarditis in rat with homologous disease. Nodular lesion at base of mitral valve characterized by a prominent mononuclear cell infiltrate. Fibrous tissue proliferation and capillary proliferation is also observed.  $\times 142$ .



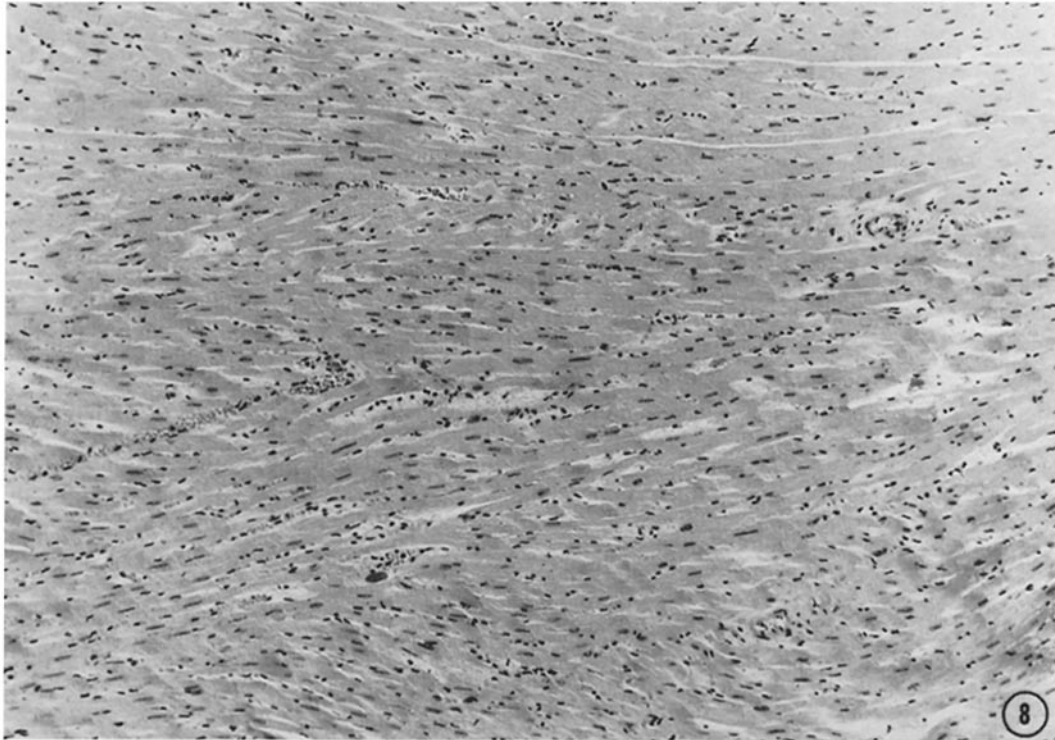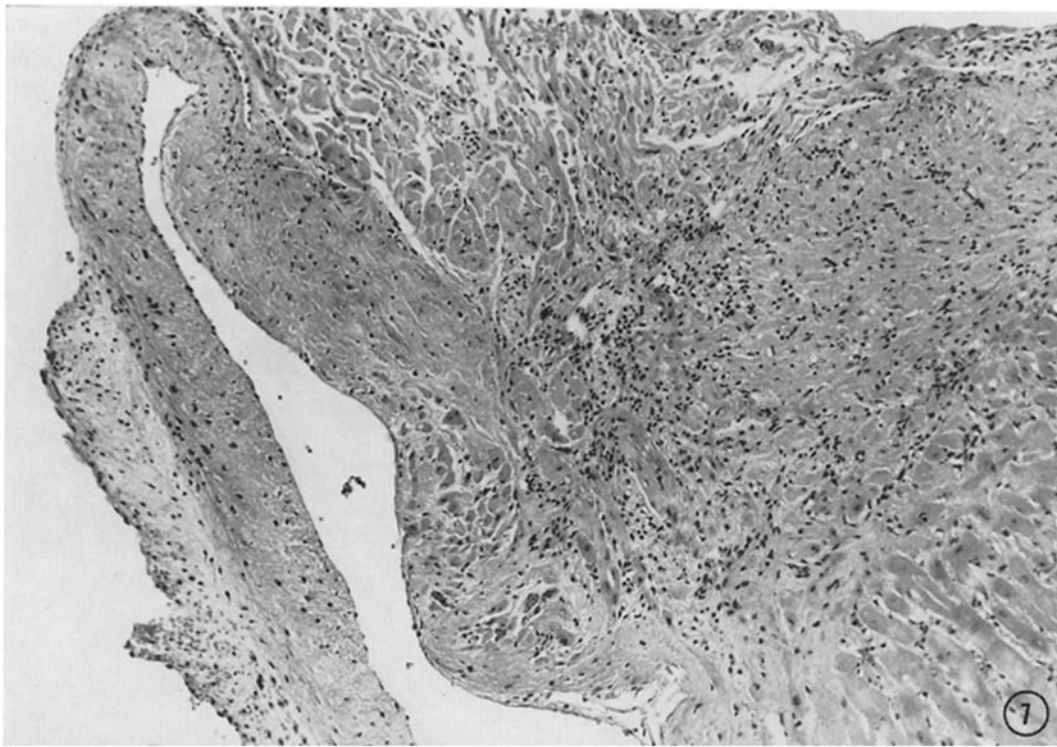


(Stastny *et al.*: Homologous disease in the adult rat)

PLATE 46

FIG. 7. Photomicrograph of base of mitral valve demonstrating the collagenization of the inflammatory nodule with prominent separation of the myocardial fibers. Mild persistence of lymphocytic infiltrate is observed.  $\times 120$ .

FIG. 8. Diffuse myocarditis in rat with homologous disease. Photomicrograph of myocardium demonstrating a diffuse mononuclear inflammatory infiltrate of the interstitium of the heart. Infiltrating cells are principally lymphocytes and histiocytes.  $\times 135$ .

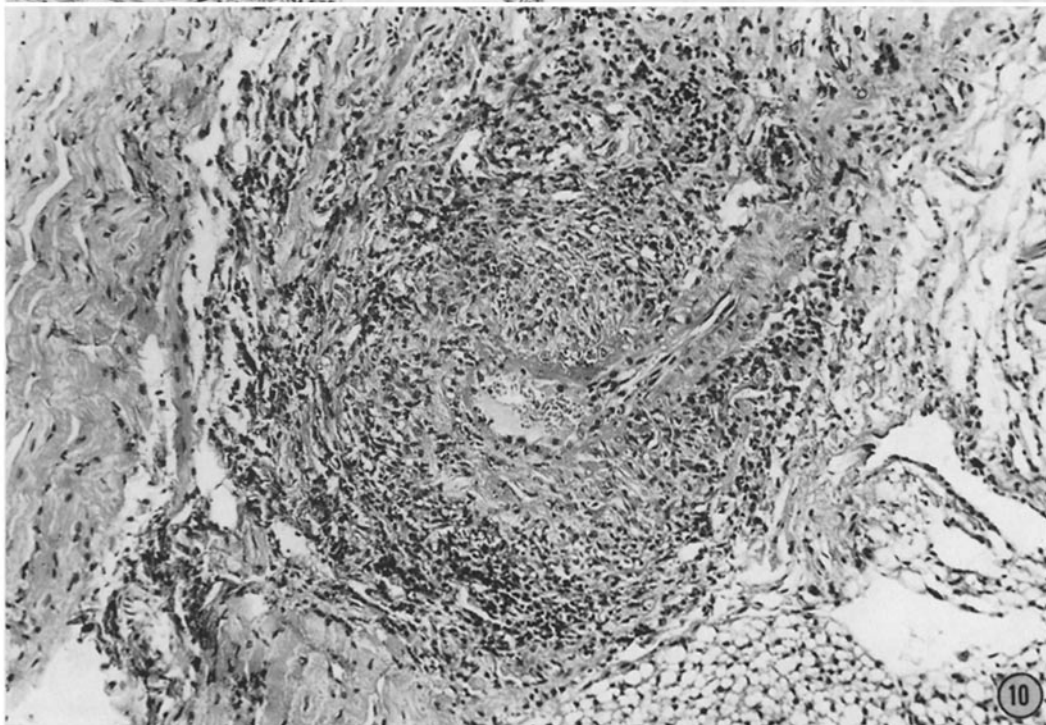
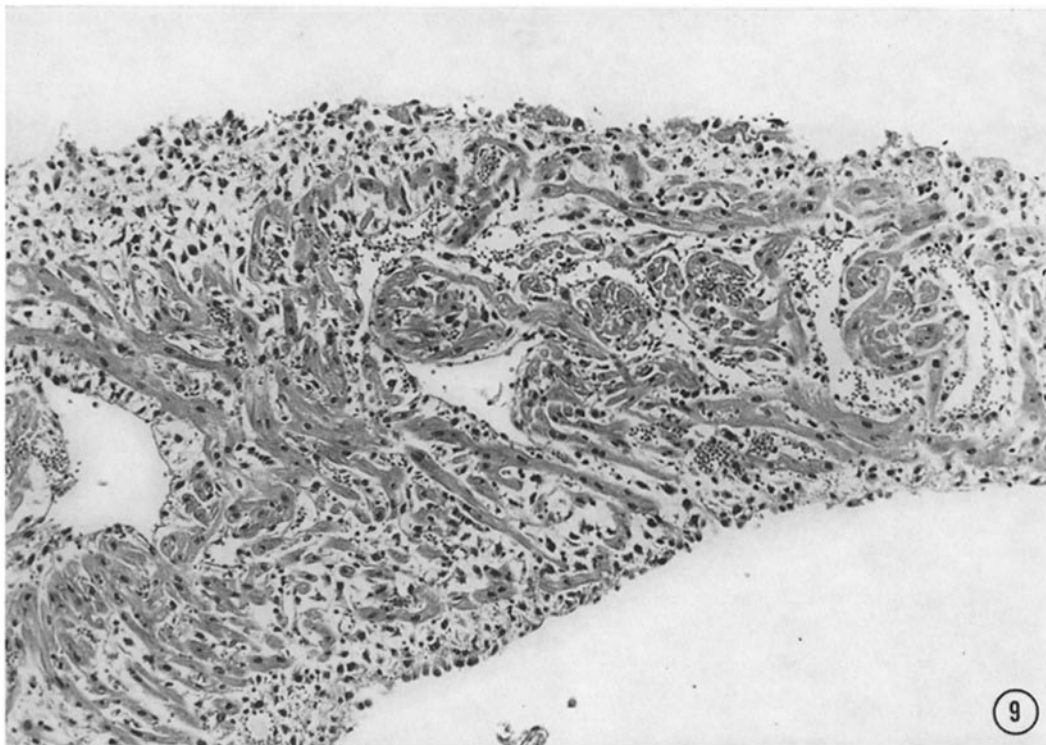


(Stastny *et al.*: Homologous disease in the adult rat)

PLATE 47

FIG. 9. Photomicrograph of atrial myocardium demonstrating prominent edema with mononuclear infiltration. Inflammatory response is diffuse and severe.  $\times 150$ .

FIG. 10. Vasculitis in rat with homologous disease. Coronary artery demonstrating fibrinoid change within the arterial wall and intense mononuclear infiltration of the wall and surrounding tissue. Note resemblance to polyarteritis nodosa.  $\times 141$ .

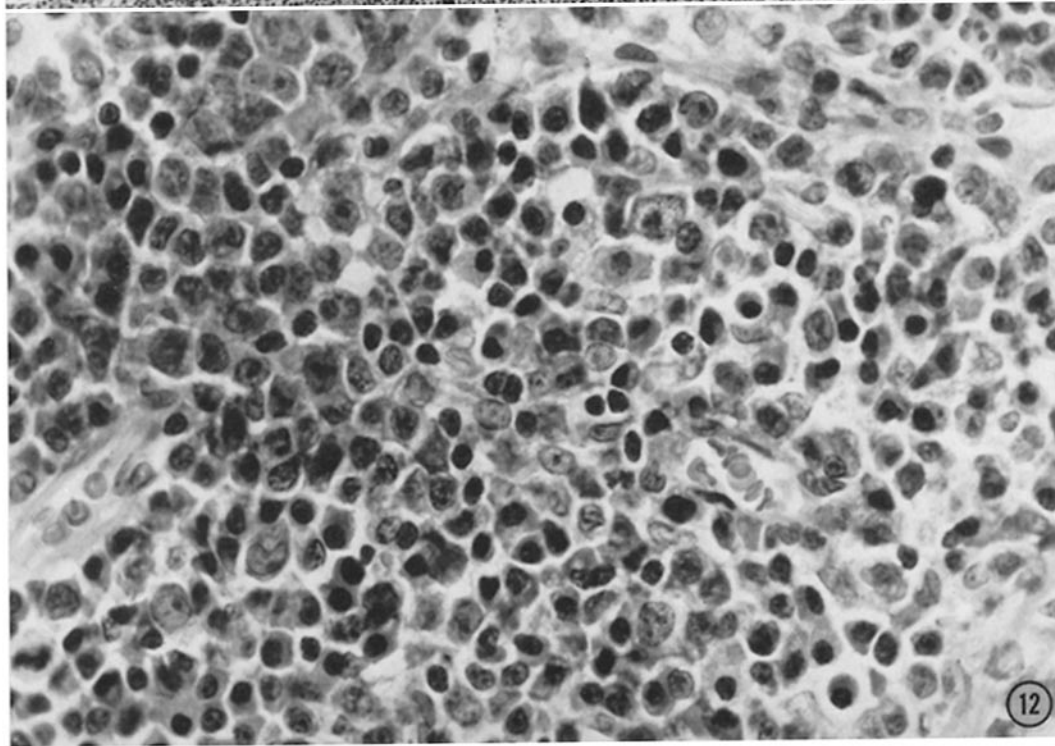
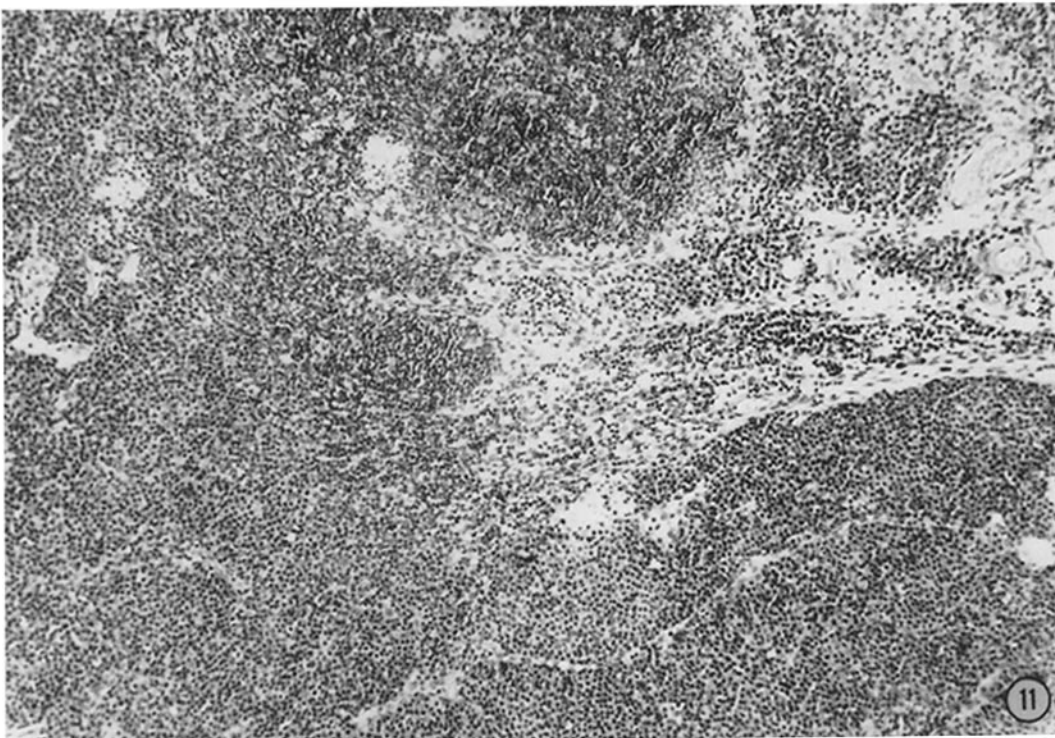


(Stastny *et al.*: Homologous disease in the adult rat)

PLATE 48

FIG. 11. Lymph node of rat with homologous disease demonstrating loss of follicular architecture and replacement by mononuclear cells.  $\times 102$ .

FIG. 12. High power photomicrograph of lymph node demonstrating large numbers of histiocytic cells and an abundance of plasma-like cells.  $\times 615$ .



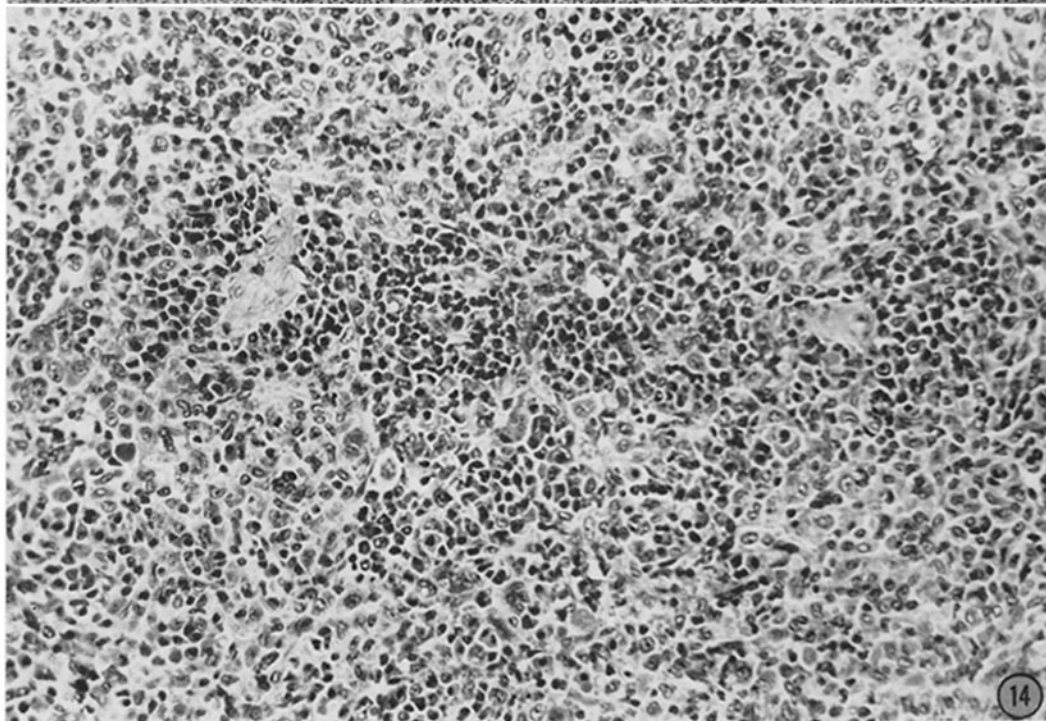
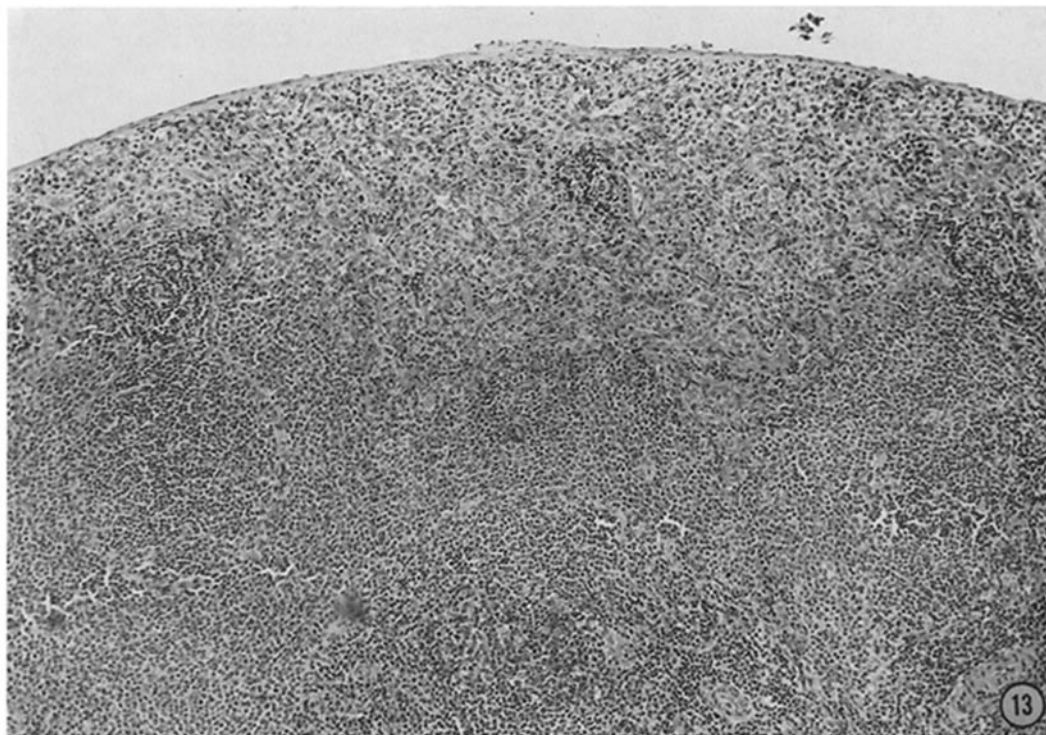
(Stastny *et al.*: Homologous disease in the adult rat)

PLATE 49

FIG. 13. Spleen of rat with homologous disease demonstrating replacement of follicular pattern by proliferation of mononuclear cells.  $\times 100$ .

FIG. 14. High power photomicrograph of splenic parenchyma demonstrating the large number of mononuclear cells present, principally histiocytes, plasma-like cells and occasional lymphocytes. Some of the histiocytes contain hemosiderin.  $\times 235$ .



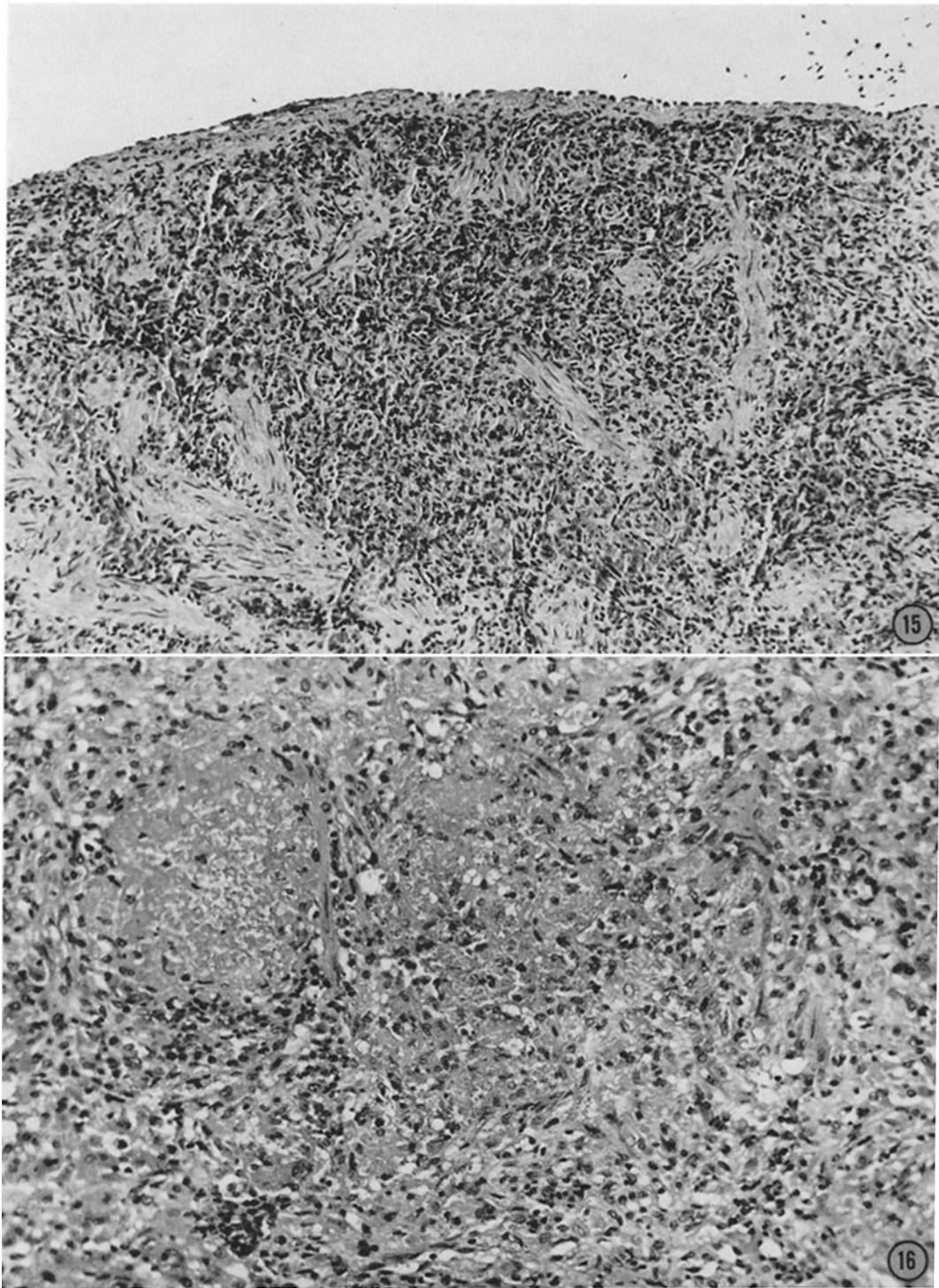


(Stastny *et al.*: Homologous disease in the adult rat)

PLATE 50

FIG. 15. Spleen of rat with homologous disease demonstrating the late changes of fibrosis with hyalinization. There is marked degree of hemosiderin pigmentation.  $\times$  154.

FIG. 16. Photomicrograph of spleen demonstrating foci of amyloid-like deposits within the parenchyma. Fibrous tissue proliferation is also observed.  $\times$  215.

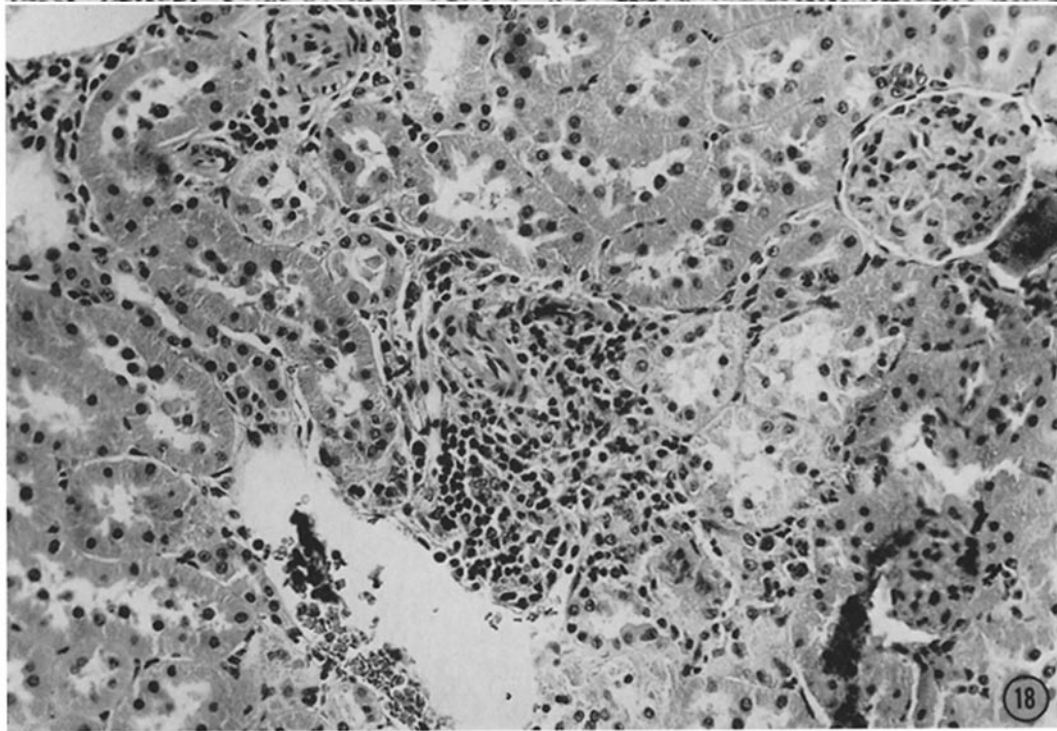
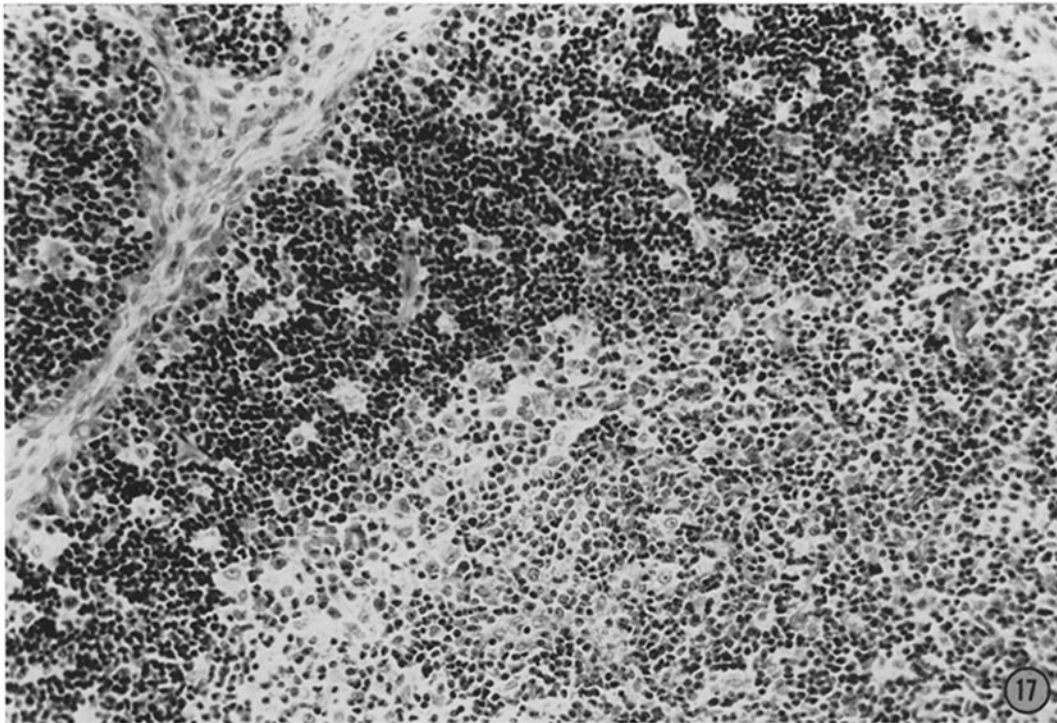


(Stastny *et al.*: Homologous disease in the adult rat)

PLATE 51

FIG. 17. Thymus of rat with homologous disease demonstrating distinct and accentuated cortical and medullary segments. The medullary portion shows prominent reticular cells and histiocytes. Both cortex and medulla show an increased number of plasma-like cells.  $\times 245$ .

FIG. 18. Kidney of rat with homologous disease displaying perivascular mononuclear infiltrate made up principally of lymphocytes and histiocytes. Glomerulus and tubules are normal.  $\times 250$ .



(Stastny *et al.*: Homologous disease in the adult rat)