

THE EXPERIMENTAL INDUCTION OF GLOMERULONEPHRITIS  
LIKE THAT IN MAN BY INFECTION WITH  
GROUP A STREPTOCOCCI\*

By CARL G. BECKER, M.D., AND GEORGE E. MURPHY, M.D.

*(From the Department of Pathology, The New York Hospital-Cornell Medical  
Center, New York, 10021)*

PLATES 1-8

(Received for publication 23 February 1967)

In the course of an epidemic of scarlet fever in Florence in 1717, physicians observed that during convalescence some patients again sickened, as often manifested by swelling of the face and suppression of the urine, with what Borsieri (1) at Pavia in 1781 termed "the secondary diseases or another stage of scarlet fever". Borsieri noted that "of all the symptoms, the most frequent is an edematous, or leucophlegmatic swelling, affecting the whole body or particular parts of it, generally with scanty, turbid, and dark colored urine, and sometimes with a total suppression of it." Similar observations had been made by von Plenciz (2) during an epidemic of scarlet fever in Vienna. Appreciating the significance of van Leeuwenhoek's (3) observations of microorganisms, he postulated in 1762 that epidemic scarlet fever results from the action of rapidly multiplying "animalcules." In his "Observations on the Dropsy, which succeeds Scarlet Fever," Wells (4) noted in 1806 that "the dropsy often comes on after a very mild fever, and when the person . . . appears to have nearly or altogether recovered his former health." He drew attention to variations in the attack rate of postscarlatinal dropsy among families as follows: "When one child of a family has been attacked with this disease, the other children of the same family, who have lately passed through the scarlet fever, are more liable to become dropsical, than the children of another family, who have also lately labored under that fever, but among whom no symptoms of the dropsy has yet occurred." He further noted that the urine of these patients regularly contained "the serum of blood" and appreciated that red urine contained "the red matter of blood." By 1827, Bright (5), from correlation of clinical and gross anatomical observations, had established connection between "dropsy attended with coagulable urine" and altered structure of the kidneys.

The principal microscopic changes in glomeruli in several fatal cases of acute glomerulonephritis that followed scarlet fever were clearly illustrated by Reichel (6) in

---

\*This investigation was supported by USPHS research grant HE-01803 from the National Heart Institute, N.I.H., a grant from The Cross Foundation, and USPHS pathology research training grant GM-78 from the National Institute of General Medical Sciences, N.I.H.

The work was reported in the main on May 6, 1965, to the New York Pathological Society and on March 10, 1967, to The American Association of Pathologists and Bacteriologists.

1905. Because of evidence of recent infection with streptococci in the majority of cases of acute diffuse proliferative glomerulonephritis that he had examined, Löhlein (7) concluded that these renal changes, in a majority of cases, were the result of the action of streptococcal toxins. Schick (8), in an effort to explain the latent period between scarlet fever and nephritis, hypothesized that the latter might be a result of the development during the latent period of lowered resistance or hypersensibility of the host to the action of either persisting microorganisms that caused the scarlet fever or microorganisms causing a superimposed infection. Impressed by the similar latent periods preceding serum disease and postscarlatinal nephritis, von Pirquet (9) suggested that the latter, like serum disease (10), is a manifestation of altered reactivity ("allergy"), and he implied that it results from interaction of microorganisms with antibodies produced against them in the latent period.

By 1907, much evidence had accumulated to indicate that scarlet fever was caused by streptococci (11) and, by 1924,  $\beta$ -hemolytic streptococci had been definitively demonstrated by the Dicks (12) and by Dochez and Sherman (13) to be the causative agents of scarlet fever, and by Bloomfield and Felty (14) to be common causative agents of tonsillitis. Longcope (15) reported in 1929 that, of a large number of cases of acute or subacute glomerulonephritis, the large majority were known to be preceded by infections, notably tonsillitis and sinusitis, from most of which  $\beta$ -hemolytic streptococci were cultured. From serial estimations of serum antistreptolysin O titer in 116 consecutive cases of acute glomerulonephritis, Lyttle, Seegal, Loeb, and Jost (16) demonstrated that in 94% of the cases recent infection with  $\beta$ -hemolytic streptococci had occurred. The work of Lancefield (17) led to the demonstration that the very large majority of strains of  $\beta$ -hemolytic streptococci cultured from human infections belonged to a serologic group designated A. From analysis of differences between glomerulonephritis and rheumatic fever, Seegal and Earle (18) as well as Rammelkamp, Weaver, and Dingle (19) hypothesized that only certain strains of Group A streptococci have "nephritogenic" capability. The epidemiologic and clinical observations of Rammelkamp and associates (20, 21) and of others (22) support this hypothesis.

How streptococci induce glomerulonephritis has not been determined. To gain knowledge of this subject, the experimental induction of glomerulonephritis, like that in man, by infection of animals with Group A streptococci would be valuable. Numerous efforts to attain this goal have been unsuccessful in the past. The purpose of the present communication is to report the experimental induction of glomerulonephritis like that in man by infection with Group A streptococci.

#### *Materials and Methods*

*Streptococci.*—Group A streptococci of Types 1, 3, 11, 12, 13, 15, 17, 19, 49, and London were used to inoculate rabbits. Two strains of Type 1 streptococci were used. One of these was originally isolated in London, England (23), from the throat of a 13 yr old girl 1 wk after onset of acute glomerulonephritis and was obtained through the courtesy of Dr. R. E. O. Williams and Mr. W. R. Maxted. This strain will be referred to as Type 1 (Mary). A strain, B225, of Type 12 streptococci was originally isolated in Bainbridge, Md., (21) from the nasopharynx of an adult male shortly before he developed acute glomerulonephritis during

an epidemic of infection due to Type 12 streptococci and was obtained through the courtesy of Dr. C. A. Stetson. A strain, B737, of Type 49 streptococci, obtained through the courtesy of Doctors L. W. Wannamaker and R. C. Lancefield, was originally isolated from a vesicle in the skin of a 3 yr old girl with extensive pyoderma during an epidemic of infection with Type 49 streptococci among children at Red Lake Indian Reservation in Minnesota.<sup>1</sup> During this epidemic, acute glomerulonephritis, not evident in this child, was known to have developed in 63 others, or approximately 6.6% of the children of late preschool and early school age on the reservation, and in about 60% of the cases was associated with extensive pyoderma (24). Type 1 (Mary), Type 12, and Type 49 streptococci of "parent" (stock) cultures were subcultured in Todd-Hewitt broth made with neopeptone. Streptococci of some of these subcultures were rotated with lightly heparinized human blood (25). The microorganisms that survived such rotation will be referred to as "in vitro-selected streptococci." The M protein content of these selected streptococci was significantly greater than that of streptococci of the parent cultures (25). Streptococci of other subcultures of Type 1 (Mary) and Type 12 streptococci were inoculated intracutaneously into rabbits which had been previously sensitized, by intravenous injection, to products of Group A streptococci. 60 hr later, streptococci were aspirated from sites of the resulting allergic inflammation. These microorganisms, which will be referred to as "in vivo-selected streptococci," were significantly richer in M protein than streptococci of the parent cultures.<sup>2</sup> Rabbits were infected with parent or in vitro-selected streptococci of Types 1, 12, 49, or with in vivo-selected streptococci of Types 1 and 12. Streptococci of parent and selected cultures were stored in lyophilized form. Strain K43 of Type 1 streptococci and the strains of Types 3, 11, 13, 15, 17, 19, and London streptococci were originally isolated from humans without evidence of glomerulonephritis. Prior to use in these experiments, they had undergone several to many serial passages through mice and/or in the skin of rabbits. These streptococci were subcultured in Todd-Hewitt broth made with neopeptone.

*Culture of Streptococci for Inoculations.*—Streptococci of a lyophilized culture were inoculated into 40 ml of Todd-Hewitt broth and grown overnight at 37°C. The culture so obtained was refrigerated and used as stock culture for a given course of inoculations. On the day of a scheduled inoculation, a sample (1.0 ml) of stock culture was transferred to 5 ml of Todd-Hewitt broth. This subculture was incubated for 4–6 hr and then centrifuged. The supernatant broth was decanted and the bacterial sediment washed twice with 5 ml volumes of Tyrode's solution. The streptococci were resuspended in 5 ml of Tyrode's solution and then diluted in 10-fold steps with Tyrode's solution to a final dilution of 10<sup>-6</sup>. Samples (0.1 ml) of the 10<sup>-1</sup>–10<sup>-6</sup> dilutions of streptococci were transferred to sterile Petri dishes and 5% rabbit blood agar was added. The plates were incubated at 37°C and hemolytic colonies were counted the following day. The approximate number of streptococci per 0.1 ml aliquot of each dilution was as follows: 10<sup>-1</sup>, 100,000–500,000; 10<sup>-2</sup>, 10,000–50,000; 10<sup>-3</sup>, 1,000–5,000; 10<sup>-4</sup>, 100–500; 10<sup>-5</sup>, 10–50; and 10<sup>-6</sup>, 0–5.

*Inoculation of Rabbits.*—106 New Zealand red rabbits, weighing between 2.5 and 3.5 kg at the beginning of the experiments, were fed Rockland rabbit pellets and given drinking water ad lib. They were inoculated as follows:

*Schedule A:* Some clinical investigators (18, 26, 27) have reported that the streptococcal infections preceding glomerulonephritis are often "deep," i.e. peritonsillar or cervical abscess, otitis media, sinusitis, and skin, wound, and puerperal infections, as opposed to "superficial" infections of the nasopharynx. Because some of these deep infections may be attended by transient streptococcemia, approximately one-fourth of the rabbits were inoculated with

<sup>1</sup> Ayoub, E. M. Personal communication.

<sup>2</sup> Becker, C. G. Manuscript in preparation.

streptococci both intracutaneously and intravenously. On each of days 1, 2, 5, 6, 7, and repeatedly between days 10–22, they received intracutaneously at different sites from  $10^4$  to  $10^6$  streptococci. On each of days 3, 4, 8, and 9, they were inoculated intravenously with from  $10^8$  to  $10^4$  streptococci. These rabbits received from one to two such series of inoculations spaced from 1 to 3 months apart. Each series was with streptococci of a different serologic type. This schedule of inoculations will henceforth be referred to as schedule A. A large majority of the rabbits that received inoculations according to schedule A subsequently received inoculations according to schedule B.

*Schedule B:* Because the streptococcal infections that precede glomerulonephritis in man very often appear to be superficial rather than deep, approximately three-fourths of the rabbits were inoculated *only* intracutaneously, approximately every other day for a total of 4 to 7 inoculations per series with from  $10^8$  to  $10^6$  streptococci. They received from one to three such series of inoculations spaced from 1 to 4 months apart. This schedule of inoculations will henceforth be referred to as schedule B. Rabbits usually received no more than one series of inoculations with streptococci of a given serologic type.

*Schedule C:* Included in this report are three rabbits which, in the course of experiments previously reported (28, 29), were inoculated *only* intracutaneously. Two of these animals received from  $2 \times 10^4$  to  $4 \times 10^6$  streptococci of only one type, London, on the same 2 successive days. The other animal received on eight occasions, spaced 4–14 wk apart, from  $10^1$  to  $3.5 \times 10^6$  streptococci of one of seven different serotypes. On five of these occasions, the number of streptococci inoculated ranged from  $4 \times 10^3$  to  $8 \times 10^4$ . On the last occasion,  $3.5 \times 10^6$  streptococci of Type London were inoculated.

*Control Rabbits not Inoculated with Streptococci.*—10 healthy rabbits of the same breed and size and housed in the same animal quarters as those inoculated according to schedules A or B served as normal controls and were sacrificed at various periods during the experiments.

*Measurement of Protein and Blood in Urine.*—Before, during, and between series of inoculations, rabbits were placed in metabolism cages and samples of their urine collected. Urinary protein was measured semiquantitatively by mixing 5 drops of 20% sulfosalicylic acid with 2 ml of centrifuged urine. Precipitate was graded on an ascending scale of 0 to + + + +. No precipitate was observed after addition of sulfosalicylic acid to samples of urine of more than 200 presumably healthy rabbits. 2+ or greater proteinuria was considered to be marked. In most cases, urinary protein was also measured quantitatively by the method of Shevsky and Stafford (30). The amount of protein in urine samples of more than 200 presumably healthy rabbits had been found in this laboratory to usually be between 0.072 and 0.144 g/liter and ranged from 0 to 0.216 g/liter. Proteinuria of 0.5 g/liter or greater was considered to be marked.

*Determination of Blood Urea Nitrogen.*—Rabbits were bled at various times from marginal ear veins. Blood urea nitrogen was measured by the method of Van Slyke and Cullen (31). The mean urea nitrogen in the blood of presumably healthy rabbits was found to be 22.78 mg/100 ml (SD  $\pm$  3.37 mg/100 ml).

*Determination of Antistreptolysin O Titer.*—Measurement of antistreptolysin O titer in sera of rabbits and sera of patients with glomerulonephritis was made according to a method devised by Todd (32) and modified by Hodge and Swift (33). Previously, it was found in this laboratory, that the titer of antistreptolysin O antibodies in the sera of more than 100 rabbits never inoculated with Group A streptococci was in every case less than 10 units. In man, a titer above 200 units is generally regarded as evidence of recent infection with Group A streptococci (34).

*Determination of Erythrocyte Sedimentation Rate (ESR) and Counting of Blood Leukocytes.*—The ESR was determined according to the Westergren method, and blood leukocytes were counted with a Spencer Brite-Line hemocytometer.

*Autopsy of Rabbits and Preparation of Tissues for Light Microscopy.*—Some rabbits died in the course of these experiments. Others were sacrificed by intravenous injection of sodium

pentobarbital given rapidly. Autopsies were performed on all animals. To determine whether or not streptococemia was present, blood taken from the heart or vena cava of all animals inoculated with streptococci was streaked on the surface of 5% rabbit blood agar and dropped into tubes of 5 ml of Todd-Hewitt broth. The hearts, kidneys, and adrenals were removed, as well as portions of lung, liver, spleen, pancreas, mesentery, and skeletal muscle. Blocks of tissues, including those cut transversely through the equators of the kidneys, were fixed in Zenker's-5% acetic acid solution or buffered formalin. Blocks fixed in the former were embedded in paraffin, and sections 5  $\mu$  thick were cut and stained routinely with hematoxylin and eosin. Some sections cut from blocks of kidneys were stained with Masson's trichrome, periodic acid-Schiff (PAS), or Azan stain. Other sections of kidneys were stained with Yello-solve I, MSB 109, or PAS-MSDB 109 stains, as described by Lendrum et al. (35, 36). Blocks of some kidneys fixed in formalin were also embedded in paraffin and sections 5  $\mu$  thick were cut and stained with Congo red or crystal violet.

*Measurement of Size of Sections of Renal Glomeruli and Number of Nuclei Therein.*—Sections 5  $\mu$  thick and stained with hematoxylin and eosin were used. An equatorial section of kidney was divided into three zones by India ink lines which extended from the capsule through the medulla. Beginning at the capsule of each zone and moving to the medulla, the diameters of 10 glomeruli were measured in each zone with an ocular micrometer, and the number of their nuclei counted with an ocular grid. Thus a total of 30 glomeruli were measured and counted in each section. Measurements and counts so made were found to be reproducible. This method provides for sampling of glomeruli in all layers of the cortex. The mean glomerular diameter and the mean number of nuclei per glomerular section were determined in the case of each of 66 rabbits that received one to many courses of inoculations with streptococci and each of 10 healthy control rabbits not inoculated with streptococci. For the control animals these values were 89.2 and 65.4  $\mu$  respectively. (Table I).

*Photomicrography.*—All photomicrographs were made by the authors on Kodachrome II, type A film with a Zeiss photomicroscope with achromatic-aplanatic condenser (1.40 N.A.), planachromatic or planapochromatic objectives, and neutral density D-12 (12% light transmittance) and Tiffen Photar 82C filters.

*Photolithography.*—The full color and black and white illustrations are photolithographs made without hand retouching or dot etching by the Litho-Krome Company, Columbus, Ga., from Kodachrome photomicrographs. Fidelity of color and structural detail in the color lithographs were achieved by carefully controlled photographic masking. Accurate tone values and structural detail in the black and white lithographs were achieved by use of two different plates, each printing a black ink. One plate imparts highlight, the other shadow detail.

*Morphologic Comparison between Human and Rabbit Glomerulonephritis.*—For the purpose of morphologic comparison between experimentally induced and naturally occurring glomerulonephritis, from acute to chronic stages, photolithographs of renal tissue of 11 rabbits are submitted alongside those of renal tissue of 7 humans. The sex and age of the patients were as follows: one boy and two girls were 4-6 yr old, two teenage males were 14-16 yr, and one man and one woman were 28 and 59 yr, respectively. Specimens of kidney of four of the patients were obtained by biopsy. The kidneys of the remaining three patients were obtained at autopsy. The human kidneys were prepared for microscopic examination by the methods used to prepare the rabbit kidneys. Acute glomerulonephritis was present in four patients, two children, one adult, and a 14 yr old male, and caused the deaths of the latter and a four yr old girl. Glomerulonephritis in a recurrent acute to subacute stage was present in one patient, a 16 yr old male. Chronic glomerulonephritis was present in a 5 yr old boy and a 59 yr old woman, and caused the death of the latter. From five of the seven patients with glomerulonephritis, clear-cut serologic or bacteriologic evidence of recent infection with Group A streptococci was obtained. From the nose, throat, and an infected postauricular mass of the sixth patient who died with acute glomerulonephritis,  $\beta$ -hemolytic streptococci were cultured, but

no attempt was made to identify the serologic group to which they belonged. In the seventh patient, the nephrotic syndrome developed a few months after a severe sore throat at 52 yr of age and was found from examination of biopsied kidney to be a manifestation of diffuse proliferative glomerulonephritis. Progressive deterioration of renal function followed and death due to chronic glomerulonephritis with azotemia occurred 7½ yr after appearance of the first signs of glomerulonephritis. Serologic, bacteriologic, and other pertinent clinical data concerning the 7 patients and comparable data concerning the 11 rabbits are presented with the explanations of the respective photolithographs. Finally, for the purpose of morphologic comparison of normal with nephritic rabbit kidneys, photomicrographs of normal kidneys are submitted alongside those of the nephritic kidneys.

#### RESULTS

8 days to a few weeks after onset of a given infection with Group A streptococci known to have been nephritogenic for man, marked proteinuria, often with hematuria, and occasionally with azotemia, was detected in 22 of the 106 rabbits in the experiments here reported. 15 of these rabbits were sacrificed a few days to a few weeks thereafter, and 8 showed renal changes of acute glomerulonephritis. Such changes occurred in two other rabbits, whose urine was not examined, that were sacrificed 16 days after only one infection, which was produced with streptococci of Type London. Recurrent acute glomerulonephritis was found in 2 others of the 15 sacrificed soon after marked proteinuria was detected and in a rabbit whose urine was not examined that died 8 days after onset of infection with streptococci of Type London, which followed seven previous infections with streptococci of six different serotypes. The remaining seven animals in which marked proteinuria had occurred died or were sacrificed many months later, in some cases after additional infections. Two of these had become azotemic and two convulsed and died after giving birth; in these animals, there were renal changes of chronic latent glomerulonephritis or chronic active glomerulonephritis.

The various stages of the experimentally induced glomerulonephritis will be taken up separately and the renal changes compared with those of the various stages of poststreptococcal glomerulonephritis in man.

#### *Acute Glomerulonephritis*

Five examples are presented.

#### *Histories and Gross Anatomical Observations.—*

*Rabbit 97-06:* This male rabbit was inoculated, according to schedule A, with Type 12 streptococci of parent culture. On the 22nd day after the first inoculation, the rabbit was found to have gross hematuria. The urinary protein concentration was ++/++++. Cultures of peripheral blood on rabbit blood agar and in Todd-Hewitt broth were sterile. The rabbit was sacrificed 10 days later. Cultures of vena caval blood were sterile. The kidneys were 1.5 times normal weight.

*Rabbit 10-831:* This female rabbit was inoculated, according to schedule B, with in vivo-selected Type 1 (Mary) streptococci over a period of 10 days. Urinary protein was normal on

the second day, +/++++ (0.504 g/liter) on the third day, and normal on the 4 succeeding days. Hematuria was not detected on any of these days. On the 8th day, gross hematuria was observed and the urinary protein rose to +++/++++ (1.99 g/liter). It fell to +/++++ (0.64 g/liter) on the 9th day, and rose to +++/++++ (2 g/liter) on the 10th day, fell to 1.5 g/liter on the 11th day, and to normal on the 12th day at which time the rabbit was sacrificed. Cultures of vena caval blood were sterile. The kidneys were pale and their weight was 1.5 times normal.

*Rabbits 80-19 and 80-20:* These rabbits were inoculated, according to schedule C, on the same two successive days with Type London streptococci of parent cultures. On the 3rd, 8th, and 16th days after the first inoculation, blood cultures of both animals were made and were sterile. The sedimentation rate of erythrocytes (ESR) in 2 hr, in the case of rabbit 80-19, increased to 50 mm on the 5th day, fell to 25 mm on the 8th day, increased to 50 mm on the 10th day, and fell to 30 mm on the 16th day. The ESR in 2 hr, in the case of rabbit 80-20, increased to 80 mm on the 5th day and fell progressively to 70 mm on the 8th day, 45 mm on the 10th day, and 10 mm on the 16th day. In both animals, the number of leukocytes in the blood increased to a peak value on the 10th day, to 18,000/mm<sup>3</sup> in rabbit 80-19 and 24,000/mm<sup>3</sup> in rabbit 80-20. At no time was urine of either animal examined. The animals were sacrificed on the 16th day. The kidneys were not weighed.

*Rabbit 10-467:* This male rabbit was inoculated, according to schedule B, with in vitro-selected Type 12 streptococci over a period of 14 days. The urine remained normal during and after this course of inoculations. 4 months later, the rabbit was inoculated with in vitro-selected Type 1 streptococci over a period of 11 days. On the 11th day, +/++++ (0.83 g/liter) proteinuria was observed. 2 days later, proteinuria had disappeared. By the 15th day, the blood urea nitrogen (BUN) had risen from normal to 62 mg/100 ml. On the 20th day, ++/++++ (1.2 g/liter) proteinuria and microscopic hematuria were observed. The rabbit was sacrificed on the 23rd day, by which time the BUN had fallen to 23 mg/100 ml. Cultures of vena caval blood were sterile. The kidneys were 1.34 times normal weight. The cortices were obviously pale and contained numerous petechial hemorrhages (Figs. 1 *b* and 1 *d*).

*Histologic Observations.*—Proliferation and swelling of endothelial and mesangial cells, and to a lesser extent epithelial cells, were present in renal glomeruli of rabbits with acute glomerulonephritis that died or were sacrificed soon after the appearance of marked proteinuria. In rabbits with hypercellular glomeruli at the time of sacrifice 10 days or less after the beginning of the first series of inoculations, the nuclei of glomerular endothelial and mesangial cells were, in the majority, compact and deeply basophilic (Fig. 9). In contrast, in hypercellular glomeruli of rabbits that were sacrificed 2–4 wk after the beginning of the first series of inoculations or that were sacrificed or died after two or more series of inoculations, the nuclei of glomerular endothelial and mesangial cells were often, in the majority, vesicular and pale-staining, as in human acute proliferative glomerulonephritis (Figs. 18–20). A mitotic figure was rarely observed in an endothelial cell (Fig. 18) as is rarely observed in acute glomerulonephritis in man (Fig. 20).

As shown in Table I, in the kidneys of rabbits with acute glomerulonephritis (group I), the mean number of nuclei per glomerular section was 94 and the mean diameter of glomerular sections was 103.3  $\mu$ . In contrast, the values for these measurements were 65.13 and 88.74  $\mu$ , and 68.54 and 88.5  $\mu$ , respectively,

TABLE I  
*Number of Nuclei per Glomerular Section and Diameter of Glomerular Sections in Kidneys of Rabbits with Acute Glomerulonephritis and Rabbits without Glomerulonephritis*

Group No.	Rabbits in group*	No. of rabbits	Mean No. of nuclei per glomerular section	Mean diameter of glomerular sections ( $\mu$ )
I	Rabbits inoculated with streptococci, developed acute glomerulonephritis, and did not have terminal streptococemia	10	94 (SD $\pm$ 13.76)†	103.3 (SD $\pm$ 8.98)§
II	Rabbits inoculated with streptococci, did not have glomerulonephritis, and did not have terminal streptococemia	31	65.13 (SD $\pm$ 5.36)	88.74 (SD $\pm$ 5.385)
III	Rabbits inoculated with streptococci, did not have glomerulonephritis, but had terminal streptococemia	5	68.54 (SD $\pm$ 7.70)	88.5 (SD $\pm$ 5.28)¶
IV	Normal control rabbits not inoculated with streptococci	10	65.4 (SD $\pm$ 4.81)	89.2 (SD $\pm$ 3.59)

\* Animals in groups I and II were sacrificed at comparable times (between 11 and 32 days) after the beginning of a course of streptococcal inoculations. Animals in group III died between 5 and 12 days after the beginning of a course of streptococcal inoculations.

† Glomerular sections of group I are significantly more cellular than glomerular sections of groups II, III, and IV taken together.  $F = 10.9595$ ,  $P < 0.005$ .

§ Glomerular sections of group I are of significantly greater diameter than glomerular sections of groups II, III, and IV taken together.  $F = 28.6825$ ,  $P < 0.001$ .

|| Glomerular sections of group III are *not* more cellular than glomerular sections of group IV.  $F = 0.50277$ ,  $P > 0.25$ .

¶ Glomerular sections of group III are *not* of greater diameter than glomerular sections of group IV.  $F = 0.02071$ ,  $P > 0.25$ .

for the kidneys of rabbits comparably inoculated with streptococci but which did not develop renal disease (groups II and III) and 65.4 and 89.2  $\mu$  for control rabbits not inoculated with streptococci (group IV). Both the mean number of nuclei in glomerular sections and the mean diameter of glomerular sections were very significantly greater in kidneys of rabbits of group I than in kidneys of rabbits of groups II, III, and IV taken together. The magnitude of these



differences is enhanced if one expands this two dimensional data to apply to the three dimensional glomerulus. These differences in glomerular size and cellularity are illustrated in Figs. 2-5, 8-13, and 17-19.

Swollen, proliferating, endothelial and mesangial cells often narrowed or occluded the lumina of glomerular capillaries (Figs. 3-5, 9-13, 18, 19, 23, and 24), as is usually evident in human acute glomerulonephritis (Figs. 16, 20, 26, and 28). Necrosis of individual glomerular capillary loops (Fig. 24), and even entire glomerular lobules occasionally occurred, as in the human disease (Figs. 26 and 28). Proliferating cells caused many glomeruli to appear hyperlobulated (Figs. 10 and 13), as in the human disease (Fig. 16). Cellularity was occasionally more marked in some lobules of a glomerulus than in others in both the rabbit and human glomerulonephritis. The number of polymorphonuclear leukocytes in glomeruli of the kidneys of both the rabbits and the humans here reported was variable but usually small. When present, they were almost always in the lumina of glomerular capillaries, rarely in capillary walls or mesangium. Glomerular visceral epithelial cells were often swollen and moderately increased in number in both the rabbits and humans. As in poststreptococcal, proliferative glomerulonephritis in man, the glomerular basement membranes almost without exception did not appear to be thickened on examination with the light microscope. As in the human disease, plasma protein including fibrin, and/or erythrocytes, were sometimes present in Bowman's space and the lumen of renal tubules (Figs. 18, 19, 23, and 24). As in acute glomerulonephritis in man, the tubular epithelium was often swollen and vacuolated (Figs. 4, 5, and 12), and in some instances focally necrotic. Occasionally, small clusters of inflammatory cells, mostly lymphocytes, were adjacent to tubules and sometimes adjacent to the parietal layer of Bowman's capsules. The renal pelves were normal.

#### *Recurrent Acute Glomerulonephritis*

Three examples are presented.

#### *Histories and Gross Anatomical Observations.—*

*Rabbit 96-50:* This female rabbit was inoculated, according to schedule A, with Type 15 streptococci of parent culture. 2 wk after the first inoculation, the urine was normal. 2½ months later the rabbit was inoculated, according to schedule A, with Type 12 streptococci of parent culture. Neither proteinuria nor hematuria were detected at the following times thereafter: 2 wk, 4, 5, and 6 months. In the 7th month, ++/++++ proteinuria was detected. In the 12th month, the urinary protein was 0. 13 months after the second series of inoculations, the rabbit was inoculated, according to schedule B, with Type 49 streptococci of parent culture over a period of 14 days. On the 7th, 12th, and 17th days after the first inoculation of this series, urinary protein was 0/++++ (0 g/liter). On the 24th day, urinary protein was +/++++ (0.36 g/liter), but by the 54th day was normal and remained so on four urinalyses performed in the succeeding 6 months. 10 months after the third series of inoculations, the rabbit was inoculated, according to schedule B, with Type 1 (Mary) of

parent culture over a period of 14 days. On the 5th day after the first inoculation of this series, the urinary protein was 0/++++ (0 g/liter). On the 8th day, microscopic hematuria was detected and the urinary protein was +/++++ (0.432 g/liter). Urinary protein remained at this level and microscopic hematuria persisted until sacrifice on the 19th day. Cultures of the blood were sterile. The kidneys were pale and 1.5–2 times normal weight. The renal cortices were finely pitted and contained petechial hemorrhages.

*Rabbit 96-52:* This female rabbit was inoculated, according to schedule A, with Type 12 streptococci of parent culture. No urinalyses were performed in association with these inoculations. 2 months later, the rabbit was inoculated, according to schedule A, with Type 15 streptococci of parent culture. On the 14th day after the first inoculation, the urinary protein was 0/++++. 5 months after the second series of inoculations, the rabbit received, according to schedule B, a series of inoculations with Type 49 streptococci of parent culture. On the 20th day after the first inoculation of this series, the urinary protein was 0/++++, on the 28th day +/++++, and on the 58th day 0/++++. 7 months after the third series of inoculations, the rabbit received, according to schedule B, a series of inoculations with Type 12 streptococci of parent culture over a period of 14 days. On the 7th day after the first inoculation, the urinary protein was 0/++++ (0 g/liter). On the 12th day, microscopic hematuria was detected and the urinary protein was ++/++++ (1.152 g/liter). The latter remained elevated for 7 days. During the next 10 months, modest intermittent proteinuria occurred. At the end of this time, the rabbit was inoculated, according to schedule B, with Type 1 (Mary) streptococci of parent culture over a period of 14 days. On the 8th day after the first inoculation of this series, the urinary protein was 0/++++ (0 g/liter). On the 15th day, microscopic hematuria was detected and the urinary protein was +/++++ (1.08 g/liter) and remained elevated until sacrifice on the 19th day. Cultures of blood were sterile. The kidneys were pale and 1.5–2 times normal weight. The cortices were pitted and contained petechial hemorrhages.

*Rabbit 70-55:* This female rabbit was inoculated repeatedly according to schedule C. 5 times, at intervals of 4 to 8 wk, streptococci of parent cultures of the following serotypes were inoculated: Types 1 (strain K43), 11, 17, 13, and 3. 3 months later, the animal was inoculated with Type 19 streptococci, and 6 wk subsequently with Type 17 streptococci. 4 months later the rabbit was inoculated with Type London streptococci and sickened on the 6th day after onset of infection. On the 8th day, the ESR was 125 mm in 1 hr and the animal died. There had been no examination of urine. At autopsy Group A, Type London streptococci were cultured from vena caval blood. The kidneys appeared pale and swollen, but were not weighed. On cut surface, the cortico-medullary junctions and cortical markings were indistinct, and the cortices had a finely mottled pale yellow appearance.

*Histologic Observations.*—The renal changes in rabbits 96-50 and 96-52 will be taken up first and separately from those in rabbit 70-55. Proliferation and swelling of glomerular endothelial, mesangial, and epithelial cells were present and many cells contained vesicular nuclei (Figs. 14, 21, 25, 27, and 29–33). The mean number of nuclei per glomerular section and mean diameter of glomerular sections in these rabbits were 83.5 and 104.5  $\mu$ , respectively (normal 65.4 and 89.2  $\mu$ , respectively). Glomerular basement membranes did not appear, by light microscopy, to be thickened. Focal necrosis of individual capillaries as well as entire lobules occurred in some glomeruli (Figs. 14, 21, 25, 27, 29, and 30), as occurs in human glomerulonephritis (Figs. 26 and 28). Plasma protein including fibrin, and/or erythrocytes, were often present in Bowman's space

(Figs. 21, 25, 27, and 29). About such extravasated material, epithelial cells had sometimes proliferated and formed epithelial crescents like those in human glomerulonephritis (Figs. 29-35). The experimentally induced crescents were not significantly collagenized or hyalinized, which along with the proliferative and exudative characteristics described above indicates that they were of recent origin and probably developed during the period of 19 days after the beginning of the last series of inoculations. It is reasonable to infer likewise that the very similar crescents in the patient referred to in Figs. 34 and 35 were of recent origin and developed during the period of 1 month after the last upper respiratory infection. In the rabbits, plasma protein and/or erythrocytes were present in some renal tubules (Figs. 22 and 25) and vacuolization and degeneration of some tubular epithelial cells (Fig. 22) were observed. Adjacent to altered tubules were occasional clusters of inflammatory cells, mostly lymphocytes. In addition, there was evidence of previous injury to the kidneys. Hyalinized scars replaced lobules of some glomeruli and fibrous adhesions between tuft and capsule were present in others. Occasional glomeruli with fibrotic capsules and a few completely atrophic, hyalinized glomeruli were observed, especially in rabbit 96-52. There were several ectatic tubules, some of which were filled with hyaline casts. Focally, there were slightly increased amounts of collagenous tissue in the renal interstitium. Within this tissue, remnants of atrophic nephrons were sometimes present. The renal pelves were normal.

The striking feature of the kidneys of rabbit 70-55 was the marked swelling of glomerular tufts. This swelling, illustrated in Fig. 6, was associated with moderate increase, sometimes focally accentuated, of endothelial, mesangial, and epithelial cells. Widening of the mesangial regions appeared to be due to edema and cellular proliferation and swelling. Very similar changes may occur in acute glomerulonephritis in man (Fig. 7). The mean number of nuclei per glomerular section and the mean diameter of glomerular sections in rabbit 70-55 was 115 and 154  $\mu$ , respectively (normal 65.4 and 89.2  $\mu$ , respectively). The glomerular basement membranes did not appear, by light microscopy, to be thickened. Some glomeruli appeared hyperlobulated (Fig. 15), as in acute glomerulonephritis in man (Fig. 16). In addition, there was, as in rabbits 96-50 and 96-52, evidence of previous injury to the kidneys. There was hyaline thickening of some Bowman's capsules (Figs. 6 and 15), some glomeruli were completely atrophic and hyalinized, and occasional tubules were ectatic.

#### *Chronic Latent Glomerulonephritis*

*Chronic Latent Glomerulonephritis with Superimposed Toxemia of Pregnancy.* Some rabbits which had developed marked proteinuria, sometimes with hematuria, after inoculations with Group A streptococci were mated. Two such rabbits died after convulsions at the end of pregnancy. One of these cases will be described in detail.

*History and Gross Anatomical Observations.—*

*Rabbit 96-26:* This female rabbit was inoculated, according to schedule A, with Type 49 streptococci of parent culture. On the 4th day after the first inoculation, no protein was detected in the urine. On the 12th day, +++/++++ (2.6 g/liter) protein and many erythrocytes were detected in the urine. 10 and 40 days later the urine was normal. 3 months after the first series of inoculations, the rabbit received, according to schedule A, a series of inoculations with Type 12 streptococci of parent culture. On the 12th day after the first inoculation of this series, the urine was normal. 3 months later, the rabbit was mated. Midway through gestation the urine was normal. A few hours after giving birth to four normal young, the rabbit began to convulse and died 1 hr later. Autopsy was performed immediately thereafter and +/++++ proteinuria was detected in bladder urine. The kidneys were pale and 1.5-2 times normal weight. The finely granular cortices contained petechial hemorrhages.

*Histologic Observations.—*Endothelial and mesangial cells were swollen and increased in number, often to the point of occluding glomerular capillary lumina (Figs. 36, 37, and 39). Exclusive of scarred glomeruli, the mean number of nuclei per glomerular section and the mean diameter of glomerular sections were 95 and 98  $\mu$ , respectively, (normal 65.4 and 89.2  $\mu$ , respectively). Because of increase in number and size of cells, many glomeruli appeared hyperlobulated (Figs. 38 and 39). As in the kidneys of rabbits with acute or recurrent acute glomerulonephritis, endothelial and mesangial cell nuclei were in the majority vesicular. Glomerular basement membranes did not appear, by light microscopy, to be thickened. Small amounts of protein were occasionally present in Bowman's spaces and in renal tubules. Many tubular epithelial cells were swollen and vacuolated (Figs. 37-40). In addition, there was evidence of renal disease antedating pregnancy. Many glomeruli contained lobular scars (Figs. 38 and 40) such as are sometimes found in poststreptococcal glomerulonephritis in man (Fig. 41). Some glomeruli were held by fibrous adhesions to the parietal layer of Bowman's capsule (Fig. 38). Occasional glomeruli were entirely or partially hyalinized (Fig. 39). Slight fibrosis of the renal interstitium was also observed. The renal pelves were normal.

*Chronic Latent Glomerulonephritis with Death Caused by Intercurrent Pneumonia.**History and Gross Anatomical Observations.—*

*Rabbit 99-41:* This male rabbit was inoculated, according to schedule B, with Type 12 streptococci of parent culture over a period of 15 days. 10 days after the first inoculation, microscopic hematuria and +/++++ (0.5 g/liter) proteinuria were detected. Urinary protein returned to normal within 6 days. 4 months later, the rabbit received, according to schedule B, a series of inoculations with Type 49 streptococci of parent culture over a period of 12 days. On the 6th, 19th, 27th, 30th, and 46th day after the first inoculation of this series the urinary protein was normal. 5 months after this series of inoculations, the rabbit was inoculated, according to schedule B, with Type 1 (Mary) streptococci of parent culture over a period of 14 days. On the 10th day, +/++++ (0.514 g/liter) urinary protein and microscopic hematuria were observed. Urinary protein remained elevated for 1 wk, at the end of which the blood urea nitrogen was 37 mg/100 ml. During the 6 months thereafter, transient

increases in urinary protein, i.e. +++++ (0.5 g/liter), occurred. The rabbit was then inoculated, according to schedule B, with Type 12 streptococci of parent culture over a period of 10 days. On the 9th day, the blood urea nitrogen was 40 mg/100 ml and the urinary protein was normal. 3 months later, the blood urea nitrogen was 40 mg/100 ml and the urinary protein +++++ (0.5 g/liter). Proteinuria persisted until the rabbit died of intercurrent pneumonia due to a Gram-negative bacillus, probably of the Pasteurella group, 6 months after the last series of inoculations. At autopsy the renal cortices were finely granular. The weight of the kidneys was normal.

*Histologic Observations.*—Approximately 30% of glomeruli were entirely sclerotic. Fibrosis and hyalinization of the parietal layer of Bowman's capsule were present in many other glomeruli. Remaining glomeruli were hypercellular and larger than normal. These changes, very similar to those described by Bell (37) as representing "latent chronic" glomerulonephritis in man, are illustrated in Figs. 42, 45, and 48. Figs. 43 and 46 show similar changes present in the kidneys of a woman with chronic glomerulonephritis of 7½ yr duration. Exclusive of sclerotic glomeruli, the mean number of nuclei per glomerular section and the mean diameter of glomerular sections in the kidneys of rabbit 99-41 were 83 and 106  $\mu$ , respectively (normal 65.4 and 89.2  $\mu$ , respectively). The increased cellularity appeared to be mainly due to proliferation of cells in the mesangial regions. These regions also contained increased amounts of fibrillar tissue, most of which stained like young mesangial fibers and some of which stained like mature collagen. Focal necrosis of glomerular tufts in association with escape of protein was rarely observed (Fig. 48). Many renal tubules were shrunken or ectatic, and some contained hyaline casts. Interstitial fibrous tissue was moderately to markedly increased in amount, and within it were remnants of atrophic nephrons (Figs. 45 and 48). The renal pelves were normal.

#### *Chronic Active Glomerulonephritis*

##### *History and Gross Anatomical Observations.*—

*Rabbit 96-38:* This male rabbit was inoculated, according to schedule A, with Type 12 streptococci of parent culture. On the 12th day after the first inoculation, the urine was normal. 2 months after the first series of inoculations, the rabbit received, according to schedule A, a series of inoculations with Type 49 streptococci of parent culture. No urinalyses were performed in association with these inoculations. 7 months later, the rabbit was inoculated, according to schedule B, with Type 12 streptococci of parent culture over a period of 16 days. 26 days after the first inoculation of this series, gross hematuria and +++/++++ proteinuria were observed. 1 month later, ++/++++ protein in the urine was detected, and by the 5th month the urine was normal. 8 months after the third series of inoculations, the rabbit was inoculated, according to schedule B, with Type 49 streptococci of parent culture. On the 2nd and 9th days after the first inoculation of this series, the urine was normal. Urinary protein on the 12th day was +++++ (0.5 g/liter) and rose to ++++/++++ (4.32 g/liter) on the 15th day. On subsequent days the urinary protein was as follows: 17th day, ++++/++++ (2.66 g/liter); 22nd day, +++/++++ (1.62 g/liter); and 52nd day, ++/++++ (0.82 g/liter). Thereafter, the urinary protein declined gradually to 0.36 g/liter over a period of 2 months, but never returned to normal. The rabbit then began

to lose weight rapidly and was sacrificed 6 months after the beginning of the last series of inoculations. Blood urea nitrogen 1 day antemortem was 206 mg/100 ml. Although the renal cortices were shrunken, the weight of the kidneys was normal.

*Histologic Observations.*—The vast majority of glomeruli were partly or entirely sclerotic. Fibrous crescents were present in some glomeruli. There were many diffusely or focally scarred glomerular tufts with hyalinized adhesions to Bowman's capsules. Rare, hypertrophied glomeruli were observed. The majority of the tubules were atrophic and surrounded by dense fibrous tissue. Nests of markedly ectatic tubules were also present. Hyaline casts were observed in many tubules. These changes are illustrated in Figs. 44, 47, and 50. Glomeruli in formalin-fixed sections took up neither Congo red nor methyl violet stains. The renal pelves were normal. Figs. 43, 46, and 49 show renal changes in two humans with chronic glomerulonephritis that are similar to those in rabbit 96-38.

#### DISCUSSION

The experimental induction of glomerulonephritis with streptococci or their products has been attempted many times in the past (38-41). The methods employed included inoculation with living streptococci, implantation of micro-pore diffusion chambers containing living streptococci, injection of killed streptococci, and injection of toxic filtrates. The renal alterations induced by these procedures or combinations thereof are not analogous to the spectrum of renal changes that occur in poststreptococcal glomerulonephritis in man.

The question arises: Why did a spectrum of changes like those of glomerulonephritis in humans develop in rabbits in the experiments now reported, whereas previous attempts to induce this spectrum of changes with Group A streptococci were apparently unsuccessful? There are several possible explanations.

First, the strains of Group A streptococci which induced glomerulonephritis in rabbits in the experiments now reported were, with one exception, originally isolated from humans with or exposed to others with acute glomerulonephritis. The one exception is a strain of streptococci of Type London originally isolated from the blood of a patient with puerperal septicemia (42) but not known to be nephritogenic for man. However, we have recently learned of an epidemic in 1961-62 of acute glomerulonephritis among children in Břilina, Czechoslovakia, from whom Group A streptococci were cultured in the acute stage of the disease and identified as Type London streptococci.<sup>3</sup> In many of the previously reported experiments, the Group A streptococci used had not been obtained from patients with acute glomerulonephritis. In earlier experiments performed in this laboratory, kidneys of 131 rabbits, which had been successively infected intracutaneously with Group A streptococci of 1-13 different

<sup>3</sup> Srámek, J., R. C. Lancefield, and C. G. Becker. Personal communications.

serotypes, were examined microscopically. Acute proliferative glomerulonephritis was found to have developed in a majority of animals last infected with either one of two of these strains, but only rarely or not at all in animals last infected with one of the other strains.<sup>4</sup> The observation that only two among many strains of Group A streptococci were capable of inducing acute glomerulonephritis with frequency in rabbits is analogous to the observations of Rammelkamp (43) and others which indicate that only certain strains of Group A streptococci are capable of inducing acute glomerulonephritis with frequency in man. Taken together, these observations suggest that nephritogenicity of certain strains of Group A streptococci can be manifested in animal species in addition to man.

Second, in our experiments most of the rabbits were infected repeatedly, usually with strains of different serotypes. It is likely that most humans with clinically evident acute glomerulonephritis have had at least one and perhaps several infections with Group A streptococci of different serotypes before the infection that is followed by glomerulonephritis.

Third, living streptococci were inoculated into the rabbits in our experiments. This permitted intimate contact between cells of the host and the population of parasites. Such contact is perhaps necessary if selection of streptococci capable of establishing infection in the host is to occur. Such selection could not occur if streptococci were kept from the cells of the host by the walls of a diffusion chamber.

In experiments reported here, some rabbits developed slight transient proteinuria (0.2–0.3 g/liter, rarely greater) during the first few days of a course of inoculations. Marked proteinuria (++++ or 0.5–4.32 g/liter) and hematuria, sometimes gross, developed from 8 days to 3 wk after the beginning of a course of inoculations. The sequence of events comprising streptococcal infection, slight and transient proteinuria within a few days, and then marked proteinuria, often with hematuria, after a latent period of 8 days to a few weeks following the infection is strikingly like that which occurs in humans who develop glomerulonephritis following streptococcal infection.

Rammelkamp (43) and others have interpreted the transient proteinuria which occurs within the first few days of a streptococcal infection in humans as an expression of renal injury from the action of a toxin. The results of our experiments support the hypothesis that early, transient proteinuria following streptococcal infection is the result of toxin-induced rather than immunologically induced injury to the kidneys, in that early, slight and transient proteinuria was detected in some rabbits after the first inoculation with Group A streptococci. Since rabbits are not naturally parasitized by Group A streptococci, it is very unlikely that any antibodies to these microorganisms had been elaborated in these rabbits before we infected them with Group A streptococci.

---

<sup>4</sup> Murphy, G. E., and C. G. Becker. Unpublished observations.

As stated previously, a latent period of from 8 days to a few weeks was observed between the first of a course of streptococcal inoculations and the development of marked proteinuria in rabbits. Temporally, this latent period is like that between the beginning of streptococcal infection and the onset of glomerulonephritis in man. It is reasonable to speculate that similar events occur in both rabbits and humans during this latent period. Von Pirquet (9, 10) implied that postscarlatinal nephritis is a manifestation of allergy in which persisting microorganisms that caused the scarlet fever react with antibodies produced against them during the latent period between scarlet fever and glomerulonephritis. Recently, a number of investigators (44-47) have demonstrated by immunofluorescence microscopy deposits of immunoglobulins in glomeruli in biopsied renal tissue of patients with proved poststreptococcal acute glomerulonephritis, which is in harmony with von Pirquet's hypothesis.

Among rabbits that developed poststreptococcal acute or recurrent acute glomerulonephritis in our experiments, deposits of immunoglobulins in glomeruli can be demonstrated in some of these animals but not in others by immunofluorescence microscopy.<sup>5</sup> Similarly, among a large group of humans with poststreptococcal acute glomerulonephritis, Seegal<sup>6</sup> can demonstrate by immunofluorescence microscopy deposits of immunoglobulins in glomeruli in some of these patients but not in others, including cases of severe glomerulonephritis. The events that occur during the latent period, that is, before glomerulonephritis is manifest, remain obscure. It is hoped that these events can be elucidated through investigation of glomerulonephritis induced experimentally by infection with Group A streptococci.

The blood cultures taken at autopsy of all of 10 rabbits with acute glomerulonephritis were sterile, which indicates that the acute glomerulonephritis in these rabbits was not due to streptococcemia. This conclusion is supported by the fact that streptococcemia as demonstrated by positive blood cultures at autopsy was an uncommon occurrence in these experiments. Of the remaining 96 rabbits infected with streptococci, only 6 died with streptococcemia. One of these, rabbit 70-55 exhibited renal changes that probably represented recurrent acute glomerulonephritis. As shown in Table I, sections of renal glomeruli of the remaining five that died with streptococcemia (group III) were neither more cellular nor of greater diameter than those of control rabbits not inoculated with streptococci (group IV) or those of rabbits inoculated with streptococci but which neither developed glomerulonephritis nor died with streptococcemia (group II).

Cellular proliferation in glomeruli was common to the kidneys of the majority of rabbits sacrificed soon after developing marked proteinuria following streptococcal infections. However, exudation of fibrinous material from glomeruli was

<sup>5</sup> Becker, C. G., Unpublished observations.

<sup>6</sup> Seegal, B. C. Personal communication.



slight in some rabbits and marked in others. Rabbits could be classified into two groups based on the character of glomerular lesions observed: (*a*) those with proliferative lesions with little or no exudate, and (*b*) those with proliferative lesions with a considerable amount of exudate. When rabbits are so classified, two features emerge.

First, rabbits which received only one or two courses of streptococcal infection, developed marked proteinuria, and were sacrificed shortly thereafter, were found to have proliferative glomerular lesions with minimal exudate. In contrast, some rabbits which received four or more courses of streptococcal infection, developed marked proteinuria, and were sacrificed shortly thereafter, were found to have proliferative-exudative lesions. This observation suggests that damage to the wall of the glomerular capillary severe enough to result in significant exudation of plasma protein may be related directly to the number of streptococcal infections experienced by the rabbits. It may thus be an expression of intensity of allergy to streptococcal products.

Second, the development of epithelial crescents was only observed in the kidneys of rabbits with proliferative-exudative lesions. As illustrated, epithelial cells in the process of forming crescents proliferate about fibrinous exudate in Bowman's space in both rabbits and humans with glomerulonephritis.

One of the most persistent questions concerning the natural history of glomerulonephritis following streptococcal infection in humans is whether or not acute glomerulonephritis can progress to chronic glomerulonephritis. Löhlein (7), in 1907, concluded that such progression did occur. Subsequently, several clinical investigators (48-50) reached the same conclusion from observations made over several to many years. From histologic examination of kidneys of adults biopsied serially during and after attacks of acute poststreptococcal glomerulonephritis, Jennings and Earle (51) and McCluskey and Baldwin (52) obtained evidence of progression of the disease to chronic glomerulonephritis.

Among rabbits in our experiments, some developed functional and anatomical evidence of recurrent acute glomerulonephritis, of chronic latent glomerulonephritis, or of chronic active glomerulonephritis following infections with Group A streptococci. Certain features of both the histories of these rabbits and the anatomical alterations in their kidneys may bear on the question of what factors determine progression of poststreptococcal glomerulonephritis in humans.

Rabbits 96-50 and 96-52 were sacrificed 19 days after the fourth and fifth courses, respectively, of inoculations with streptococci. At the time of sacrifice, they had proteinuria which was first detected at 8 and 15 days, respectively, after the first inoculation of the last series. No proteinuria was detected on the 5th and 7th days, respectively, after this inoculation. When their kidneys were examined, proliferative-exudative glomerular lesions with epithelial crescents

were found. These were not significantly collagenized or hyalinized and appeared to have developed after the beginning of the final series of inoculations with streptococci. In addition, rare hyalinized glomeruli or focal hyalinized scars in glomerular tufts were also present. These scars appear to be the result of glomerular injury sustained as a result of previous series of inoculations. In fact, proteinuria was detected in these rabbits after one or more of the previous series of inoculations.

On the basis of these observations, we interpret the changes in the kidneys of rabbits 96-50 and 96-52 as representing a recurrence of acute glomerulonephritis. The suggestion is made, therefore, that humans who develop acute glomerulonephritis with proliferative-exudative glomerular lesions and epithelial crescent formation may be suffering from recurrent acute glomerulonephritis. The previous episodes of glomerulonephritis may have gone unnoticed clinically and caused little, if any, permanent anatomic alteration of the kidneys. However, their effect, perhaps cumulative, may have been to increase the sensitivity of the kidneys to further attacks of glomerulonephritis, which by virtue of the increased sensitivity are of greater severity.

Support for this inference can be found in the case of rabbit 96-38.

This rabbit received four series of inoculations with streptococci. Marked proteinuria was observed after the third series and then ceased. The urine remained normal for the succeeding 7 months. The rabbit then received a fourth series of inoculations and on the 12th day marked proteinuria was again observed, although the urine had been normal on the 9th day. Proteinuria increased to 4.32 g/liter, the greatest excretion of protein observed in these experiments, and gradually decreased, but never ceased. The rabbit became severely azotemic and moribund, and was sacrificed 6 months after the last series of inoculations. The vast majority of glomeruli were entirely sclerotic. Fibrous crescents were present about some scarred glomeruli, suggesting a significant degree of exudate from damaged glomeruli during an acute phase of glomerulonephritis. Minimal recent exudate was present about some glomeruli. Glomeruli in which there were still some patent capillaries were hypercellular.

The history and anatomical alterations of the kidneys of this rabbit are strikingly like those of humans who develop acute glomerulonephritis and progress over a period of several months to 1 or 2 yr through chronic active glomerulonephritis to death. In such patients, the beginning of their terminal illness is usually considered to be the time of onset of acute glomerulonephritis. Because little is known of such patients prior to this time, they are usually thought to be suffering from their first attack. However, it is possible that they are suffering from a recurrent attack of glomerulonephritis. Previous clinically unnoticed or short-lived attacks may have so conditioned them that the final attack of glomerulonephritis is severe and the disease is now maintained at a high level of activity leading to the eventual and often surprisingly rapid

destruction of the majority of nephrons. This hypothesis is supported by results of experiments reported here.

In 1938, Bell (37) described certain anatomical changes in the kidneys of a woman who had survived acute glomerulonephritis and of several other adults without such history. All had minimal clinical evidence of renal disease at the time of their death from nonrenal causes. The renal changes consisted of complete hyalinization of some glomeruli, usually about 10%, while remaining glomeruli were enlarged and hypercellular. Epithelial crescents were in most cases inconspicuous or absent. Bell interpreted these changes as representing "latent chronic glomerulonephritis," or an intermediate stage between a primary acute attack of glomerulonephritis and the terminal chronic stage. More recently, similar changes have been described by Jennings and Earle (51) in the kidneys of patients subjected to serial renal biopsy at various times after recovery from the initial manifestations of acute poststreptococcal glomerulonephritis. At the time of biopsy, these patients were relatively well, but had modest proteinuria. McCluskey and Baldwin (52) referred to this stage of disease as latent glomerulonephritis and observed that some of these patients apparently recovered, whereas in others the disease progressed.

Two rabbits in our experiments developed renal alterations similar to those in humans with chronic latent glomerulonephritis.

In the case of rabbit 96-26, marked proteinuria was detected 12 days after the beginning of the first series of inoculations with streptococci. Proteinuria had disappeared 10 days later. 3 months thereafter, the rabbit received another series of inoculations after which proteinuria was not detected. 3 months after this series, the rabbit was mated. After a normal period of gestation, the rabbit gave birth to four normal young, convulsed several times, and died. The kidneys were large, pale, and pitted. Glomeruli were large, hypercellular, and hyperlobulated, and approximately 10% were completely hyalinized or contained hyalinized lobules. The case of this rabbit is analogous to some cases of toxemia of pregnancy in man. These observations suggest that in the latent stage of chronic poststreptococcal glomerulonephritis altered renal reactivity is present but unapparent, and may be accentuated by physiological conditions and events other than streptococcal infections, in this instance gestation and labor.

Another example of this phenomenon may have occurred in the case of rabbit 99-41. After the third of four series of inoculations, the rabbit developed modest proteinuria and azotemia which persisted for 12 months until death from intercurrent pneumonia due to a Gram-negative bacillus. At autopsy, the renal cortices were finely granular. Approximately 30% of glomeruli were completely sclerotic. Other glomeruli were large and hypercellular, particularly in mesangial regions. Protein, freshly exuded, was present in Bowman's space of a few glomeruli. It is possible that these proliferative and exudative changes were accentuated by the intercurrent pulmonary infection.

The above interpretation implies that in chronic latent glomerulonephritis persistence and progression of renal disease, at however low a level, may be the result of altered host reactivity to a wide variety of endogenous and exogenous stimuli, in addition to Group A streptococci of nephritogenic strains which originally induce the altered reactivity.

#### SUMMARY

106 rabbits received one or more courses of inoculations, spaced 1-4 months apart, with Group A streptococci, usually of strains isolated from patients with acute glomerulonephritis. 8 days to a few weeks after onset of a given infection with streptococci known to have been nephritogenic for man, marked proteinuria, often with hematuria and occasionally with azotemia, was detected in 22 of the animals. 15 of these were sacrificed a few days to a few weeks thereafter, and 10 showed renal changes like those of acute or recurrent acute glomerulonephritis in man. Such changes occurred in three other rabbits whose urine was not examined that died or were sacrificed 1-3 wk after onset of infection with streptococci of a serotype known to include a strain nephritogenic for man. The remaining seven animals in which marked proteinuria had occurred died or were sacrificed many months later, in some cases after additional infections. Two of these had become azotemic and two convulsed and died after giving birth; in these animals, there were renal changes like those that occur in man in chronic latent glomerulonephritis, toxemia of pregnancy superimposed on chronic latent glomerulonephritis, or chronic active glomerulonephritis. Anatomical changes in the kidneys in the experimentally induced and in naturally occurring glomerulonephritis, from acute to chronic stages, are compared and illustrated. The pathogenesis of poststreptococcal glomerulonephritis is discussed.

It is a pleasure to acknowledge the technical assistance of Miss Gioconda Carrozza, Mr. John Shuman, Mrs. Clara Reiss, Miss Judith Chesner, Miss Kathy Kalty, Miss Margaret Poire, and Mr. Nicolas Blagojevic in this investigation.

The high quality of work of Mr. J. Tom Morgan and Mr. Walter G. Barbee, Jr. of the Litho-Krome Co., Columbus, Ga., in making the photolithographic illustrations is appreciated.

#### BIBLIOGRAPHY

1. Burserius de Kanilfeld, J. B. 1801. *The Institutions of the Practice of Medicine*. (Translated from the Latin by W. C. Brown.) Cadell and Davies, Edinburgh. 2:420.
2. von Plenciz, M. A. 1762. *Tractatus III de Scarlatina*. J. T. Trattner, Vienna.
3. Dobell, C. 1932. *Antony van Leeuwenhoek and His "Little Animals"*. Harcourt, Brace & Co., New York.
4. Wells, W. C. 1812. Observation on the dropsy which succeeds scarlet fever. *Trans. Soc. Imp. Med. Chir. Knowledge*. 3:167.

5. Bright, R. 1827. Reports of Medical Cases Selected with a View of Illustrating the Symptoms and Cure of Diseases by a Reference to Morbid Anatomy. Longman, London. **1**:1.
6. Reichel, H. 1905. Über Nephritis bei Scharlach. *Z. Heilk.* **6**:72.
7. Löhlein, M. 1907. Über die entzündlichen Veränderungen der Glomeruli der menschlichen Nieren und ihre Bedeutung für die Nephritis. Arbeiten aus dem pathologischen Institut zu Leipzig. S. Hirzel, Leipzig. 1.
8. Schick, B. 1907. Die Nachkrankheiten des Scharlach. *Jahrb. Kinderheilk.* **65**(Suppl.):132.
9. von Pirquet, C. E. 1911. Allergy. *Ann. Internal Med.* **7**:424.
10. von Pirquet, C. E., and B. Schick. 1905. Die Serumkrankheit. Deuticke, Leipzig and Vienna.
11. Gabritchewsky, G. 1907. Über Streptokokkenerytheme und ihre Beziehungen zum Scharlach. *Berlin Klin. Wochenschr.* **44**:556.
12. Dick, G. F., and G. H. Dick. 1923. Experimental scarlet fever. *J. Am. Med. Assoc.* **81**:1166.
13. Dochez, A. R., and L. Sherman. 1924. The significance of streptococcus hemolyticus in scarlet fever; and the preparation of a specific anti-scarlatinal serum by immunization of the horse to streptococcus hemolyticus scarlatinae. *J. Am. Med. Assoc.* **82**:542.
14. Bloomfield, A. H., and A. R. Felty. 1923. Bacteriologic observations on acute tonsillitis with reference to epidemiology and susceptibility. *Arch. Internal Med.* **32**:483.
15. Longcope, W. T. 1929. The pathogenesis of glomerular nephritis. *Bull. Johns Hopkins Hosp.* **45**:335.
16. Lyttle, J. D., D. Seegal, E. N. Loeb, and E. L. Jost. 1938. The serum antistreptolysin titer in acute glomerulonephritis. *J. Clin. Invest.* **17**:632.
17. Lancefield, R. C. 1933. Serological differentiation of human and other groups of hemolytic streptococci. *J. Exptl. Med.* **57**:571.
18. Seegal, D., and D. P. Earle, Jr. 1941. A consideration of certain biological differences between glomerulonephritis and rheumatic fever. *Am. J. Med. Sci.* **201**:528.
19. Rammelkamp, C. H., Jr., R. S. Weaver, and J. H. Dingle. 1952. Significance of the epidemiological differences between acute nephritis and acute rheumatic fever. *Trans. Assoc. Am. Physicians.* **65**:168.
20. Rammelkamp, C. H., Jr., and R. S. Weaver. 1953. Acute glomerulonephritis. The significance of the variations in the incidence of the disease. *J. Clin. Invest.* **32**:345.
21. Stetson, C. A., C. H. Rammelkamp, Jr., R. M. Krause, R. J. Kohen, and W. D. Perry. 1955. Epidemic acute nephritis: Studies on etiology, natural history, and prevention. *Medicine.* **34**:431.
22. Wertheim, A. R., J. D. Lyttle, E. N. Loeb, D. P. Earle, Jr., B. C. Seegal, and D. Seegal. 1953. The association of type-specific hemolytic streptococci with acute glomerulonephritis. *J. Clin. Invest.* **32**:359.
23. Goldsmith, H. J., M. A. Cowan, and E. Gooder. 1958. Familial outbreak of acute glomerulonephritis due to Griffith type 1 streptococcus. *Lancet.* **2**:674.

24. Kleinman, H. 1954. Epidemic acute glomerulonephritis at Red Lake. *Minn. Med.* **37**:479.
25. Becker, C. G. 1964. Selection of group A streptococci rich in M-protein from populations poor in M-protein. *Am. J. Pathol.* **44**:51.
26. Musser, J. H., R. H. Turner, and W. A. Sodeman. 1937. A group of patients showing either heart failure or acute nephritis with onset within three weeks after delivery. *Trans. Assoc. Am. Physicians.* **52**:198.
27. Futcher, P. H. 1940. Glomerular nephritis following skin infections. *Arch. Internal Med.* **65**:1192.
28. Murphy, G. E., and H. F. Swift. 1949. Induction of cardiac lesions, closely resembling those of rheumatic fever, in rabbits following repeated skin infections with group A streptococci. *J. Exptl. Med.* **89**:687.
29. Murphy, G. E. 1960. Nature of rheumatic heart disease, with special reference to myocardial disease and heart failure. *Medicine.* **39**:306.
30. Shevsky, M. C., and D. D. Stafford. 1923. A clinical method for the estimation of protein in urine and other body fluids. *Arch. Internal Med.* **32**:222.
31. Van Slyke, D. D., and G. E. Cullen. 1914. A permanent preparation of urease and its use in the determination of urea. *J. Biol. Chem.* **19**:211.
32. Todd, E. W. 1932. Antigenic streptococcal hemolysin. *J. Exptl. Med.* **55**:267.
33. Hodge, B. E., and H. F. Swift. 1933. Varying hemolytic and constant combining capacity of streptolysins: influence on testing for antistreptolysins. *J. Exptl. Med.* **58**:277.
34. Paul, J. R. 1957. *The Epidemiology of Rheumatic Fever.* American Heart Association, New York. 3rd edition. 24.
35. Lendrum, A. C., D. S. Fraser, W. Slidders, and R. Henderson. 1962. Studies on the character and staining of fibrin. *J. Clin. Pathol.* **15**:401.
36. Lendrum, A. C., D. S. Fraser, and W. Slidders. 1964. Further observations on the age changes in extravascular fibrin. *Ned. Tijdschr. Geneesk.* **108**:2373.
37. Bell, E. T. 1938. A clinical and pathological study of subacute and chronic glomerulonephritis including lipoid nephrosis. *Am. J. Pathol.* **14**:691.
38. MacNider, Wm. de B. 1924. A review of acute experimental nephritis. *Physiol. Rev.* **4**:595.
39. Horn, H. 1937. The experimental nephropathies. *Arch. Pathol.* **23**:71.
40. Kobernick, S. D. 1952. Experimental rheumatic carditis, periarteritis nodosa, and glomerulonephritis. *Am. J. Med. Sci.* **224**:329.
41. Tan, E. 1964. Experimental renal disease induced by streptococci. *In* The Streptococcus, Rheumatic Fever, and Glomerulonephritis. J. W. Uhr, editor, Williams and Wilkins, Co., Baltimore. 238.
42. Lancefield, R. C., and E. W. Todd. 1928. Antigenic differences between matt hemolytic streptococci and their glossy variants. *J. Exptl. Med.* **48**:783.
43. Rammelkamp, C. H., Jr. 1964. Concepts of pathogenesis of glomerulonephritis derived from studies in man. *In* The Streptococcus, Rheumatic Fever, and Glomerulonephritis. J. W. Uhr, editor. Williams and Wilkins Co., Baltimore. 289.
44. Seegal, B. C., G. Andres, K. C. Hsu, and J. B. Zabriskie. 1965. Studies on the pathogenesis of acute and progressive glomerulonephritis in man by immunofluorescein and immunoferritin techniques. *Federation Proc.* **24**:100.

45. Feldman, J. D., M. R. Mardiney, and S. E. Shuler. 1966. Immunology and morphology of acute post-streptococcal glomerulonephritis. *Lab. Invest.* **15**:283.
46. Michael, A. F., Jr., K. N. Drummond, R. A. Good, and R. L. Vernier. 1966. Acute post-streptococcal glomerulonephritis: Immune deposit disease. *J. Clin. Invest.* **45**:237.
47. McCluskey, R. T., P. Vassalli, G. Gallo, and D. S. Baldwin. 1966. An immunofluorescent study of pathogenic mechanisms in glomerular disease. *New Engl. J. Med.* **274**:695.
48. Hume, W. E., and F. J. Natrass. 1927-28. The late effects of war nephritis. *Quart. J. Med.* **21**:1.
49. Murphy, F. D., and B. J. Peters. 1942. Treatment of acute nephritis. The immediate results and the outcome ten years later in eighty-nine cases. *J. Am. Med. Assoc.* **118**:183.
50. Murphy, F. D., and E. E. Schulz. 1956. Natural history of glomerular nephritis: A report of patients treated from 10 to 25 years after the acute stage. *Arch. Internal Med.* **98**:783.
51. Jennings, R. B., and D. P. Earle, Jr. 1961. Post-streptococcal glomerulonephritis: Histopathologic and clinical studies of the acute, subsiding acute and early chronic latent phases. *J. Clin. Invest.* **40**:1525.
52. McCluskey, R. T., and D. S. Baldwin. 1963. Natural history of acute glomerulonephritis. *Am. J. Med.* **34**:213.

EXPLANATION OF PLATES

PLATE 1

Capsular aspects and cut surfaces of the kidneys of a normal control rabbit (Figs. 1 *a* and 1 *c*) and a rabbit with experimentally induced acute glomerulonephritis (Figs. 1 *b* and 1 *d*). Kidneys are actual size.

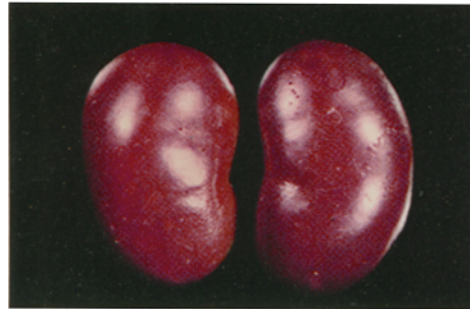FIG. 1 *a*. 1 yr old control male rabbit (not inoculated with Group A streptococci) that weighed 2900 g when sacrificed. The kidneys were of normal reddish-brown color and normal size. Together they weighed 13 g. Their capsular surfaces were smooth; no petechiae were observed. Cut surfaces are shown in Fig. 1 *c*.

FIG. 1 *b*. 1 yr old male rabbit 10-467 that weighed 2960 g when sacrificed 23 days after the beginning of the second series of intracutaneous inoculations with Group A streptococci and 3 days after marked proteinuria was observed. The BUN had risen from normal to 62 mg/100 ml by the 15th day after the beginning of the last series of inoculations and was 23 mg/100 ml at the time of sacrifice. The antistreptolysin titer was less than 10 units 3 wk before last series of inoculations and 1000 units at time of sacrifice. Autopsy blood cultures yielded no bacteria. As shown, the kidneys were pale tan and swollen and together weighed 17.5 g. Their capsular surfaces were very slightly granular and cortical petechiae were observed. Cut surfaces are shown in Fig. 1 *d*. Alterations observed microscopically in these kidneys are shown in Figs. 5, 12, 19, 23, and 24.

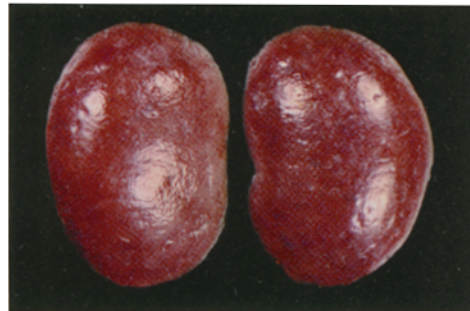
FIG. 1 *c*. Cut surfaces of the normal kidneys shown in Fig. 1 *a*. Normal reddish-brown cortices contrast with the pale tan cortices of the abnormal kidneys in Fig. 1 *d*.

FIG. 1 *d*. Cut surfaces of the abnormal kidneys shown in Fig. 1 *b*. The pale tan cortices of these swollen kidneys contrast with the reddish-brown cortices of the normal kidneys shown in Fig. 1 *c*.

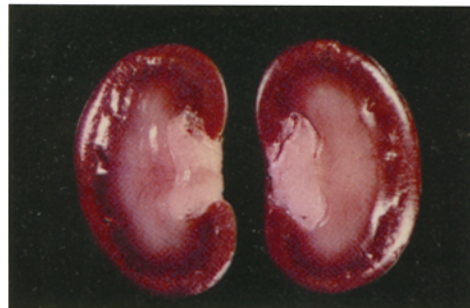




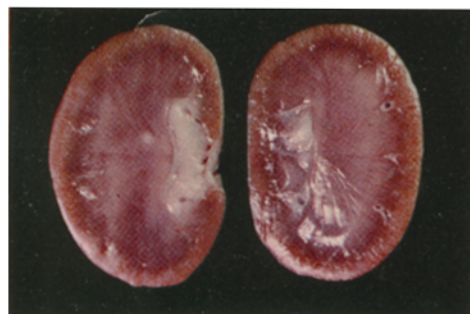
1a



1b



1c



1d

(Becker and Murphy: Induction of glomerulonephritis with Group A streptococci)

## PLATE 2

FIG. 2. Normal renal glomeruli of adult control rabbit (not infected with Group A streptococci) for comparison with glomeruli in Figs. 3-7. Hematoxylin and eosin.  $\times 200$ .

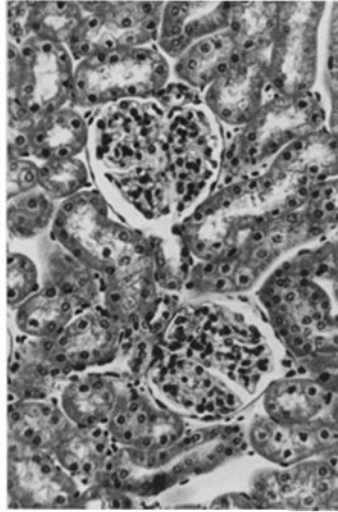
FIG. 3. Glomeruli of rabbit 97-06, sacrificed 32 days after first series of inoculations with Group A streptococci and 10 days after onset of hematuria. No bacteria were grown in autopsy blood cultures. The kidneys were 1.5 times normal weight. Hypercellularity of tufts with narrowing of capillary lumina. Figs. 10, 13, and 18 are also from this animal. Hematoxylin and eosin.  $\times 200$ .

FIG. 4. Glomeruli of rabbit 80-20, sacrificed 16 days after beginning of first infection with Group A streptococci. No bacteria were grown in autopsy blood cultures. The kidneys were not weighed. Swelling and hypercellularity of tufts with narrowing of capillary lumina. Focal vacuolization of tubular cells. Hematoxylin and eosin.  $\times 200$ .

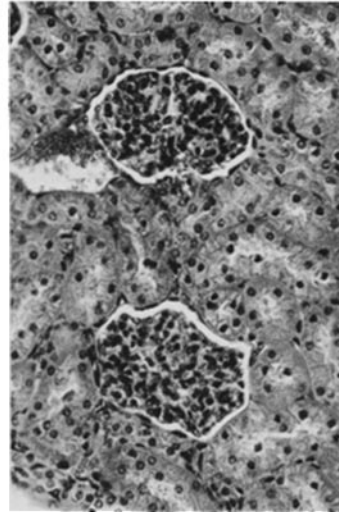
FIG. 5. Glomeruli of rabbit 10-467 referred to in Figs. 1 *b* and 1 *d*. Hypercellularity of tufts with narrowing of capillary lumina, as in Figs. 12, 19, 23, and 24 from the same animal. Hematoxylin and eosin.  $\times 200$ .

FIG. 6. Glomerulus of rabbit 70-55 that died 8 days after beginning of eighth infection with Group A streptococci. Antistreptolysin O titer 3 months before last infection was 200 units and above 1000 units a few hours before death. Group A, Type London streptococci were grown in autopsy blood cultures. The kidneys were pale and swollen but were not weighed. The cortical markings and corticomedullary junctions were indistinct. Marked swelling and increased cellularity of tuft with narrowing of some capillary lumina. Widening of mesangial regions due to edema and cellular proliferation. Proliferation also of endothelial cells. Polymorphonuclear leukocytes in lumina of several capillaries. Note resemblance to human glomeruli in Fig. 7. Fig. 15 is also from this animal. Hematoxylin and eosin.  $\times 200$ .

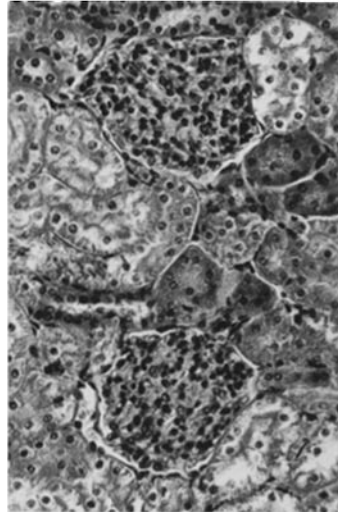
FIG. 7. Swollen glomeruli in biopsied kidney of patient 1, a 28 yr old man with acute glomerulonephritis. Biopsy 3 wks after onset of sore throat followed in a week by anasarca. Antistreptolysin O titer was 150 units 11 days before biopsy and 500 units 7 days after biopsy (The New York Hospital, biopsy S-63-3658). Widening of mesangial regions due to edema and cellular proliferation. Proliferation also of endothelial cells. Narrowing of some capillary lumina. Note resemblance to rabbit glomeruli in Fig. 6. Hematoxylin and eosin.  $\times 200$ .



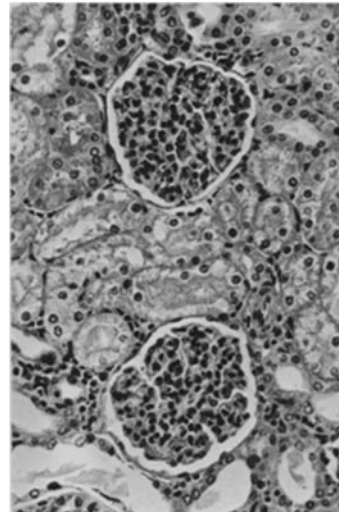
2



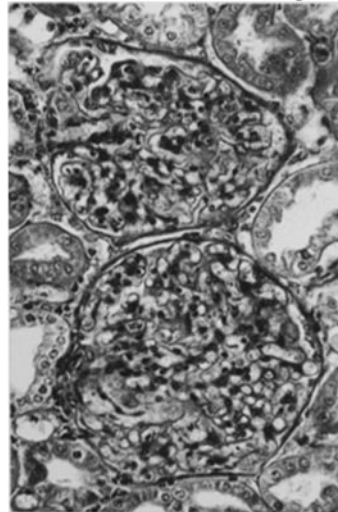
3



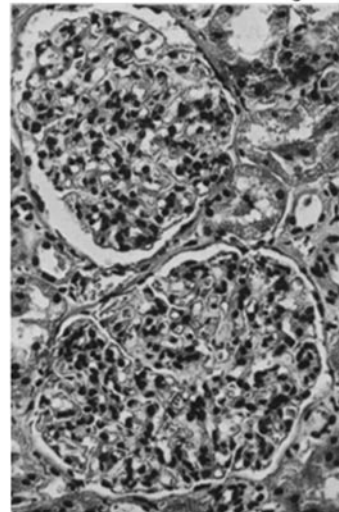
4



5



6



7

(Becker and Murphy: Induction of glomerulonephritis with Group A streptococci)

PLATE 3

FIG. 8. Normal glomerulus of adult control rabbit (not infected with Group A streptococci), for comparison with rabbit glomeruli in Figs. 9–15. Hematoxylin and eosin.  $\times 320$ .

FIG. 9. Glomerulus of rabbit 10-831 sacrificed 12 days after first series of inoculations with Group A streptococci and 4 days after marked proteinuria and gross hematuria were observed. Antistreptolysin O titer was less than 10 units at time of sacrifice. No bacteria were grown in autopsy blood cultures. The kidneys were 1.5 times normal weight. Hypercellularity of tuft with narrowing of capillary lumina. Hematoxylin and eosin.  $\times 320$ .

FIG. 10. Glomerulus of rabbit 97-06, referred to in Figs. 3, 13, and 18. Hypercellularity and hyperlobulation of tuft with marked narrowing or occlusion of capillary lumina. Note resemblance to human glomerulus in Fig. 16. Hematoxylin and eosin.  $\times 320$ .

FIG. 11. Glomerulus of rabbit 80-19, sacrificed 16 days after beginning of first infection with Group A streptococci. No bacteria were grown in autopsy blood cultures. The kidneys were not weighed. Swelling and hypercellularity of tuft with narrowing of capillary lumina. Hematoxylin and eosin.  $\times 320$ .

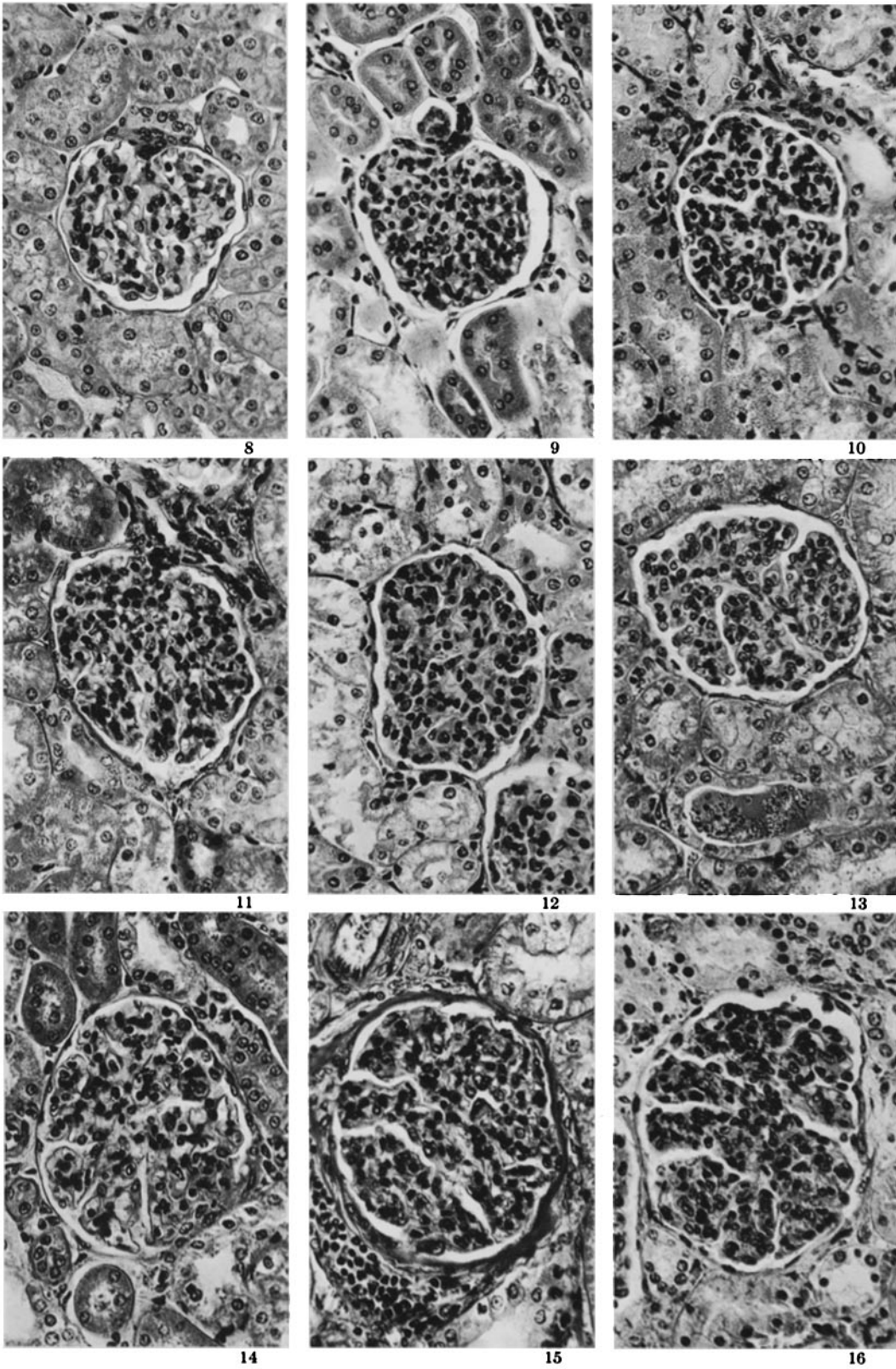
FIG. 12. Glomerulus of rabbit 10-467, referred to in Figs. 1 *b* and 1 *d*. Hypercellularity with marked narrowing or occlusion of capillary lumina, as in Figs. 5, 19, 23, and 24 from the same animal. Focal vacuolization of tubular cells. Hematoxylin and eosin.  $\times 320$ .

FIG. 13. Glomerulus of rabbit 97-06, referred to in Figs. 3, 10, and 18. Hypercellularity and hyperlobulation of tuft with marked narrowing of capillary lumina. Red blood cell cast in tubular lumen. Hematoxylin and eosin.  $\times 320$ .

FIG. 14. Glomerulus of rabbit 96-50, sacrificed 19 days after beginning of fourth series of inoculations with Group A streptococci and 10 days after proteinuria and microscopic hematuria were observed. Antistreptolysin O titer 9 months before last series of inoculations was 300 units, 100 units 1 month before last series, and 300 units at time of sacrifice. No bacteria were grown in autopsy blood cultures. The kidneys were 1.5 to 2 times normal weight and petechiae were observed in the slightly granular cortices. Swelling and hypercellularity of tuft with narrowing of lumina of many capillaries. Adhesion of right lower portion of tuft to Bowman's capsule. Other changes in the kidneys of this animal are shown in Figs. 21, 22, 25, and 29–33. Hematoxylin and eosin.  $\times 320$ .

FIG. 15. Glomerulus of rabbit 70-55, referred to in Fig. 6. Swelling, hypercellularity, and hyperlobulation of tuft with marked narrowing or obliteration of capillary lumina. Note striking resemblance to human glomerulus in Fig. 16. Hematoxylin and eosin.  $\times 320$ .

FIG. 16. Glomerulus of patient 2, a 4 yr old girl who died with proteinuria, hematuria, anasarca, hypertension, and cardiac failure about 1 wk after symptoms of an upper respiratory infection were recognized.  $\beta$ -hemolytic streptococci were cultured from the nose, throat, and a postauricular fluctuant mass (The New York Hospital, autopsy 13,091). No  $\beta$ -hemolytic streptococci were grown in autopsy blood cultures. Kidneys were pale and swollen (1.5 times normal weight) and petechiae were observed beneath the capsule. Swelling, hypercellularity, and hyperlobulation of tuft with marked narrowing or obliteration of capillary lumina. Note striking resemblance to rabbit glomerulus in Fig. 15. Fig. 20 is also from this child. Hematoxylin and eosin.  $\times 320$ .



(Becker and Murphy: Induction of glomerulonephritis with Group A streptococci)

PLATE 4

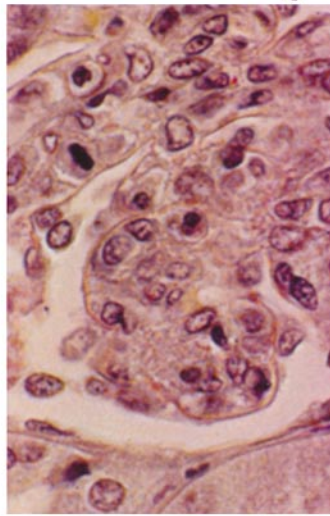
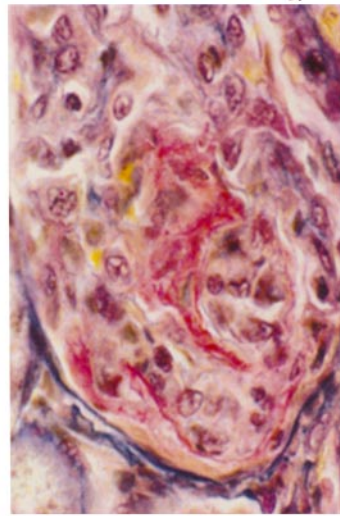
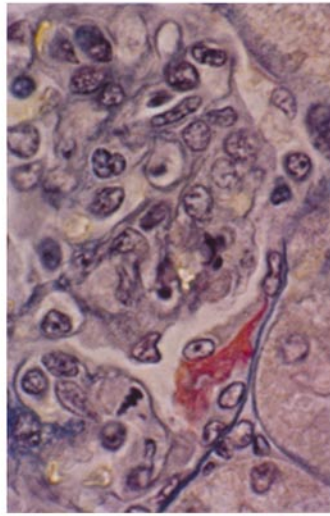
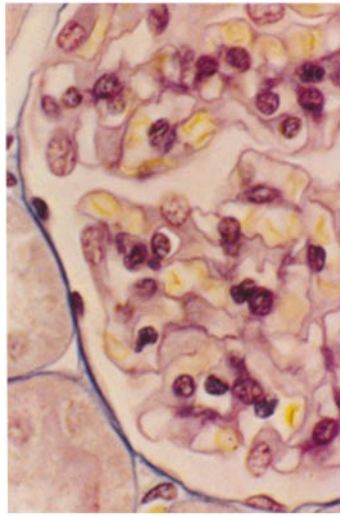
FIG. 17. Normal glomerulus of adult rabbit (not infected with Group A streptococci), for comparison with rabbit glomeruli in Figs. 18 and 19. PAS-MSDB 109.  $\times 800$ .

FIG. 18. Glomerulus of rabbit 97-06, referred to in Figs. 3, 10, and 13. Hypercellularity of tuft with marked narrowing or obliteration of capillary lumina. Mitotic figure in endothelial cell in left lower portion of figure. Basement membranes of capillaries appear delicate. Capsular epithelial cell has moved over a deposit of fibrin (red-staining material) on other epithelial cells of the capsule. PAS-MSDB 109.  $\times 800$ .

FIG. 19. Glomerulus of rabbit 10-467, referred to in Figs. 1 *b*, 1 *d*, 5, 12, 23, and 24. Hypercellularity of tuft with obliteration of capillary lumina and exudation of fibrin. PAS-MSDB 109.  $\times 800$ .

FIG. 20. Glomerulus of the 4 yr old girl referred to in Fig. 16. Hypercellularity of tuft with obliteration of capillary lumina. Mitotic figure in endothelial cell in left upper portion of figure. PAS-MSDB 109.  $\times 800$ .





(Becker and Murphy: Induction of glomerulonephritis with Group A streptococci)

PLATE 5

FIG. 21. Glomerulus of rabbit 96-50, referred to in Figs. 14, 22, 25, and 29-33. Hypercellularity and focal necrosis of tuft with hemorrhage into Bowman's capsular space. Proliferation of capsular epithelial cells. Hematoxylin and eosin.  $\times 320$ .

FIG. 22. Red blood cells and "hyaline" casts in lumina of renal tubules of rabbit 96-50, referred to in Figs. 14, 21, 25, and 29-33. Vacuolization of many tubular epithelial cells. Masson trichrome.  $\times 164$ .

FIG. 23. Glomerulus of rabbit 10-467, referred to in Figs. 1 *b*, 1 *d*, 5, 12, 19, and 24. Marked hypercellularity of tuft with obliteration of capillary lumina and hemorrhage into Bowman's capsular space. MSDB 109.  $\times 512$ .

FIG. 24. Glomerulus and associated proximal tubule of rabbit 10-467, referred to in Figs. 1 *b*, 1 *d*, 5, 12, 19, and 23. Swelling and hypercellularity of tuft with marked narrowing or obliteration of capillary lumina. Fibrin and red blood cells in Bowman's capsular space. Red blood cells in tubular lumen. Hematoxylin and eosin.  $\times 320$ .

FIG. 25. Glomerulus and tubules of rabbit 96-50, referred to in Figs. 14, 21, 22, and 29-33. Swelling of tuft and lobular necrosis with red blood cells and fibrin (red-staining material) in Bowman's capsular space. Material that stains like fibrin in tubular lumina. Yellosolve I.  $\times 320$ .

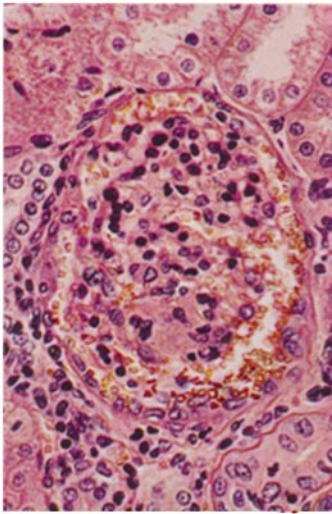
FIG. 26. Glomerulus of patient 3, a 14 yr old boy who, 2 months prior to death, suffered a hand laceration. Infection of wound developed and was not treated with an antimicrobial agent. About 1 month before death, swelling of the face, nausea, and vomiting occurred. 2 wk later, antistreptolysin O titer was 800 units. Rapidly progressive renal failure ensued with increasing proteinuria, hematuria, hypertension, and azotemia (The New York Hospital, autopsy 17,684). The kidneys were pale and about 2.5 times normal weight. Many cortical petechiae were evident. Lobular necrosis, exudation, and proliferation of epithelial cells. Masson trichrome.  $\times 256$ .

FIG. 27. Glomerulus of rabbit 96-52, sacrificed 19 days after beginning of fifth series of inoculations with Group A streptococci. Antistreptolysin O titer was 200 units 9 months before last series of inoculations, 10 units 8 months later, and 50 units at time of sacrifice. No bacteria were grown in autopsy blood cultures. The kidneys were 1.5 to 2 times normal weight and petechiae were observed in the slightly granular cortices. Lobular necrosis and exudation. Note resemblance to human glomerulus in Fig. 28. Masson trichrome.  $\times 320$ .

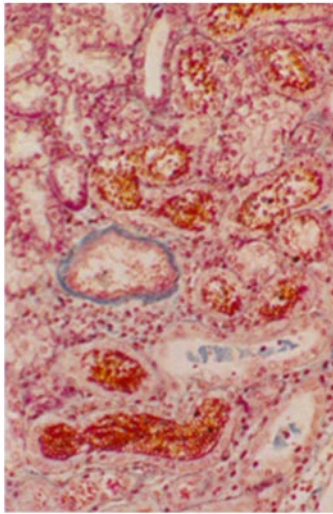
FIG. 28. Glomerulus of patient referred to in Fig. 26. Lobular necrosis and exudation. Masson trichrome.  $\times 256$ .

FIG. 29. Glomerulus of rabbit 96-50, referred to in Figs. 14, 21, 22, 25, and 30-33. Lobular necrosis and exudation and crescentic proliferation of epithelial cells. Note similarity of these changes to those in Fig. 26. Masson trichrome.  $\times 320$ .

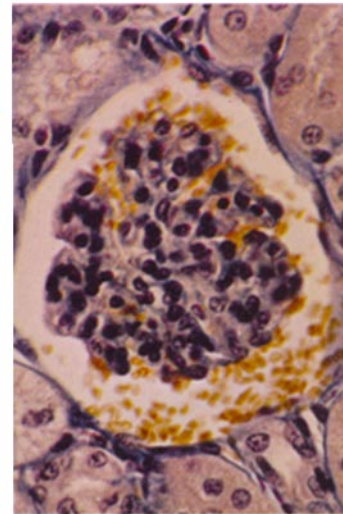




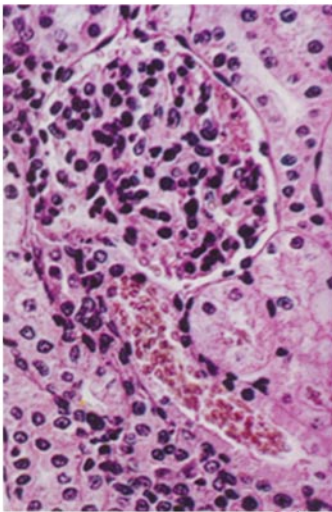
21



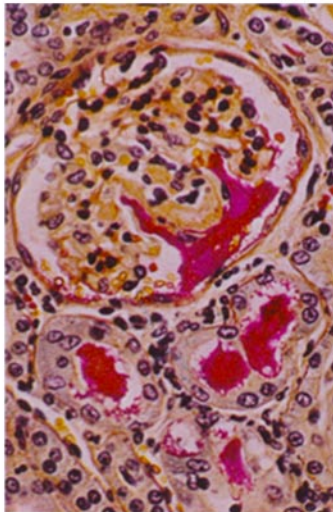
22



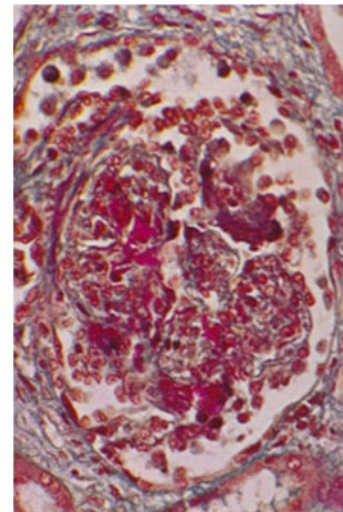
23



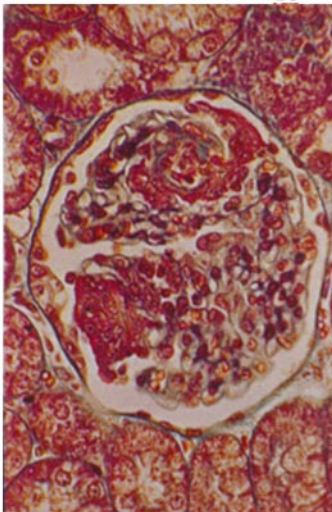
24



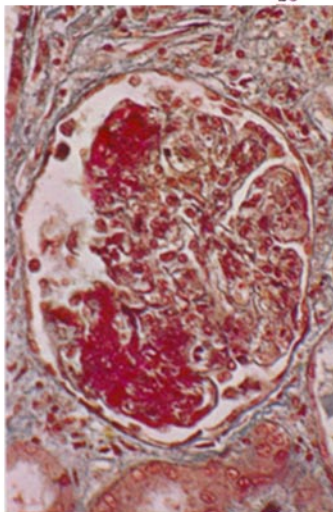
25



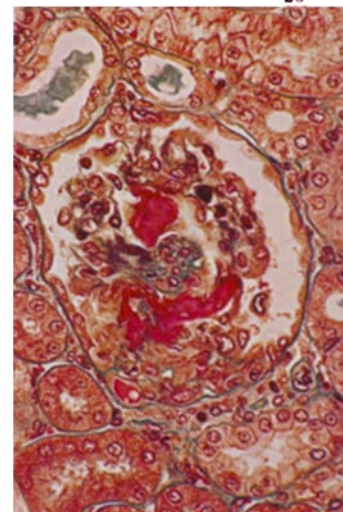
26



27



28



29

(Becker and Murphy: Induction of glomerulonephritis with Group A streptococci)

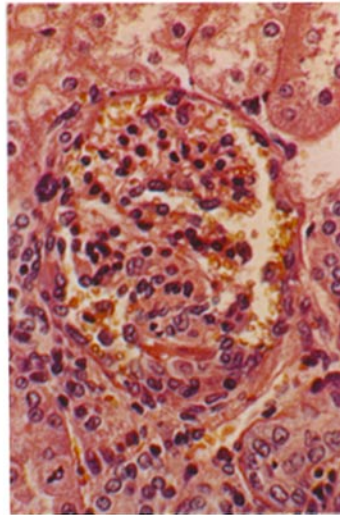
#### PLATE 6

FIGS. 30-33. Figs. 30 through 33, together with Fig. 29, illustrate the development of crescentic proliferation of epithelial cells of Bowman's capsule in reaction to glomerular tuft alterations in the kidneys of the rabbit referred to in Figs. 14, 21, 22, 25, and 29. Fig. 30 shows lobular degeneration and hemorrhage, a small focus of exudation, and reacting proliferated capsular epithelial cells. Figs. 31-33 show synchiae between hypercellular and hyperlobulated tufts and crescents of proliferated capsular epithelial cells. Note the close resemblance of the changes in the rabbit kidney shown in the three latter figures to those in the human kidney shown in Figs. 34 and 35. Hematoxylin and eosin. Magnifications of rabbit figures are  $\times 320$ .

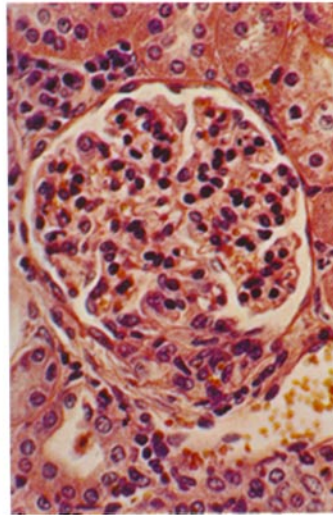
FIG. 34. Glomerulus in biopsied kidney of patient 4, a 16 yr old male. Hematuria at ages 9 and 13. Open biopsy about 5 months after a sore throat, that was soon followed by hematuria and periorbital edema, and 1 month after recurrence of hematuria that developed a few days after onset of another sore throat. Antistreptolysin 0 titer was 250 units 1 wk before biopsy and 250 units 10 days after biopsy (The New York Hospital, biopsy S-62-10,283). Hypercellular and hyperlobulated tuft adherent to a crescentic mass of proliferated capsular epithelial cells. Note the close resemblance of these changes to those in the rabbit kidney shown in Figs. 32 and 33. Hematoxylin and eosin.  $\times 256$ .

FIG. 35. Glomerulus in human kidney referred to in Fig. 34. Hypercellular and hyperlobulated tuft adherent to a crescentic mass of proliferated capsular epithelial cells. Note the close resemblance of these changes to those in the rabbit kidney shown in Fig. 33. Hematoxylin and eosin.  $\times 256$ .

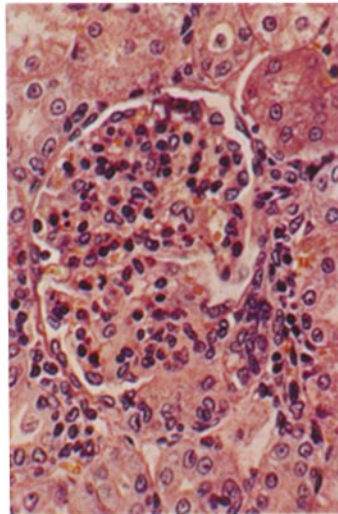




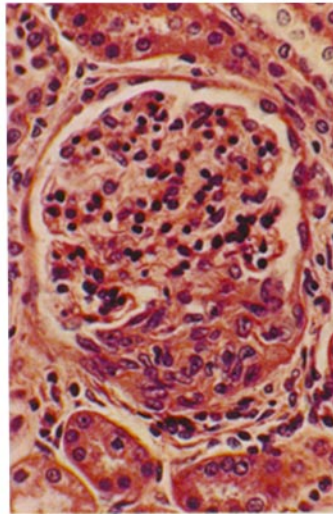
30



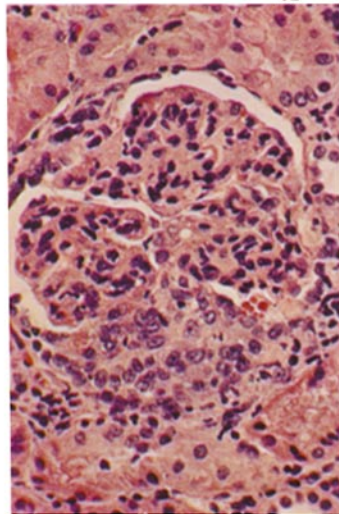
31



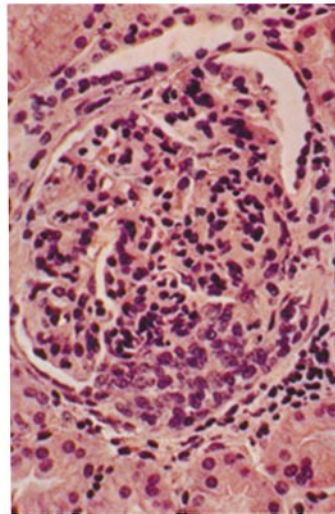
32



33



34



35

(Becker and Murphy: Induction of glomerulonephritis with Group A streptococci)

PLATE 7

FIG. 36. Normal glomeruli of adult control rabbit (not infected with Group A streptococci) for comparison with rabbit glomeruli in Fig. 37. Hematoxylin and eosin.  $\times 128$ .

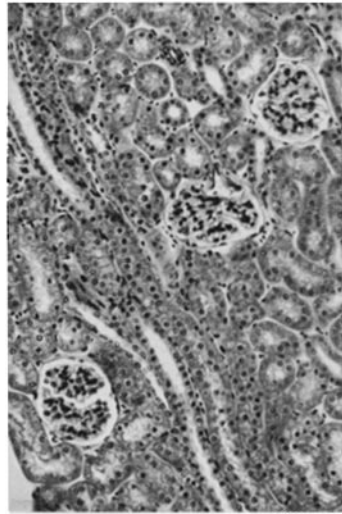
FIG. 37. Glomeruli of rabbit 96-26, that convulsed and died a few hours after giving birth to four young, 4 months after beginning of second series of inoculations with Group A streptococci. Antistreptolysin O titer was 50 units 1 wk antemortem. No bacteria were grown in autopsy blood cultures. The kidneys were 1.5 to 2 times normal weight and several petechiae were observed in the slightly granular cortices. Tufts are swollen and hypercellular and the lumina of many capillaries are narrowed or obliterated. Figs. 38-40 are also from the kidneys of this animal. Hematoxylin and eosin.  $\times 128$ .

FIG. 38. Glomeruli of the same animal. Hyperlobulation and lobular scars in tufts. In left upper portion of the figure adhesion between a scarred tuft and Bowman's capsule can be seen. Masson trichrome.  $\times 128$ .

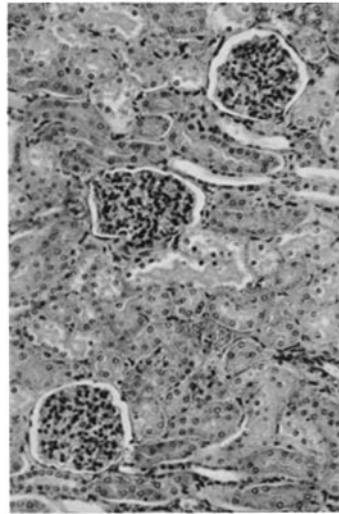
FIG. 39. Glomeruli of the same animal. The upper glomerulus is partially hyalinized. The lower glomerulus is swollen and hypercellular and the lumina of many of its capillaries are narrowed. Hematoxylin and eosin.  $\times 200$ .

FIG. 40. Glomerulus of the same animal. Scarred lobule apparently just adherent to Bowman's capsule. Note resemblance to human glomerulus in Fig. 41. Hematoxylin and eosin.  $\times 320$ .

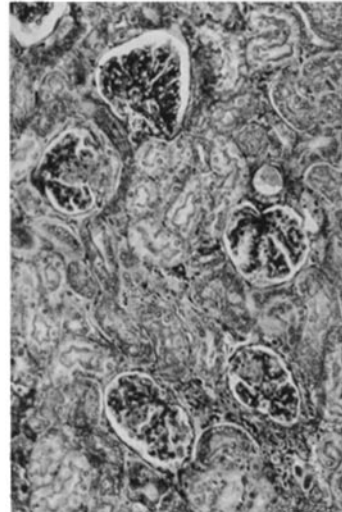
FIG. 41. Glomerulus in biopsied kidney of patient 5, a 6 yr old girl with resolving acute glomerulonephritis. Biopsy approximately  $3\frac{1}{2}$  wk after onset of the disease. In the 2 wk prior to biopsy, proteinuria and hematuria decreased considerably and BUN fell from 80 mg/100 ml to normal. Antistreptolysin O titer was 700 units 2 wk before biopsy and 400 units 10 days after biopsy (The New York Hospital, biopsy S-62-10,108). Focally hypercellular tuft with a scarred lobule adherent to Bowman's capsule. Note resemblance to rabbit glomerulus in Fig. 40. Azan.  $\times 320$ .



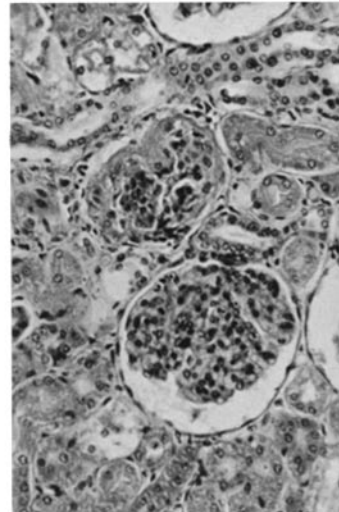
36



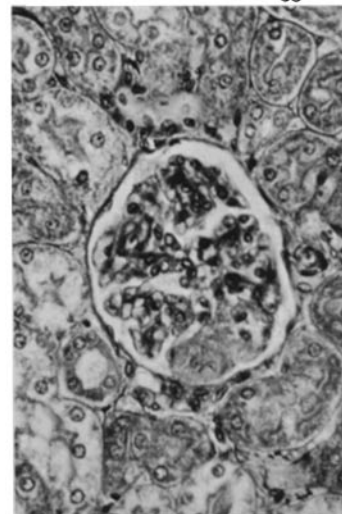
37



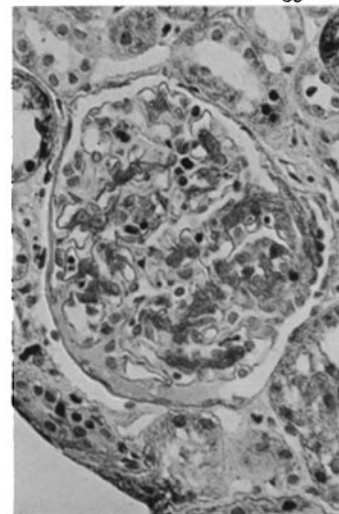
38



39



40



41

(Becker and Murphy: Induction of glomerulonephritis with Group A streptococci)

PLATE 8

FIG. 42. Kidney of rabbit 99-41 that died with intercurrent pneumonia due to Gram-negative bacilli 6 months after fourth series of inoculations with Group A streptococci. After third series 1 yr antemortem, BUN became elevated and remained so for at least 3 months. Antistreptolysin 0 titer less than 10 units 1 day antemortem. No bacteria grown in autopsy blood cultures. The renal cortices were finely granular. The weight of the kidneys was normal. Majority of glomeruli are scarred or hyalinized. Focal loss of tubules and interstitial scarring. Note resemblance to human kidney in Fig. 43. Figs. 45 and 48 are also from this animal. Masson trichrome.  $\times 64$ .

FIG. 43. Kidney of patient 6, a 59 yr old woman who died of chronic glomerulonephritis with azotemia (BUN 226 mg/100 ml 1 day antemortem).  $7\frac{1}{2}$  yr before death, a severe sore throat was followed in 3 months by the nephrotic syndrome. 6 months later, proliferative glomerulonephritis with mesangial scarring, but without crescents, and several hyalinized glomeruli were found in biopsied kidney. Progressive deterioration of renal function followed (The New York Hospital, autopsy 22,412). The kidneys were one-half normal weight. Diffusely scarred or hyalinized glomeruli with loss or dilatation of tubules, tubular casts, and scarring of interstitium. Note resemblance to rabbit kidneys in Figs. 42 and 44. Fig. 46 is from same patient. Masson trichrome.  $\times 50$ .

FIG. 44. Kidney of rabbit 96-38, azotemic and moribund when sacrificed 6 months after fourth series of inoculations with Group A streptococci. 12-15 days after first inoculation of this series, proteinuria developed and persisted until death (BUN 206 mg/100 ml 1 day antemortem). During last 3 months of life, antistreptolysin 0 titer was 300 units. No bacteria grown in autopsy blood cultures. The kidneys were markedly scarred. Majority of glomeruli are diffusely scarred. Many tubules have disappeared, others are dilated, and tubular casts are evident. Extensive scarring of interstitium. Note resemblance to human kidney in Fig. 43. Figs. 47 and 50 are also from this animal. Masson trichrome.  $\times 50$ .

FIG. 45. Rabbit kidney referred to in Figs. 42 and 48. Diffuse scarring of glomeruli with a hypertrophied, hypercellular glomerulus. Atrophy of tubules and scarring of interstitium. Note resemblance to human kidney in Fig. 46. Masson trichrome.  $\times 102$ .

FIG. 46. Human kidney referred to in Fig. 43. Diffuse scarring of glomeruli with two hypertrophied, hypercellular glomeruli with focal scarring of mesangium. Atrophy of some tubules, ectasia of others, and scarring of interstitium. Note resemblance to rabbit kidneys in Figs. 45 and 47. Masson trichrome.  $\times 80$ .

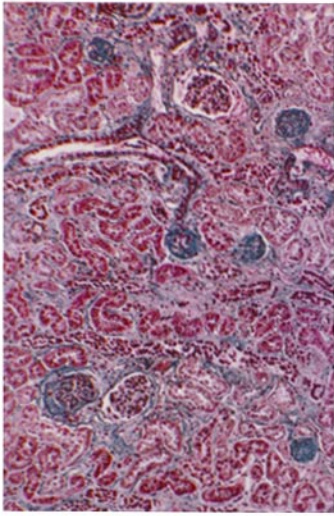
FIG. 47. Rabbit kidney referred to in Figs. 44 and 50. Diffusely or focally scarred glomeruli. Atrophy of some tubules, ectasia of others, and scarring of interstitium. Note resemblance to human kidney in Fig. 46. Masson trichrome.  $\times 102$ .

FIG. 48. Rabbit kidney referred to in Figs. 42 and 45. Hypercellularity of lower glomerulus with capsular scarring. Upper glomerulus exhibits fine scarring of mesangium and capillary necrosis in right lower portion with protein in capsular space. Masson trichrome.  $\times 200$ .

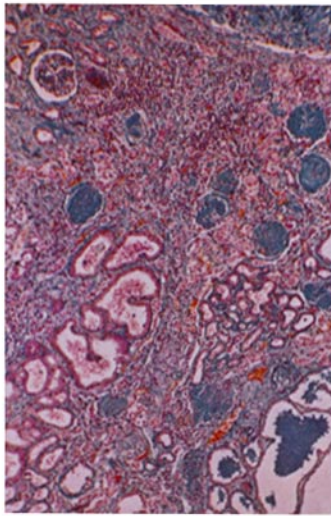
FIG. 49. Biopsied kidney of patient 7, a 5 yr old boy with chronic active glomerulonephritis. Biopsy 9 wk after earache followed in several days by facial edema, proteinuria, and oliguria. Antistreptolysin 0 titer 1200 units 8 wk before biopsy, 500 units 5 days before biopsy, and 50 units 6 wk after biopsy (The New York Hospital, biopsy S-63-4654). Diffusely or focally scarred glomerular tufts with adhesions to capsules. Atrophy of some tubules, ectasia of others, and scarring of interstitium. Note resemblance to rabbit kidneys in Figs. 47 and 50. Hematoxylin and eosin.  $\times 80$ .

FIG. 50. Rabbit kidney referred to in Figs. 44 and 47. Diffusely or focally scarred glomerular tufts with hyalinized adhesions to capsules. Exudate in capsular space and several proliferated capsular epithelial cells in right lower portion of figure. Note resemblance to human kidney in Fig. 49. Masson trichrome.  $\times 128$ .

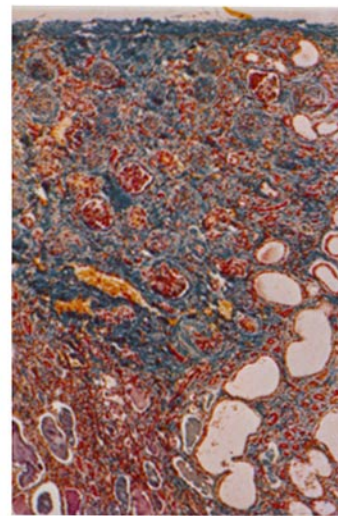




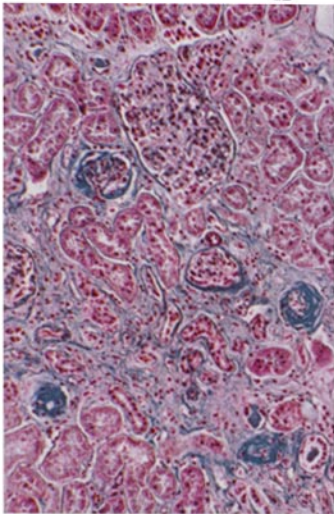
42



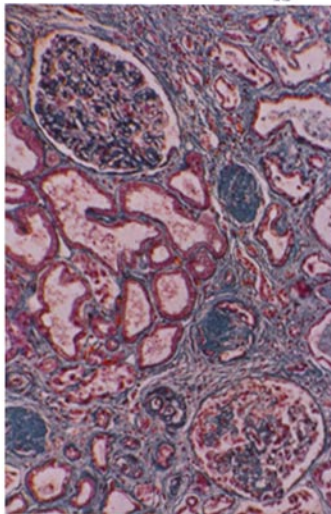
43



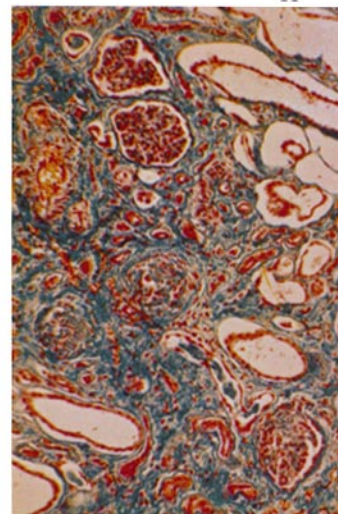
44



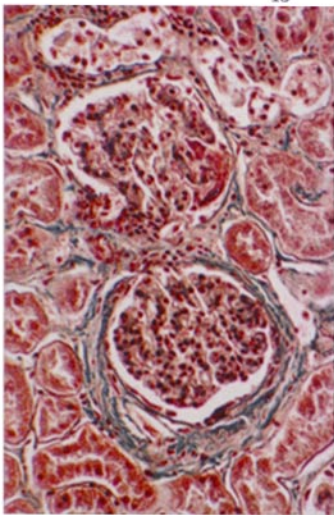
45



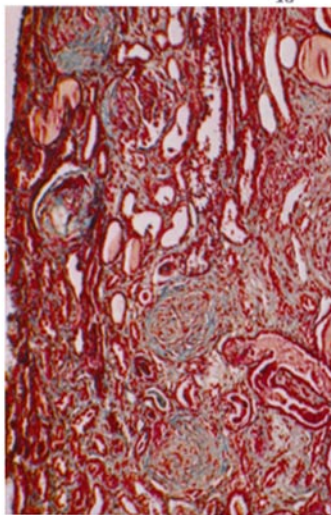
46



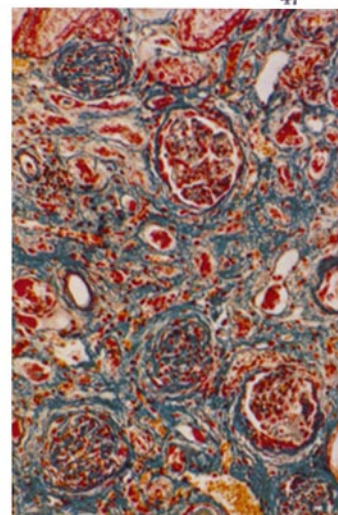
47



48



49



50

(Becker and Murphy: Induction of glomerulonephritis with Group A streptococci)