

AUTOLOGOUS IMMUNE COMPLEX NEPHRITIS INDUCED WITH  
RENAL TUBULAR ANTIGEN

II. THE PATHOGENETIC MECHANISM\*

BY RICHARD J. GLASSOCK,† § M.D., THOMAS S. EDGINGTON,‡ M.D.,  
J. IAN WATSON,|| M.D., AND FRANK J. DIXON, M.D.

*(From the Department of Experimental Pathology, Scripps Clinic and  
Research Foundation, La Jolla, California 92037)*

PLATES 74 and 75

(Received for publication 19 October 1967)

The induction of glomerular lesions in rats by immunization with homologous, heterologous, isologous, or autologous kidney extracts has been well documented since Heymann's original description in 1959 (1). Although it was initially thought that these lesions were mediated by a direct autoimmune reaction against fixed glomerular antigens, subsequent observations have suggested that they are evoked by glomerular localization of nonglomerular antigen-antibody complexes (2). That the latter is the case is now strongly supported by several observations. First, the light, immunofluorescent, and electron microscopic character of the glomerular lesions resemble those seen in experimental glomerulonephritis induced by known circulating nonglomerular antigen-antibody complexes (2-5). Second, as shown in the accompanying paper (6), a tubular rather than a glomerular antigen elicits the antibody responsible for the induction of this disease. Third, the immunizing antigen could be detected in the glomerular deposits of rats with glomerulonephritis induced by immunization with heterologous antigen (2, 7). Fourth, an autologous material identical to or cross-reactive with the nephritogenic antigen is localized in the glomerular deposit along with host  $\gamma$ -globulin and complement (6). Finally, minute quantities of exogenous antigen, apparently too small to account for the antigen deposited in the glomeruli, are capable of inducing typical autologous immune complex (AIC) nephritis.

\* This is publication 251 from the Department of Experimental Pathology, Scripps Clinic and Research Foundation. This investigation was supported by United States Public Health Service Grant AI-07007 and Contract AT (04-3)-410 from the Atomic Energy Commission.

† Supported by United States Public Health Service Training Grants—GM 683 (TE) and 1-TI-AI-301 (RG).

§ Present address: Department of Medicine, Harbor General Hospital, Torrance, Calif., and the University of California, Los Angeles. Work performed during a leave of absence from Department of Medicine, Peter Bent Brigham Hospital and Harvard Medical School, Boston, Mass.

|| Present address: Division of Immunochemistry and Allergy, Royal Victoria Hospital, Montreal, Canada.

These observations have led to the concept of an *autologous immune complex pathogenesis* for this disease. Although autoimmune in a broad sense, this glomerulonephritis is not caused by antibodies directed against glomerular antigens and therefore does not conform to the original definition of specific antitissue autoimmunity. This model, taken together with antiglomerular basement membrane antibody-induced autoimmune nephritis (8-10), illustrates the variety of pathogenetic mechanisms which may be involved in autoimmune diseases and emphasizes the necessity of considering separately the immunizing event, the specificity of the antibody response, and the pathogenetic events directly responsible for tissue injury in the study of suspected autoimmune diseases. A preliminary report concerning some of these studies has been published (7).

### Materials and Methods

#### *Induction of AIC Nephritis with Renal Tubular Antigen.—*

AIC nephritis was induced in male Lewis rats<sup>1</sup> by the technique described in the accompanying paper (6). Crude nephritogenic renal tubular epithelial (RTE) antigen, Fx1A, containing 76  $\mu$ g Nitrogen/mg dry weight, was prepared from Sprague-Dawley rat kidneys (6). Immunization usually consisted of a single foot-pad injection of Fx1A in complete Freund's adjuvant containing 2 or 4 mg *Mycobacterium tuberculosis* H37R<sub>a</sub><sup>2</sup> per milliliter. In a few experiments *M. tuberculosis* was omitted from the adjuvant preparation. In some experiments disease was induced by the repeated intraperitoneal administration of Fx1A in complete Freund's adjuvant (1, 5).

*Preparation of Kidney Antigens.—*Crude kidney fractions, as well as purified RTE antigens, were prepared and designated as previously described (6, 11). In addition, human kidney Fx1A was prepared from autopsy material.

#### *Preparation of Antisera.—*

Rabbit anti-rat RTE antigens, albumin, fibrinogen, and  $\gamma$ - and  $\beta_{1C}$ -globulins as well as sheep anti-rabbit  $\gamma$ -globulin were prepared as previously described (6, 11, 12). Rabbit anti-rat RTE contained antibodies to all three RTE-specific antigens, RTE- $\alpha_3$ , RTE- $\alpha_4$ , and RTE- $\alpha_5$  (6, 11). Anti-human RTE was prepared in rabbits using kidney fractions of human derivation (7, 11). Rabbit anti- $\alpha_5$  was prepared by absorption of anti-RTE with purified RTE- $\alpha_3$  and RTE- $\alpha_4$ . The specificity of the antiserum was confirmed by the capacity of the anti- $\alpha_5$  to react immunohistochemically with glomerular deposited RTE- $\alpha_5$  in kidney from rats with AIC nephritis and by the production in Ouchterlony plates of a single precipitin line with either purified RTE- $\alpha_5$  or Fx1A solubilized at 10 mg/ml in 1% sodium desoxycholate (Fx1A-DOC).

The  $\gamma_2$ -globulin fractions of all antisera were employed in this study and were precipitated with ammonium sulfate at 50% saturation followed by isolation from DEAE-cellulose as described by Levy and Sober (13).

#### *Immunofluorescent Studies.—*

All immunohistochemical reagents and procedures were performed as described in the preceding paper (6).

#### *In Vivo Tissue Fixation.—*

*Fixation of anti- $\alpha_5$  and anti-RTE:* Anti- $\alpha_5$  was subjected to Sephadex G-200 gel filtration

<sup>1</sup> Microbiological Associates, Inc., Walkersville, Md.

<sup>2</sup> Difco Laboratories, Detroit, Mich.

and the 7S peak was collected and labeled with  $^{131}\text{I}$  by the method of McConahey and Dixon (14). Control nonimmune rabbit  $\gamma_2$ -globulin, absorbed in parallel with RTE- $\alpha_3$  and RTE- $\alpha_4$ , was reisolated on Sephadex G-200 and labeled with  $^{125}\text{I}$  by the same method. Equal quantities of labeled immune (anti- $\alpha_6$ ) and nonimmune (control) 7S globulins were mixed and were reisolated as the "fall through" peak on DEAE-cellulose, 0.0175 M phosphate, pH 6.5 (13). The mixture of 1.5  $\mu\text{g}$  of each labeled protein was given intravenously to each of three normal male Lewis rats, and to three male Lewis rats with established AIC nephritis.

24 hr later, a cardiac blood sample was obtained, the rats were sacrificed, and the visceral organs were perfused with cold PBS via the thoracic aorta. The kidneys, liver, spleen, lung, stomach, small bowel, colon, and samples of skeletal and cardiac muscle, were assayed for  $^{131}\text{I}$  and  $^{125}\text{I}$  and specific organ fixation of anti- $\alpha_6$  calculated (9).

The relative distribution of fixed radioactivity in renal subfractions was evaluated by pooling all of the kidneys in each group of rats. They were minced and homogenized in cold PBS in a Dounce homogenizer, and the homogenates were spun for 3 min at 300 g at 4°C. The sediments were washed six times with cold PBS at 200 g for 5 min. Equal aliquots of the supernates were then spun at 78,400 g for 45 min and the resultant sediments and supernatants collected. The amount of  $^{131}\text{I}$  and  $^{125}\text{I}$  in each fraction was quantitated and expressed as a per cent of that present in the whole kidney.

Similar experiments were carried out with anti-RTE. In this situation, both control and immune  $\gamma_2$ -globulins were labeled with  $^{131}\text{I}$  and each preparation was injected separately into both normal rats and rats with AIC nephritis. Organ fixation in each group of rats was calculated as the difference between fixation of immune  $\gamma$ -globulin and nonimmune globulin 24 hr after injection (15).

As a further control, a potent rabbit anti-rat nephrotoxic  $\gamma_2$ -globulin was supplied by Dr. Emil R. Unanue and its fixation was studied in normal rats and also those with AIC nephritis by the same method.

#### *Immune Elimination of Passively Administered Rabbit Anti- $\alpha_5$ .—*

Anti- $\alpha_5$  was labeled with  $^{131}\text{I}$ , and normal control rabbit  $\gamma_2$ -globulin was labeled with  $^{125}\text{I}$ . Equal quantities of these proteins were mixed and the center of the 7S peak was reisolated on Sephadex G-200. To test for the presence of aggregation or denaturation of these labeled proteins, tracer quantities (approximately 30  $\mu\text{g}$ ) of the reisolated labeled proteins were given intravenously to normal rabbits. A different degree of alteration of these  $\gamma$ -globulins would result in different catabolic rates reflected by a changing ratio of the two radioisotopically labeled proteins in the serum TCA-precipitable fractions of serially obtained blood samples.

Normal male Lewis rats were then given varying amounts of from 0.8 to 100  $\mu\text{g}$  of anti- $\alpha_5$   $^{131}\text{I}$  paired with normal  $\gamma$ -globulin  $^{125}\text{I}$  per dose, and the serum TCA-precipitable radioactivity was followed periodically up to 24 hr. The corrected  $^{131}\text{I}/^{125}\text{I}$  ratio was determined as above: a falling ratio reflected preferentially increased catabolism or tissue fixation of the anti- $\alpha_5$   $\gamma_2$ -globulin. Some rats were sacrificed during passive immune elimination and in vivo fixation of antibody to kidney was determined as previously outlined. The immune elimination of passively administered antibody was also studied in otherwise normal male Lewis rats which had been bilaterally nephrectomized 24 hr prior to the intravenous injection of the radioactively labeled proteins.

#### *Studies of Immune Responses in AIC Nephritis.—*

*In vitro serologic techniques:* Following immunization with nephritogenic or nonnephritogenic renal antigens, rats were studied serially for the presence of circulating antibody to solubilized preparations of renal tubular antigens, Fx1A-DOC, to purified preparations of RTE- $\alpha_5$ , and nonnephritogenic tubular antigens, RTE- $\alpha_3$  and RTE- $\alpha_4$ , by Ouchterlony technique using 1% Agarose, 0.1 M Veronal, 0.01 M EDTA, pH 8.6, as the supporting medium. Sera were also

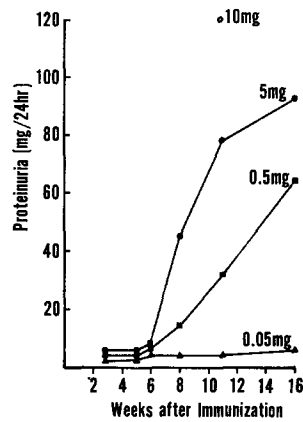
studied for antibody to RTE- $\alpha_5$  using their ability to inhibit the subsequent immunofluorescent staining by specific heterologous antibody of glomerular deposited RTE- $\alpha_5$  in kidney sections from rats with AIC nephritis. The blocking by normal and test rat sera was evaluated in twofold dilutions in PBS between 1:2 and 1:16 incubated on the eluted section for 45 min in a humid chamber. The sections were washed three times for 5 min each in PBS and stained first with standard rabbit anti-RTE ( $\gamma_2$ -globulin at 1 mg per ml), followed by fluoresceinated sheep anti-rabbit  $\gamma$ -globulin as previously described (6). The titer of the test serum was expressed as the highest dilution which would completely abolish staining of the glomerular deposited antigen. This test is referred to as the immunofluorescent inhibition test (IFIT).

*In vivo studies:* In order to evaluate the presence of antiglomerular antibody the in vivo fixation of  $\gamma_2$ -globulin derived from rats with AIC nephritis was studied. Pools of sera were obtained 4–6 wk after the last of a series of 10–13 intraperitoneal injections of either Sprague-Dawley Fx1A or Fx1B in complete Freund's adjuvant. Severe morphologic and functional nephrotic renal disease was present in the group immunized with Fx1A and uniformly absent in rats immunized with Fx1B.  $\gamma_2$ -Globulin was isolated from these three pools and from normal Lewis rat serum by precipitation of globulins with ammonium sulfate at 50% saturation and preparative electrophoresis on Pevikon block (16). The  $\gamma_2$ -globulin from each pool was labeled with  $^{131}\text{I}$  and 3–5  $\mu\text{c}$  were injected into groups of five normal Lewis rats. These rats were sacrificed at 24 hr after injection and in vivo organ fixation was determined on perfused kidney, liver, and lung. Tissue-fixed radioactivity in animals receiving the normal rat  $\gamma_2$ -globulin served as controls for nonspecific localization due to residual blood contamination (15). Fixation was expressed as a per cent of the administered dose fixed per gram wet weight of organ and was calculated as previously described. The intrarenal distribution of radioactivity was evaluated by pooling the kidneys from each group of five rats and fractionating into glomerular sediments and tubular supernates as described above. Results were expressed as the per cent of kidney-fixed radioactivity distributed between glomerular and the tubular fractions.

## RESULTS

*Induction and Natural History of AIC Nephritis.*—Following a single footpad injection of 0.5 mg or more of the crude nephritogenic tubular antigen (Fx1A) in adjuvant, containing 2 mg *M. tuberculosis* per ml of oil, abnormal proteinuria usually appeared by the 8th wk. The rate of increase and course of proteinuria appeared to be a dose-dependent phenomenon with progressively increased levels following injections of 5 and 10 mg of Fx1A (Text-fig. 1). As indicated in the preceding paper, RTE- $\alpha_5$  probably represents less than 5% of Fx1A which means that less than 25  $\mu\text{c}$  of RTE- $\alpha_5$  in a Fx1A preparation is nephritogenic. This is consistent with the preceding studies employing purified RTE- $\alpha_5$  for the induction of AIC nephritis (6). Doubling the amount of *M. tuberculosis* in the adjuvant was found to enhance the effectiveness of a given single dose of crude tubular antigen. In this situation proteinuria was first observed 5 wk following immunization (Table I). Granular deposits of rat  $\gamma$ -globulin (Fig. 1) along glomerular capillary walls usually preceded the onset of abnormal proteinuria by 1–2 wk while  $\beta_{1\text{C}}$  became detectable about the time proteinuria appeared. The glomerular deposits of RTE- $\alpha_5$  were usually detected somewhat later than the deposits of host  $\gamma$ -globulin or complement, perhaps reflecting the relative insensitivity of the detection methods for anti-

gen. Antigen and  $\beta_{1C}$  were not detected in glomeruli in the absence of host  $\gamma$ -globulin localization. With time, deposits of host  $\gamma$ -globulin tended to increase and become confluent, suggesting a heavy linear involvement. However, on close inspection of these sections, discrete granularities were apparent



TEXT-FIG. 1. Induction of AIC nephritis. The onset and severity of proteinuria is shown following single immunization in the rear foot-pads with 0.25 ml of Fx1A (0.05 mg, ▲; 0.5 mg, ■; 5 mg, ●; or 10 mg, ○) in adjuvant containing 2 mg *M. tuberculosis* per ml of oil. Proteinuria in excess of 10 mg per 24 hr was accepted as indicative of glomerular injury.

TABLE I  
*Development of AIC Nephritis Induced with Renal Tubular Antigen*

Weeks following immunization*	Proteinuria mg/24 hr	Glomerular deposits				Membranous glomerular lesions‡
		$\gamma$ -globulin	$\beta_{1C}$ -globulin	Fibrinogen	N.Ag‡	
1	0.5	0	0	0	0	0
2	0.5	0	0	0	0	0
3	0.6	0-±	0	0	0	0
4	1.7	±1+	0-±	0	0	0
5	16.5	2+	1+	0	0-±	±
6	66	3+	2+	0	±	1+
7	132	4+	3+	0	1+	1+
8	140	4+	3+	0	1-2+	1+
9	148	4+	3+	0	2+	2+
Normal Rat	0.5	0	0	0	0	0

\* 5 mg Sprague-Dawley Fx1A dry weight in adjuvant containing 4 mg *M. tuberculosis* per milliliter oil given once in the rear footpads.

‡ N.Ag, deposits of nephritogenic antigen detected on KSCN eluted sections, see text.

§ The histopathologic lesions during this period of observation consist predominantly of PAS-positive fine granular deposits along the subepithelial aspect of the glomerular basement membrane (6).

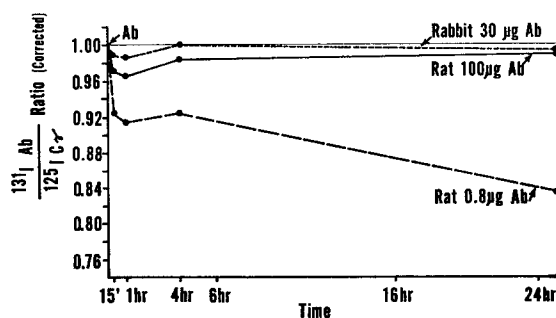
in all instances. Antigen was always present in a lighter but similar granular pattern to that of  $\gamma$ -globulin and  $\beta_{1G}$ -globulin (6). Deposits of fibrin were rarely seen and only in very late disease when they occasionally were observed in Bowman's space. Control stains for host albumin were uniformly negative. A single immunization with adjuvant alone or with Fx1A in incomplete adjuvant did not produce morphologic or immunohistochemical evidence of disease nor proteinuria.

*Participation of Autologous Antigen.*—These studies utilized renal tissue from rats in which AIC nephritis had been induced by relatively large amounts of human or rat Fx1A given in multiple intraperitoneal immunizations (1, 5). By immunofluorescent techniques anti-rat RTE-stained deposits along the glomerular capillary walls of rats with AIC nephritis induced with either human or rat Fx1A. Absorption of this antibody with rat Fx1A abolished the immunofluorescent reaction in AIC nephritis induced with either human or rat Fx1A. But absorption of the same anti-rat RTE with human Fx1A failed to diminish the immunofluorescence reaction in AIC nephritis induced with either antigen (Fig. 2), establishing the presence of autologous RTE in the glomeruli after injection of human antigen.

*Participation of Exogenous Antigen.*—With these large repeated doses of injected human antigen the deposition of both human and autologous RTE antigen in the glomeruli could be detected using anti-human and anti-rat RTE. Following absorption of anti-human RTE with rat Fx1A, the immunofluorescent reaction was greatly diminished but irregular fine granular deposits of human RTE antigen could still be found (Fig. 3). Such residual staining was abolished by absorption of antiserum with human Fx1A. When the same procedures were carried out with kidneys from rats in which AIC nephritis had been induced with rat Fx1A, nephritogenic antigen was demonstrated in the glomeruli with whole anti-human RTE or with anti-rat RTE absorbed with human Fx1A, but not with anti-human RTE absorbed with rat Fx1A.

*Presence of Autologous Nephritogenic Antigen in the Circulation.*—In order to provide a continuing source of antigen in the absence of a large deposit of exogenously administered antigen, autologous antigen must be available to react with circulating antibody during the development of disease. Attempts to detect circulating RTE- $\alpha_5$  in normal animals using micro-Ouchterlony techniques and specific antisera were not successful. Similarly it was not possible to detect circulating RTE- $\alpha_5$  by the immunofluorescent antibody inhibition test described previously (6). However, in normal Lewis rats it was found that passively administered hyperimmune rabbit anti- $\alpha_5$  had an accelerated removal from the circulation when compared to nonimmune rabbit  $\gamma$ -globulin (Text-fig. 2). This accelerated elimination of passively administered antibody was strongly dependent upon the amount of anti- $\alpha_5$  administered. Small amounts, approximately 0.8  $\mu$ g, were removed in an accelerated fashion,

whereas, larger amounts, 10 or 100  $\mu\text{g}$ , of immune  $\gamma$ -globulin were eliminated at a rate indistinguishable from that of nonimmune rabbit  $\gamma$ -globulin. No difference in elimination of the immune and control  $\gamma$ -globulin occurred in rabbits (Text-fig. 2). The curves of elimination suggested that at the time of injection combination of passively administered anti- $\alpha_5$  with antigen available in the circulation occurred. Subsequent disappearance of the anti- $\alpha_5$  occurred at a reasonably constant rate consistent with either or both the slow entry of antigen into the circulation and slow removal of antigen-antibody

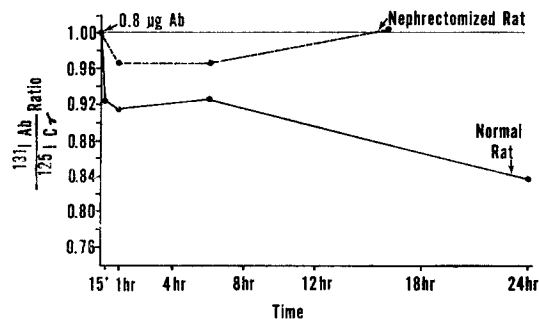


TEXT-FIG. 2. Demonstration of circulating RTE- $\alpha_5$  by immune elimination of rabbit antibody specific for rat RTE- $\alpha_5$  from the circulation of normal rabbits and rats. Normal rabbits were given a mixture of rabbit anti- $\alpha_5$   $^{131}\text{I}$  (30  $\mu\text{g}$ ) and normal rabbit  $\gamma_2$ -globulin  $^{125}\text{I}$  (30  $\mu\text{g}$ ) intravenously and the TCA-precipitable  $^{131}\text{I}/^{125}\text{I}$  ratio was determined at the indicated levels (----). The same procedure was carried out with groups of rats which received either 100  $\mu\text{g}$  (—) of anti- $\alpha_5$   $^{131}\text{I}$  or 0.8  $\mu\text{g}$  (---) of the same antibody paired with control  $\gamma$ -globulin  $^{125}\text{I}$ . Significant elimination of 100  $\mu\text{g}$  of antibody was not observed within 24 hr, but at the 0.8  $\mu\text{g}$  dose approximately 7.5 and 16% of the anti- $\alpha_5$  was eliminated in 15 min and 24 hr respectively. In vivo kidney fixation at a comparable time was only 0.07% of the injected antibody indicating that the loss of anti- $\alpha_5$  from the circulation was not the result of its reaction with RTE- $\alpha_5$  in the kidney.

complexes. Up to 16% of the 0.8  $\mu\text{g}$  of hyperimmune anti- $\alpha_5$  globulin was eliminated over 24 hr, which equals approximately 128 ng of antibody protein eliminated from the circulation. The initial immediate removal of specific antibody from the circulation was not associated with significant in vivo kidney fixation and therefore did not appear to represent fixation of specific antibody by RTE- $\alpha_5$  in the renal tubular epithelium. 10 min following intravenous injection of 0.8 or 100  $\mu\text{g}$  of rabbit anti- $\alpha_5$  0.07 and 0.08% respectively of the injected immune globulin were fixed to the recipient rats kidney. The amount of renal fixation is insufficient to account for the immediate elimination of approximately 7.5% of the immune globulin at the 0.8  $\mu\text{g}$  dose level. Most of the radioactivity lost from the circulation early was recovered from the spleen and liver as would be expected if circulating antigen-antibody complexes were

being formed and removed by the reticuloendothelial system. Lewis rats bilaterally nephrectomized 24 hr prior to the injection of 0.8  $\mu\text{g}$  anti- $\alpha_5$  did not eliminate the antibody at an accelerated rate during the subsequent 24 hr (Text-fig. 3), which is evidence against aggregation or denaturation of this dilute protein.

*In Vivo Organ Fixation of  $\gamma$ -Globulin from Nephritic Rats.*—No evidence of in vivo fixing antiglomerular antibody in the sera of AIC-nephritic rats could be found. Approximately 0.06% of a tracer dose of  $\gamma_2$ -globulin from male Lewis rats immunized with nonnephritogenic supernate of a tubular rich fraction of Sprague-Dawley kidneys, Fx1B, fixed per gram of kidney, liver,



TEXT-FIG. 3. Effect of bilateral nephrectomy on elimination of rabbit anti- $\alpha_5$  from the serum of normal rats. A group of Lewis rats, nephrectomized 24 hr prior to intravenous administration of 0.8  $\mu\text{g}$  anti- $\alpha_5$   $^{131}\text{I}$  paired with control  $\gamma_2$ -globulin  $^{125}\text{I}$  (-----), showed no elimination of specific antibody at 16 hr. By contrast a group of intact rats eliminated anti- $\alpha_5$  (——). In view of the absence of renal fixation in vivo, the antigen responsible for the elimination of anti- $\alpha_5$  must be renal derived.

and lung. A threefold increase in the renal fixation of  $\gamma_2$ -globulin from Lewis rats with AIC nephritis immunized with Fx1A was observed without significant increase in fixation to other organs. However, the proportion of radioactivity in the kidneys, bound to particulate material such as whole glomeruli, did not differ from that in controls injected with normal rat  $\gamma$ -globulin. Over 90% of kidney-fixed  $\gamma_2$ -globulin could be recovered in a low speed supernatant indicating the lack of glomerular binding antibody.

*In Vivo Organ Fixation of Heterologous Antibody to Renal Antigens (Table II).*—Using the more precise paired label technique only 0.15% of 1.5  $\mu\text{g}$  P of rabbit anti- $\alpha_5$  fixed per gram of normal rat kidney over a 24 hr period. Approximately 5 times more of this antibody fixed in AIC-nephritic kidneys, reflecting fixation either to glomerular bound antigen or to tubular antigens abnormally exposed to circulating antibody. Most of the kidney-fixed antibody could be recovered in a low speed sediment, as would be expected if antibody



were largely glomerular bound. A slightly greater proportion of the kidney-fixed radioactivity was recoverable in this low speed sediment in kidneys from rats with AIC nephritis than normals. The remainder of the labeled  $\gamma$ -globulin was recoverable from the sediment after high speed centrifugation comparable with that employed in the preparation of Fx1A from kidney homogenates. Although the methodology was not strictly comparable, anti-RTE which contained antibodies to all three renal tubular epithelial cell antigens (RTE- $\alpha_3$ , RTE- $\alpha_4$ , and RTE- $\alpha_5$ ) also fixed to AIC-nephritic kidneys to a greater extent than to normal kidneys. As a control, labeled nephrotoxic  $\gamma$ -globulin, containing antibody primarily to glomerular basement membranes (GBM), was injected into normal and rats with AIC nephritis. There was less renal fixation of this anti-GBM globulin per gram of kidney in rats with AIC nephritis than

TABLE II

*In Vivo* Kidney Fixation of Rabbit Antibody to RTE Antigens\* in Normal and Nephritic Rats

Antibody	Amount† injected	Normals	AIC Nephritics	$\frac{\text{AIC Nephritics}}{\text{Normals}}$
	$\mu\text{g}$			
Anti- $\alpha_5$ §	1.5	0.15	0.71	4.73
Anti-RTE	280	0.15	0.33	2.2
Anti-GBM Antibody	148	2.9	1.3	0.45

\* Average per cent dose per gram Lewis kidney at 24 hr. (3 rats per group).

†  $\gamma_2$ -globulin protein.

§ Paired label technique.

|| Single label technique.

in normal rats, which is an indication that the increased fixation of the anti- $\alpha_5$  in kidneys from rats with AIC nephritis was not a result of contaminating antibody to GBM.

*Serologic Studies in Rats with AIC Nephritis.*—Circulating antibody to RTE- $\alpha_5$  in rats with AIC nephritis could not be found using micro-Ouchterlony techniques. However, using an immunologically specific inhibition test, the IFIT, low titers of antibody to RTE- $\alpha_5$  could be found in rats with AIC nephritis. Commencing about 3 wk after a single immunization, titers of anti-RTE- $\alpha_5$  at 1:2 to 1:4 were found which persisted through the 8th wk but no longer could be detected by the 9th wk after immunization, at a time when glomerular lesions were fully developed.

#### DISCUSSION

The results of the present investigation establish the following points pertinent to the pathogenetic mechanism involved in the induction of AIC glomerulonephritis induced in rats by immunization with tubular antigen. Typical

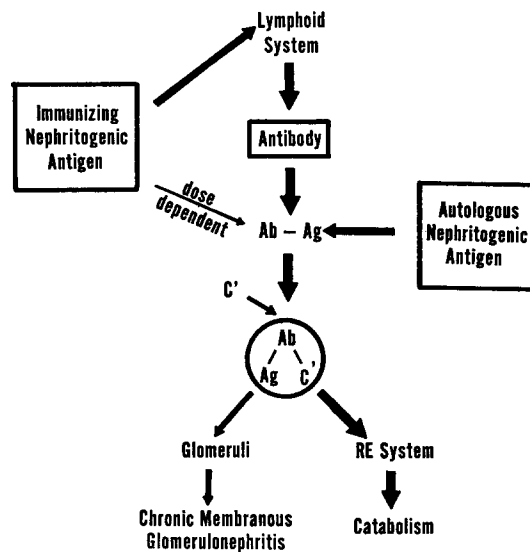
glomerulonephritis can be induced in rats by a single immunization with microgram amounts of crude or purified RTE antigen in complete Freund's adjuvant. It is unlikely that the amount of antigen employed is sufficient to account for the amount of RTE antigen deposited in the glomeruli as observed by immunofluorescent and ultrastructural techniques (3, 6). Furthermore, in rats with AIC nephritis induced with heterologous antigen, autologous antigen can be found along glomerular capillary walls, deposited in a pattern identical to  $\gamma$ -globulin and  $\beta_{1C}$ -globulin (7). Therefore, it seems likely that autologous antigen is one and perhaps the major source of antigen for the antigen-antibody-complement deposits found in the glomeruli in this renal disease. Since heterologous as well as autologous RTE antigen can be found in glomeruli after intensive heterologous immunization, and since increasing the amount of immunizing antigen appears to enhance the development and severity of the nephritis, it is likely that exogenous antigen if present in large enough amounts can also participate in the formation of nephritogenic immune complexes. A circulating antibody response to renal tubular but not glomerular antigens has been shown in rats with AIC nephritis and has also been demonstrated by Grupe and Kaplan (17). Further,  $\gamma$ -globulin eluted from kidneys, presumably glomeruli, in this disease reacts with tubular cells and not glomeruli (17). Thus, nephritis appears to be associated with the deposition of host antibody and autologous RTE- $\alpha_5$  in the glomeruli.

Approximately 7.5% of a tracer dose of  $\gamma_2$ -globulin containing antibody specific for RTE- $\alpha_5$  was rapidly eliminated from the circulation of normal rats. This occurred despite the recovery of only 0.07% of the injected immune globulin fixed to the kidney over a comparable time period. This demonstrates that small amounts of nonkidney-fixed RTE- $\alpha_5$ , or an antigenically related molecule, normally were available to react with circulating anti- $\alpha_5$ . Since 24 hr after bilateral nephrectomy the accelerated immune elimination of anti- $\alpha_5$  did not occur, the reacting antigen must be derived from the kidney and its half-life must be rather brief. The increased glomerular fixation of globulin-containing antibody to RTE- $\alpha_5$  in AIC-nephritic rats is consistent with the immunofluorescent observations that RTE- $\alpha_2$  is deposited in glomeruli from rats with AIC nephritis (6).

It was determined that approximately 60 ng of anti- $\alpha_5$  was eliminated from the circulation of a normal Lewis rat in 15 min. Since the antigen-antibody ratio of complexes formed in vivo is not known, determination of the amount of available RTE- $\alpha_5$  cannot be made. A state of natural unresponsiveness to minute concentrations of this tissue antigen would appear to exist in normal animals. Immunization with autologous, homologous, or heterologous RTE- $\alpha_5$  in complete adjuvant, apparently terminates the tolerant state. It seems most likely that the continued liberation of autologous antigen from the kidney in the presence of continued synthesis of antibody capable of reacting with

autologous RTE- $\alpha_5$  leads to the formation of autologous immune complexes which deposit in an immunologically nonspecific fashion in the glomeruli and induce a progressive membranous glomerulonephritis manifest clinically as the nephrotic syndrome. The salient features of the autologous immune complex pathogenesis as elucidated in this study are diagrammatically presented in Text-fig. 4.

Although this postulated pathogenetic mechanism is unique among the experimentally induced glomerulonephritides, at least one spontaneous disease of laboratory animals may have a similar pathogenetic basis. The spontaneous



TEXT-FIG. 4. This schematic outline of the autologous immune complex pathogenesis is used to illustrate the salient features of this concept as they apply to AIC nephritis.

renal disease observed in NZB/NZW F1 hybrid mice (18, 19) has many morphologic and immunohistochemical resemblances to rats with AIC nephritis (20).  $\gamma$ -Globulin,  $\beta$ 1C-globulin, and nuclear antigens are deposited in the glomeruli in a granular fashion in this spontaneous disease (20) and by electron microscopy subepithelial deposits are frequently observed (21). Acid eluates from diseased glomeruli do not have specificity for normal glomerular base. Thus, in this spontaneous disease, nuclear antigen(s)-autoantibody complexes appear to be pathogenetically related to the production of renal injury. Whether the nuclear antigen(s), which appear to be at least in part DNA, is of autologous origin or represents exogenous antigen, possibly of viral origin (22), has not been ascertained.

The use of purified antigens in the study of AIC nephritis has provided a

better understanding of some of the earlier immunologic observations. It is clear that single microgram immunizations using homologous renal tubular antigen are nephritogenic and that repeated large intraperitoneal immunizations are not essential (1, 23, 24). Also, it is understandable that the various antikidney antibodies, detected by a variety of *in vitro* techniques after immunization with crude preparations, would bear little relationship to the development of AIC nephritis (25, 26). The crude antigenic materials would in all likelihood elicit antibodies to several nonnephritogenic antigens as well as to RTE- $\alpha_5$  (11).

In view of the autologous immune complex pathogenesis of this disease and its slow development, earlier reports of its transfer within 2 wk after parabiosis (27) or lymphoid cell transfer (27, 28) must be reevaluated. The evidence presented from these latter studies suggests that the renal changes transferred were not similar to the original AIC nephritis, but showed a proliferative response and did not demonstrate the immunofluorescent and electron microscopic hallmarks of AIC nephritis. It is possible that this glomerulitis was part of a homologous disease reaction associated with the transfer of incompatible immunologically competent cells to tolerant hosts (29). The transfer of a very mild AIC nephritis with isologous lymphoid cells appears possible but its induction period is at least as long as that of the initially immunized rat.<sup>3</sup>

The concept that autologous circulating antigens can react with host antibody and participate in the formation of immune complexes has important implications in the understanding of a variety of diseases including certain types of human glomerulonephritis. Some human idiopathic membranous glomerulonephritides with nephrotic syndrome are morphologically very similar to AIC nephritis in the rat (30). With the demonstration of immunologic cross-reactions of environmental antigens with a variety of human tissue antigens (reviewed in reference 31), it is possible that exposure to such environmental antigens might induce formation of antibodies cross-reactive with host antigens present in the circulation (32). Circulating pathogenic immune complexes could then be formed. A situation not too dissimilar from this has been produced in experimental thyroiditis (33). In human systemic lupus erythematosus with nephritis the deposition of a nuclear antigen(s) (34) and antinuclear antibody (35) in the kidney has been implicated in the pathogenesis of the renal lesions.

#### SUMMARY

The pathogenetic mechanism involved in a form of experimental allergic glomerulonephritis induced by immunization of rats with renal tubular antigen

<sup>3</sup> Glasscock, R. J., J. I. Watson, S. Lee, J. D. Feldman, and F. J. Dixon. Autologous immune complex nephritis induced with renal tubular antigen. III. Cellular and parabiotic transfer. Manuscript in preparation.

has been investigated. A single immunization with less than a milligram of a crude renal tubular preparation, probably containing less than 25  $\mu\text{g}$  of the specific nephritogenic antigen, is effective in the induction of this form of chronic membranous glomerulonephritis. In the nephritic kidney autologous nephritogenic tubular antigen is found in the glomerular deposits along with  $\gamma$ -globulin and complement. When large amounts of antigen are injected during induction of the disease the exogenous immunizing antigen can also be detected in the glomerular deposits. It appears that this disease results from the formation of circulating antibodies capable of reacting with autologous renal tubular antigen(s) and the deposition of these antibodies and antigen(s) plus complement apparently as immune complexes in the glomeruli. This pathogenetic system has been termed an autologous immune complex disease and the resultant glomerulonephritis has been similarly designated.

We wish to acknowledge the capable technical assistance of Mrs. Shirley Gourdine. The senior author is greatly indebted to Dr. John P. Merrill for his support.

#### BIBLIOGRAPHY

1. Heymann, W., D. B. Hackel, J. Harwood, S. G. F. Wilson, and J. L. P. Hunter. 1959. Production of the nephrotic syndrome in rats by Freund's adjuvants and rat kidney suspension. *Proc. Soc. Exptl. Biol. Med.* **100**:660.
2. Dixon, F. J., E. R. Unanue, and J. I. Watson. 1965. Immunopathology of the kidney. *In* IVth International Symposium of Immunopathology. P. Grabar and P. A. Miescher, editors. Schwabe & Co., Basel. 363.
3. Feldman, J. D. 1963. Pathogenesis of ultrastructural glomerular changes induced by immunologic means. *In* IIIrd International Symposium of Immunopathology. P. Grabar and P. A. Miescher, editors. Schwabe & Co., Basel. 263.
4. Okuda, R., M. Kaplan, F. Cuppage, and W. Heymann. 1965. Deposition of autologous gamma globulin in kidneys of rats with nephrotic and disease of various etiologies. *J. Lab. Clin. Med.* **66**:204.
5. Watson, J. I., and F. J. Dixon. 1966. Experimental glomerulonephritis. IX. Factors influencing the development of kidney in adjuvant nephritis in rats. *Proc. Soc. Exptl. Biol. Med.* **121**:216.
6. Edgington, T. S., R. J. Glassock, and F. J. Dixon. 1968. Autologous immune complex nephritis induced with renal tubular antigen. I. Identification and isolation of the pathogenetic antigen. *J. Exptl. Med.* **127**:555.
7. Edgington, T. S., R. J. Glassock, and F. J. Dixon. 1967. Autologous immune complex pathogenesis of experimental allergic glomerulonephritis. *Science.* **155**:1432.
8. Steblay, R. W. 1962. Glomerulonephritis induced in sheep by injection of heterologous GBM and Freund's complete adjuvant. *J. Exptl. Med.* **116**:253.
9. Lerner, R. A., and F. J. Dixon. 1966. Transfer of ovine experimental allergic glomerulonephritis (EAG) with serum. *J. Exptl. Med.* **124**:431.
10. Lerner, R. A., R. J. Glassock, and F. J. Dixon. 1967. The role of antiglomerular

- basement membrane antibody in the pathogenesis of human glomerulonephritis. *J. Exptl. Med.* **126**:989.
11. Edgington, T. S., R. J. Glasscock, and F. J. Dixon. 1967. Characterization and isolation of specific renal tubular epithelial antigens. *J. Immunol.* **99**:1199.
  12. Kekwick, R. A., M. E. Mackay, M. H. Nance, and B. R. Record. 1955. The purification of human fibrinogen. *Biochem. J.* **60**:671.
  13. Levy, H. B., and H. A. Sober. 1960. A simple chromatographic method for preparation of gamma globulin. *Proc. Soc. Exptl. Biol. Med.* **103**:250.
  14. McConahey, P. J., and F. J. Dixon. 1966. A method of trace iodination of proteins for *in vivo* studies. *Intern. Arch. Allergy Appl. Immunol.* **29**:185.
  15. Unanue, E. R., and F. J. Dixon. 1965. Experimental glomerulonephritis. V. Studies on the interaction of nephrotoxic antibodies with tissues of the rat. *J. Exptl. Med.* **121**:697.
  16. Müller-Eberhard, H. J. 1960. A new supporting medium for preparative electrophoresis. *Scand. J. Clin. Lab. Invest.* **12**:33.
  17. Grupe, W. E., and M. H. Kaplan. 1967. A proximal tubular antigen in the pathogenesis of autoimmune nephrosis. *Federation Proc.* **26**:573.
  18. Helyer, B. J., and J. B. Howie. 1963. Renal disease associated with positive lupus erythematosus tests in a cross-bred strain of mice. *Nature.* **197**:197.
  19. Hicks, J. D., and F. M. Burnet. 1966. Renal lesions in the "autoimmune" mouse strains NZB and F<sub>1</sub>NZB × NZW. *J. Pathol. Bacteriol.* **91**:467.
  20. Dixon, F. J., T. S. Edgington, and P. H. Lambert. 1967. Nonglomerular antigen-antibody complex induced nephritis. In Vth International Symposium of Immunopathology. P. Grabar and P. A. Miescher, editors Schwabe & Co., Basel. In press.
  21. Mellors, R. C. 1965. Autoimmune disease in NZB/BL mice. I. Pathology and pathogenesis of a model system of spontaneous glomerulonephritis. *J. Exptl. Med.* **122**:25.
  22. Mellors, R. C., and C. Y. Huang. 1966. Immunopathology of NZB/BL mice. V. Virus-like (filterable) agent separable from lymphoma cells and identifiable by electron microscopy. *J. Exptl. Med.* **124**:1031.
  23. Heymann, W., E. P. Kmetec, S. G. F. Wilson, J. L. P. Hunter, D. B. Hackel, and F. Cuppage. 1963. Experimental autoimmune renal disease in rats. In IIIrd International Symposium of Immunopathology. P. Grabar and P. A. Miescher, editors. Schwabe & Co., Basel. 240.
  24. Heymann, W., E. P. Kmetec, S. G. F. Wilson, J. L. P. Hunter, D. B. Hackel, R. Okuda, and F. Cuppage. 1965. Experimental autoimmune renal disease in rats. *Ann. N. Y. Acad. Sci.* **124**:310.
  25. Hunter, J. L. P., D. B. Hackel, and W. Heymann. 1960. Nephrotic syndrome in rats produced by sensitization to rat kidney proteins: Immunologic studies. *J. Immunol.* **85**:319.
  26. Boss, J. H., E. Silber, and D. Nelken. 1967. Antibodies to species homologous tissue antigens in the rat. II. Circulating antibodies during the development of autoimmune renal disease. *Clin. Exptl. Immunol.* **2**:455.
  27. Heymann, W., J. L. P. Hunter, D. B. Hackel, and F. Cuppage. 1962. Transfer of experimental autoimmune nephrosis in rats. *Proc. Soc. Exptl. Biol. Med.* **111**:568.

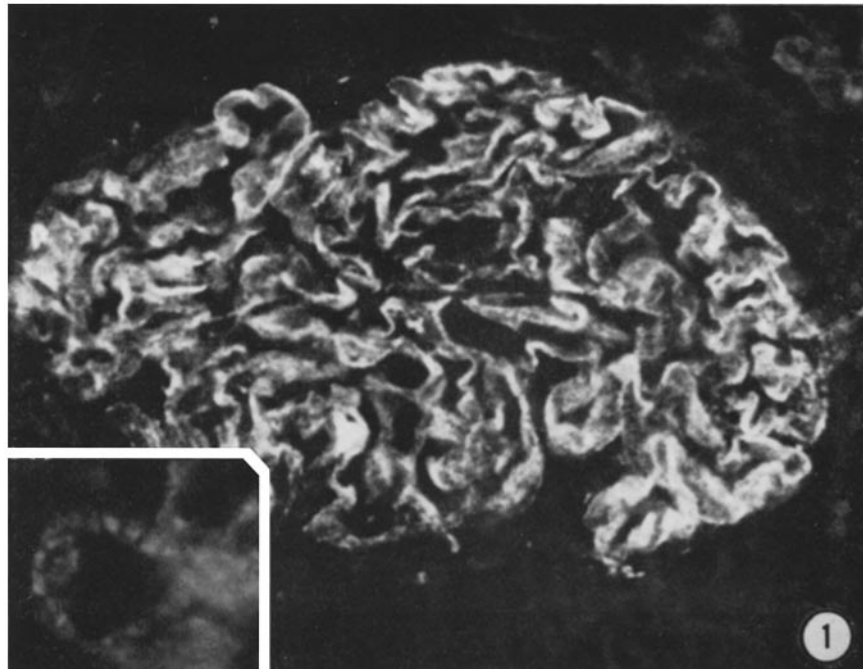
28. Hess, E. V., C. T. Ashworth, and M. Ziff. 1962. Transfer of an autoimmune nephrosis in the rat by means of lymph node cells. *J. Exptl. Med.* **115**:421.
29. Armstrong, M. Y. K., J. Andre-Schwartz, R. M. Lewis, and R. S. Schwartz. 1967. Induction of glomerulonephritis by lymphoid cells. *Clin. Res.* **15**:292.
30. Alousi, M. A., R. S. Post, W. Heymann, and F. Cuppage. 1967. Immunohistochemical and electron microscopic studies of experimental autoimmune nephrosis in rats; comparison with human renal biopsies. *Federation Proc.* **26**:743.
31. Dumonde, D. C. 1966. Tissue specific antigens. *Advan. Immunol.* **5**:245.
32. Weigle, W. O. 1967. Natural and Acquired Immunologic Unresponsiveness. World Publishing Co., Cleveland.
33. Weigle, W. O., and G. J. High. 1967. Behavior of autologous thyroglobulin in the circulation of rabbits immunized with either heterologous or altered homologous thyroglobulin. *J. Immunol.* **98**:1105.
34. Koffler, D., P. Shur, and H. Kunkel. 1967. Immunological studies concerning the nephritis of systemic lupus erythematosus. *J. Exptl. Med.* **126**:607.
35. Krishnan, C., and M. H. Kaplan. 1967. Immunopathologic studies of systemic lupus erythematosus. II. Anti-nuclear reaction of  $\gamma$ -globulin eluted from patients with lupus nephritis. *J. Clin. Invest.* **46**:569.

## EXPLANATION OF PLATES

## PLATE 74

FIG. 1. Immunofluorescent demonstration of host  $\gamma$ -globulin deposited as a partially confluent sheet of granules along the glomerular capillary walls of a rat with AIC nephritis induced by immunization once with 5 mg rat kidney Fx1A in complete adjuvant. The distinctly granular character of the deposits is illustrated in the inset.  $\times 300$  (Inset,  $\times 1000$ ).



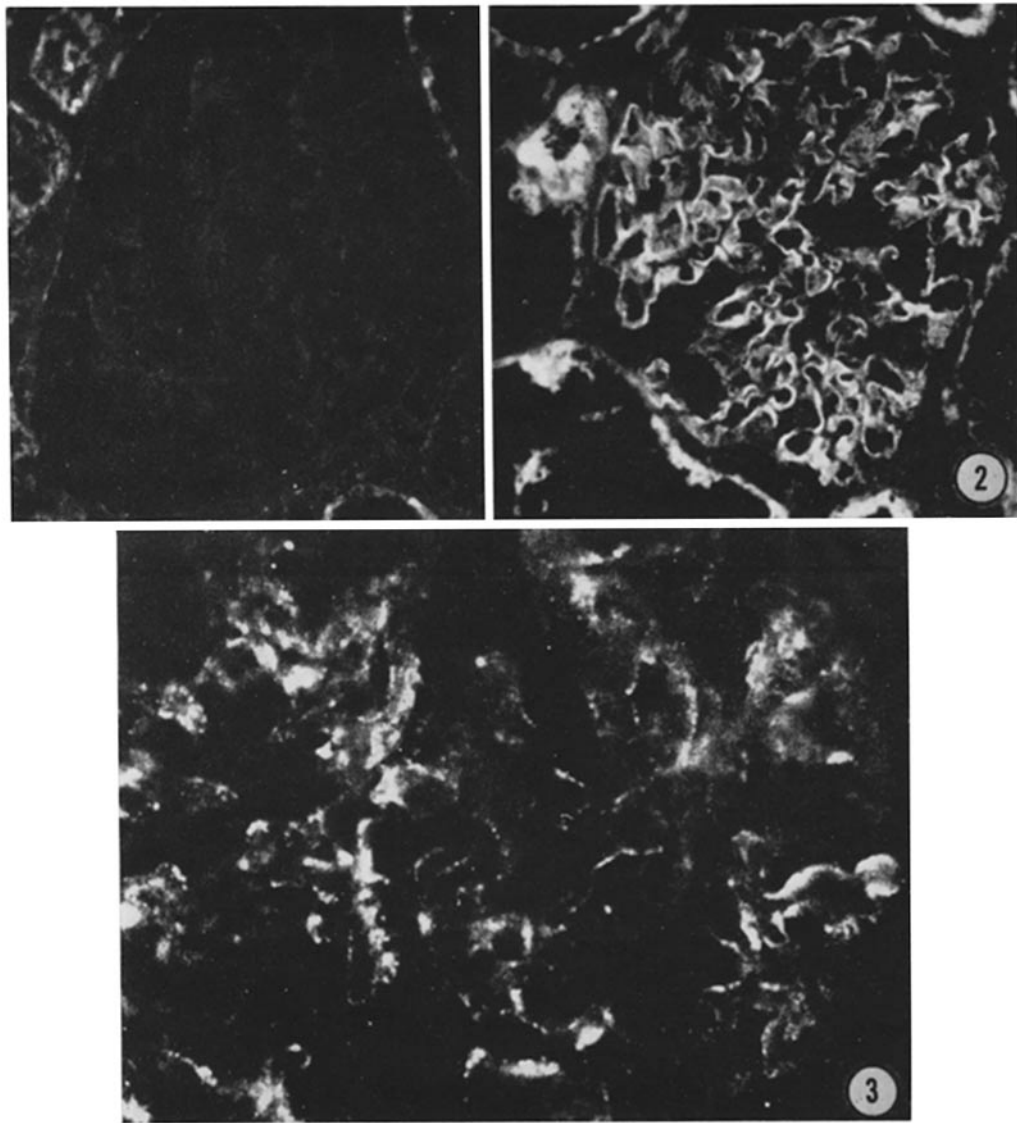


(Glassock et al.: Autologous immune complex nephritis. II)

PLATE 75

FIG. 2. Autologous antigenic specificity of glomerular deposited nephritogenic antigen in AIC nephritis induced with human Fx1A. The nephritogenic antigen is demonstrated on the right with anti-rat RTE which has been absorbed three times with 5 mg human Fx1A/mg  $\gamma_2$ -globulin. This antisera should then contain antibody only to the rat-specific determinants of the nephritogenic antigen. On the left can be seen the results of a similar absorption of anti-rat RTE with rat Fx1A which abolishes the reaction.  $\times 250$ .

FIG. 3. The presence of exogenous antigen in the glomerular deposits of AIC nephritis induced by repeated heavy immunization with human Fx1A. Anti-human RTE, absorbed three times with rat Fx1A (5 mg/mg  $\gamma$ -globulin) and demonstrating immunohistochemical specificity for human renal tubular epithelium, reacts with glomerular deposited nephritogenic antigen. Absorption of this human specific anti-serum with human Fx1A abolished the reaction.  $\times 500$ .



(Glassock et al.: Autologous immune complex nephritis. II)