

FURTHER STUDIES ON METACHROMASIA IN CULTURED
HUMAN FIBROBLASTS

STAINING OF GLYCOSAMINOGLYCANS (MUCOPOLYSACCHARIDES) BY ALCIAN
BLUE IN SALT SOLUTIONS*

BY B. SHANNON DANES,† M.D., J. E. SCOTT,§ Ph.D.
AND ALEXANDER G. BEARN, M.D.

*(From the Division of Human Genetics, Department of Medicine, Cornell University
Medical College, New York 10021)*

(Received for publication 30 April 1970)

During the last several years metachromatic stains have been applied to cultured cells derived from patients with a variety of inherited diseases. The initial studies on the genetic mucopolysaccharidoses (1, 2) showed that the appearance of metachromasia in fibroblast cultures from affected individuals and heterozygous carriers was correlated with the presence in the cells of chemically identified glycosaminoglycans (mucopolysaccharides). However, the metachromatic reaction employed in the conventional manner is not specific; it results from the reaction of the dye (toluidine blue) with negatively charged substances (3, 4) including intracellular lipids, nucleic acids, polypeptides, and metaphosphates.

Since the initial observation on the mucopolysaccharidoses, metachromasia has been demonstrated in fibroblast cultures derived from clinically affected and normal heterozygotes in a number of genetic disorders and in a small number of presumed noncarrier individuals (5). Thus, the question has been raised (6-8) concerning the limitations of metachromasia as a diagnostic tool.

Identification of glycosaminoglycans in tissues has been based on the observation (9) that cetylpyridinium precipitates of polyanions from solution can be selectively resolubilized by the progressive addition of electrolytes. The analogous histochemical method, (10) which uses Alcian blue in place of cetylpyridinium chloride, seems a feasible way to detect and identify specific glycosaminoglycans within the cultured cells. We describe here the application of this histochemical method to fibroblast cultures.

* This research was made possible by a grant from The National Foundation-March of Dimes and was partially supported by U.S. Public Health Service grant AM 13429 and by a grant from the National Foundation for Genetics and Neuromuscular Diseases.

† Address requests for reprints to B. Shannon Danes.

§ Medical Research Council Rheumatism Research Unit, Canadian Red Cross Memorial Hospital, Taplow, Maidenhead, Berkshire, England.

Methods

Skin biopsies were obtained from 52 normal individuals and a total of 66 patients with a number of genetic disorders. Only patients with the classical clinical and biochemical phenotype for each disorder were included in this study. In addition, skin biopsies were obtained from 6 normal individuals whose cell cultures had previously shown cellular metachromasia, and from 19 members of their families. The establishment of the cell lines from skin biopsies by standard culture methods (11) averaged approximately 6 wk, so that the cells studied had been grown as monolayer cultures for 1–2 months (2–6 subcultures by trypsinization) prior to these studies. For histochemical studies, approximately 20,000 cells were inoculated into a 2 oz glass flask containing a cover slip and were grown in reinforced Eagle's medium containing 10% by volume of serum from a newborn calf. 7 days after subculturing, the cover slip was removed and washed vigorously in warm balanced salt solution for approximately 5 sec. Each cover slip was then cut with a diamond pencil into three parts. One part was immediately immersed in methanol for 5 min and stained with the metachromatic dye (toluidine blue O), as previously described in detail (1). The two other parts of the cover slip were stained for glycosaminoglycans in a simple one-step procedure, using Alcian blue 8 GX (10).

The stock solutions were: 1% Alcian blue 8 GX (Imperial Chemical Industries, Ltd., Teesside, England.) in distilled water, 4 M magnesium chloride, 1 M sodium acetate, and 1 M hydrochloric acid. The solutions of dye, buffer, and $MgCl_2$ were mixed with distilled water to give a solution containing 0.05% Alcian blue in 0.025 M acetate buffer at pH 5.7 and the required concentration of $MgCl_2$. The cover slips carrying cell monolayers were immersed overnight at room temperature in 8 ml of dye solution in an upright Columbia coplin jar (Arthur H. Thomas Co., Philadelphia, Pa.). The preparations were dehydrated in 70% and 100% alcohol, cleared in xylene, and mounted with Permount. In the initial studies the $MgCl_2$ concentrations ranged from 0.1 to 0.6 M, but it became apparent that only two concentrations (0.1 and 0.3 M) were needed to differentiate between "normal" and "abnormal" cultured cells.

Since glycosaminoglycans are water-soluble, the influences of saline washing and of fixation were studied by dividing each of several cover slip preparations into four parts, one of which was unwashed and the other three washed for 5 sec, 1 min, or 10 min and then placed in either methanol or 100% ethanol (-4° or $-20^\circ C$) for 10 min; each was stained with either toluidine blue O or Alcian blue. The intensity of staining with either dye used appeared the same in the first three washing conditions, whereas there was a definite decrease in basophilia after the 10-min washing. Methanol-treated preparations gave the most intense metachromasia; methanol or ethanol decreased alcianophilia. The most reproducible staining with Alcian blue occurred when the cover slip preparation was washed quickly in saline and immediately put in the dye solution.

For chemical studies, cells of the same lines as those studied histochemically were grown for about 2 wk in round bottles on a roller apparatus in reinforced Eagle's medium containing 10% by volume of serum from a newborn calf. The isolation and estimation of total glycosaminoglycans (as uronic acid) by the carbazole method have been previously described (11).

RESULTS

Cytoplasmic staining observed with toluidine blue O will be referred to as orthochromasia (blue) or metachromasia (pink), and that with Alcian blue as alcianophilia. All cultures stained with Alcian blue in 0.1 M $MgCl_2$.

The cultured skin fibroblasts from 52 normal, unrelated persons showed no cellular metachromasia (Table I, Fig. 1 *a*); the cytoplasm stained light blue

TABLE I
Histochemical Reaction of Skin Fibroblast Cultures from Patients with Various Genetic Disorders

| Patients Studied | No. of patients | Metachromasia* | Alciano- philia‡ | Acid glycosaminoglycan content§ (µg uronic acid/mg cellular protein ± SD) |
|--|-----------------|----------------|---------------------|---|
| Normals | 52 | — | — | 5.3 ± 1.1 |
| | 6 | + | — | 4.0 ± 0.7 |
| Hurler | 6 | + | + | 11.2 ± 2.1 |
| Hunter | 9 | + | + | 18.2 ± 5.4 |
| Sanfilippo | 2 | + | — | 12.3 ± 3.0 |
| Generalized spondyloepi- physeal dysplasia (Morquio) | 3 | — | — | 5.6 ± 0.0 |
| | 1 | + | + | 5.9 |
| Multiple epiphyseal dys- plasias | 1 | + | — | 7.7 |
| Epiphysometaphyseal dysplasia | 1 | — | — | 4.0 |
| Scheie | 3 | + | + | 9.4 ± 0.5 |
| Maroteaux-Lamy | 5 | — | + | 7.1 ± 0.9 |
| Marfan | 4 | — | — | 11.7 ± 0.3 |
| | 4 | + | — | 21.0 ± 1.4 |
| General gangliosidosis | 2 | + | + | 12.4 ± 1.3 |
| Larsen's syndrome | 2 | +/- | + | 27.2 ± 0.5 |
| Cystic fibrosis | | | | |
| Class I | 2 | + | — | 4.5 ± 0.9 |
| Class II | 2 | + | — | 7.7 ± 2.9 |
| Class III | 2 | — | — | 4.0 ± 0.2 |
| Familial amaurotic idiocy | 1 | + | — | 4.6 |
| Chediak-Higashi | 1 | — | — | 5.9 |
| Progeria | 2 | — | — | 4.7 |
| Primary amyloidosis | 1 | — | — | 4.9 |
| Pseudoxanthoma elasti- cum | 2 | + | — | 5.1 |
| Hyperlipidemia Type 1 | 2 | — | — | 4.1 |
| Gaucher's disease | 8 | + | — | 4.0 |

* Cytoplasmic staining with toluidine blue 0 is referred to as metachromasia (pink) (+) or orthochromasia (blue) (-).

‡ Cytoplasmic staining with Alcian blue solution containing 0.3 M MgCl₂.

§ Measured on cultures (in duplicate) of the same cell lines grown previously.

(orthochromasia). These cultures contained an occasional cell showing metachromatic granules. In an Alcian blue solution containing 0.1 M $MgCl_2$, the nuclei were stained but not the cytoplasm, except for a rare alcianophilic granule (Fig. 1 *b*). Cultures stained with Alcian blue solution containing 0.3 M or 0.4–0.6 M $MgCl_2$ showed virtually no alcianophilia. Because of this lack of staining the cell population was difficult to see. Some extracellular fibrous ma-

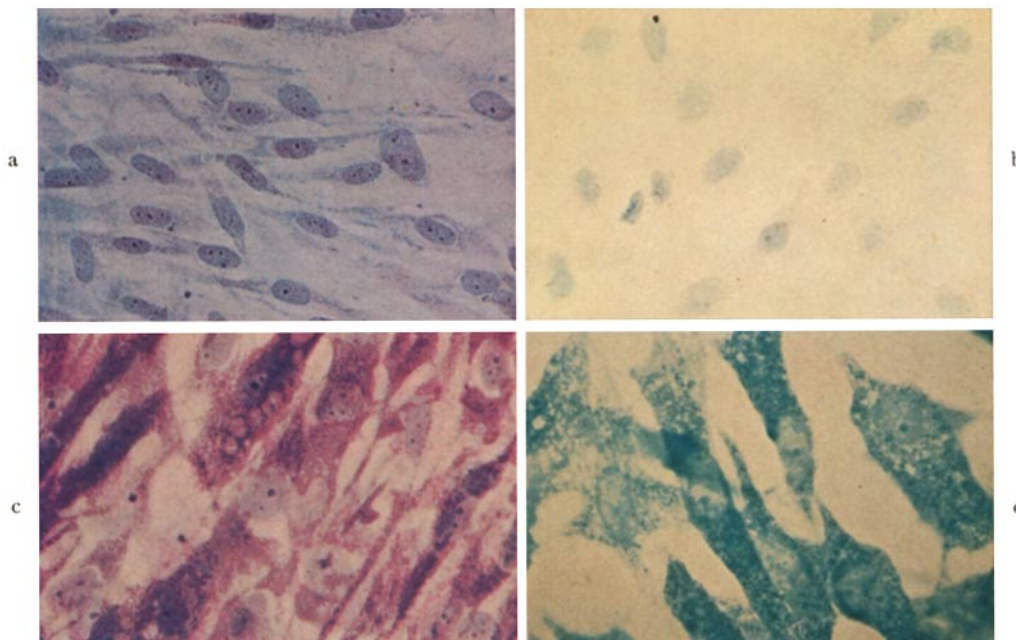


FIG. 1. Monolayers of skin fibroblasts grown in cell culture. (*a*) Fibroblasts from a normal individual stained with toluidine blue O, and (*b*) with Alcian blue solution containing 0.1 M $MgCl_2$. (*c*) Fibroblasts from a patient with the Hurler syndrome stained with toluidine blue O and (*d*) with Alcian blue containing 0.1 M $MgCl_2$. $\times 400$.

terial was present in many preparations which stained with Alcian blue up to 0.3 M $MgCl_2$ but not in higher $MgCl_2$ concentrations.

Cultures from six normal persons from whom metachromatic cultures had been obtained in previous studies again showed marked metachromasia. The uronic acid content was normal and the cultures were not alcianophilic at 0.3 M $MgCl_2$. In each family (Table II), the culture from one parent showed metachromasia (four fathers, two mothers) whereas that from the other parent was orthochromatic. No culture was alcianophilic at 0.3 M $MgCl_2$ and uronic acid contents were normal. In one family, cellular metachromasia was traced through three generations.

In three of the genetic mucopolysaccharidoses studied (Hurler, Hunter, and Scheie syndromes), the cultured skin fibroblasts showed marked cytoplasmic metachromasia. Although discrete metachromatic inclusions could be seen, the staining was diffuse throughout the cytoplasm (Fig. 1 *c*). The same cell lines treated with Alcian blue solutions containing 0.1 M MgCl₂ showed staining of

TABLE II
Metachromasia in Skin Fibroblast Cultures from Six Apparently Normal Families

| Families studied | Metachromasia* | Acid glycosaminoglycans† (μ g uronic acid/mg cellular protein) |
|------------------|----------------|--|
| 1 Sib | + | 5.1 |
| Mother | + | 4.6 |
| Father | - | 4.9 |
| 2 Sib | + | 3.9 |
| Mother | - | 4.5 |
| Father | + | 3.7 |
| 3 Sib | + | 4.2 |
| Mother | + | 3.9 |
| Father | - | 4.0 |
| 4 Sib | + | 2.9 |
| Mother | - | 3.5 |
| Father | + | 4.1 |
| 5 Sib | + | 2.9 |
| Mother | - | 3.9 |
| Father | + | 4.3 |
| 6 Sib 1 | + | 4.0 |
| Sib 2 | - | 3.1 |
| Sib 3 | - | 3.9 |
| Sib 4 | + | 3.4 |
| Mother | - | 3.9 |
| Father | + | 4.7 |
| Maternal | | |
| Grandmother | - | 3.8 |
| Grandfather | - | 4.4 |
| Paternal | | |
| Grandmother | - | 5.9 |
| Grandfather | + | 4.0 |

* Cytoplasmic staining with toluidine blue O is referred to as metachromasia (pink) (+) or orthochromasia (blue) (-). No alcianophilia at 0.3 M MgCl₂ was detected in any of the cultures.

† Means \pm SD: All cultures 4.1 ± 0.7 ; metachromatic cultures 4.0 ± 0.7 ; ametachromatic cultures 4.2 ± 0.8 .

the nuclei and intensely stained discrete cytoplasmic granules (Fig. 1 *d*). The cytoplasm did not show diffuse alcianophilia. At 0.3 M MgCl₂ only the cytoplasmic granules were stained. In Alcian blue solutions containing higher concentrations of MgCl₂, no cellular staining was observed.

Two patients with the clinical and biochemical phenotype of Sanfilippo syndrome were studied. Although the cultured fibroblasts showed marked metachromasia and increased uronic acid content ($12.3 \pm 3.0 \mu\text{g}/\text{mg}$ cellular protein), no cytoplasmic alcianophilia was observed at 0.3 M MgCl₂.

In the spondyloepiphyseal dysplasias studied, which included the Morquio syndrome, four showed neither metachromasia nor alcianophilia at 0.3 M MgCl₂, one showed both, and another only metachromasia. The cellular uronic acid content was normal or slightly increased in all cultures.

In cultures from five cases of Maroteaux-Lamy syndrome, four of whom were from the same family, the fibroblasts consistently showed no metachromasia. When they were stained with Alcian blue solutions containing 0.1 or 0.3 M MgCl₂, discrete inclusions were seen throughout the cytoplasm. The uronic acid content ($7.1 \pm 0.9 \mu\text{g}/\text{mg}$ cellular protein) was slightly increased.

In the eight cases of the Marfan syndrome, the cytoplasm of the fibroblasts did not show increased alcianophilia at either 0.1 or 0.3 M MgCl₂ although four cases were metachromatic and four orthochromatic. The uronic acid content of both groups was higher than normal; the metachromatic group had a higher uronic acid content ($21.0 \pm 1.4 \mu\text{g}/\text{mg}$ cellular protein) than the orthochromatic cultures ($11.7 \pm 0.3 \mu\text{g}/\text{mg}$ cellular protein). We have no explanation for the lack of cytoplasmic alcianophilia.

Two patients with generalized gangliosidosis produced skin fibroblasts showing marked metachromasia and alcianophilia at 0.3 M MgCl₂. Thus, these cells could not be distinguished from those derived from patients affected with a genetic mucopolysaccharidosis. The uronic acid content ($12.4 \pm 1.3 \mu\text{g}/\text{mg}$ cellular protein) was above normal.

Cultures derived from two patients with Larsen's syndrome showed vacuoles containing material that was sometimes metachromatic but more often orthochromatic. Alcianophilia was marked at 0.3 M MgCl₂. The cellular uronic acid content was high ($27.2 \pm 0.5 \mu\text{g}/\text{mg}$ cellular protein).

Cellular metachromasia of the cultures derived from patients with cystic fibrosis was divided into three classes: class I—vesicular, class II—generalized (vesicular-granular-cytoplasmic), and class III—orthochromatic (ameta-chromatic). No culture showed alcianophilia at 0.3 M MgCl₂. The intracellular uronic acid content was similar to that of normal controls.

The other genetic disorders studied are not associated with deranged glycosaminoglycan metabolism (Table I). The cultures derived from the patients with adult Gaucher's disease, when stained with toluidine blue O, showed large metachromatic cells within a population of orthochromatic cells. Cultures showed no alcianophilia at 0.3 M MgCl₂. Fibroblast cultures from one patient

with familial amaurotic idiocy showed marked cytoplasmic metachromasia but no cytoplasmic alcianophilia at 0.3 M $MgCl_2$. Fibroblast cultures from a patient with Chediak-Higashi syndrome showed cytoplasmic inclusions which stained slate gray-green with both toluidine blue O and Alcian blue. Pseudoxanthoma elasticum showed marked metachromasia but no alcianophilia at 0.3 M $MgCl_2$. Fibroblasts derived from two patient with progeria, one with primary amyloidosis, and two with hyperlipidemia Type I showed no metachromasia or alcianophilia at 0.3 M $MgCl_2$.

DISCUSSION

Cellular metachromasia of cultured fibroblasts has been used to detect abnormal cell phenotypes (1, 2). Since the original observation was made (1) two major difficulties have been encountered. Firstly, metachromatic staining is sometimes open to misinterpretation because of the inevitable variations occurring in culture technique; in particular, unhealthy cells may stain a purple to lavender color which may be akin to metachromasia. Secondly, the nonspecificity of the physicochemical reaction of metachromasia (3, 4) lends itself to oversimplification concerning its significance.

To determine if the metachromasia observed in a culture is primarily due to glycosaminoglycans, we can now apply a more specific histochemical method for the differentiation of this group of compounds.

The eight glycosaminoglycans present in tissue are negatively charged by virtue of the sulfate ester groups and the carboxyl groups of uronic acids (12); therefore, they are bound to and precipitated by cationic dyes such as toluidine blue O and Alcian blue. It has been shown (9) that the electrostatic combination of polyanions with organic cations is reversible in the presence of inorganic electrolytes. Thus, it was possible to apply the "critical electrolyte concentration" concept to the differentiation of glycosaminoglycans (10). Alcian blue 8 GX was found to stain with increasing selectivity as increasing amounts of magnesium chloride were incorporated into the dye solution. When purified preparations of glycosaminoglycans from animal tissues were used, all polyanions stained at low electrolyte concentrations (<0.05 M $MgCl_2$) (10). In 0.1 M $MgCl_2$, RNA, DNA, and all known glycosaminoglycans (including hyaluronic acid) stained; at 0.3 M only dermatan sulfate, chondroitin 4- and 6- sulfates, heparan sulfate, keratan sulfate, and heparin stained; and above 0.4 M only keratansulfate and heparin stained.

The glycosaminoglycans found in the normal cultured skin fibroblast are hyaluronic acid (68%), dermatan sulfate (16%), and chondroitin 4- and 6-sulfates (16%) (6). Heparan sulfate and keratan sulfate have not been isolated from such cultures. The staining characteristics of normal cultured fibroblasts correlate well with these chemical data; the mild diffuse alcianophilia in normal cells at 0.1 M $MgCl_2$ probably reflected the presence of such polyanions as RNA, DNA, and hyaluronic acid (10), whereas the cytoplasm was virtually unstained at higher $MgCl$ concentrations.

The use of toluidine blue O in studies such as these has led to some concern about the frequency of metachromasia in cells cultured from control populations (7, 8, 13). 6% of the cultures established from normal, unrelated individuals showed unequivocal metachromasia in our laboratory (5). Matalon and Dorfman (6), studying a similar nonhospital population, found 7%. Both values are plausibly acceptable figures if the frequency of heterozygous carriers of inherited metabolic diseases is calculated. However, cytoplasmic metachromasia was reported by Taysi et al. (7) in 27% of cultures derived from a pediatric hospital population and by Nadler et al. (14) in 15% of all their control cultures.

In order to determine the significance of this metachromasia of cultured fibroblasts from presumed normal individuals, we studied six of the normal families in our series found to have metachromatic cultures (Tables I and II). It became apparent that metachromasia was probably not due to increased intracellular glycosaminoglycans; the cultures showed no alcianophilia in 0.3 M MgCl₂ and the uronic acid content ($4.0 \pm 0.7 \mu\text{g}/\text{mg}$ cellular protein) was not significantly different from that of the orthochromatic cultures ($5.3 \pm 1.1 \mu\text{g}/\text{mg}$ cellular protein). However, as the cellular metachromasia could be traced throughout at least three generations in one family and two generations in the other five families studied, this cytoplasmic staining appeared to indicate an inherited cellular trait, whose basis is at present unknown.

These family studies (Table II) have shown that metachromasia observed in fibroblast cultures derived from normal individuals is a genuine, reproducible reaction that can be traced to one parent in each family studied. We should again like to emphasize the importance of examining the cultured fibroblasts of the parents with metachromasia before considering the metachromasia to be a "false positive" finding.

If the extracellular alcianophilic material should prove to consist of connective tissue glycosaminoglycans derived from the cultured fibroblasts, the relevance of many of the data on intracellular glycosaminoglycans (2, 6, 11) may need to be reassessed.

Metachromasia in cultures from persons with disorders associated with increased intracellular amounts of glycosaminoglycans was expected. Differential staining with Alcian blue has confirmed the chemical findings that the cultured fibroblasts from persons affected with some of the genetic mucopolysaccharidoses show the altered phenotype. Cells derived from patients with Hurler, Hunter, and Scheie syndromes contained granules which stained with Alcian blue; this finding correlates well with the chemical finding (6) of increased intracellular dermatan sulfate in such cultures. In contrast, cultured cells from patients with the Sanfilippo syndrome, which is associated with increased heparan sulfate in tissues and urine, shows no alcianophilia. Cultured fibroblasts from this syndrome have been shown to accumulate dermatan sulfate but to a lesser degree than in the Hurler and Hunter syndromes; this

may account for the absence of alcianophilia in these cultured fibroblasts. Heparan sulfate has not been isolated from such cultures.

The cellular concentration of glycosaminoglycans in the Maroteaux-Lamy syndrome is only modestly increased (Table I). This probably explains the lack of metachromasia. The observed alcianophilia may indicate that this is a more sensitive test or that the slight rise in uronic acid content is due predominantly to alcianophilic glycosaminoglycans.

An increase in hyaluronic acid content of cultured cells from patients with the Marfan syndrome, associated with cellular metachromasia, has been reported (15). In the present study, although the patient group was considered to be homogeneous by clinical criteria, cultures from four patients were metachromatic, whereas those from four others were orthochromatic. Cellular uronic acid was increased in all cultures, but there was no staining with Alcian blue even at 0.1 M $MgCl_2$, under conditions in which hyaluronic acid should have stained, at least if it is highly polymerized.

Although cytoplasmic metachromasia has been observed in cultures derived from the majority of patients with cystic fibrosis (11, 16), glycosaminoglycans did not seem (17) to be stored within the fibroblasts as they are in the genetic mucopolysaccharidoses. As was to be expected, therefore, the cytoplasm of the cells was not alcianophilic.

Metachromasia in cultured fibroblasts from patients with disorders not associated with increased cellular concentrations of polyanions has been difficult to explain (7, 8). It is believed that metachromasia occurs whenever dye molecules aggregate (18). In the anomalous instances, such aggregation must be caused by a factor other than reaction with polyanions, since in all diseases studied (Table I) in which the skin fibroblasts showed unequivocal metachromasia not associated with increased uronic acid content, alcianophilia was absent.

SUMMARY

Staining with Alcian blue in various concentrations of magnesium chloride (alcianophilia) has been found to be a useful supplement to metachromatic staining to detect increased cellular concentrations of glycosaminoglycans (mucopolysaccharides). In many instances alcianophilia at 0.3 M $MgCl_2$ is more specific than metachromasia and does not give "false positives" sometimes found in normal individuals and in those with cystic fibrosis, Gaucher's disease, familial amaurotic idiocy, and pseudoxanthoma elasticum. On the other hand, it gives a "false negative" reaction in the Sanfilippo syndrome (perhaps because the characteristically elevated glycosaminoglycan in this disease, heparan sulfate, is not synthesized by cultured skin fibroblasts), and in the Marfan syndrome. It detects the Maroteaux-Lamy syndrome, which metachromasia does not.

The "false positives" given by metachromasia in all six families studied thus far are genuine, reproducible reactions that can be traced through at

least three generations of normal individuals within a family. There is therefore, in these families, a genetic factor that causes such metachromasia, but it is not increased glycosaminoglycan concentration.

BIBLIOGRAPHY

1. Danes, B. S., and A. G. Bearn. 1966. Hurler's syndrome, a genetic study in cell culture. *J. Exp. Med.* **123**:1.
2. Matalon, R., and A. Dorfman. 1966. Hurler's syndrome, biosynthesis of acid mucopolysaccharides in tissue culture. *Proc. Nat. Acad. Sci. U.S.A.* **56**:1310.
3. Sylvén, B. 1958. On the interaction between metachromatic dyes and various substrates of biological interest. *Acta histochem., Suppl.* **1**:79.
4. Pearse, A. G. E. 1968. Carbohydrates and Mucosubstances. *In* Histochemistry Theoretical and Applied. J. and A. Churchill Ltd., London. 3rd edition. 334.
5. Bearn, A. G., and B. S. Danes. 1969. A genetic study of cystic fibrosis of the pancreas in cell culture. *Trans. Ass. Amer. Physicians Philadelphia.* **82**:248.
6. Matalon, R., and A. Dorfman. 1969. Acid mucopolysaccharides in cultured human fibroblasts. *Lancet.* **2**:838.
7. Taysi, K., M. L. Kistenmacher, H. H. Punnett, and W. J. Mellman. 1969. Limitations of metachromasia as a diagnostic aid in pediatrics. *N. Engl. J. Med.* **281**:1108.
8. Milunsky, A., and J. W. Littlefield. 1969. Diagnostic limitations of metachromasia. *N. Engl. J. Med.* **281**:1128.
9. Scott, J. E. 1960. Aliphatic ammonium salts in the assay of acidic polysaccharides from tissues. *Methods Biochem. Anal.* **8**:145.
10. Scott, J. E., and J. Dorling. 1965. Differential staining of acid glycosaminoglycans (mucopolysaccharides) by Alcian blue in salt solutions. *Histochemie* **5**:221.
11. Danes, B. S., and A. G. Bearn. 1969. Cystic fibrosis of the pancreas, a study in cell culture. *J. Exp. Med.* **129**:775.
12. Meyer, K. 1969. Biochemistry and biology of mucopolysaccharides. *Amer. J. Med.* **47**:664.
13. Bearn, A. G., and B. S. Danes. 1970. Metachromasia elaborated. *N. Engl. J. Med.* **282**:102.
14. Nadler, H. L., M. A. Swae, J. M. Wodnicki, and M. E. O'Flynn. 1969. Cultivated amniotic-fluid cells and fibroblasts derived from families with cystic fibrosis. *Lancet.* **2**:84.
15. Matalon, R., and A. Dorfman. 1968. The accumulation of hyaluronic acid in cultured fibroblasts of the Marfan syndrome. *Biochem. Biophys. Res. Commun.* **32**:150.
16. Matalon, R., and A. Dorfman. 1968. Acid mucopolysaccharides in cultured fibroblasts of cystic fibrosis of the pancreas. *Biochem. Biophys. Res. Commun.* **33**:954.
17. Danes, B. S., and A. G. Bearn. 1969. Cystic fibrosis, distribution of mucopolysaccharides in fibroblast cultures. *Biochem. Biophys. Res. Commun.* **36**:919.
18. Padday, J. F. 1970. Metachromasy of dyes in solution. Proceedings NATO Meeting. St. Margherita, Italy. E. A. Balazs, Editor. Academic Press, London. **2**:1007.