

Immunoscintigraphy using a technetium-99m labelled monoclonal anti-CEA antibody in the follow-up of colorectal cancer and other tumours producing CEA

A. Hertel¹, R.P. Baum¹, M. Lorenz², T. Baew-Christow¹, A. Encke² & G. Hör¹

Departments of ¹Nuclear Medicine and ²Surgery, Johann Wolfgang Goethe University Medical Center, D-6000 Frankfurt/Main 70, FRG.

Summary Using the intact monoclonal IgG₁ anti-CEA antibody BW 431/26 (Behringwerke Marburg, FRG) labelled with ^{99m}Tc by a new labelling procedure (Schwarz method), 72 patients suspected of tumour recurrences (colorectal cancer, *n* = 59) and with rising serum carcinoembryonic antigen (CEA) levels were studied. Sixty-nine of 72 studies had a positive result by immunoscintigraphy of which 52 have since been proven histologically/clinically. In six patients only immunoscintigraphy revealed a tumour recurrence while all other diagnostic modalities were negative. Of 52 studies 46 were true positive (diagnostic sensitivity 88%). In this series there was one false positive result. About one-third of all patients injected with the antibody developed a human anti-mouse response (HAMA), but no severe side effects were seen even after four applications. For the follow-up of colorectal and other CEA positive adenocarcinomas this ^{99m}Tc-labelled monoclonal antibody seems to be very promising in patients with rising serum CEA, especially if conventional diagnostic imaging procedures remain negative.

Numerous studies have established the important role of immunoscintigraphy in clinical oncology for the follow-up of tumour recurrences (Baum *et al.*, 1988). So far, labelling of antibodies has mainly been performed with iodine-131 or indium-111. The many advantages of technetium-99m (cheap, readily available, reduced radiation dose, better imaging) makes it the ideal radionuclide to be combined with highly specific monoclonal antibodies. The intact anti-CEA antibody BW 431/26 labelled with ^{99m}Tc via activated thiol groups (Schwarz method; Schwarz & Steinsträsser, 1987) was studied for its diagnostic potential in a mixed prospective/retrospective protocol in patients with known or suspected tumour recurrences and rising serum carcinoembryonic antigen (CEA) level (Baum *et al.*, 1989). Forty patients were checked for the development of human anti-mouse antibodies (HAMA) in serial blood measurements up to 207 days post-injection after up to four applications of 2 mg BW 431/26.

Patients and methods

Antibody BW 431/26

Intact IgG₁, affinity constant 10¹⁰ M⁻¹ detects exclusively a protein epitope on cell bound CEA (Bosslet *et al.*, 1988). Two mg antibody was used per injection and showed highly preserved immunoreactivity after labelling (90–95%).

^{99m}Tc labelling

This was carried out as described by Schwarz & Steinsträsser (1987) where activated thiol groups are linked with ^{99m}Tc (1.1 GBq, 30 mCi). Preparation is performed with a standard labelling kit and takes about 10 min. The labelling yield was controlled with TLC using Gelman[®] sheets with ethylmethylketone as the running agent.

Patients

Seventy-two patients underwent 76 studies with BW 431/26; the majority were colorectal cancer patients (*n* = 59). The indications for imaging were either rising serum CEA and suspicion of tumour recurrence or detection/exclusion of

extrahepatic lesions in patients with known liver metastases.

Serum CEA levels ranged from 1.8 to 4925 ng ml⁻¹ (median 44 ng ml⁻¹). Ten patients had levels below 10 ng ml⁻¹.

HAMA assays

Two ELISA assays were used: Enzygnost[®] HAMA micro (Behringwerke Marburg, FRG) measuring HAMA with antibody applied *in vivo* bound on solid phase, and Immustrip[®] (Medac, Hamburg, FRG) for detection of anti-isotypic HAMA. Forty patients were checked for HAMA development with blood samples taken before, 1–2 weeks and 4–6 weeks post-injection and at up to 207 days.

Imaging

Images were acquired with a Sopha SPECT gamma camera (Sopha Medical, Frankfurt, FRG). Single photon emission computed tomography (SPECT) of the abdomen or pelvis was performed 6 h after injection of the antibody (360° rotation, 64 frames, 30 s frame⁻¹, applying the Wiener filter for reconstruction). Planar scans (three anterior and three posterior views) acquiring up to 2000 kcounts were done at 4–8 h and 18–26 h post-injection. Interpretation of the scans was performed blindly by two observers and the results were then compared with radiological or clinical findings.

Results

Positive scintigraphic results for tumour recurrence were found in 69 of 76 studies of which 52 have since been proven histologically/clinically. One finding was true negative, one false positive and six false negative (liver/lung metastases). Statistically, this resulted in a sensitivity of 89% and a specificity of 99% (of examined anatomical regions), this last figure requiring larger prospective studies for confirmation. Of great importance are the results in six patients with elevated serum CEA where all other diagnostic modalities (CT scan, sonography, endoscopy) were negative and only immunoscintigraphy detected the (histologically confirmed) tumour recurrences (Figure 1). Scintigraphic images were of excellent quality. High blood pool activity was seen in early images but this dropped sufficiently in late images. Urinary excretion and faint bowel uptake was regularly observed. Thyroid uptake indicating free ^{99m}Tc was not seen, confirming *in vivo* the excellent quality of the labelling techni-

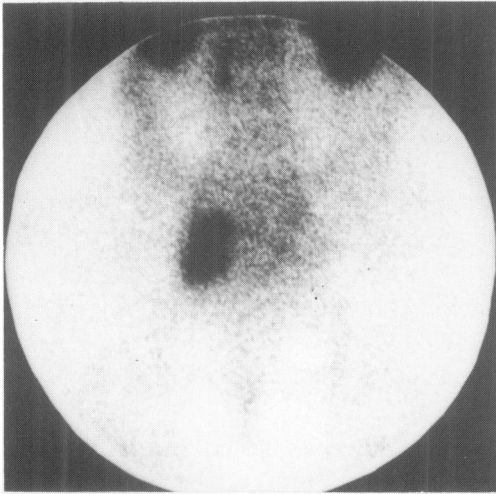


Figure 1 Pelvic recurrence of a sigmoid adenocarcinoma (1 year after primary tumour resection) as shown by immunoscintigraphy (posterior view 24 h after injection of ^{99m}Tc-BW 431/26).

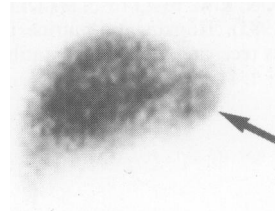


Figure 2 Small metastasis of colon carcinoma in the left liver lobe (CEA, 44 ng ml⁻¹). Second application of antibody BW 431/26. Clear tumour detection despite strongly raised serum HAMA level. Conventional diagnostic procedures were negative (also in case 1), but the recurrences were confirmed by surgical intervention.

que with more than 95% labelling yield found in TLC (and also by HPLC *in vitro* (Schwarz & Steinsträsser, 1987)). Imaging up to 26 h post-injection allowed a good tumour contrast with many recurrences being diagnosed from planar images without the need for computer processing or blood pool subtraction.

No side effects were seen after up to two antibody injections; only one patient (out of over 800 immunoscintigraphic studies so far) showed a mild allergic reaction after the third application of anti-CEA antibody (urticaria of the abdomen) which could be easily treated. Thirteen of 40 patients monitored for HAMA had elevated HAMA titres. In seven cases HAMA was three times above a weak positive control serum and clearly changed biodistribution of antibody was seen in repeated imaging (rapid blood clearance, intense liver/spleen uptake). Three of these seven patients developed titres eight times above a weak positive control serum (strong HAMA serum reaction) after repeated imaging. In all these cases, despite changed biodistribution, clear tumour detection was possible (Figure 2). This could be explained by the development of mainly anti-isotypic HAMA (against the Fc region) still enabling antigen binding as the antigen binding sites are not blocked (Hertel *et al.*, 1989b; Schroff *et al.*, 1985). Ten serial HAMA measurements with 43 samples were tested with both HAMA assays resulting in a good correlation ($r = 0.92$, $P < 0.001$) (Hertel *et al.*, 1989a).

Discussion

This early clinical experience with ^{99m}Tc-labelled monoclonal anti-CEA antibody BW 431/26 allows the following conclusions.

First, a rising serum CEA titre and suspicion of tumour recurrence and exclusion of extrahepatic lesions prior to regional chemotherapy are clear indications for immunoscintigraphy with anti-CEA antibody. Second, the ^{99m}Tc labelling of the antibody is not only safe, fast and cheap but also enables the completion of the study within 24 h with apparently no loss in image quality. Radiation dose can be reduced to a fifth compared with ¹³¹I labelling (Roedler *et al.*, 1987). HAMA development does not seem to play an important role concerning serious side effects (up to three applications in diagnostics). Nevertheless, repeat imaging requires careful HAMA monitoring. The good results of this first experience should be confirmed by larger studies in order to check specificity.

Remaining problems are high blood pool activity in early images obscuring lesions which should be confirmed with additional SPECT. Bowel activity sometimes makes differentiation between tumour uptake and non-specific uptake difficult. SPECT is also important for differentiating tumour lesions in the pelvis from bladder or lymph node metastases from blood vessels.

These results confirm our experience in over 400 studies with ¹³¹I- and ¹¹¹In-labelled monoclonal antibodies in clinical oncology which has shown that immunoscintigraphy has an important role in the follow-up of tumour recurrences where conventional modalities remain negative or equivocal (Baum *et al.*, 1988). The introduction of ^{99m}Tc-labelled monoclonal antibodies seems to be a decisive step towards a more widespread application of immunoscintigraphy and may improve the poor prognosis of colorectal cancer through earlier detection of recurrences and therefore more effective treatment.

We thank Behringwerke Marburg, FRG, Radiochemisches Labor Hoechst, Frankfurt, FRG and Medac Hamburg, FRG for generously providing the antibody and HAMA assays.

References

- BAUM, R.P., LORENZ, M., SENEKOWITSCH, R. & 8 others (1988). Clinical experience in cancer diagnosis with radiolabeled monoclonal antibodies in 200 patients and initial attempts at radioimmunotherapy. In *Radiolabeled Monoclonal Antibodies for Imaging and Therapy. Potential, Problems and Prospects*, Srivastava, S. (ed) p. 613. Pergamon Press: New York.
- BAUM, R.P., HERTEL, A., LORENZ, M., ENCKE, A. & HÖR, G. (1989). Tc-99m labelled anti-CEA monoclonal antibody for tumour immunoscintigraphy: first clinical results. *Nucl. Med. Commun.*, **10**, 345.
- BOSSLET, K., STEINSTRÄSSER, A., SCHWARZ, A. & 4 others (1988). Quantitative considerations supporting the irrelevance of circulating serum CEA for the immunoscintigraphic visualization of CEA expressing carcinomas. *Eur. J. Nucl. Med.*, **14**, 523.
- HERTEL, A., BAUM, R.P., HERRMANN, A. & HÖR, G. (1989a). Frequency of human anti-mouse antibodies after 156 immunoscintigraphic studies and comparison of 2 HAMA assays. *Eur. J. Nucl. Med.*, **3**, C2.
- HERTEL, A., BAUM, R.P., AUERBACH, B., HERRMANN, A. & HÖR, G. (1989b). A simple procedure to detect anti-idiotypic human anti-mouse antibodies (HAMA) after immunoscintigraphy. *Eur. J. Nucl. Med.*, **8**, 445.

ROEDLER, H.D., LEHEL, U. & MOSER, E.A. (1987). Radiation dose to the patient from radioimmunosintigraphy. *Nuklearmedizin*, **10**, 721.

SCHROFF, R.W., FOON, K.A., BEATTY, S.M., OLDHAM, R.K. & MORGAN, Jr, A.C. (1985). Human anti-murine immunoglobulin responses in patients receiving monoclonal antibody therapy. *Cancer Res.*, **45**, 879.

SCHWARZ, A. & STEINSTRÄSSER, A. (1987). A novel approach to Tc-99m labeled monoclonal antibodies. *J. Nucl. Med.*, **28**, 721.