

# The nature and relevance of late lung pathology following localised irradiation of the thorax in mice and rats

J.D. Down

Radiotherapy Research Unit, Institute of Cancer Research, Clifton Avenue, Sutton, Surrey SM2 5PX, UK.

An acute inflammatory pneumonitis followed by chronic pulmonary fibrosis is often described in patients as a consequence of thoracic radiotherapy involving a portion of the lung. The lung is the least tolerant when the entire thorax is included in the radiation beam. In this case a severe life-threatening pneumonitis dominates the clinical picture with doses low enough to rank the lung second to the haemopoietic tissues in susceptibility to systemic radiotherapy (van Dyke *et al.*, 1981; Keane *et al.*, 1981). Our investigations were prompted by the need to establish a dependable experimental representation of radiation lung damage in laboratory animals so that hazardous or beneficial regimes may be adequately predicted.

Two phases of response to whole thoracic irradiation have been well characterised in the CBA mouse. The earlier phase, occurring between 2 and 6 months, was histologically identified as a radiation pneumonitis with oedema and inflammatory hyperplasia of the alveoli. Pleural effusions were an outstanding feature of the late response beyond 6 months. Acute lung damage had largely resolved by this time leaving minimal changes in the lung parenchyma up to 18 months after treatment. Both types of injury were linked with elevated breathing rate, an increase in CT-derived lung density, and mortality (Down & Steel, 1983; Nicholas & Down, 1985).

Considerable attention has focussed on the interdependence of these early and late reactions. Dose modification by anaesthetics, WR2721, slow repair, fractionation and low dose-rate in CBA mice have demonstrated an expression of the late response that is at variance with the preceding radiation pneumonitis (Table I). Travis and co-workers have described dissociation of pulmonary fibrosis from pneumonitis in the same mouse strain (Travis & Down, 1981; Travis *et al.*, 1984; Parkins *et al.*, 1985). These authors mentioned that under some circumstances pleural effusions were observed but they did not give details of the prevalence of this response, nor did they discuss its significance for the assessment of late lung pathology (Travis, 1980; Travis *et al.*, 1980). A steep dose-dependent rise in pleural fluid levels has recently been demonstrated during the late phase. This parameter showed radiation dose-sparing with WR2721 and low dose-rate, comparing well with that obtained from the concurrent assessment of breathing rate and lethality (Down *et al.*, 1984; Down *et al.*, 1985).

Total radiation exposure of the C57B1 thorax produced no evidence of an early pneumonitis. These mice therefore survived this period but were equally intolerant of the later response characterised by pleural effusions (Down & Steel, 1983). More recently we have been able to circumvent both the lethality and pleural effusions by

**Table I** Dissociation of early and late damage in CBA mice irradiated to the whole thorax

<i>Modification</i>	<i>Early damage (2-6 months)</i>	<i>Late damage (&gt;6 months)</i>	<i>Source</i>
Anaesthetic protection	+	-	Down <i>et al.</i> , 1983
WR2721 protection	+	++	Travis <i>et al.</i> , 1984 Down <i>et al.</i> , 1984
'Slow repair'	+	-	Travis & Down, 1981
Fractionation	+	++	Parkins <i>et al.</i> , 1985
Low dose-rate (2 cGy min <sup>-1</sup> )	++	+	Down <i>et al.</i> , 1985

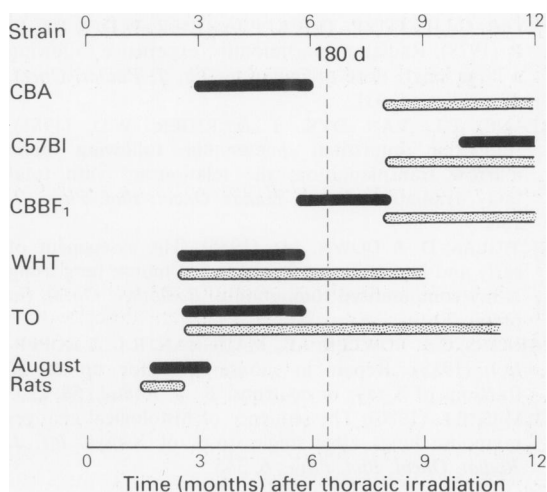
The - sign denotes no modification; + and ++ signs indicates a discordant effect of treatment on one phase of damage relative to the other.

localising the radiation field to include only the right hemithorax. Breathing rate, X-ray CT and histology then revealed a late development of a pneumonitis reaction in the irradiated right C57B1 lung (Down *et al.*, unpublished data). A prolonged latent period was also seen in the CBBF<sub>1</sub> hybrids (CBA♀ × C57B1♂)F<sub>1</sub> but not to the same extent.

The inherent peculiarity of the radiation response in C57B1 mice has encouraged us to extend these studies to two other mouse strains (WHT and TO) and one strain of rat (August). An *early* incidence of pleural effusion was clearly evident in the WHT and TO mice overlapping with the concurrent expression of radiation pneumonitis. Throughout this period the functional and mortality response was variable and the overall radiation tolerance was low. In further contrast to CBAs, the WHT and TO mice that survived to 9 months did exhibit microscopic areas of interstitial and sub-pleural fibrosis. This lesion was, however, an inconsistent finding limited to a sparsely focal nature.

In a study on August rats given 11–20 Gy to the thorax, an even earlier development of the effusive hydrothorax was seen at 8 weeks after 15 or 20 Gy irradiation. Fourteen Gy induced an acute pneumonitis with only slight accumulations of pleural fluid. Other histological changes included medial thickening and sub-endothelial blebbing of the arterioles, a heavy mast cell infiltrate and occasional areas of dense collagen accumulation. A more moderate invasion of mast cells was evident in the injured lungs of TO or WHT mice and was almost absent in CBA or C57B1 mice. The strain-related propensity to a mast cell response is an intriguing observation but its importance has yet to be elucidated.

The timing of pneumonitis and effusive phases for each strain is schematically summarised in Figure 1. An early and isolated incidence of pneumonitis was observed only in CBA mice. Hence they provide a reliable model for studying this phenomenon in humans. The absence of a prominent fibrotic pathology in the lungs of these animals is also in accordance with the clinical counterpart where the radiation doses at which widespread pneumonitis can be acceptably tolerated



**Figure 1** The overall incidence of radiation pneumonitis (■) and pleural effusions (▨) in different animal strains following thoracic irradiation (10–20 Gy). A late development of the pneumonitis reaction in C57B1 mice was recognised only after hemithorax irradiation. The early accumulation of pleural fluid in August rats was prominent only at doses of 15 Gy and above. The standard LD<sub>50</sub> analysis at 180 days will only exclusively measure the preceding incidence of radiation pneumonitis in the CBA mouse strain.

are at or below the lower limits of fibrosis (Fryer *et al.*, 1978; Van Dyke *et al.*, 1981). An independent expression of pleural effusions and the strain-related variation in response time implicates radiation damage to a separate target cell population with perhaps genetically determined variations in cell turnover. Whilst the precise origin of these effusions has yet to be resolved, such a condition is rarely encountered as a side-effect in clinical radiotherapy. Efforts should therefore be made to recognise and exclude the complicating influence of large pleural fluid volumes in experimental animals before a clearer understanding of radiation effects on lung can be envisaged.

## Reference

- DOWN, J.D. & STEEL, G.G. (1983). The expression of early and late damage after thoracic irradiation: a comparison between CBA and C57B1 mice. *Radiat. Res.*, **96**, 603.
- DOWN, J.D., COLLIS, C.H., JEFFERY, P.K. & STEEL, G.G. (1983). The effects of anaesthetics and misonidazole on the development of radiation-induced lung damage in mice. *Int. J. Radiat. Oncol. Biol. Phys.*, **9**, 221.
- DOWN, J.D., LAURENT, G.J., McANULTY, R.J. & STEEL, G.G. (1984). Oxygen dependent protection of radiation lung damage in mice by WR2721. *Int. J. Radiat. Biol.*, **46**, 597.
- DOWN, J.D., EASTON, D.F. & STEEL, G.G. (1985). Repair in the mouse lung during low dose-rate irradiation. *Radiother. Oncol.* (in press).

- FRYER, C.J.H., FITZPATRICK, P.J., RIDER, W.D. & POON, P. (1978). Radiation pneumonitis: experience following a large single dose of radiation. *Int. J. Radiat. Oncol. Biol. Phys.*, **4**, 931.
- KEANE, T.J., VAN DYK, J. & RIDER, W.D. (1981). Idiopathic interstitial pneumonia following bone marrow transplantation: the relationship with total body irradiation. *Int. J. Radiat. Oncol. Biol. Phys.*, **7**, 1365.
- NICHOLAS, D. & DOWN, J.D. (1985). The assessment of early and late radiation injury to the mouse lung using X-ray computerised tomography. *Radiother. Oncol.* (in press).
- PARKINS, C.S., FOWLER, J.F., MAUGHAN, R.L. & ROPER, M.J. (1985). Repair in mouse lung for up to 20 fractions of X-rays or neutrons. *Br. J. Radiol.*, **58**, 225.
- TRAVIS, E.L. (1980). The sequence of histological changes in mouse lungs after single doses of X-rays. *Int. J. Radiat. Oncol. Biol. Phys.*, **6**, 345.
- TRAVIS, E.L., DOWN, J.D., HOLMES, S.J. & HOBSON, B. (1980). Radiation pneumonitis and fibrosis in mouse lung assayed by respiratory frequency and histology. *Radiat. Res.*, **84**, 133.
- TRAVIS, E.L. & DOWN, J.D. (1981). Repair in mouse lung after split doses of X-rays. *Radiat. Res.*, **87**, 166.
- TRAVIS, E.L., PARKINS, C.S., HOLMES, S.J., DOWN, J.D. & FOWLER, J.F. (1984). WR-2721 protection of pneumonitis and fibrosis and mouse lung after single doses of X-rays. *Int. J. Radiat. Oncol. Biol. Phys.*, **10**, 243.
- VAN DYKE, J., KEANE, T.J., KAN, S., RIDER, W.D. & FRYER, C.J.H. (1981). Radiation pneumonitis following large single dose irradiation: a re-evaluation based on absolute dose to lung. *Int. J. Radiat. Oncol. Biol. Phys.*, **7**, 461.