

H. V. INGRAM *ET AL.*: A LASER OPHTHALMOSCOPE FOR RETINAL PHOTOTHERAPY

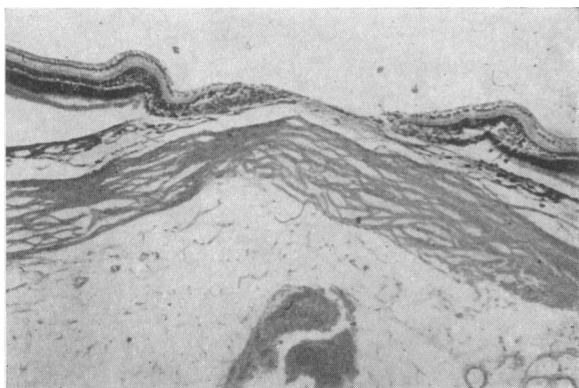


FIG. 7.—Section of a 3-joule lesion, showing extensive disruption of retinal tissue with hole-formation.




FIG. 8.—Oscillograph trace of a laser application lasting 800 microseconds (with a mean power of 1 kilowatt).

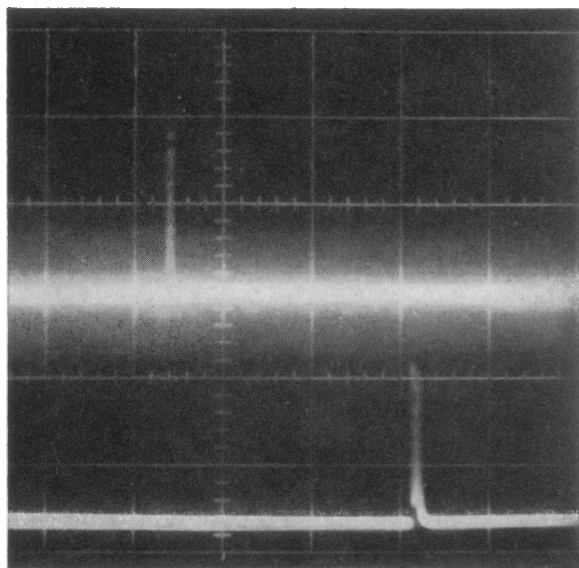


FIG. 9.—Oscillograph trace of a Q-spoiled laser application—a 12-megawatt pulse in 100 nanoseconds (one nanosecond = 1/1,000 of a millionth of a second).

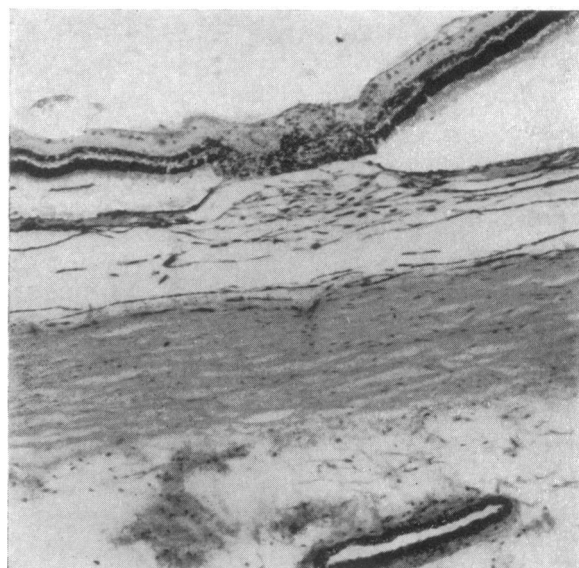


FIG. 10.—Section of a 0.19-joule lesion after 1 week. The diameter of the lesion was 0.5 mm.

G. W. BEVERIDGE AND A. A. H. LAWSON: BULLOUS LESIONS IN ACUTE BARBITURATE INTOXICATION

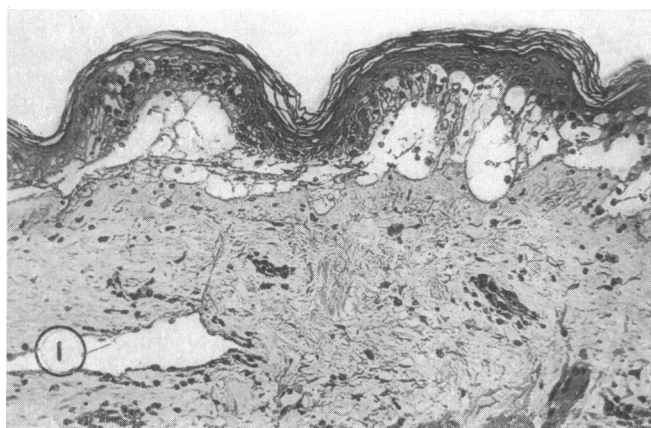


FIG. 1.—Section of an early bulla. (Haemalum and eosin.  $\times 150$ .)

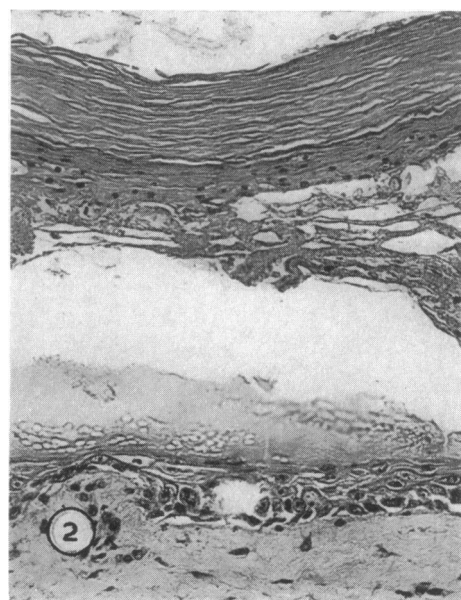


FIG. 2.—Section from margin of an intact bulla. (Haemalum and eosin.  $\times 200$ .)

Of 53 (67%) who had a recorded history of previous mental illness, 43 had had multiple admissions to mental hospitals and 27 had spent an aggregate of over six months in them. Schizophrenia was diagnosed in 59 (78%) cases.

Official records reveal that 30 (40%) of the cases had criminal records. Of these, 27 had committed more than one indictable offence, and 21 had served prison sentences ranging from one sentence in seven cases to two who had served over 11 sentences.

A psychiatric and criminological follow-up for a limited period was made of those who had been discharged or had left hospital. Of the 68 cases "at risk," 21 (31%) had been readmitted to mental hospitals, not as the result of police action. Twenty-eight (41%) had committed further offences, not necessarily in the same category as the one discussed. The disposal of the subsequent offences was varied and included readmission to mental hospital and prison sentences.

The group differences between those admitted as either prosecuted or unprosecuted cases are briefly stated.

Comment on the adverse social sequelae of certain aspects of the present system of dealing with mentally abnormal offenders is made.

I would like to express my gratitude to the Warden and Fellows—particularly Dr. Nigel Walker—of Nuffield College, Oxford, for the facilities provided by them during my tenure of the Gwyllim Gibbon Research Fellowship. I am deeply indebted to the Home Office Research Unit, and the Criminal Records Office, and to the Governors, Medical Officers, and Officers of H.M. Prisons for their invaluable co-operation. My thanks are due, too, to the many hospitals who answered my inquiries. My special thanks to Miss E. Briggs, of Horton Hospital, for her unstinting help, and to Dr. J. H. Watkin, of the same hospital, for permission to publish this paper.

#### REFERENCES

- Prisons and Borstals*, Report on the work of the Prison Department in the year 1963 (1963), p. 57. H.M.S.O., London. Cmnd. 2381.  
Rollin, H. R. (1963). *Brit. med. j.*, 1, 786.

## Occurrence of Bullous Lesions in Acute Barbiturate Intoxication

G. W. BEVERIDGE,\* M.B., M.R.C.P.ED.; A. A. H. LAWSON,† M.B., M.R.C.P.ED.

[WITH SPECIAL PLATE]

*Brit. med. j.*, 1965, 1, 835-837

In spite of the fact that the cutaneous manifestations of sensitivity to barbiturates are extensively documented, the occurrence of bullous lesions in patients suffering from acute barbiturate intoxication appears to have received little recognition. The following study was undertaken in order to determine the incidence and possible specificity of these lesions.

### Patients and Methods

During the period from 1 October 1963 to 30 June 1964 there were admitted to the regional poisoning treatment centre in the Royal Infirmary of Edinburgh 290 patients with barbiturate overdosage and 69 with overdosage from other sedative drugs such as phenothiazine derivatives and non-barbiturate hypnotics. In the patients who were thought to be suffering from barbiturate intoxication, and in all those with impairment of consciousness and in whom the nature of the ingested poison was obscure, the diagnosis was confirmed by analysis of serum for barbiturate (Wright and Johns, 1953). During the initial assessment all the cases were carefully examined for cutaneous lesions. The level of consciousness was recorded, using a system of grading similar to that used by Reed *et al.* (1952); and in all cases the regime of therapy adopted was similar to that advocated in the treatment of barbiturate poisoning by Nilsson (1951) and by Plum and Swanson (1957).

Where there was evidence of respiratory insufficiency assessment was made by an anaesthetist; an endotracheal tube was inserted and where necessary the patient was maintained on a respirator. Patients requiring these measures are recorded in Table II as suffering from severe respiratory insufficiency. Patients were regarded as hypotensive when the systolic blood-

pressure was less than 100 mm. Hg in those over the age of 55 and less than 90 mm. Hg in the others. When hypotension was present the blood-pressure was maintained just above these levels by raising the foot of the bed, and in severe poisonings by intramuscular or continuous intravenous infusions of metaraminol (Aramine). All patients were maintained in a state of adequate hydration. The pulse, blood-pressure, and respiratory state were recorded at half-hourly intervals.

Every two hours the patients were turned by the nursing staff and examined for the development of any skin lesions, and in particular blister formation. If any were noted these were recorded and confirmed by a doctor. Each patient was examined carefully by a doctor at eight-hourly intervals, and when skin lesions were noted these were also assessed by one of us (G. W. B.). The time of appearance, nature, and site of all cutaneous lesions were recorded.

In 15 patients who developed bullae the following additional investigations were carried out. Liver and renal function were assessed by the conventional tests. When the patients had recovered from the effects of poisoning a challenging dose of the barbiturate ingested was given orally in the normal therapeutic dose. Patch tests were applied to the skin of the forearm, using phenobarbitone, amylobarbitone, pentobarbitone as a 10% aqueous solution of each drug, and a piece of capsule from Nembutal (pentobarbitone sodium).

### Results

During the course of the investigation definite bullous lesions were noted in 19 (6.5%) out of the 290 patients suffering from barbiturate intoxication (Table I). With one exception these lesions had made their appearance within 24 hours of ingestion of the drug. No blisters developed in the group of patients who had ingested other sedative drugs.

\* Senior Registrar, Department of Dermatology, Royal Infirmary, Edinburgh.

† Senior House Officer, Regional Poisoning Treatment Centre, Royal Infirmary, Edinburgh.

TABLE I.—*Features in Cases Developing Bullae*

Case No.	Sex and Age	Drugs Ingested	Serum Level (mg./100 ml.)	Time Until Admission (hr.)	Duration of Unconsciousness (hr.)	Distribution of Bullous Lesions
1	F 75	Sodium amyltal (amylobarbitone sodium) + alcohol	3.9	17	53	(R) Greater trochanter. (R) Lateral aspect of knee. (R) Lateral malleolus
2	M 27	Nembutal (pentobarbitone sodium) + alcohol	2.8	39	87	Both medial aspects of knees. Both lateral malleoli. 2nd, 3rd, and 4th interdigital clefts both hands
3	F 21	Tuinal (quinabarbitone sodium + amylobarbitone sodium)	7.8	9	18	(L) Forearm. Medial aspects both knees. Both medial malleoli. (L) Iliac crest
4	M 42	Sodium amyltal	4.3	9	36	(R) Lateral aspect knee. (L) Medial aspect knee. (R) Lateral malleolus. (L) Medial malleolus
5	M 35	Nembutal + alcohol	4.2	17½	75	(L) Parietal region. (R) Deltoid. (L) Lateral malleolus. Medial aspects both knees
6	M 23	Barbiturate. Salicylate	6	12	36	(L) Dorsum foot. Both greater trochanters. Medial aspects both knees
7	M 15	Barbiturate	4.9	10½	13	(L) Greater trochanter. (L) Lateral aspect knee. (R) Dorsum of foot
8	M 56	Nembutal	5	17	32	(L) Thumb. (R) Index finger. (R) Lateral aspect of thigh. (R) Lateral malleolus
9	F 42	"	2.2	2	28	(L) Scapula. Both iliac crests. Medial aspect both knees
10	F 38	Seconal (quinabarbitone sodium elixir) + mepromate	4.9	17	36	(L) Anterior neck (necklace distribution). Medial aspect both knees. Medial malleoli
11	M 65	Nembutal	2.5	5½	18	Interdigital clefts of fingers, both hands. (R) Greater trochanter. Great toes both feet. (L) Scapula
12	F 89	Tuinal	2.0	14½	17½	(L) Greater trochanter. (L) Heel. (R) Dorsum foot
13	M 70	Nembutal	1	11½	13	(R) Anterior thigh
14	F 73	Carbrital (pentobarbitone sodium + carbromal)	5	12½	36	(L) Scapula. (L) Gluteal region. (R) Heel
15	F 51	Nembutal	0.8	18	20	(R) Middle finger. (R) Thigh. Medial aspects both knees
16	M 28	Seconal	1.7	6½	24½	(L) Posterior axillary fold
17	M 26	Tuinal + salicylate	2.0	12	13	(L) Dorsum great toe
18	F 35	Cyclobarbitone + sodium amyltal	5.2	13½	33½	(R) Lateral and medial aspects knee. (L) Medial aspect knee. (L) Great toe. (R) Dorsum foot. (R) Greater trochanter
19	F 34	Phenobarbitone	2.2	12	18	(R) Medial and lateral aspects knee. (L) Medial aspect knee. (R) Lateral part foot

The development of lesions in patients suffering from barbiturate intoxication was characteristic. In some cases frank bullae were present on admission, but where it was possible to observe the lesions developing the first indication was a patch of faint erythema which became slightly raised and had a well-defined margin. In a few instances the lesions did not progress to bulla formation and receded in a few hours, and since these lesions may not have been specific they are not recorded in Table I. Clinically the bullae which developed had a moderately thick wall, were clearly defined, and around the margin there was slight erythema but no evidence of a marked tissue reaction. The bullae were tense and remained localized on pressure. Fig. A shows a typical group of bullae. When the roofs of the bullae were opened and the pale-yellow fibrinous fluid had been removed this left a raw erythematous surface with areas of punctate erythema presumably corresponding to the dermal papillae. The appearance was comparable to that seen in a superficial burn, and the lesions healed in a similar way without scarring except where secondary infection occurred. In three cases deep ulceration resulted in scar formation which in one case required treatment by plastic surgery.

All the lesions developed in sites where pressure could have occurred, but not necessarily over sites of maximum pressure; and in Table I it will be noted that the lesions were relatively infrequent over the maximum pressure areas in the supine patient—namely, the back, gluteal regions, sacrum, and greater trochanters. Four patients had large bullous lesions occurring on the dorsum and contiguous surfaces of fingers (Cases 2,

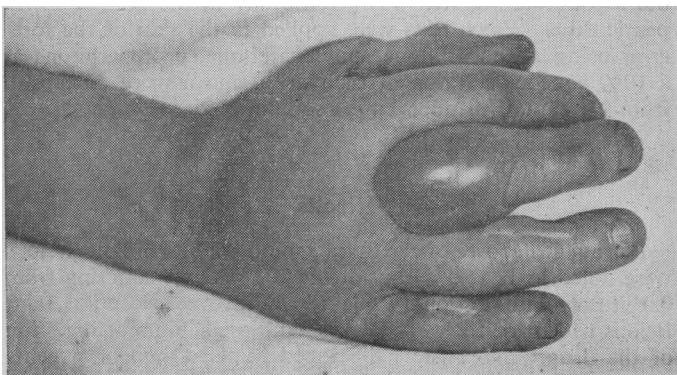


FIG. A.—A typical group of bullae.

8, 11, and 15), two patients had lesions on the dorsum of toes (Cases 17 and 18), and in one patient small bullae appeared on the neck (Case 10), where very light pressure had been present while a tape supporting an endotracheal tube was in contact with the skin. In 18 of the patients bullae developed after admission to hospital, and these appeared while the patient was undergoing the routine care of the skin used in the poisoning treatment centre.

The level of consciousness of the 290 patients suffering from barbiturate intoxication and the 69 patients who had ingested other sedative drugs, and the other complications—namely, hypotension and respiratory insufficiency—are recorded in Table II. It will be seen that all the patients who developed

TABLE II

Groups	No. of Cases	Minimum Level of Consciousness			Hypotension	Respiratory Insufficiency
		0-I	II	III		
Barbiturate overdosage without bullae	271	114	120	37	40	12
Barbiturate overdosage with bullae	19	—	8	11	5	4
Overdosage with other sedative drugs	69	55	12	2	3	3

bullae were at one stage deeply unconscious to the level of grade II or III. There are, however, comparable patients in the other groups from the point of view of depth of unconsciousness, hypotension requiring treatment with metaraminol, and respiratory insufficiency, who did not develop bullae.

In the 15 cases of barbiturate intoxication who developed bullae and were further investigated, liver-function tests were within normal limits and the blood urea was within the normal range except in two cases. One developed acute renal failure and required haemodialysis (Case 5), but subsequent investigation did not suggest any pre-existing renal disease, and in another (Case 17) the blood urea was transiently elevated. A detailed history revealed no previous cutaneous sensitivity to drugs; one patient suffered from chronic psoriasis (Case 8) and one from mild eczema of the hands (Case 1). Before leaving hospital the 15 patients were all given a challenging dose of the barbiturate they had ingested in the normal hypnotic dose and no evidence of sensitivity was noted. No evidence of a cutaneous reaction to the patch tests was observed after 48 hours.

### Histopathology

In four cases a biopsy was obtained from the margin of an intact bullous lesion, and in one case an entire early bulla was removed. The major findings in all the histological sections examined were comparable. The bulla appeared to have formed as a result of massive epidermal disintegration and to a less extent the subepidermal collection of fluid (Special Plate, Figs. 1 and 2). The roof of the bulla consists of stratum corneum and epidermal cells which show massive necrosis, the cytoplasm of the cells has become intensely eosinophilic, and there is either loss of nuclear staining or the nuclei have become pyknotic. In the section of an early bulla there is little evidence of prickle cells (Fig. 1), and in the sections from more advanced lesions all semblance of cellular structure has disappeared (Fig. 2). The bulla fluid is acellular except for some fragments of nuclear material and very occasional polymorphs. Apart from slight oedema in the papillary layer of the dermis, and occasional polymorphs and lymphocytes around some of the small vessels in the upper dermis, there is no evidence of a marked inflammatory reaction. In some of the older bullae which were examined there is a thin layer of cells in the dermal base of the cavity; these, however, were only in evidence at the periphery and probably represented epidermal regeneration (Fig. 2).

### Discussion

Bullous lesions have been noted in 6.5% of a series of patients who were suffering from moderate or severe acute barbiturate intoxication. The lesions do not appear to be dependent upon depth of coma or associated complications such as hypotension and respiratory insufficiency (Table II). Holten (1952) described very similar lesions in a series of 501 patients in which he recorded a 4% incidence of skin lesions; 13 of his 20 cases which developed the lesions did so within 48 hours of ingestion of barbiturate, and the distribution and development of lesions were very similar to those recorded here. He concluded that the lesions were specific for acute barbiturate poisoning and pointed out their diagnostic significance. This valuable observation apparently received little prominence, and Sørensen (1963) criticized this view, and produced evidence from which he concluded that the skin manifestations were not specific and could occur with other ingested poisons and also in carbon-monoxide poisoning. He quotes nine cases which were shown to have taken no barbiturate, but gives no indication of the time interval during which the skin lesions developed or their exact nature, and in particular there is no mention of discrete bulla formation. Sørensen expresses the view that the lesions are solely the result of pressure.

From the clinical and histological observations recorded in this paper it would seem that, while light pressure may in some instances be a localizing factor, the main reason for the development of the bullae is the primary toxic action of the barbiturate on the epidermis, producing a massive coagulative neurosis of this tissue in certain limited areas of the body surface, there being no uniform or typical localization for development of this process. From this standpoint the mechanism of development of the lesions may to some extent be comparable to that of the Nikolsky sign in pemphigus and dermatitis herpetiformis or the formation of bullae following minor friction in epidermolysis bullosa. In some areas the skin may be more susceptible to the toxic effect of the barbiturate, and it may be that the development of the bullae is related to the development of fixed drug eruptions, for toxic epidermolysis has recently been reported at the site of a former fixed drug eruption (Browne and Ridge, 1961). Another

possible explanation is that local factors result in an increased concentration of barbiturate, and it has been suggested that this is the result of the poor peripheral circulation which occurs in barbiturate intoxication (Soltz-Szots and Sluga, 1963). These authors report histological changes in one case comparable to the changes seen in this investigation, except that there was evidence of thrombosis in small vessels and extravasation of red cells. The latter thrombotic changes were not noted in this investigation; thus at present we feel that further evidence is required on the probable method of localization of the bullae.

Since the bullae occurred in a small proportion of patients the possibility of the lesions being the result of drug sensitivity was considered. From the history and investigations carried out no evidence of this was obtained, nor did screening tests for impairment of liver or renal function demonstrate any consistent abnormality. Furthermore, the histology also does not support the possibility of the lesions being due to sensitivity, as there is no evidence of a marked inflammatory reaction in the upper dermis such as is noted in bullous erythema multiforme. The bullae differ from those of dermatitis herpetiformis in that there is extensive necrosis of the epidermal roof and the fluid is almost acellular and contains no eosinophils. Pemphigus is excluded by the massive destruction of epidermal cells and the absence of any acantholytic cells. On the basis of the histopathological changes the lesions are comparable to those described by Lyell (1956), who noted in his cases of toxic epidermal necrolysis that the major damage was confined to the epidermis which had undergone massive necrosis, and that there was no marked inflammatory change in the dermis. Lyell thought that in this syndrome the epidermal damage was probably the result of a circulating toxin. In the cases which we have observed, although the lesions have differed clinically from Lyell's disease in that they have shown no tendency to become generalized, the histopathology is comparable, and it seems reasonable to attribute the lesions to the direct toxic effects of the barbiturate.

### Summary and Conclusions

The occurrence of characteristic bullous lesions in 19 (6.5%) out of 290 patients suffering from acute barbiturate intoxication is reported. The evidence that this appears to be a direct toxic effect of the drug is presented.

The histopathology of the bullous lesions, which is comparable with toxic epidermal necrolysis, is described.

We believe that, clinically, these lesions are sufficiently characteristic to suggest strongly the possibility of acute barbiturate poisoning when the clinician is presented with an unconscious patient.

We wish to thank Professor G. H. Percival and Dr. H. J. S. Matthew for their encouragement and helpful criticism in the conduct of this study. We also wish to acknowledge the help of Mr. T. C. Dodds, department of medical photography, University of Edinburgh, in preparing the photograph and photomicrographs.

### REFERENCES

- Browne, S. G., and Ridge, E. (1961). *Brit. med. J.*, **1**, 550.  
 Holten, C. (1952). *Acta dermat-venereol. (Stockh.)*, **32**, Suppl. No. 29, p. 162.  
 Lyell, A. (1956). *Brit. J. Derm.*, **68**, 355.  
 Nilsson, E. (1951). *Acta med. scand.*, **139**, Suppl. No. 253.  
 Plum, F., and Swanson, A. G. (1957). *J. Amer. med. Ass.*, **163**, 827.  
 Reed, C. E., Driggs, M. F., and Foote, C. C. (1952). *Ann. intern. Med.*, **37**, 290.  
 Soltz-Szots, J., and Sluga, W. (1963). *Z. Haut-u. Geschl.-Kr.*, **35**, 299.  
 Sørensen, B. F. (1963). *Dan. med. Bull.*, **10**, 130.  
 Wright, J. T., and Johns, R. G. S. (1953). *J. clin. Path.*, **6**, 78.