

Putaminal petechial haemorrhage as the cause of chorea: a neuroimaging study

Ming-Hong Chang, Hung-Ting Chiang, Ping-Hong Lai, Chern-Guey Sy, Susan Shin-Jung Lee, Yeung-Yuk Lo

Abstract

Objectives—A hyperintense putamen on either CT or MRI as a finding associated with chorea has occasionally been described and is almost always associated with non-ketotic hyperglycaemia. The cause of the hyperintensity of the striatum in these images is still controversial. Some reports have found that calcification was responsible whereas others have advocated petechial haemorrhage as the cause. The purpose of this study was to determine whether hyperintense striata are caused by petechial haemorrhage or calcification, with the sequential imaging changes.

Subjects and methods—Five patients presenting with an acute onset of either hemichorea or generalised chorea and showed either unilateral or bilateral hyperdense striatum on the initial CT were assessed. Neuroimaging studies including sequential CT and MRI examinations and detailed biochemical tests were performed.

Results—Three patients had pronounced hyperglycaemia and the other two patients had no biochemical abnormalities. In all patients, the first CT scans, performed within two weeks of the onset of chorea, showed a high density over the striatum contralateral to the chorea, which diminished or disappeared two months later. T1 weighted imaging disclosed hypersignal intensities over the striatum contralateral to the chorea on admission which diminished two months later. T2 weighted imaging at two months showed hyposignal intensity changes corresponding to the area with hypersignal changes on T1 weighted images, implying haemosiderin deposition.

Conclusion—Based on the evolution of clinical manifestations and the findings of neuroimaging, putaminal petechial haemorrhage might be a new entity causing either hemichorea or generalised chorea.

dysfunction of the basal ganglia, particularly of the striatum, is generally assumed to be responsible.¹⁻³ Various structural lesions in the contralateral subthalamic nucleus and striatum seem to play a critical part in the development of chorea,¹⁻³ with acute vascular accident being the most common pathological process.³ Since the advent of CT, there have been occasional reports of chorea development secondary to striatal pathology, which is commonly seen as a lesion of increased density.⁴⁻⁹ There is much controversy regarding the cause of the striatal hyperdensity on CT; some advocate calcification,^{4,5} and others have reported petechial haemorrhage to be the cause.^{8,9} It has also been questioned whether non-ketotic hyperglycaemia is the only systemic disease associated with a hyperdense putamen manifesting as chorea.^{8,9} Previous reports of imaging findings were only single case reports. We collected five patients with chorea whose CT disclosed a hyperdense striatum. A series of sequential neuroimaging examinations, including CT and MRI, were performed within two weeks of the onset of chorea and two months later. Based on these imaging studies, we attempted to differentiate whether the hyperdensity of the striatum on CT was caused by calcification or haemorrhage.

Materials and methods

Within a period of two years, we encountered five choreic patients (four men, one woman) whose brain CT on admission showed a hyperdensity over the basal ganglion contralateral to the choreic side. Their age ranged from 60 to 73 years. Those who clearly had underlying diseases causing the chorea, such as hyperthyroidism, hereditary diseases, or drugs history, were excluded. Biochemical tests, including HbA1C and osmolality, and coagulation function were obtained. Brain CT and MRI were performed within two weeks after the onset of chorea and repeated two months later.

Brain CT was performed with a Somatom HiQ scanner (Siemens) in the axial plane with an 8 mm thickness without contrast enhancement. Images were obtained on admission and two months later.

Brain MRI was performed on a 1.5 T superconducting system (Sigma; GE Medical Systems). Spin echo T1 weighted images with 600/20/2 (repetition time/echo time/excitations) and T2 weighted images with 2500/90/1 were obtained in the axial plane. Images were 5 mm thick with a 2.5 mm gap between sections. The acquisition matrix was

Section of Neurology,
Veterans' General
Hospital, Kaohsiung
and
Department of
Neurology at National
Yang-Ming University
M-H Chang
Y-Y Lo

Department of
Medicine
H-T Chiang
S S-J Lee

Department of
Radiology, Veterans'
General Hospital,
Kaohsiung, Taiwan
P-H Lai
C-G Sy

Correspondence to: Dr
Ming-Hong Chang, Section
of Neurology, Veterans'
General Hospital-Kaohsiung,
No 386, Ta-Chung 1st Road,
Kaohsiung, Taiwan.

Received 11 November 1996
and in revised form 24
March 1997
Accepted 27 March 1997

(*J Neurol Neurosurg Psychiatry* 1997;63:300-303)

Keywords: petechial haemorrhage, striatum, CT, MRI

Chorea may be the manifestation of a wide variety of degenerative, vascular, metabolic, or toxic disorders involving the CNS, in which

Table 1 Summary of clinical data

Patient No	Age/sex	Limbs with chorea	Concentrations			Use of haloperidol
			Sugar at admission	Serum osmolality	HbA1C	
1	71/M	RUl, LUl, LLol	102	291	5.1	Yes
2	68/M	RUl	94	287	5.6	No
3	73/M	LUl, LLl, RUl, facial	413	315	10.7	Yes
4	60/F	RUl, RLol	364	308	11.3	No
5	68/M	RUl	476	317	10.6	No

R = right; L = left; U = upper; Lo = lower; l = limb.

256 × 256, with a 20 cm field of view. Examination of MRI was done immediately after the first CT study and both MRI and CT were performed two months later.

All imaging studies were reviewed by the same two neuroradiologists who were unaware of the patient's clinical status and were experienced in interpreting CT and MRI. If there was a disagreement, a consensus of opinion was reached through discussion.

Results

CLINICAL DATA

Three patients (patients 2, 4, and 5) had hemichorea and patients 1 and 3 had generalised chorea. Table 1 shows the limbs or muscles involved. Patients 3, 4, and 5 had pronounced hyperglycaemia, increased HbA1C concentration and serum osmolality. The choreic movement of patients 4 and 5 subsided within one week after fluid supply and correction of the metabolic derangements. Patients 1 and 3 had violent hyperkinesia and received 1 mg haloperidol twice a day for five to seven days. In all patients, the chorea diminished gradually and subsided completely within three weeks. Patients 1 and 2 did not have any recognisable systemic disorders (table 1).

NEUROIMAGING FINDINGS

Brain CT of patients 1 and 3 showed bilateral, faintly increased densities over the putamen or caudate nucleus. Patients 2, 4, and 5 had similar hyperdense lesions over the striatum contralateral to the chorea, which had diminished or disappeared on follow up examination. T1 weighted imaging of these lesions initially disclosed a hypersignal intensity, which corresponded to the high density lesions found on CT, over the striatum contralateral to the chorea, which also diminished two months later (figure). T2 weighted imaging showed slightly increased or isodense changes in the striatum at the first examination. The increased hyposignal intensity observed on T2 weighted images on the follow up examination corresponded to the area with hypersignal intensity on T1 weighted imaging (table 2).

Discussion

Jones *et al* first described a patient with hypertensive putaminal haemorrhage presenting with hemichorea.⁶ Brain CT showed a dense and homogeneous haematoma, a common finding in hypertensive haemorrhages. Subsequently, Sanfield *et al*³ and Inbody *et al*⁷ described two choreic patients, with and with-

out diabetes, whose CT showed unilateral or bilateral faint hyperdensity over the putamen. They concluded that these lesions were best ascribed to calcification. Altafullah *et al*⁸ and Nakagawa *et al*⁹ also reported two patients with non-ketotic hyperglycaemic chorea whose CTs disclosed faintly increased densities over the contralateral basal ganglion. Brain MRI of these patients suggested that the hypersignal intensity was the result of petechial haemorrhage. Because the chorea subsided either spontaneously or after medication, necropsy is not readily available. Therefore, the issue of whether the faintly increased densities over the striatum should be ascribed to petechial haemorrhage or calcification remains unsettled. The CT findings in our five patients were similar to those described by Sanfield *et al*³ and Nakagawa *et al*.⁹ Brain MRI was obtained within two weeks after the onset of chorea. The T1 weighted images clearly showed a hypersignal intensity over the basal ganglia which may be explained by the presence of methaemoglobin¹⁰ resulting from petechial haemorrhages. Subsequent resolution of this hypersignal intensity on T1 weighted images with increased hyposignal intensity on T2 weighted images over the basal ganglia, and the continual diminution or disappearance of high densities on CT imaging on follow up, all suggest that the process may be due to the evolution of petechial haemorrhage with haemosiderin deposition.¹⁰

The differential diagnosis of a hyperdense putamen on CT includes calcification and petechial haemorrhage.¹¹ A definite distinction can be made by noting the time course of the clinical and signal changes and by direct measurement of tissue density in Hounsfield units. Although it is not possible to entirely exclude calcification based on imaging abnormalities alone, such rapid resolution of the hyperdense lesions over a few months is certainly more likely to be caused by haemorrhage than calcification.^{11 12} In addition, the clinical presentation of our patients with acute onset of chorea also favoured haemorrhage rather than a chronic process such as calcification as the cause of image hyperdensity. Lastly, the tissue density values in the hyperdense putamen were in the range of 40 to 50 Hounsfield units, a finding similar to that for petechial haemorrhage, whereas measurement of the calcified choroid plexus and pineal glands in the same patients gave values of around 80 Hounsfield units.¹¹ All the above findings supported petechial haemorrhage as a cause of the hyperdense putamen. Therefore, we propose that putaminal petechial haemorrhage is a new entity, that may be an uncommon but not rare, causing chorea.

Altafullah *et al*⁸ and Nakagawa *et al*⁹ first reported two patients with non-ketotic hyperglycaemic chorea whose neuroimages had faintly increased densities over the contralateral basal ganglion, suggesting petechial haemorrhage. Therefore, they proposed that non-ketotic hyperglycaemia complicated by multiple putaminal petechial haemorrhage was the cause of hemichorea. Since then, it has been generally accepted that non-ketotic hypergly-

Table 2 Summarised results of neuroimaging findings

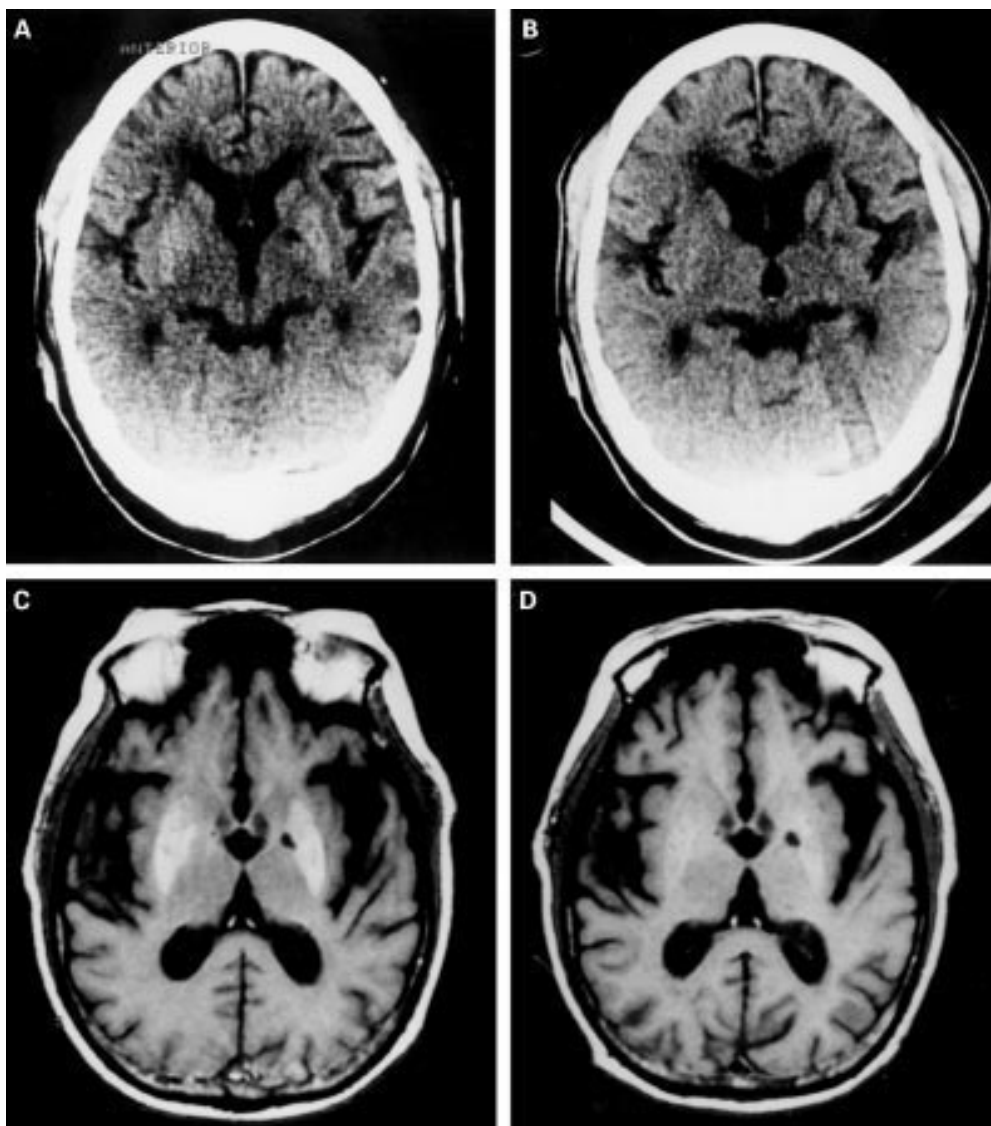
Patient No	Scan	CT findings	MRI findings	
			T1	T2
1	(1)	↑↑Bil P, C	↑↑Bil P, C	Iso
	(2)	↑Bil C	↑Bil P, C	↓Bil P
2	(1)	↑↑L P	↑↑L P	Iso
	(2)	Iso	↑L P	↓L P
3	(1)	↑↑Bil P, C	↑↑Bil P, C	Iso
	(2)	↑Bil P, C	↑Bil P, C	↓Bil P, C
4	(1)	↑↑L P	↑↑L P	Iso
	(2)	Iso	↑L P	Iso
5	(1)	↑↑L P	↑↑L P	Iso
	(2)	Iso	Iso	↓L P

↑↑ = moderately, ↑ = mildly increased signal intensity or density; ↓↓ = moderately, ↓ = mildly decreased signal intensity or density; L = left; R = right; Bil = bilateral; P = putamen; C = head of caudate nucleus; Iso = normal density or signal intensity.

caemia is the sole cause of putaminal petechial haemorrhages manifesting with chorea. However, our series of patients included two with non-diabetic chorea whose brain CTs indicated the presence of petechial haemorrhage. Furthermore, a series of examinations in these

patients excluded coagulation diseases or other systemic disorders, which can contribute to the haemorrhage. Therefore, our findings in these patients showed that non-ketotic hyperglycaemia is not the only possible cause of petechial haemorrhage over the basal ganglia in patients presenting with chorea.

The clinical range of putaminal haemorrhage is one of great variability, directly reflecting the size of the haematoma and its pattern of extension. The classic manifestations of massive putaminal haemorrhage are relatively abrupt onset of unilateral motor and sensory deficits with accompanying visual abnormalities and change of consciousness.¹³ Since the advent of CT, precise determination of the size and location of hyperdense and homogeneous haematoma is possible. Recently, a syndrome of the small haematoma have been reported, and chorea is one of its clinical manifestations.¹³ Although the haematoma is small, it is very dense and homogenous and not restricted to the putamen and head of the cau-



(A) The unenhanced CTs of patient 1 on admission show faint hyperdense lesions over the bilateral striatum. (B) T1 weighted image (TE/TR 20/600) shows hypersignal intensities over the bilateral putamen and head of caudate nucleus. (C) (D) Follow up examination shows diminution of the high densities and signal intensities over bilateral striatum.

date nucleus. These findings are different from the imaging studies of our patients, which showed sharply defined lesions of faintly increased density without a mass effect, which were located strictly within the striatum. These findings are also very different from those of common hypertensive intracranial haemorrhages. To date, our series is the largest to describe the CT and MRI findings of petechial haemorrhage in patients with or without diabetes, manifesting with chorea.

Most patients with chorea showed partial or complete resolution of symptoms after treatment with neuroleptic drugs, but this treatment usually had to be continued for a long period. However, when the cause of the chorea was a stroke, the chorea usually remitted spontaneously.³ Chorea associated with non-ketotic hyperglycaemic chorea has also been reported to show dramatic improvement after correction of hyperglycaemia.¹⁴ All of our patients had a good prognosis and the hyperkinesia disappeared within three weeks, implying that chorea secondary to putaminal petechial haemorrhage is a benign and limited disease.

Non-ketotic hyperglycaemia has occasionally been associated with various neurological abnormalities¹⁵⁻¹⁶ in which choreoathetosis is a rare manifestation.¹⁷⁻¹⁸ Recently, we¹⁹ and Lin *et al.*¹⁴ described several patients who presented with non-ketotic hyperglycaemic chorea. Neuroimaging studies including CT and MRI do not show the changes we have found. Therefore, we can clearly separate non-ketotic hyperglycaemic choreic patients into two groups, one with petechial haemorrhage and the other without definite structural lesions. At present, we are unable to predict which patients will develop putaminal haemorrhage. This implies that a critical unidentified factor plays an

important part in the production of this pattern of haemorrhage and further investigation is required to determine this factor.

- 1 Martin TP, Akock NS. Hemichorea associated with a lesion of corpus luyisii. *Brain* 1934;57:504-5.
- 2 Hyland H, Foroman DM. Prognosis in hemiballism. *Neurology* 1957;7:381-31.
- 3 Dewey RB, Jankovic J. Hemiballism-hemichorea: clinical and pharmacological findings in 21 patients. *Arch Neurol* 1989;46:862-7.
- 4 Sanfield JA, Finkel J, Lewis S, Rosen SG. Alternating choreoathetosis associated with uncontrolled diabetes mellitus and basal ganglia calcification. *Diabetes Care* 1986;9:100-1.
- 5 Inbody S, Jankovic J. Hyperkinetic mutism: bilateral ballism and basal ganglia calcification. *Neurology* 1986;36:825-7.
- 6 Jones HR, Baker RA, Kott S. Hypertensive putaminal hemorrhage presenting with hemichorea. *Stroke* 1985;16:130-1.
- 7 Srinivas K, Rao VM, Subbulakshmi N, Bhaskaran J. Hemiballism after striatal hemorrhage. *Neurology* 1987;37:1428-9.
- 8 Altafullah I, Pascual-Leone A, Duvall K, Anderson DC, Taylor S. Putaminal hemorrhage accompanied by hemichorea-hemiballism. *Stroke* 1990;21:1093-4.
- 9 Nakagawa T, Mitani K, Nagura H, Bando M, Yamanouchi H. Chorea-ballism associated with nonketotic hyperglycemia and presenting with bilateral hyperintensity of the putamen on MR T1-weighted images--a case report. *Rinsho Shinkeigaku* 1994;34:52-5.
- 10 Bradley WG. MR appearance of hemorrhage in the brain. *Radiology* 1993;189:15-26.
- 11 Midroni G, Willinsky R. Rapid postanoxic calcification of the basal ganglia. *Neurology* 1992;42:2144-6.
- 12 Triulzief T. Cerebral hemorrhage: CT and MR. *Rev Neuro-radiol* 1990;3(suppl 2):39-44.
- 13 Kase C, Mohr JP. Supratentorial intracranial hemorrhage. In Barnett HJM, Stein BM, Mohr JP, Yatsu FM, eds. *Stroke: pathophysiology, diagnosis and management*. New York:Churchill Livingstone, 1986:525-47.
- 14 Lin JJ, Chang MK. Hemiballism-hemichorea and non-ketotic hyperglycaemia. *J Neurol Neurosurg Psychiatry* 1994;57:748-50.
- 15 Maccario M. Neurological dysfunction association with non-ketotic hyperglycemia. *Arch Neurol* 1968;19:535-6.
- 16 Foster DW. Diabetes mellitus. In: Braunwald E, Isselbacher K, Petersdorf R, et al. eds. *Harrison's principles of internal medicine*. 12th ed. New York:Mcgraw-Hill 1991:1739-54.
- 17 Rector GW, Herlong HF, Moses H. Non-ketotic hyperglycemia appearing as choreoathetosis or ballism. *Arch Intern Med* 1982;142:154-5.
- 18 Totoritis M, Cornish P, Thompson F. Non-ketotic hyperglycemia. *Arch Intern Med* 1982;142:1045.
- 19 Chang MH, Li JY, Lee SR, Men CY. Non-ketotic hyperglycaemic chorea: a SPECT study. *J Neurol Neurosurg Psychiatry* 1996;60:428-30.