

SHORT REPORT

Machado-Joseph disease presenting as severe asymmetric proximal neuropathy

I N van Schaik, G J Jöbbsis, M Vermeulen, H Keizers, P A Bolhuis, M de Visser

Abstract

Despite much effort, a 74 year old man with progressive proximal weakness and sensory disturbances due to axonal neuropathy remained a diagnostic problem. Investigation of his family disclosed an additional patient with a cerebellar syndrome and a family member with mainly pyramidal features. Analysis of DNA showed a CAG repeat expansion in the Machado-Joseph disease gene in all three patients. Although not conclusively proved, we think that the neuropathy of the index case is linked to the CAG repeat expansion. Machado-Joseph disease should be considered in progressive axonal neuropathy.

(*J Neurol Neurosurg Psychiatry* 1997;63:534-536)

Keywords: neuropathy; Machado-Joseph disease; SCA3; trinucleotide repeat expansion

Machado-Joseph disease comprises four different clinical types depending on the age of onset.¹⁻³ Patients with Machado-Joseph disease type I have a mean age at onset of 23 years and display predominantly pyramidal and extrapyramidal signs. Most patients with Machado-Joseph disease have type II, presenting with ataxia as the dominant symptom and a mean age at onset of 35 years. In patients with type III, with a mean age at onset of 53 years, the clinical features are those of peripheral neuropathy with muscle atrophy with fasciculations in addition to ataxia. Patients with the rare type IV have parkinsonism variably combined with ataxia, muscle atrophy, and sensory loss, and have a later onset than type III.⁴

The genetic defect of Machado-Joseph disease consists of an expanded trinucleotide repeat within the coding region of a novel gene on chromosome 14q.⁵ Normal alleles vary from 13 to 36 CAG repeats whereas mutated alleles contain between 61 and 84 repeats.^{5,6} Repeat numbers are related to age of onset,^{3,7-12} and to clinical phenotype (I, II, and III).^{3,7,10,12} Of the rare Machado-Joseph disease type IV, only two patients have been characterised genetically so

far, and seemed to have a relatively short CAG repeat expansion.⁴

Recently, a new subtype has been proposed based on a report of two patients with spastic paraplegia without cerebellar ataxia.¹³ Whether these cases really represent a new subtype or just an atypical presentation of Machado-Joseph disease type I is disputable. However, they illustrate that ataxia need not necessarily be the main feature and that cerebellar symptoms may be masked by other neurological signs. Here we describe a patient with severe asymmetric proximal motor-sensory neuropathy without apparent cerebellar features. Examination of family members prompted a diagnosis of Machado-Joseph disease. Subsequent DNA analysis disclosed a CAG expansion in the Machado-Joseph disease gene in all three patients.

Case summaries

The proband, patient A (figure), a 74 year old man of Dutch descent developed difficulty walking at the age of 50 due to buckling of his left knee. Subsequently, in the course of two decades, weakness spread to his left arm, right leg, and finally his right arm. At the age of 73 he became confined to a wheelchair and needed assistance for normal daily activities. He experienced pins and needles with numbness of the left arm and altered temperature sensation of the lower limbs with periods of burning feet. Medical history disclosed non-insulin dependent diabetes mellitus for the past two years, hypertension, myocardial infarction, a left-sided total hip replacement, and meniscectomy. Medication consisted of metoprolol, triamterene, hydrochlorothiazide, tolbutamide, and calcium carbasalate.

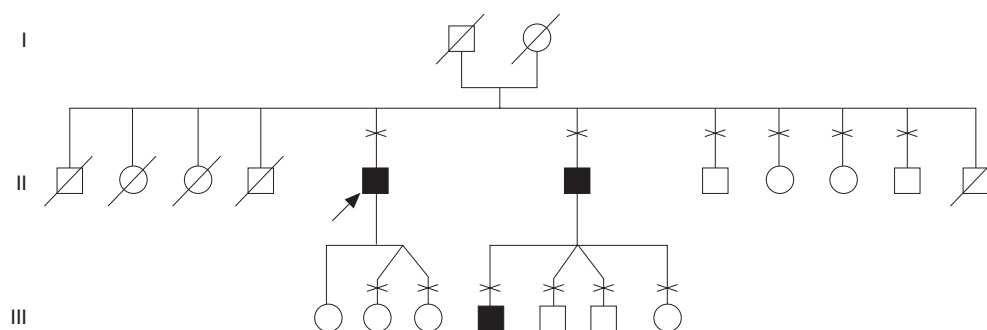
On examination there were cold, bluish discoloured legs with pitting oedema; absence of abnormal cranial nerve signs except for saccadic eye movement on pursuit; fasciculations of arm muscles; generalised atrophy, especially of the proximal muscles and more severe on the left; severe paresis of the left leg (grade 2-3 on MRC scale); and paresis of the other limbs, proximal grade 3-4 and distal grade 4. Sensory deficit consisted of diminished sensation to pain and light touch in the left arm and diminished vibration and position sense of the entire lower limbs. There was areflexia except for the

Department of
Neurology, Academic
Medical Center,
University of
Amsterdam,
Amsterdam, The
Netherlands
I N van Schaik
G J Jöbbsis
M Vermeulen
H Keizers
P A Bolhuis
M de Visser

Correspondence to:
Dr G J Jöbbsis, Department of
Neurology, H2-214,
Academic Medical Center,
PO box 22700, 1100 DE
Amsterdam, The
Netherlands.

Received 31 January 1997
and in revised form 6 April
1997

Accepted 2 May 1997



Pedigree structure with filled symbols designating patients with Machado-Joseph disease. Examined subjects are indicated by the crosses above the pedigree symbol. Arrow indicates proband.

tendon reflexes of the right arm and plantar responses were flexor.

Extensive laboratory investigation was unremarkable except for an IgG- κ paraproteinaemia which was classified as a monoclonal gammopathy of undetermined significance (MGUS). Antibodies against myelin associated glycoprotein and GM1-gangliosides were absent. Magnetic resonance imaging showed slight atrophy of the cerebellum, cerebrum, and cervical spinal cord but not of the brainstem and was otherwise normal. Electrophysiological studies disclosed decreased compound muscle action potentials (CMAPs), decreased sensory nerve action potentials (SNAPs), and slightly delayed nerve conduction velocities in the upper and lower limbs (table). The peroneal CMAP and left sided sural SNAPs were absent. Electromyography showed signs of severe denervation and reinnervation. These findings were considered to be consistent with axonal motor-sensory neuropathy. Visual and brainstem auditory evoked potentials were normal, eye movement recording showed square wave jerks and saccadic pursuit. With magnetic stimulation no central conduction disturbance of motor neurons was found. Biopsy of the quadriceps muscle showed chronic and active denervation atrophy with some rimmed vacuoles and sarcoplasmic glycogen masses. An ischaemic forearm test disclosed a normal increase of lactate after exercise. Sural nerve biopsy showed chronic axonal degeneration with signs of regeneration and extensive loss of both myelinated and unmyelinated fibres. The large myelinated fibres were nearly absent in the unimodal histogram. Immunohistochemical techniques did not show IgG or complement deposits. Staining for leucocyte markers showed some cells scattered throughout the epineurium and perineurium. There were no signs of active

inflammation. Ten months after examination he died at home during his sleep due to an unknown cause. Permission for necropsy was not given by his family.

A younger brother of the proband (patient B), a 72 year old man with progressive walking difficulty for at least 10 years, displayed on examination cerebellar features such as gait ataxia, dysarthria, and saccadic eye movements on pursuit. Except for diminished vibration sense of the feet, there were no sensory signs or upper motor signs. The ankle and knee jerks were absent. Brain MRI showed atrophy of cerebellum and brainstem. Eye movement recording showed spontaneous nystagmus, abnormal smooth pursuit, and diminished vestibulo-ocular and caloric nystagmus.

Patient C, a 29 year old son of patient B with symptoms of clumsiness and stiffness, had spasticity in addition to nystagmus, saccadic eye movements, and dysidiadochokinesia.

The figure shows additional family members neurologically examined.

Methods and results of genetic analysis

DNA was obtained by extraction from leucocytes using standard methods. The Machado-Joseph disease CAG repeat was amplified by polymerase chain reaction from genomic DNA as described elsewhere.⁵ The size of the CAG repeat was determined by polyacrylamide/urea/formamide gel electrophoresis using a sequence ladder as a length marker. Determinations of CAG repeat length showed a repeat number (including one interspersed CAA) of 22 and 54 for patient A, 22 and 62 for patient B, and 22 and 68 for patient C.

Discussion

Although the index case with severe, asymmetric, proximal motor-sensory neuropathy is not suggestive of Machado-Joseph disease, this

Neurophysiological findings in the index patient

	Motor				Sensory				
	Dlt (ms)	Amplitude (mV)		NCV (m/s)	Dlt (ms)	Amplitude (μ V)		NCV (m/s)	F response
		Distal	Proximal			Distal	Proximal		
R median nerve	5.7	2.7	6.8	52	3.9				38.4-40.5
R ulnar nerve	3.2	18.3	13.6	39	5.3	16.2	1.0	46	29.3-29.8
R peroneal nerve	4.4	A	A	A			9.8	49	
L peroneal nerve	3.5	A	A	A	9.9	A			
R posterior tibial nerve	12.1			36.5					
L posterior tibial nerve	3.8	0.5	0.8	38					

Dlt = Distal latency time; NCV = nerve conduction velocity; A = absent.

diagnosis was finally considered most likely. The family contained additional members with longstanding neurological complaints; these relatives were either unavailable or clinical investigation or DNA analysis showed that they did not have Machado-Joseph disease. The index patient had had non-insulin dependent diabetes mellitus for two years which was well regulated with an oral antidiabetic drug. His neurological symptoms started long before the diabetes was diagnosed. Moreover, the type of neuropathy, distribution of signs and symptoms, and the neurophysiological and pathological findings are not consistent with any of the known diabetic neuropathy syndromes. The same holds true for the IgG monoclonal gammopathy of undetermined significance (MGUS). Neuropathies associated with IgG MGUS are normally symmetric, slowly progressive, and never lead to complete paralysis or respiratory failure. Neurophysiological studies show segmental demyelination and nerve biopsies often show deposits of immunoglobulins in the peripheral nerve; both features were absent in the index case.

The repeat length of 54 CAGs of patient A is below the smallest repeat expansion reported for Machado-Joseph disease so far—that is, 61.^{4,13} In view of the correlation between repeat number and phenotype,^{3,7,10,12} it is tempting to speculate that the atypical presentation of the index case is related to the short repeat expansion.

Machado-Joseph disease has been considered to be distinct from autosomal dominant cerebellar ataxia type I (ADCA I, reviewed by Junck and Fink¹⁴). Characteristics that seemed to separate Machado-Joseph disease included clinical signs (faciolingual contraction fasciculations and pseudoexophthalmus), distribution of pathology (sparing of the inferior olivary nuclei and Purkinje cells but substantial involvement of the dentate nuclei and substantia nigra), and the nearly exclusive occurrence in people of Portuguese or Azorean descent. Recently, the genetic defect of Machado-Joseph disease was found to be identical to a subset of ADCA I—that is, spinocerebellar ataxia type 3 (SCA3).^{8,9,11,15-18} Several hypothetical mechanisms could account for a mutation giving rise to two disorders or various phenotypes within one disorder.¹⁴ Alternatively, contrary to previous classification systems the most common type of Machado-Joseph disease with mainly cerebellar features might be identical to SCA3. Other types of Machado-Joseph disease should be present in ADCA I/SCA3 families as well.

This Dutch family has three presentation forms: amyotrophy with neuropathy, cerebellar ataxia, and spasticity. Our findings sustain the presence of an age related presentation in west European, non-Portuguese/non-Azorean ADCA I with the Machado-Joseph disease/SCA3 repeat expansion. If, despite a shared mutation, the particular features of Machado-Joseph disease such as the age related presenta-

tion are taken to constitute sufficient grounds to distinguish it from SCA3, our kindred shows that Machado-Joseph disease is also present in patients of Dutch descent. Whatever the outcome of the nosological debate, Machado-Joseph disease/SCA3 should be considered in severe, progressive proximal axonal neuropathy, especially if the family history shows relatives with a cerebellar syndrome. In a heterogeneous group of disorders with a highly variable presentation like ADCA I, DNA analysis will help to delineate the nosological boundaries. The range of phenotypes in Machado-Joseph disease could become larger when CAG repeat expansions are systematically sought in families with neurodegenerative diseases of unknown origin.

This work was supported in part by grants from the Schuhmacher-Kramer foundation and the Prinses Beatrix Fonds. INvS and GJJ contributed equally to this study. We are grateful to Dr AAWM Gabreëls-Festen for assessment of the sural nerve biopsy and Dr R Witteveen for referral of the index patient.

- Rosenberg RN. Machado-Joseph disease: an autosomal dominant motor system degeneration. *Mov Disord* 1992;7:193-203.
- Barbeau A, Roy M, Cunha L, et al. The natural history of Machado-Joseph disease. An analysis of 138 personally examined cases. *Can J Neurol Sci* 1984;11:510-25.
- Sasaki H, Wakisaka A, Fukazawa T, et al. CAG repeat expansion of Machado-Joseph disease in the Japanese: analysis of the repeat instability for parental transmission, and correlation with disease phenotype. *J Neurol Sci* 1995;133:128-33.
- Tuite PJ, Rogaeva EA, St George-Hyslop PH, Lang AE. Dopa-responsive parkinsonism phenotype of Machado-Joseph disease: confirmation of 14q CAG expansion. *Ann Neurol* 1995;38:684-7.
- Kawaguchi Y, Okamoto T, et al. CAG expansions in a novel gene for Machado-Joseph disease at chromosome 14q32.1. *Nature Genet* 1994;8:221-8.
- Maruyama H, Nakamura S, Matsuyama Z, et al. Molecular features of the CAG repeats and clinical manifestation of Machado-Joseph disease. *Hum Mol Genet* 1995;4:807-12.
- Dürr A, Stevanin G, Cancel G, et al. Spinocerebellar ataxia 3 and Machado-Joseph disease: clinical, molecular, and neuropathological features. *Ann Neurol* 1996;39:490-9.
- Ranum LPW, Lundgren JK, Schut LJ, et al. Spinocerebellar ataxia type I and Machado-Joseph disease: incidence of CAG expansions among adult-onset ataxia patients from 311 families with dominant, recessive, or sporadic ataxia. *Am J Hum Genet* 1995;57:603-8.
- Matilla T, McCall A, Subramony SH, Zoghbi HY. Molecular and clinical correlations in spinocerebellar ataxia type 3 and Machado-Joseph disease. *Ann Neurol* 1995;38:68-72.
- Maciel P, Gaspar C, DeStefano AL, et al. Correlation between CAG repeat length and clinical features in Machado-Joseph disease. *Am J Hum Genet* 1995;57:54-61.
- Cancel G, Abbas N, Stevanin G, et al. Marked phenotypic heterogeneity associated with expansion of a CAG repeat sequence at the spinocerebellar ataxia 3/Machado-Joseph disease locus. *Am J Hum Genet* 1995;57:809-16.
- Takiyama Y, Igarashi S, Rogaeva EA, et al. Evidence for inter-generational instability in the CAG repeat in the MJD1 gene and for conserved haplotypes at flanking markers amongst Japanese and Caucasian subjects with Machado-Joseph disease. *Hum Mol Genet* 1995;4:1137-46.
- Sakai T, Kawakami H. Machado-Joseph disease: a proposal of spastic paraplegic subtype. *Neurology* 1996;46:846-7.
- Junck L, Fink JF. Machado-Joseph disease and SCA3: the genotype meets the phenotypes. *Neurology* 1996;46:4-8.
- Schols L, Vieira-Saccker AMM, Schols S, Pruntek H, Epplen JT, Riess O. Trinucleotide expansion within the MJD1 gene presents clinically as spinocerebellar ataxia and occurs most frequently in German SCA patients. *Hum Mol Genet* 1995;4:1001-5.
- Haberhausen G, Damian MS, Leweke F, Muller U. Spinocerebellar ataxia, type 3 (SCA3) is genetically identical to Machado-Joseph disease (MJD). *J Neurol Sci* 1995;132:71-5.
- Higgins JJ, Nee LE, Vasconcelos O, Ide SE, Lavedan C, Goldfarb LG, Polymeropoulos MH. Mutations in American families with spinocerebellar ataxia (SCA) type 3: SCA3 is allelic to Machado-Joseph disease. *Neurology* 1996;46:208-13.
- Silveira I, Lopes-Cendes I, Kish S, et al. Frequency of spinocerebellar ataxia type 1, dentatorubropallidolysian atrophy, and Machado-Joseph disease mutations in a large group of spinocerebellar ataxia patients. *Neurology* 1996;46:214-8.