

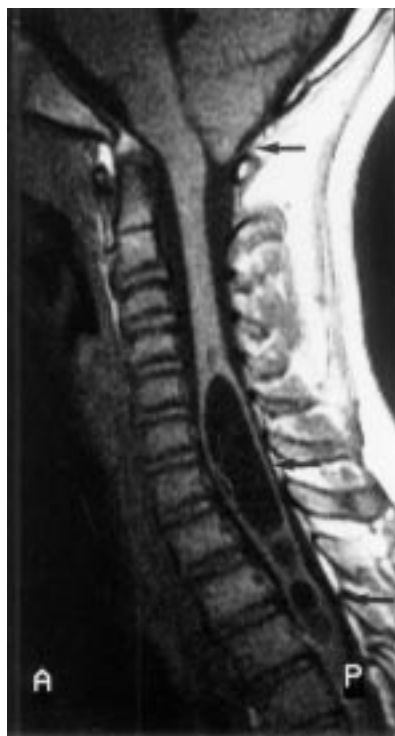

Figure 1 T1 weighted spin echo midsagittal MRI (TR: 404 ms, TE: 15 ms) showing Chiari I malformation with herniated cerebellar tonsils (arrow) and spindle shaped hydrosyringomyelia from C5 to T4 (arrow), with further smaller cavitations to T7 (arrow).

tion as well as two sleeping EEG records and 24 hour EEG records showed normal activity. Due to the unexplained nature of the repeated syncopes, a cerebral MRI was performed. This showed type I Chiari malformation with herniated cerebellar tonsils and compression of the foramen magnum. A subsequent MRI of the spine showed hydrosyringomyelia from C5 to T4, with further smaller cavitations to T7, with no evidence of cavitation above C4. No associated tumour could be found (figure). After consultation with our neurosurgeons we decided against neurosurgical intervention for the time being in view of the completely normal neurological status of the patient. A cerebral and spinal control MRI one and two years later showed no progression of the syrinx.

After diagnosing the extended hydrosyringomyelia and Chiari type I malformation, the question arose whether there is a relation between this and the repeated syncopal events. Considering the normal results of repeated cardiological investigations and EEG records (including resting, sleeping, and 24 hour EEGs) a cardiogenic or epileptogenic aetiology of the described syncopes seems unlikely.

There are various pathophysiological models of syncopes in patients with hydrosyringomyelia. According to the model of Williams, an increase of intrathoracic pressure caused, for example, by coughing, leads to a shift of CSF from the spinal to the cranial compartment. During the subsequent relaxation period a flow back to the spinal compartment due to a "sucking effect" may lead to hindbrain herniation with impaction of the cerebellar tonsils and to interference with the medullary baroreceptor reflex or dysfunction of the midbrain reticular activating system,

thus leading to syncope.<sup>4</sup> In our patient, with syncopes occurring with no evidence of preceding symptoms such as coughing to cause consecutively cerebral or spinal pressure changes, this explanation seems unlikely. The fact that autonomic disturbances occur even in subjects without foramen magnum anomaly indicates that anomalies of the posterior fossa may be not the only factor in the pathogenesis of autonomic disturbances associated with syringomyelia. In this context Noguez *et al* found some subclinical autonomic disturbances in patients with syringomyelia, especially in those with brainstem involvement. However, in some patients with no signs of such involvement, a fall of more than 2 SD in mean arterial pressure in response to standing was still found. Therefore for some patients the authors assume an underlying sympathetic defect (for example, produced by destruction of the lateral horns of grey matter), which is incomplete and not extensive enough to cause permanent orthostatic hypotension.<sup>5</sup> This would suggest that cavitation in the medulla with involvement of sympathetic structures could be another factor responsible for consecutive autonomic disturbances in patients with hydrosyringomyelia. This defect could result in temporary interruption of the spinal vegetative reflex arc with temporary postural hypotension. Considering the pattern of syringomyelic areas affected in our patient, damage to sympathetic structures neighbouring the syrinx may have led to temporary dysfunction of the sympathetic system with subsequent syncope. The assumption of a merely temporary interruption of the spinal vegetative reflex might explain the repeated normal results of clinical examination and Schellong tests, and that several changes of body position did not lead to a syncopal event in our patient. Furthermore it may be that pathophysiology of syncopes in patients with hydrosyringomyelia/Chiari I malformations is more complex—for example, due to synergistic neuropsychological influences such as increased attention while studying at school.

Despite the theoretical models outlined, the relation between isolated syncopal events in patients with hydrosyringomyelia and anomalies of the posterior fossa generally remains speculative. Furthermore the association of isolated syncopes and hydrosyringomyelia represents a very small fraction of all patients presenting with syncopes. Thus the decision to perform cerebral MRI in patients with unexplained syncopes must be considered on a case by case basis, although our case report shows that some patients may profit by performance of cerebral and cervical MRI to rule out hydrosyringomyelia and anomalies of the posterior fossa.

JOACHIM WOELFLE  
FRITZ HAVERKAMP

Department of Pediatrics

BURKARD KREFT

Department of Radiology, University of Bonn,  
Germany

Correspondence to: Dr J Woelfle, Zentrum f Kinderheilkunde, Rhein Friedrich-Wilhelms-Universität, Adenauerallee 119, D-53113 Bonn, Germany. Telephone 0049 228 2873200; fax 0049 228 2873314.

1 Hampton F, Williams B, Loizou LA. Syncope as a presenting feature of hindbrain herniation with syringomyelia. *J Neurol Neurosurg Psychiatry* 1982;45:919–22.

2 Larson SJ, Sanges A, Baker JB, Reigel DH. Herniated cerebellar tonsils and cough syncope. *J Neurosurg* 1974;40:524–8.

3 Aminoff MJ, Wilcox CS. Autonomic dysfunction in syringomyelia. *Postgrad Med J* 1972;48: 113–5.

4 Williams B. Simultaneous cerebral and spinal fluid pressure recordings. 2. Cerebrospinal disassociation with lesions at the foramen magnum. *Acta Neurochir (Wien)* 1981;59:123–42.

5 Noguez MA, Newman PK, Male VJ, Foster JB. Cardiovascular reflexes in syringomyelia. *Brain* 1982;105:835–49.

### Magnetic resonance imaging of acute infarction of the anterior spinal cord

Infarction in the territory supplied by the cervical anterior spinal artery occurs infrequently, especially in young people. The anterior spinal artery supplies the ventral two thirds of the spinal cord and provides its major blood supply. In the cervical cord, the anterior spinal artery is supplied by anterior radicular arteries arising from the cervical branches of the vertebral arteries and the ascending cervical arteries.<sup>1</sup> There have been few reports of MRI in the first hours after the start of an anterior spinal artery syndrome. We describe a case of an acute anterior spinal cord syndrome appearing after two suppressed sneezes that was studied with MRI only four hours after the onset of symptoms.

A 37 year old previously healthy woman suddenly experienced severe anterior thoracic pain after two consecutive suppressed sneezes. Five minutes later, the pain irradiated to the arms and was followed by paresthesiae and weakness in both upper limbs. One hour later the weakness and paresthesiae had extended to the legs. On admission neurological examination showed tetraparesis, with a predominantly distal motor deficit in the arms (0/5 power distal and 3/5 proximal). There was an overall reduction in power to 3/5 in the legs. The deep tendon reflexes were diminished in the arms and absent in the legs. Plantar responses were indifferent. There was a loss of sensation for pain and temperature below the T2 dermatome. Light touch and vibratory and position sensitivity were preserved. The patient also developed a neurogenic bladder.

With these the clinical features, an infarction in the territory of the anterior spinal artery was suspected and an emergency MRI of the cervical spine was performed four hours after the onset of symptoms. This initial MRI, using fast spin echo sequences, failed to show any spinal cord signal abnormality (figure, A); immediately afterwards, a conventional sagittal dual echo long TR spin echo sequence showed a linear high signal intensity lesion affecting the anterior part of the cervical spinal cord between C3 and C7 (figure, B and C). No cord swelling was identified. All the findings were consistent with the clinical diagnosis of infarction of the anterior spinal artery.

Chest radiography, ECG, and routine laboratory examinations were normal. Chest CT performed to rule out aortic dissection was also normal. The patient was treated initially with intravenous methylprednisolone (1 g daily for three days).

Over the next 12 hours she developed flaccid paralysis of the lower and distal upper limbs, with continued diminished muscle power of the deltoid and biceps muscles. Deep tendon reflexes were abolished except for the biceps reflexes. The sensorial level was unchanged. An ECG failed to disclose thrombi. Somatosensory evoked potentials in the arms and legs showed no conduction blocks. Blood coagulation tests were normal.

Antinuclear and antiphospholipid antibodies analysis were negative. Serological tests for HIV, Epstein-Barr virus, lues, *Borrelia burgdorferi*, varicella zoster virus, and herpes simplex virus were negative. Four days later a follow up cervical spine MRI, including angiographic sequences of the vertebrobasilar system, was performed. Vertebral artery dissection could be ruled out, but the spinal cord showed pronounced swelling and on the long TR conventional spin echo sequences a diffuse high intensity signal covering almost the entire diameter of the cervical spine was identified that spared only its posterolateral borders (figure, D). The inferior extension of the signal abnormality reached the T1 level. Spinal angiography was not performed, as it was not considered to be clinically justified. A third MRI performed two months later showed an extensive area of atrophic myelomalacia of the cervical cord between C3 and T1.

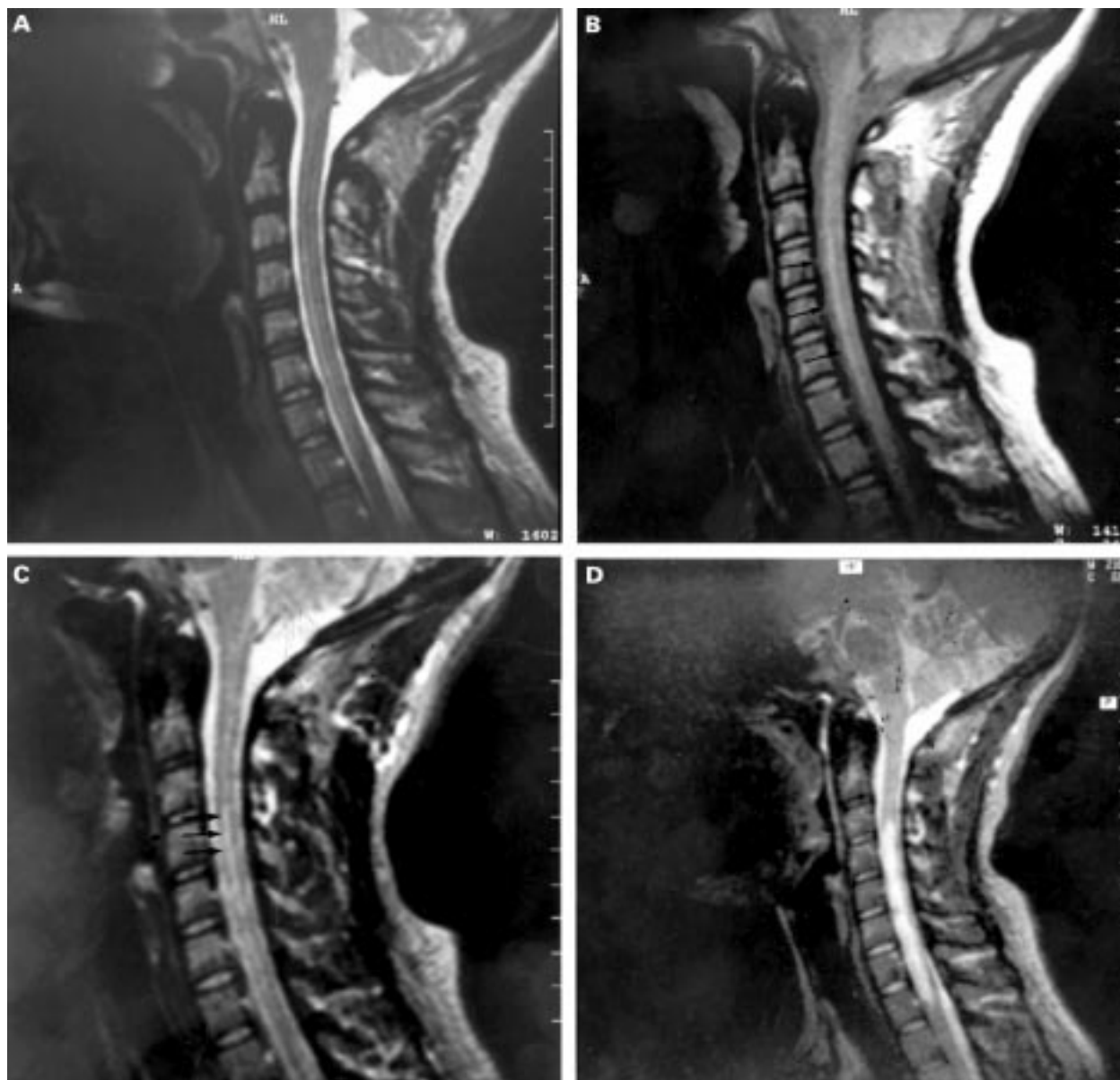
The patient made a slow clinical recovery, and four months later appreciable tetraparesis persisted.

Infarction of the cervical spine cord is rare, especially in young people. We think that the patient presented with infarction of the anterior spinal cord because of the sudden onset and rapid development of typical clinical features after two violent sneezes, with no posterior column involvement (dissociated sensory impairment), absence of cord compression, and exclusion of other known neurological diseases, all of which point to anterior spinal artery syndrome as a result of infarction in the territory supplied by this artery.

Different causes of anterior spinal cord infarction have been described in young people—namely, arteriovenous fistula, spinal surgery, cardiac surgery, arteriography, fibrocatilagenous embolism, polyarteritis nodosa, and carotid or vertebral artery dissection. However, the final cause is not identified in

half of the cases.<sup>2,3</sup> Spinal cord or brainstem infarctions have been reported in association with chiropractic manipulation<sup>1</sup> and hyperextension of the neck. Dissection of the vertebral artery was found in all these cases. In our patient this second diagnosis was ruled out with the combination of conventional MRI and MR angiography. Gutowski *et al*<sup>4</sup> reported another case of cervical posterior spinal artery infarction after sneezing. In our patient, the spinal cord infarction could have been caused by abnormal neck movements in association with the suppressed sneezes. The relation of extreme flexions of the neck (violent sneeze) with the abrupt onset of symptoms suggests vascular compression or obstruction of the vertebrobasilar system without arterial dissection.

Most cases of spinal cord infarction are associated with arteriovenous fistulas<sup>5</sup> that are not always identified on MRI, and it has been suggested that spinal angiograms should



(A) Sagittal fast spin echo T2 weighted image (5000/112) performed four hours after the clinical event showing no remarkable abnormalities. (B) Sagittal conventional spin echo proton density weighted image (2200/20) performed immediately after the sequence shown in (A) clearly shows a linear high signal intensity lesion affecting the anterior portion of the cervical spinal cord (arrows). (C) Sagittal conventional spin echo T2 weighted image (2200/80) confirms the high signal intensity lesion affecting the anterior portion of the cervical spinal cord (arrows). (D) A follow up MRI study performed four days later, using a conventional spin echo T2 weighted image (2200/80) shows a swollen and hyperintense cervical spinal cord.

be performed, at least in young patients, when no obvious cause is known. However, a more recent report shows a higher sensitivity of MRI in detecting this kind of malformation. In the presented case vertebral angiography was not considered clinically justified. The clinical contribution of MRI in those cases of anterior spinal infarction with an obvious traumatic event and in which a high quality cervical spine MRI has ruled out spinal vascular malformations and vascular dissection, may be limited and should not be considered mandatory.

MRI is a sensitive modality in the evaluation of the spinal cord for infarction. It rules out extradural compression, vascular malformations, and space occupying lesions. The differential diagnosis includes infectious or parainfectious myelitis, multiple sclerosis, and vasculitis. In inflammatory or demyelinating lesions, it is well known that T2 weighted images show lesions some time before the clinical onset, whereas with ischaemic lesions a normal or almost normal MRI is usually seen in the first few hours. The sudden onset of clinical symptoms after a rapid movement of the neck is very suggestive of infarction, but not of myelitis. In the acute phase after infarction the diameter of the spinal cord remains normal and diagnosis is based on signal abnormalities on the long TR sequences, which reflect the presence of cytotoxic oedema. However in the subacute phase, with the appearance of extensive vasogenic oedema, the high signal abnormalities are more evident and associated with cord swelling. In our case the anterior location and the temporal MRI changes, together with the sudden onset and rapid development of typical clinical symptoms, should help in differentiating spine infarction from other spinal cord lesions such as multiple sclerosis and neoplastic conditions.

We have not found any reported case of spinal cord infarction in which MRI was performed in the first four hours after the clinical event. In this acute phase only a subtle anterior linear hyperintensity was identified on the T2 weighted images. This abnormal intensity was not clearly seen on the fast spin echo sequence; however, we were able to identify it with a conventional spin echo sequence. Despite the fact that fast spin echo sequences have been accepted for routine use in the examination of spinal cord lesions, replacing conventional spin echo sequences, the second are more sensitive and should be used in selected cases, when obvious clinical lesions have not been clearly shown on the fast spin echo sequences. Fast spin echo imaging of the spine is in most ways similar to conventional spin echo imaging. However, there may be difficulties in detecting very small intramedullary lesions.<sup>6</sup>

A ROVIRA  
S PEDRAZA  
*Magnetic Resonance Unit*  
M COMABELLA  
J ALVAREZ  
*Department of Neurology*

A SALGADO  
*Intensive Care Unit, Hospital General Universitari  
Vall d'Hebron, Barcelona*

Dr A Rovira, Unitat de Resonància Magnètica, Hospital General Universitari Vall d'Hebron, Psg Vall D'Hebron 119-129, 08035 Barcelona, Spain. Telephone 0034 3 4286034; fax 0034 3 4286059.

1 Sherman DG, Hart RG, Easton JD. Abrupt change in head position and cerebral infarction. *Stroke* 1981;12:2-6.

- 2 Foo D, Rossier AB. Anterior spinal artery syndrome and its natural history. *Paraplegia* 1983;21:1-10
- 3 Yuh WTC, Marsh EE, Wang AK, Russell JW, Chiang F, Koci TM, et al. MR Imaging of spinal cord and vertebral body infarction. *AJNR Am J Neuroradiol* 1992;13:145-54.
- 4 Gutowski NJ, Murphy RP, Beale DJ. Unilateral upper cervical posterior spinal artery syndrome following sneezing. *J Neurol Neurosurg Psychiatry* 1992;55:841-3.
- 5 Dillon WP, Norman D, Newton TH, Bolla K, Mark A. Intradural spinal cord lesions: Gd-DTPA-enhanced MR imaging. *Radiology* 1989;170:229-37
- 6 Thorpe JW, Kendall BE, MacManus DG, McDonald WI, Miller DH. Dynamic gadolinium-enhanced MRI in the detection of spinal arteriovenous malformations. *Neuroradiology* 1994;36:522-9.

### Myoclonus induced by tacrine

Several adverse effects of tetrahydroaminoacridine, or tacrine, have been reported since 1986, when Summers and colleagues described that its use could lead to an improvement in cognitive defects in patients with Alzheimer's disease. The most common of them are hepatic toxicity, which makes liver function monitoring necessary, and cholinergic effects. Convulsions have also been described.<sup>1</sup> We report on a patient with moderate Alzheimer's disease who presented with non-epileptic myoclonus during treatment with tacrine.

The patient was a 68 year old woman who had been diagnosed with dementia of probable Alzheimer's type four years previously. A mini mental test examination score was 12 points. She had no other disease and was treated with clometiazole. She had no history of epilepsy or myoclonus related to dementia. Four days before admission she had started treatment with 40 mg tacrine daily and 24 hours later she progressively developed generalised uncontrolled abnormal movements, affecting all her limbs and her mouth. These abnormal movements were non-rhythmic, with a spontaneous presentation, although they could be brought on by touch and sound. They were suggestive of myoclonus and were reduced after treatment with clonazepam. Blood analyses were normal. Brain MRI showed a moderate degree of cortical and subcortical atrophy and EEG showed mild and diffuse neuronal dysfunction with an absence of spikes. Myoclonus disappeared 24 hours after withdrawal of tacrine. A few months later, tacrine was restarted to confirm the causative relation. She developed generalised myoclonus during the next 48 hours.

To our knowledge, non-epileptic myoclonus may appear in 20%-30% of patients with very advanced Alzheimer's disease, but non-epileptic myoclonus in association with tacrine in humans has not been previously reported. Tacrine is a centrally active non-competitive reversible acetylcholinesterase inhibitor and its action results in a prolongation of cholinergic activity.<sup>2</sup> Svejdova et al reported that non-epileptic myoclonus was induced in baboons (*Papio papio*) by 7-MEOTA (7-methoxytacrine, a tacrine derivative).<sup>3</sup> They speculated about a possible anticholinergic effect of 7-MEOTA by an antagonistic action on the muscarinic acetylcholine receptors. This effect has also been suggested by other authors.

S ABILLEIRA  
ML VIGUERA  
F MIQUEL

*Department of Neurology, Hospital General  
Universitari de la Vall d'Hebron, Barcelona, Spain*

Correspondence to: Dr Sònia Abilleira, Department of Neurology, Hospital General Universitari de la Vall d'Hebron, Psg Vall d'Hebron 119-129, 08035 Barcelona, Spain.

- 1 Lebert F, Hasenbroeck C, Pasquier F, et al. Convulsive effects of tacrine. *Lancet* 1996;347:1339-40.
- 2 Davis KL, Powchik P. Tacrine. *Lancet* 1995;345:625-30.
- 3 Svejdova M, Rektor I, Silva-Barrat C, et al. Unexpected potentializing effect of a tacrine derivative upon the non-epileptic-myoclonus in baboons *Papio papio*. *Prog Neuropsychopharmacol Biol Psychiatry* 1990;6:961-66.

### Primary HIV-1 infection presenting with transient neurological deficit

An association between cerebrovascular disease (causing transient neurological deficit, transient ischaemic attacks, or cerebral infarction) and advanced HIV disease or AIDS is recognised.<sup>1-3</sup> There is also one report of ischaemic stroke as the first manifestation of HIV infection.<sup>4</sup> We report a patient with primary HIV-1 infection who presented with a transient neurological deficit. A previously healthy 33 year old right handed male homosexual presented as an emergency with sudden onset of right sided weakness, dysarthria, and dysphasia. He had been unwell for 10 days with fever, pharyngitis, malaise, myalgia, transient non-pruritic macular rash on the upper chest, and transient paraesthesiae affecting the hands. On admission to hospital the neurological features were improving but mild weakness of the right lower limb and expressive dysphasia were present. The neurological deficit resolved completely within 24 hours. Fever (>39°C), a petechial enanthem on the hard palate, and cervical lymphadenopathy were also noted. There were no features of endocarditis or meningeal irritation. Atypical lymphocytes were present in a blood film with normal full blood count. The erythrocyte sedimentation rate was raised at 45 mm/h; serum C reactive protein concentration was 14 mg/l (normal <10 mg/l). A chest radiograph, echocardiogram, cerebral MRI, urinalysis, blood and urine bacterial cultures, and serological tests for syphilis were negative. An examination of CSF showed a lymphocytic pleocytosis (70 lymphocytes/mm<sup>3</sup>) and increased CSF protein (1.62 g/l; normal <0.45 g/l); HIV RNA gag and pol sequences were detected in the CSF by polymerase chain reaction. Antibody studies indicated recent HIV-1 seroconversion, with rising anti-HIV IgG (enzyme linked immunosorbent assay (ELISA)) and falling anti-HIV IgM (ELISA). Serology for Epstein-Barr virus, cytomegalovirus, and toxoplasma was negative. Serum anticardiolipin antibodies were detected at a low concentration (18 GPL U/ml, normal <10 U/ml); lupus anticoagulant was not detected. Fever and leg pains persisted for three weeks. He was treated with zidovudine, lamivudine, saquinavir, and low dose aspirin, and made a complete symptomatic recovery within one month. No explanation other than HIV infection was identified to account for the neurological features, which were assumed to have an ischaemic cause. Antiviral triple therapy was continued for six months. The most common neurological manifestations of primary HIV infection are lymphocytic meningitis, reversible acute encephalitis, and peripheral mononeuritis; these have previously been found to be associated with accelerated progression of HIV disease. Focal neurological events would seem to occur