

SHORT REPORT

Hyperekplexia and trismus due to brainstem encephalopathy

Mark W Kellett, Peter R D Humphrey, Brian M Tedman, Malcolm J Steiger

Abstract

The brainstem is said to be the generator of pathological startle responses due to reticular reflex myoclonus or hyperekplexia. A patient with facial weakness, nystagmus, and pyramidal tract signs had generalised reflex spasms in response to auditory, visual and tactile stimuli which clinically and neurophysiologically resembled hyperekplexia. The case is unusual because as well as hyperekplexia, the patient's initial presentation was with an equally rare manifestation of brainstem pathology—brainstem mediated trismus. The causes of brainstem trismus and exaggerated startle responses are discussed with respect to their underlying mechanisms.

(*J Neurol Neurosurg Psychiatry* 1998;65:122-125)

Keywords: hyperekplexia; myoclonus; startle; trismus; brainstem

The normal startle response is a form of physiological myoclonus that is present in most normal people, and probably has its origin in the brainstem.¹ Hyperekplexia and reticular reflex myoclonus are two clinically and neurophysiologically distinct conditions presenting with pathological startle responses. Both conditions may result from brainstem disease¹⁻⁴ although hyperekplexia is most commonly due to autosomal dominant mutations of strychnine sensitive inhibitory glycine receptors.⁵

The clinical presentation of hereditary hyperekplexia with stimulus sensitive generalised jerks, prominent facial grimacing, and tonic spasm has some resemblance to tetanus. Both disorders result from impaired inhibitory neurotransmission.^{6,7} Trismus is a prominent symptom in tetanus but may also be caused by structural pathology of the brainstem.⁸ We report on a patient who presented with trismus who later developed generalised spasms provoked by various sensory stimuli in association with other brainstem signs. The initial presentation with trismus and subsequent progression suggests that both conditions were due to brainstem pathology.

Case report

A 53 year old healthy right handed man noted a scratch on his right ankle and an adjacent

insect bite while on holiday in Tunisia in November 1995. There were no signs of localised infection or inflammation and he was generally well until three days later, when he developed severe spasms of his jaw and difficulty opening his mouth. Investigations failed to disclose the cause of his symptoms, but they gradually improved over three weeks. One month after the initial symptoms he developed unpredictable spasms and stiffness of the right leg, which, over one week, progressed to generalised spasms of the whole body. On one occasion an extensor spasm of the legs and trunk threw him backwards through a glass door. The spasms were precipitated by any unexpected stimuli and by attempts to micturate or if he strained at defecation, and continued during sleep, causing him to wake. He was unable to hold objects in his hands due to sudden jerks and, therefore, needed assistance to feed. Throughout this time he had a sensation of stiffness in his legs and arms. He then developed weakness of the right side of his face, intermittent slurring of speech, difficulty swallowing and increasing unsteadiness on his feet.

On examination (six weeks after the initial trismus) there was nystagmus on gaze to the right but eye movements and pupillary responses were normal. He had a right lower motor neuron facial nerve weakness and mild dysarthria with slow tongue movements, the remainder of the cranial nerves were normal. Tone in the arms was increased, varying from extrapyramidal "lead pipe" rigidity to "clasp knife" spasticity on different occasions. Tone was also increased in both legs but there was no axial rigidity at rest. There was mild weakness of left shoulder abduction and of both triceps, and mild weakness of both hip flexors only. The biceps and supinator reflexes were brisk with reduced triceps jerks bilaterally, whereas in the legs, knee and ankle jerks were brisk especially on the right with an extensor plantar response on the right and flexor on the left. Sensation to all modalities was normal.

We made video recordings of the generalised whole body jerks. They began with blinking, followed by facial grimacing, flexion of the head, flexion of the arms towards the face, and extension of the trunk and legs. These occurred on attempts to stand and were also induced by sudden auditory, visual, or tactile stimuli in the

Department of Neurology

M W Kellett
P R D Humphrey
M J Steiger

Department of Neurophysiology, The Walton Centre for Neurology and Neurosurgery, Rice Lane, Liverpool L9 1AE, UK

B M Tedman

Correspondence to:
Dr Malcolm J Steiger, The Walton Centre for Neurology and Neurosurgery, Rice Lane, Liverpool L9 1AE, UK. Telephone 0044 151 529 4324; fax 0044 151 525 3857.

Received 30 May 1997 and in final revised form 25 November 1997
Accepted 25 November 1997

Onset latencies (ms) after taps to the nose (single trials)

EMG study	O Oculi	SCM	Ment	Biceps B	Ext Ind	Vast Med	Tib Ant	
1		9.8		21.2		37.8	48.8	
		9.8		22.2		39.4	55.2	
			9.6		21.2		46.0	
			12.6		25.2	28.6	50.2	
			11.2		24.2	28.8	48.8	
	2	12.8	13.6	16.0	28.8			
		12.4	12.0	16.8	27.6			
14.4			19.2	24.8			41.6	
13.2			19.2	24.2			51.2	

At EMG study 1 the patient was having frequent jerks and had just been started on medication. At study 2 jerks were less easily induced with the patient taking clonazepam and carbamazepine. O Oculi=orbicularis oculi; SCM=sternocleidomastoid; Ment=mentalis; Biceps B=biceps brachii; Ext Ind=extensor indicis; vast Med=vastus medialis; Tib Ant=tibialis anterior.

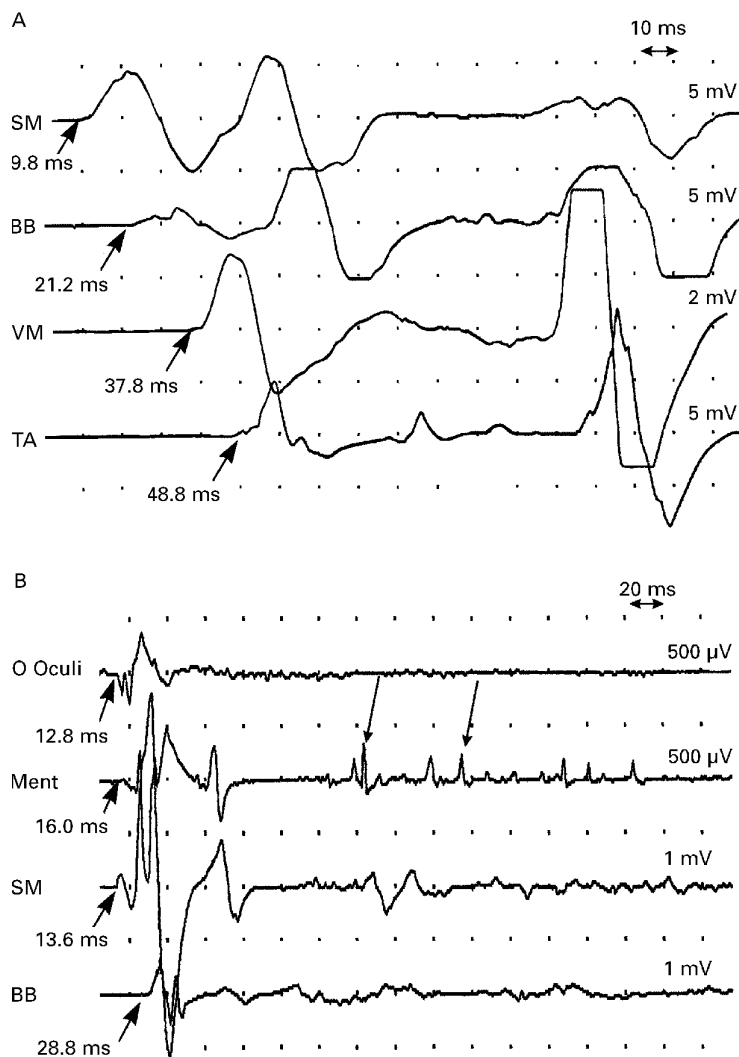
form of brief taps to the skin. Initially, taps to most areas of the body induced generalised jerks, but they were most easily induced by taps to the nose and perioral regions. After the initial generalised jerk a period of tonic spasm lasting up to 30 seconds would occur during which time the patient's breathing would be

irregular with intermittent gasping and on occasions brief periods of apnoea.

Urea and electrolytes, liver and thyroid function tests, and full blood count were normal. The erythrocyte sedimentation rate was 24 mm in the first hour. His CSF was clear and colourless with a normal cell count, a protein concentration of 0.38 g/l, and a glucose concentration of 4 mmol/l. Blood glucose concentration was 7.2 mmol/l. CSF serology for herpes simplex, measles, and varicella zoster virus was negative. Serum and CSF angiotensin converting enzyme concentrations were 25 and <3 iu/l (normal 18–66 iu/l) respectively. Treponemal serology was negative. Gastric parietal cell antibodies were positive but anti-nuclear, anti-thyroglobulin, anti-smooth muscle, and anti-reticulin antibodies were negative. Anti-glutamic acid dehydrogenase antibodies were negative in serum and CSF. Magnetic resonance imaging of the brain, cervical, and thoracic spinal cord were all normal with no enhancement after gadolinium. Somatosensory evoked potentials in both the left and right median nerves to the cortex were normal. Electromyography showed that motor unit potentials were normal with no spontaneous muscle activity. The background rhythm of the EEG was normal. During generalised jerks there was no concomitant EEG changes other than movement artefact.

Triggered EMG recordings were made on two separate occasions (onset latencies are given in the table). Reproducible short latency muscle activation was seen with initial activity in the sternocleidomastoid (figure A and B) and orbicularis oculi (figure B). During the second study (12 weeks after the first) averaged recordings from EEG electrodes placed over the frontal region showed an EEG spike coincident with activity in the orbicularis oculi with a similar pattern of activation, which was interpreted as scalp muscle activity. From the onset latencies, spinal cord conduction measured as the differences in onset between the sternocleidomastoid and the tibialis anterior was 36.4 to 45.4 ms (five trials), and central brainstem conduction from the sternocleidomastoid to the mentalis took 2.4 and 4.4 ms (two trials).

After admission to the Walton Centre he was prescribed clonazepam (2 mg thrice daily) and baclofen (10 mg twice daily) with some benefit. He gradually mobilised with less frequent spontaneous jerks. However, they remained



Single EMG recordings elicited after a tap to the tip of the nose using a tendon hammer attached to an electronic timing trigger. (A) First EMG. EMG activity was seen first in the SM, quickly followed by the BB, the VM, and the TA. In addition, tonic spasms after the initial startle response were accompanied by repeated after discharges indicative of continuing muscle activity. (B) Second EMG study 12 weeks later. Jerks were less easily induced as the patient was taking clonazepam (2 mg four times daily) and carbamazepine (400 mg twice daily), but nevertheless reproducible jerks were elicited. Activity was seen first in the orbicularis oculi (O Oculi), quickly followed by sternocleidomastoid (SM), mentalis (ment) and biceps brachii (BB). Continued muscle activation is indicated by arrows.

easily inducible and he continued to have generalised jerks leading to falls in which he was unable to protect himself. His symptoms deteriorated further when clonazepam was reduced by the patient because of troublesome drowsiness, and he sustained five fractured ribs, a fractured scapula and a dislocation of the acromioclavicular joint during one fall. Addition of sodium valproate (2000 mg daily) had little effect on the frequency and severity of the jerks. Carbamazepine slow release was then successfully added, up to 1800 mg a day, with only one fall over the subsequent month. He continues to improve. There has been complete resolution of the abnormal neurological signs.

Discussion

This man developed an acute episode of trismus after a scratch and insect bite to his lower leg. After a gradual recovery over three weeks he then developed a progressive disorder featuring brainstem and pyramidal tract signs in combination with stimulus sensitive jerks. Tetanus was considered as a cause for the trismus as it can occur with only mild localised tetanus.⁹ However, there were no features of localised tetanus around the leg wound and, furthermore, he had received tetanus toxoid in the previous three years. Trismus occurs in tetanus due to the sensitivity of the masticatory apparatus to tetanus toxin which blocks inhibitory neurotransmission. Impaired inhibitory neurotransmission at strychnine sensitive glycine receptors is a possible mechanism underlying trismus, as these receptors are involved in rhythmical masticatory movements in animals.¹⁰ Trismus due to abnormalities in programming of mastication in the trigeminal motor nuclei of the brainstem has been reported in various brainstem syndromes.^{8 11-16}

Neurophysiological studies in our patient on two occasions disclosed reproducible stereotyped patterns of muscle activation with very short onset latencies excluding a voluntary cause for the jerks. Conduction up the brainstem was extremely rapid, whereas conduction down the spinal cord was much slower. These are typical findings in hyperekplexia¹ and can be differentiated from reticular reflex myoclonus, in which efferent spinal conduction is rapid^{2 3} and approaches that seen in normal subjects.¹ The differences in activation of the mentalis and orbicularis oculi (both supplied by the facial nerve) is thought to be due to activation of the orbicularis as part of an initial blink reflex which is distinguishable from the startle response.¹ Neurophysiological studies in localised tetanus characteristically show spontaneous activity of motor units which cannot be suppressed voluntarily and shortening or absence of the silent period after a stretch reflex or after electrical stimulation of the nerve.⁹ Patterns of muscle activation and spinal cord conduction times do not seem to have been studied in tetanus.

Clinically hyperekplexia is characterised by stimulus sensitivity over the mantle area and the presence of tonic spasms, as seen in our patient. By contrast, stimulus sensitivity is usu-

ally over the limbs in reticular reflex myoclonus with spontaneous jerks occurring between induced jerks.^{2 3} Stimulus sensitivity to the mantle region has also been noted in cases of "jerking stiff man syndrome"¹⁷ and progressive encephalomyelitis with rigidity¹⁸ some of which have evidence of brainstem pathology. Our patient had a strange pattern of increased tone varying between "lead pipe" rigidity and "clasp knife" spasticity but did not have the axial rigidity seen in these disorders. Furthermore, EMG recordings did not show the continuous motor unit activity at rest seen in the stiff man syndrome.

The tonic spasms that follow the initial startle response can be prolonged and in our patient lasted 15 to 30 seconds, during which the EMG showed repetitive discharges indicating prolonged muscle contraction. The spasms were accompanied by irregular breathing and brief apnoeic spells, although a prolonged spasm early in the disease course resulted in a respiratory arrest requiring resuscitation. Apnoea is a well recognised problem in hereditary⁴ and symptomatic cases of hyperekplexia^{4 19} due to spasm of the respiratory muscles, which may lead to death.⁴

There has been controversy regarding the EEG seen in hyperekplexia. Previously, centroparietal spikes with slow waves and desynchronisation of the background rhythm have been attributed to sensory evoked cortical responses.⁴ Eye movement or muscle artefact are other proposed mechanisms.⁴ In our patient, the EEG recording with EMG showed frontal spikes synchronous with activation of orbicularis oculi, suggesting they were due to scalp muscle activity. It is impossible to know whether an underlying cortical spike was obscured by muscle activation, but baseline EEG when jerks were more easily induced showed no cortical activity associated with generalised jerks.

Sporadic hyperekplexia has been described in association with various brainstem diseases⁴ including paraneoplastic brainstem encephalitis, subacute viral encephalomyelitis, brainstem haemorrhages, sarcoidosis,¹ Chiari malformations, and multiple sclerosis.¹ Conditions indistinguishable from hyperekplexia have also been reported with vascular, traumatic, or inflammatory lesions of the thalamus and mid-brain. Extensive investigations in our patient failed to disclose the underlying pathology, although clinical neurological signs and neurophysiology support a brainstem pathology.

Hereditary hyperekplexia has been found to be due to autosomal dominant mutations of the gene coding the $\alpha 1$ subunit of the inhibitory glycine receptor on chromosome 5q.⁵ These mutations reduce the efficacy of glycinergic inhibitory neurotransmission resulting in neural hyperexcitability.⁶ The mechanism underlying sporadic hyperekplexia is unknown although neurophysiological studies disclose similar patterns of muscle activation and latencies in both hereditary and symptomatic cases.¹ In our patient, the mechanism giving rise to the exaggerated startle is unknown; however, it is possible that abnormalities in glycinergic

neurotransmission resulting from brainstem pathology was responsible, a mechanism which could also account for the initial presentation with trismus.¹⁰

We thank Professor CD Marsden for helpful comments about the case.

- 1 Brown P, Rothwell JC, Thompson PD, *et al.* The hyperkplexias and their relationship to the normal startle reflex. *Brain* 1991;114:1903–28.
- 2 Brown P, Thompson PD, Rothwell JC, *et al.* A case of postanoxic encephalopathy with cortical action and brainstem reticular reflex myoclonus. *Mov Disord* 1991;6:139–44.
- 3 Hallett M, Chadwick D, Adam J, *et al.* Reticular reflex myoclonus: a physiological type of human post-hypoxic myoclonus. *J Neurol Neurosurg Psychiatry* 1977;40:253–64.
- 4 Matsumoto J, Hallett M. Startle syndromes. In: Fahn S, Marsden CD, eds. *Movement disorders 3*. London: Butterworth-Heinemann, 1994:418–33.
- 5 Shiang R, Ryan S, Zhu Y *et al.* Mutations in the α -1 subunit of the inhibitory glycine receptor cause the dominant neurological disorder, hyperkplexia. *Nat Genet* 1993;5:351–8.
- 6 Rajendra S, Lynch JW, Pierce KD, *et al.* Startle disease mutations reduce the agonist sensitivity of the human inhibitory glycine receptor. *J Biol Chem* 1994;269:1839–42.
- 7 Williamson LC, Fitzgerald SC, Neale EA. Differential effects of tetanus toxin on inhibitory and excitatory neurotransmitter release from mammalian spinal cord cells in culture. *J Neurochem* 1992;29:2148–57.
- 8 Jelasic F, Freitag V. Inverse activity of masticatory muscles with and without trismus: a brainstem syndrome. *J Neurol Neurosurg Psychiatry* 1978;41:798–804.
- 9 Struppler A, Struppler E, Adams RD. Local tetanus in man: its clinical and neurophysiological characteristics. *Arch Neurol* 1963;8:162–78.
- 10 Inoue T, Chandler SH, Goldberg LJ. Neuropharmacological mechanisms underlying rhythmical discharge in trigeminal interneurons during fictive mastication. *J Neurophysiol* 1994;71:2061–73.
- 11 Schwerdtfeger K, Jelasic F. Trismus in postoperative, posttraumatic and other brain stem lesions caused by paradoxical activity of masticatory muscles. *Acta Neurochir (Wien)* 1985;76:62–6.
- 12 D'Costa DF, Vania AK, Millac PA. Multiple sclerosis associated with trismus. *Postgrad Med J* 1990;66:853–4.
- 13 Lapresle J, Metreau R. Trigeminal involvement as the presentation of syringomyelia and of an abnormality of the occipito-vertebral junction. *Nouvelle Presse Medicale* 1978;7:103–4.
- 14 Sandyk R, Brennan MJ. Tuberculous meningitis presenting with trismus. *J Neurol Neurosurg Psychiatry* 1982;45:1070.
- 15 Verma A, Tandon PN, Maheshwari MC. Trismus caused by paradoxical activity of jaw-closing muscles in brain stem tuberculoma. *Oral Surgery Oral Medicine and Oral Pathology* 1988;65:675–8.
- 16 Bettoni L, Bortone E, Dascola I, *et al.* Unilateral trismus caused by vertebral basilar dolichoectasia. *Eur Neurol* 1993;33:382–6.
- 17 Leigh P, Rothwell J, Traub M, *et al.* A patient with reflex myoclonus and muscle rigidity: "jerking stiff-man syndrome". *J Neurol Neurosurg Psychiatry* 1980;43:1125–31.
- 18 Burn DJ, Ball J, Lees AJ, *et al.* A case of progressive encephalomyelitis with rigidity and positive antigliutamic acid decarboxylase antibodies. *J Neurol Neurosurg Psychiatry* 1991;54:449–51.
- 19 Kullmann DM, Howard RS, Miller DH, *et al.* Brainstem encephalopathy with stimulus sensitive myoclonus leading to respiratory arrest, but with recovery—a description of two cases and review of the literature. *Mov Disord* 1996;11:715–8.