

SHORT REPORT

Immunoglobulin therapy in inflammatory myopathies

F L Mastaglia, B A Phillips, P J Zilko

Abstract

A prospective open label trial of add on therapy with intravenous immunoglobulin (IVIg) was carried out in 16 patients with inflammatory myopathy who had continued to deteriorate or had relapsed on conventional therapy. The response was assessed using isometric myometry, functional scales, MRC grading, and serum creatine kinase concentrations with a three month run in period before commencement of IVIg. Five of seven patients with isolated dermatomyositis or polymyositis and all four patients with an overlap syndrome responded to IVIg with partial or complete remission of disease and normalisation of serum creatine kinase concentrations. None of five patients with inclusion body myositis showed any functional improvement although myometry scores improved in some muscles in one case. It is concluded that IVIg is an effective therapeutic option in patients with drug resistant polymyositis or dermatomyositis. However, further controlled trials are required to confirm the efficacy of this form of treatment and to establish optimal doses and administration regimes.

(J Neurol Neurosurg Psychiatry 1998;65:107-110)

Keywords: immunoglobulin therapy; inflammatory myopathies

Most patients with polymyositis or dermatomyositis have a favourable response to treatment with corticosteroids alone or in combination with another immunosuppressive agent and achieve a complete or partial remission.¹⁻² However, in some patients the disease remains active despite optimal immunosuppressive therapy and other therapeutic options need to be considered. High dose intravenous immunoglobulin (IVIg) is effective in the treatment of various immune mediated neurological and other disorders.³⁻⁶ There have been several reports of IVIg therapy in patients with inflammatory myopathies⁷⁻¹⁶ but experience with this treatment is still limited. Most reports have been based on uncontrolled studies in which IVIg was used as add on therapy in patients who had failed to respond adequately to other forms of treatment. The largest study was that of Cherin et al⁹ who reported marked improve-

ment in 15 of 20 patients with polymyositis or dermatomyositis. The only controlled trial in these groups of patients has been that of Dalakas et al¹² who showed a beneficial effect in 11 of 12 patients with drug resistant dermatomyositis who received IVIg in a double blind cross over trial. There have been few reports of IVIg therapy in patients with inclusion body myositis who, as a group, are usually resistant to corticosteroid and immunosuppressive therapy. Improvement was reported in one of two small uncontrolled trials¹³⁻¹⁶ and minor functional benefit was found in six of 19 patients in a recent placebo controlled trial.¹⁷

We report the results of a prospective open label trial of IVIg in 16 patients with different types of inflammatory myopathy.

Patients and methods

During 1990-6 we treated 66 patients with inflammatory myopathies in a specialty clinic at the Queen Elizabeth II Medical Centre. This group comprised 23 patients with isolated dermatomyositis, nine with isolated polymyositis, 18 with polymyositis and a systemic connective tissue disease (overlap syndromes), and 16 with inclusion body myositis. Sixteen of these patients, five with dermatomyositis, two with polymyositis, four with an overlap syndrome, and five with inclusion body myositis whose condition had not been adequately controlled by prednisolone or immunosuppressive agents and who continued to deteriorate or had relapsed were entered into the trial (table). The diagnosis was made on the basis of clinical features at presentation, increase in serum creatine kinase activity, and EMG, and was confirmed by muscle biopsy in all patients. Muscle MRI studies were not performed. None of the patients treated with IVIg were known to have an associated malignancy.

Immunoglobulin therapy was started with a five day course (30 g/day; about 2 g/kg) followed by monthly three day courses (30 g/day; about 1.2 g/kg). Treatment was continued until there was no further improvement and the patient's condition remained stable over two successive monthly assessments, or for a minimum of two courses if there was no improvement. Either Intragam (Commonwealth Serum Laboratories, Australia) or Sandoglobulin (Sandoz) was used according to availability. Patients were seen regularly in the clinic before, during, and after IVIg therapy and underwent the following assessments:

Australian Neuromuscular Research Institute, University Department of Medicine and Departments of Neurology and Clinical Immunology, Queen Elizabeth II Medical Centre, Perth WA 6009, Australia
 F L Mastaglia
 B A Phillips
 P J Zilko

Correspondence to: Professor FL Mastaglia, Department of Medicine, Queen Elizabeth II Medical Centre, Nedlands WA 6009, Australia.

Received 28 May 1997 and in final revised form 26 November 1997
 Accepted 28 November 1997

Details of 16 patients treated with intravenous immunoglobulin (IVIg) and response to treatment

Case	Diagnosis	Duration (y)	Concurrent therapy	IVIg courses	Functional improvement	Change in MRC grades	Change in myometer score(%)†	Serum CK	
								Before IVIg	After IVIg
1 M 78 y	DM	1	Pred MTX CyA	2	-	-	+20.9 (NS)	253	134
2 F 68 y	DM	6	Pred MTX	3	+	+	NP	1932	29
3. F 45 y	DM	1	Pred Aza MTX PMP	10	-	-	+4.9 (NS)	324	127
4 F 35 y	DM	<1	Pred MTX	2	+	+	NP	1230	256
5 F 45 y	DM	<1	Pred MTX	1 + 3	+	+	+33.4	637	56
6 F 31 y	PM	8	Pred	6	+	+	+27.7	207	77
7 M 82 y	PM	2	Pred	1	-	-	NP	166	196
8 M 52 y	PM/SS	1	Pred Pen	8	+	+	+30.0	400	88
9 F 31 y	PM/SS	12	Pred Aza	11	+	+	+26.6	7832	184
10 F 18 y	PM/SLE	1	Pred Aza	3	+	+	+53.4	6210	189
11 F 41 y	PM/SS	6	Pred MTX	10	+	+	NP	1532	198
12 M 79 y	IBM	16	Pred	6	-	-	-12.3	107	NP
13 M 65 y	IBM	6	Nil	3	-	-	-1.9 (NS)	460	910*
14 M 69 y	IBM	17	Pred	3	-	-	+10.1 (NS)	326	374
15 F 63 y	IBM	10	Pred	6	-	-	+19.2 (NS)	61	183
16 M 75 y	IBM	5	Nil	2	-	-	-26.8	49	830*

DM=dermatomyositis; Pred=prednisolone; NS=not significant at $p<0.05$; PM=polymyositis; MTX=methotrexate; NP=not performed; SS= progressive systemic sclerosis; CyA=cyclosporin A; CK=creatine kinase; IBM - inclusion body myositis; Pen=penicillamine; SLE=systemic lupus erythematosus; Aza = azathioprine.

*Prednisone therapy stopped shortly before start of IVIg.

†Mean score for right and left shoulder abductors, elbow extensors, hip flexors and knee extensors.

- (1) bilateral measurements of isometric muscle strength in the shoulder abductors, elbow extensors, hip flexors, and knee extensors were performed by the same experienced examiner (BAP) using a Penny and Giles myometer.^{1,2} The force in Newtons for these muscle groups was averaged and the mean percentage change before IVIg and after IVIg was calculated. A paired *t* test was performed to determine the statistical significance of changes after IVIg.
- (2) Bilateral grading of the same muscle groups was carried out using a 10 level modified MRC scale. A change of at least one level in at least four muscle groups was required to record an improvement in MRC grades.
- (3) The ability to stand up from the sitting position without using the hands, to rise from the squatting position, and to climb stairs was measured, and a 30 m walk was timed.
- (4) Serum creatine kinase activity was measured.

Data from at least three assessments before commencement of IVIg therapy were available in all patients. Immunoglobulin concentrations were measured before starting therapy to exclude IgA deficiency. Patients continued on their previous corticosteroid and immunosuppressive therapy during the IVIg treatment (table).

Results

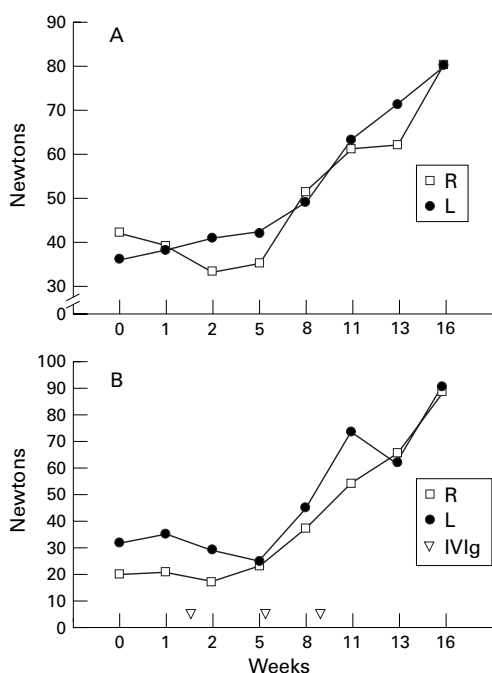
DERMATOMYOSITIS

Four of the five patients with dermatomyositis improved as shown by an increase in MRC grades, an improvement in functional abilities (for example, rising from a chair or from the

squatting position, walking time) and a fall in serum creatine kinase (table). In patient 1, in whom IVIg was given 18 months after the onset of the illness because of continued deterioration on a combination of prednisolone and methotrexate, there were improvements in myometric scores in several limb muscles by nine days after the first course of IVIg but by three weeks the patient's condition had again deteriorated and there was no response to a further course of IVIg. In patient 4, in whom IVIg was given early in the illness, and in patient 2 in whom therapy was started after a relapse six years after the onset of the illness, there was a gradual improvement in MRC grades and functional abilities and fall in serum creatine kinase over a two to three month period after the introduction of IVIg. In patient 5 the initial IVIg course was complicated by staphylococcal septicaemia which led to further deterioration in muscle function. However, gradual improvement in the patient's severe muscle weakness and skin changes occurred after a further three courses of IVIg six months later. In one patient (3) with severe drug resistant dermatomyositis IVIg was started one year after the onset of the illness with no benefit and the patient's condition continued to deteriorate leading to death (table).

POLYMYOSITIS

Of the two patients with isolated polymyositis, one (6) in whom IVIg was added at the time of a relapse eight years after the onset of her illness, showed progressive improvement in MRC grades, functional abilities, myometric scores, and serum creatine kinase concentrations over a six month period of therapy. In the other patient (7) there was no improvement



Patient 10. Polymyositis and systemic lupus erythematosus. Improvement in isometric force (Newtons) in the elbow extensors (A) and the hip extensors (B) after commencement of IVIg. Doses of other medications (prednisolone and azathioprine) were unchanged. L=Left; R=right.

after a single five day course of IVIg. This was complicated by the occurrence of a mild cortical stroke and therapy was therefore discontinued.

OVERLAP SYNDROMES

All four patients with overlap syndromes improved with IVIg therapy (table). In all the improvement was gradual over a period of three to nine months and was manifest as an improvement in MRC grades and myometric scores (figure) as well as significant functional improvement. In one (10), treatment was administered early in the illness, while in the others it was commenced later at the time of a relapse and in one patient (8) after an adverse systemic reaction to methotrexate.

INCLUSION BODY MYOSITIS

Each of the five patients with inclusion body myositis had longstanding disease of five to 17 years duration and were incapacitated mainly because of quadriceps and hand weakness as well as more widespread limb weakness. In none of the five patients was there any improvement in functional abilities or MRC grades of any of the affected muscle groups with IVIg. However, in one patient (15) there was a progressive improvement in myometric scores in some less severely affected muscle groups such as the shoulder abductors and wrist extensors.

ADVERSE REACTIONS

Minor adverse reactions occurred in five of the 16 patients: local erythema in two, itching in one, erythematous rash in one, and headache in one. More serious complications occurred

after the first course of treatment in two patients: a mild cortical stroke resulting in transient aphasia and right upper limb weakness in one (7) and staphylococcal septicaemia in another (5), resulting in cessation of IVIg therapy.

Discussion

Although the present trial was not placebo controlled, an attempt was made to assess the response to treatment with a combination of myometry and MRC grading. In addition, quantitative assessments were carried out on at least three occasions during a three month run in period before commencement of IVIg providing a baseline for comparison with subsequent assessments.

A limitation of this study was the need to continue prednisolone and other immunosuppressive agents during the period of IVIg therapy making it difficult to be certain of the extent to which any improvement was attributable to the IVIg itself. However, in view of the fact that all patients in the trial had failed to respond adequately to their previous treatment and that there was objective evidence of continued deterioration during the run in period, it seems reasonable to attribute improvement after the introduction of IVIg to the effects of that therapy or to the combined effects of IVIg and concurrent immunotherapy. It is relevant that IVIg alone was not found to be effective when used as initial treatment in an open study of 11 patients with polymyositis or dermatomyositis.¹⁴ IVIg may therefore be more effective in patients who have already had or are on concurrent corticosteroid or other immunosuppressive therapy.

The best response to IVIg in the present study was in patients with an overlap syndrome all of whom showed a clear-cut and sustained improvement after IVIg therapy. The response was more variable in patients with isolated dermatomyositis or polymyositis, four of whom showed objective improvement in muscle strength and a fall in serum creatine kinase which usually returned to normal. In the other three patients there was continued deterioration despite IVIg therapy.

Patients with inclusion body myositis did not gain any functional benefit with IVIg although myometric scores improved in some of the less severely affected muscle groups in one patient. Our experience with such patients confirms the conclusions reached by Dalakas *et al*⁷—namely, that whereas regional improvement in certain muscle groups may occur in some patients, the degree of functional benefit is minor and does not justify the routine use of this expensive form of treatment. It is possible that the lack of response in our patients was due to the fact that their disease was very longstanding (average duration 10 years) and it remains to be determined whether IVIg may be more effective if administered earlier in the course of the disease.

The doses of IVIg and the regimes used have varied in different studies and there are as yet no reliable guidelines as to the optimal administration regime or minimal effective doses. In

the present study we have used a protocol commencing with an initial five day (about 2 g/kg) course as has been used in most previous trials in patients with inflammatory myopathies and other disorders^{4,5} followed by monthly three day (about 1.2 g/kg) courses as it has been suggested in some previous studies of patients with dermatomyositis¹⁰ and chronic inflammatory demyelinating polyneuropathy⁵ that lower doses may be effective. We have not evaluated the efficacy of smaller doses of IVIg or of longer intervals between courses. In our experience in patients with polymyositis or dermatomyositis, improvement may commence after the first or second course of IVIg but in some cases is not apparent until after the third course. We would recommend that if there is no improvement after the third course of treatment it is reasonable to discontinue therapy.

Whereas IVIg is generally considered to be a safe form of treatment, adverse reactions may occur and have been discussed in recent reports based on the use of IVIg in large series of patients with neurological disorders.^{18,19} In our smaller series only two serious reactions occurred with 80 courses of IVIg, one a mild stroke and the other a case of staphylococcal septicaemia presumably due to a contaminated venous access site. The risk of precipitating a thromboembolic event is particularly important in elderly patients and is related to the effects of IVIg on plasma viscosity.^{20,21} The risk may be reduced by using lower doses of immunoglobulin and slower rates of administration. More rapid administration of the standard dose of immunoglobulin over a shorter period of one to two days rather than three days should be avoided for this reason, particularly in elderly patients.

Immunoglobulin therapy may exert its effect in various ways. In dermatomyositis improvement has been found to correlate with dissolution of deposits of C5b-9 and a reduction in ICAM-1 expression in muscle capillaries and it has been suggested that IVIg blocks the formation and deposition of the membrane attack complex by inhibiting the deposition of activated C4b and C3b fragments.^{5,22} Other possible mechanisms include binding of anti-idiotypic antibodies to circulating autoantibodies or B cells, suppression of T cell mediated responses, blockade of macrophage Fc receptors, and inhibition of myotoxic cytokines.^{5,6}

In conclusion, our findings indicate that IVIg can be effective as third line therapy in the treatment of patients with dermatomyositis, polymyositis, or overlap syndromes whose disease is not adequately controlled by corticosteroids and other immunosuppressive agents

but is not usually effective in patients with inclusion body myositis. Further controlled trials are required to refine the guidelines for the use of IVIg in the inflammatory myopathies and to establish the optimal therapeutic regimes and minimal effective doses of this expensive form of therapy.

We acknowledge financial support from the Neuromuscular Foundation of Western Australia and are grateful to Professor BA Kakulas and Dr V Fabian from the Department of Neuropathology, Royal Perth Hospital who performed the diagnostic histopathological studies, and to Mrs S Moncrieff for secretarial assistance.

- Mastaglia FL, Laing BA, Zilko P. Treatment of inflammatory myopathies. In: F L Mastaglia, ed. *Inflammatory myopathies*. Baillière's clinical neurology. London: Baillière Tindell, 1993:717-40.
- Mastaglia FL, Phillips BA, Zilko P. Treatment of inflammatory myopathies. *Muscle Nerve* 1997;20:651-64.
- Otten A, Vermeulen M, Bossuyt PMM. Intravenous immunoglobulin treatment in neurological diseases. *J Neurol Neurosurg Psychiatry* 1995;59:359-61.
- Van der Meche FGA, Van Doorn PA. The current place of high-dose immunoglobulins in the treatment of neuromuscular disorders. *Muscle Nerve* 1997;20:136-47.
- Dalakas MC. Intravenous immune globulin therapy for neurologic diseases. *Ann Intern Med* 1997;126:721-30.
- Dwyer JM. Manipulating the immune system with immune globulin. *N Engl J Med* 1992;326:107-16.
- Roifman CM, Schaffer FM, Wachsmuth SE, et al. Reversal of chronic polymyositis following intravenous immune serum globulin therapy. *JAMA* 1987;258:513-5.
- Mastaglia FL, Zilko P, Laing B, et al. Immunoglobulin therapy in patients with inflammatory myopathies. *Aust NZ J Med* 1991;21(suppl 2):607.
- Cherin P, Herson S, Wechsler B, et al. Efficacy of intravenous gammaglobulin therapy in chronic refractory polymyositis and dermatomyositis: an open study with 20 adult patients. *Am J Med* 1991;91:162-8.
- Lang BA, Laxen RM, Murphy G, et al. Treatment of dermatomyositis with intravenous gammaglobulin. *Am J Med* 1991;91:169-72.
- Jann S, Beretta S, Maggio M, et al. High-dose intravenous human immunoglobulin in polymyositis resistant to treatment. *J Neurol Neurosurg Psychiatry* 1992;55:60-2.
- Dalakas MC, Illa I, Dambrosia JM, et al. A controlled trial of high-dose intravenous immune globulin infusions and treatment for dermatomyositis. *N Engl J Med* 1993;329:1993-2000.
- Soueidan SA, Dalakas MC. Treatment of inclusion body myositis with high-dose intravenous immunoglobulin. *Neurology* 1993;43:876-9.
- Cherin P, Piette JC, Wechsler B, et al. Intravenous gamma globulin as first line therapy in polymyositis and dermatomyositis: an open study in 11 adult patients. *J Rheumatol* 1994;21:1092-7.
- Reimold AM, Weinblatt ME. Tachyphylaxis of intravenous immunoglobulin in refractory inflammatory myopathy. *J Rheumatol* 1994;21:1144-6.
- Amato AA, Barohn RJ, Jackson CE, et al. Inclusion body myositis: treatment with intravenous immunoglobulin. *Neurology* 1996;44:1516-8.
- Dalakas MC, Sonies B, Dambrosia J, et al. Treatment of inclusion body myositis with IVIg: a double-blind placebo-controlled study. *Neurology* 1997;48:712-6.
- Bertorini TE, Nance AM, Horner LH, et al. Complications of intravenous gammaglobulin in neuromuscular and other diseases. *Muscle Nerve* 1996;19:388-91.
- Brannagan TH, Nagle KJ, Lange DJ, et al. Complications of intravenous immune globulin treatment in neurologic disease. *Neurology* 1996;47:674-7.
- Silbert PL, Knezvic WV, Bridge DT. Cerebral infarction complicating intravenous immunoglobulin therapy for polyneuritis cranialis. *Neurology* 1992;42:257-8.
- Dalakas MC. High-dose intravenous immunoglobulin and serum viscosity: risk of precipitating thromboembolic events. *Neurology* 1994;44:223-6.
- Basta M, Dalakas MC. High-dose intravenous immunoglobulin exerts its beneficial effect in patients with dermatomyositis by blocking endomysial deposition of activated complement fragments. *J Clin Invest* 1994;94:1729-35.