

SHORT REPORT

## Spinocerebellar ataxia type 6 with positional vertigo and acetazolamide responsive episodic ataxia

Joanna C Jen, Qing Yue, Juliana Karrim, Stanley F Nelson, Robert W Baloh

**Abstract**

**The SCA6 mutation, a small expansion of a CAG repeat in a calcium channel gene CACNA1A, was identified in three pedigrees. Point mutations in other parts of the gene CACNA1A were excluded and new clinical features of SCA6 reported—namely, central positional nystagmus and episodic ataxia responsive to acetazolamide. The three allelic disorders, episodic ataxia type 2, familial hemiplegic migraine, and SCA6, have overlapping clinical features.**

(J Neurol Neurosurg Psychiatry 1998;65:565-568)

Keywords: SCA6; spinocerebellar ataxia; hereditary ataxia; calcium channel

Episodic ataxia type 2 (EA-2) is an autosomal dominant disorder characterised by episodes of ataxia lasting hours to days with interictal nystagmus. Precipitated by physical exertion or emotional stress, the episodes are often dramatically responsive to acetazolamide.<sup>1</sup> Symptoms typically begin before the age of 20; some patients later develop a gradually progressive cerebellar ataxia.

In two families with EA-2 and four families with familial hemiplegic migraine (FHM), point mutations were identified in CACNA1A (formerly known as CACNL1A4), which maps to chromosome 19p and codes for the human neuronal voltage dependent calcium channel  $\alpha_{1A}$  subunit.<sup>2</sup> Zhuchenko *et al*<sup>3</sup> reported an association (later confirmed by others<sup>4</sup>) between small CAG expansions (repeat numbers 21-27 compared with 4-16 in controls) in CACNA1A and a late onset dominantly inherited ataxic syndrome, which they named spinocerebellar ataxia type 6 (SCA6). They did not report episodic features or response to acetazolamide in their patients. In addition, mutations elsewhere in the gene were not excluded so that it is possible that point mutations in other parts of the gene rather than the expanded CAG repeats determined the clinical syndrome.

We now report new clinical features in three families with an expanded CAG repeat in CACNA1A (SCA6) and exclude point muta-

tions in other parts of CACNA1A. SCA6 has clinical features that overlap with those of EA-2.

**Case reports**

The study was approved by our institutional review board and informed consent was obtained from all subjects. The pedigrees are shown in the figure.

**PEDIGREE 1**

This family was previously reported as an atypical EA-2 linked to chromosome 19p (family 4).<sup>5</sup> The type of mutation was unknown. The proband began having episodes of dizziness and ataxia at the age of 42. She also noted positional vertigo so that she slept propped up with pillows. About a year later, she noticed mild interictal imbalance. Initial examination disclosed a central type of positional nystagmus (conjugate downbeat nystagmus that did not fatigue with repeated positioning). Tandem walking was impaired, but limb coordination was normal. Acetazolamide markedly decreased the episodes of dizziness and ataxia, but follow up examination still showed downbeat positional nystagmus and mild truncal ataxia. She has taken 250 mg acetazolamide twice daily for three years with continued good response.

Four of five living affected family members reported episodes of ataxia in addition to a slowly progressive ataxia. Old records documented that the proband's father initially presented at the age of 45 with positional vertigo, followed by episodic and progressive ataxia. The proband's great aunt and her daughter (II-3, III-6) reported episodes typical of basilar migraine beginning in their teens and spontaneously disappearing in their late 20s.

**PEDIGREE 2**

The proband presented at age 56 reporting positional vertigo since the age of 50, episodes of dizziness and ataxia since the age of 51, and mildly progressive ataxia beginning at the age of 55. Examination showed slight downbeat nystagmus on lateral gaze, prominent positional downbeat nystagmus with vertigo, and mild truncal ataxia. Brain MRI showed moderate vermian atrophy. Acetazolamide (250

**Department of Neurology**

J C Jen  
Q Yue  
J Karrim  
R W Baloh

**Department of Pediatrics/Hematology and Oncology**

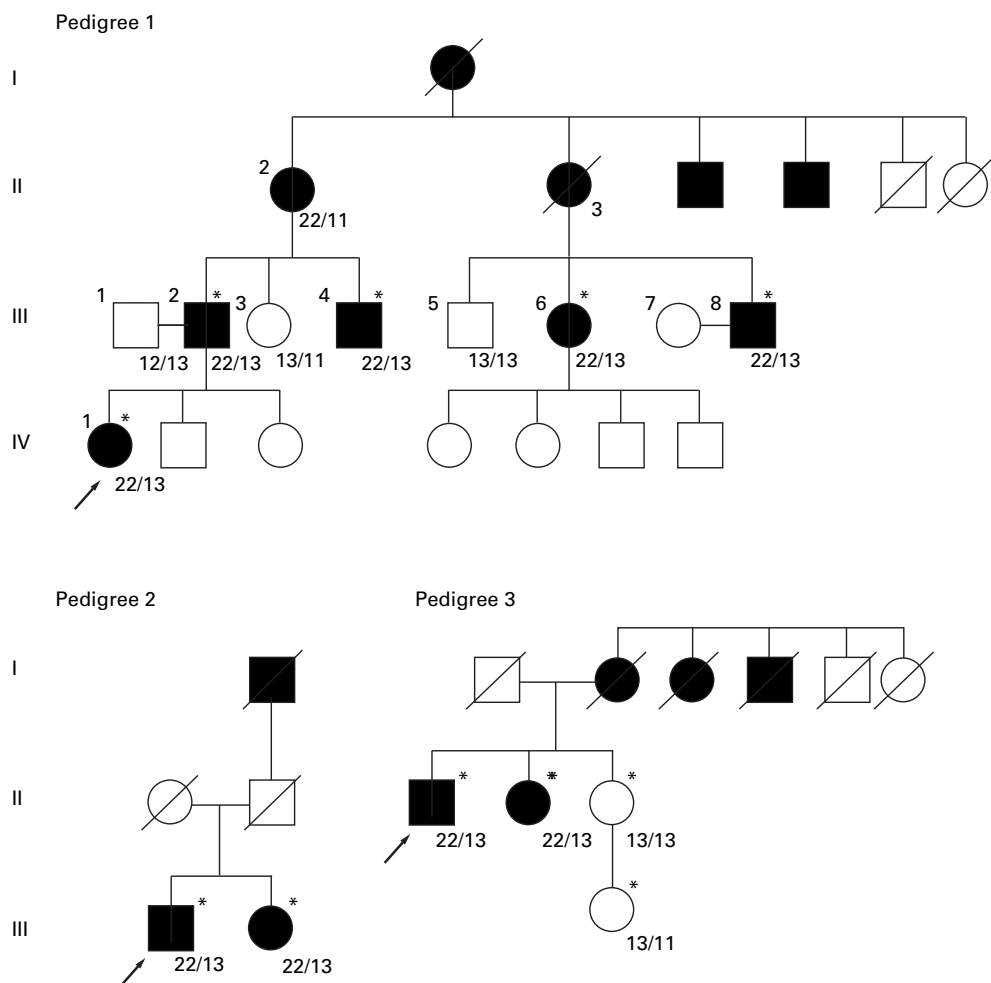
Stanley F Nelson

**Department of Surgery (Head and Neck), UCLA School of Medicine, Los Angeles, California, USA**

R W Baloh

Correspondence to:  
Dr Robert W Baloh, UCLA  
Department of Neurology,  
Box 951769, Los Angeles,  
CA 90095-1769, USA.  
Telephone 001 310 825  
5910; fax 001 310 206 1513;  
email:rwbaloh@ucla.edu

Received 18 December 1997  
and in revised form  
9 March 1998  
Accepted 19 March 1998



Three pedigrees identified with SCA6. \*Examined; arrow=proband; CAG repeat numbers for both alleles for those tested are as indicated.

mg/day) initially stopped his episodes of ataxia. After six months, the episodes began recurring. Increasing the dose to 500 mg/day again stopped the attacks, but they began recurring about six months later. He is now maintained on 750 mg/day with only infrequent episodes. The central positional nystagmus and interictal mild ataxia are unchanged on acetazolamide.

The proband's 63 year old sister reported an almost identical history of positional vertigo and spontaneous episodes of ataxia beginning in her early 50s, followed by progressive ataxia a few years later. She has used a cane since 1993. Her examination disclosed downbeat nystagmus on lateral gaze, prominent positional downbeat nystagmus, slurring of speech, and truncal and appendicular ataxia.

#### PEDIGREE 3

The proband, age 65, recalled having positional vertigo dating back to his late teens. He had to stop playing American football in high school because he developed severe vertigo when pinned to the ground. He slept propped up and avoided lying flat. He noticed fatigability and a gradual deterioration in balance in his early 50s without much fluctuation in his symptoms. Examination disclosed gaze evoked nystagmus on lateral gaze, downbeat positional nystagmus,

truncal ataxia, and increased muscle tone with hyperreflexia. He tried acetazolamide for about a month but reported no benefit. Brain MRI showed mild vermian atrophy.

The proband's 72 year old sister considered herself normal but did admit to occasional positional dizziness so that she slept with several pillows. On examination, she had slight horizontal gaze evoked nystagmus, prominent downbeat positional nystagmus, and mildly impaired tandem walking.

#### Genetic studies

CAG repeat expansions in CACNA1A were identified by 4% agarose or 10% polyacrylamide gel electrophoresis of polymerase chain reaction (PCR) amplified fragments using primers flanking the CAG repeat region.<sup>3-6</sup> The number of repeats for both the expanded and the normal alleles in IV-1 of pedigree 1 and III-1 in pedigree 2 were ascertained by electrophoresis in denaturing polyacrylamide gels and compared with a sequencing ladder.<sup>6</sup> Genetic analysis showed CAG repeat expansion to 22 in one allele, with 13 repeats in the normal allele. DNA from these two patients were used as positive controls for each set of PCR and gel electrophoresis. The repeat expansion cosegregated with phenotype (figure).

All 47 exons and flanking introns were subjected to single strand conformational polymorphism analysis (SSCP)<sup>7,8</sup> of PCR amplified genomic DNA from IV-1 and III-2 in pedigree 1, III-1, and III-2 in pedigree 2. No aberrantly migrating fragments compared with unaffected relatives or 15 unrelated controls were identified.<sup>2-6</sup>

### Discussion

We confirmed in three pedigrees an association between a small CAG repeat expansion in CACNA1A and late onset slowly progressive ataxia SCA6.<sup>3</sup> CAG repeat expansion to 22 cosegregated with affected persons in these pedigrees. No other mutation was identified in the coding sequence of CACNA1A by SSCP, a method that has been successfully applied to screen for mutations in various hereditary disorders including familial hemiplegic migraine and episodic ataxia.<sup>2-6</sup> Therefore, CAG repeat expansion in CACNA1A likely caused ataxia in these patients.

Furthermore, we identified two new clinical features in patients with SCA6: positional vertigo with central positional nystagmus and episodic ataxia responsive to acetazolamide. In several of these patients; the onset of positional vertigo and nystagmus preceded the onset of gait difficulty by many years. We think that this is the first report of a genetic cause for central positional nystagmus. The early manifestation of downbeat nystagmus would suggest relatively selective involvement of the flocculus.<sup>9</sup> Indeed, despite uniform expression of the  $\alpha_{1A}$  gene in the cerebellum, a restricted pattern of cerebellar degeneration has been found in tottering and leaner mice, which are mutant mice with ataxia and epilepsy recently found to have mutations in the mouse analogue of CACNA1A.<sup>10</sup> Detailed anatomical definition may clarify whether there is region specific or age specific alternative splicing favouring the longer splice variants containing the CAG repeats, thus rendering the cells in the flocculus particularly susceptible to pathological changes associated with the inclusion of expanded polyglutamine tracts in the calcium channel  $\alpha_{1A}$  subunit. Differential expression of the auxiliary subunits may affect the calcium channel activity. Cell specific modulators, such as kinases and phosphatases, of the calcium channel could also contribute to the restricted expression of this genetic mutation.

Similar to patients with EA-2, our patients reported episodes of dizziness and ataxia precipitated by stress and fatigue. These episodes were superimposed on a slowly progressive decline in baseline function. Such episodes may result from transient impairment of channel function triggered by environmental factors. The progressive neuronal degeneration is likely due to chronic excess calcium entry leading to an increase in intracellular calcium ultimately leading to cell death. Polyglutamines in the C-terminus of the calcium channel  $\alpha_{1A}$  subunit may affect normal voltage dependent or calcium dependent inactivation of the channel complex. Furthermore, they could interfere

with normal modulatory interactions with kinases, G proteins, complex formation, and cytoskeletal elements.

The clinical benefit of acetazolamide is presumably mediated by increasing the extracellular concentration of free protons in the cerebellum.<sup>11</sup> Calcium channels are sensitive to changes in pH: protons reduce the unitary conductance and channel open probability.<sup>12</sup> The molecular mechanism of proton block of voltage gated calcium channels was recently shown to involve a protonation site within the pore that is critical for calcium ion permeability.<sup>13</sup> Acetazolamide likely stabilises the transient dysfunction of mutant calcium channels by acidification.

Although many clinical features were common in the three pedigrees, clinical heterogeneity was found. Episodic features were prominent in pedigrees 1 and 2 but not in pedigree 3. Members of pedigree 1 experienced basilar migraine-like attacks, which are common in pedigrees with FHM.<sup>14</sup> Members of pedigrees 1 and 3 exhibited interictal hyperreflexia and spasticity, extracerebellar signs commonly seen with other SCA syndromes. Additional genetic or environmental factors must account for the clinical variability within pedigrees and among different pedigrees with the same genetic defects.

That the stable CAG repeat expansion in CACNA1A is associated with a phenotype similar to that in patients with point mutations in the same gene suggests that the incorporation of additional glutamines alters the channel function as would a missense mutation leading to an amino acid substitution. Indeed, a point mutation in CACNA1A with a predicted change in a highly conserved amino acid residue in the critical pore region results in a severe progressive ataxia syndrome.<sup>6</sup> We anticipate identification of other phenotypes associated with novel mutations in CACNA1A. Furthermore, analysis of the mutant calcium channels will undoubtedly disclose new functional domains within the channel.

This work was supported by NIH grants AG9063, P01 DC02952, and DC00008-21.

- 1 Griggs RC, Moxley RT, Lafrance RA, *et al.* Hereditary paroxysmal ataxia: response to acetazolamide. *Neurology* 1978;**28**:1259-64.
- 2 Ophoff RA, Terwindt GS, Vergouwe MN, *et al.* Familial hemiplegic migraine and episodic ataxia type-2 are caused by mutations in the  $\text{Ca}^{2+}$  channel gene CACNL1A4. *Cell* 1996;**87**:543-52.
- 3 Zhuchenko O, Bailey J, Bonnen P, *et al.* Autosomal dominant cerebellar ataxia (SCA6) associated with small polyglutamine expansions in the  $\alpha_{1A}$ -voltage-dependent calcium channel. *Nat Genet* 1997;**15**:62-9.
- 4 Zoghbi HY. CAG repeats in SCA6: anticipating new clues. *Neurology* 1997;**49**:1196-9.
- 5 Baloh RW, Yue Q, Furman JM, *et al.* Familial episodic ataxia: clinical heterogeneity in four families linked to chromosome 19p. *Ann Neurol* 1997;**41**:8-16.
- 6 Yue Q, Jen JC, Nelson SF, *et al.* Progressive ataxia due to a missense mutation in a calcium channel gene. *Am J Hum Genet* 1997;**61**:1078-87.
- 7 Orita M, Iwahana H, Kanazawa H, *et al.* Detection of polymorphisms of human DNA by gel electrophoresis as single-strand conformation polymorphisms. *Proc Natl Acad Sci USA* 1989;**86**:2766-70.
- 8 Ravnik-Glavak M, Glavak D, Dean M. Sensitivity of single-strand conformation polymorphism and heteroduplex method for mutation detection in the cystic fibrosis gene. *Hum Molec Genet* 1994;**3**:801-7.
- 9 Zee DS, Yamazaki A, Butler PH, *et al.* Effects of ablation of flocculus and paraflocculus on eye movements in primate. *J Neurophysiol* 1981;**46**:878-99.

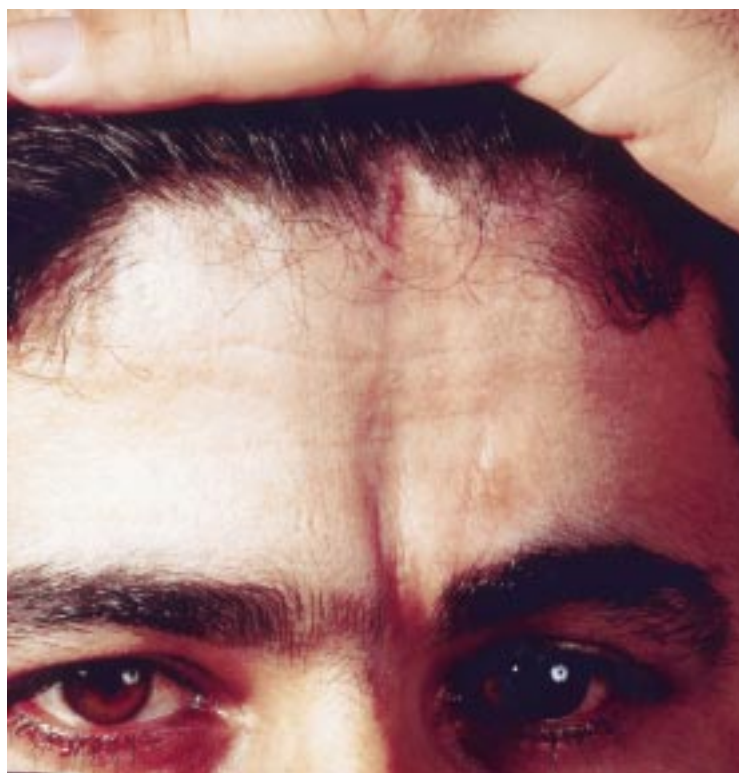- 10 Fletcher CF, Lutz CM, O'Sullivan TN, et al. Absence epilepsy in tottering mutant mice is associated with calcium channel defects. *Cell* 1996;87:607-17.
- 11 Bain PG, O'Brien MD, Keevil F, et al. Familial periodic cerebellar ataxia: a problem of cerebellar intracellular pH homeostasis. *Ann Neurol* 1992;31:147-54.
- 12 Prod'hom B, Pietrobon D, Hess P. Direct measurement of proton transfer rates to a group controlling the dihydropyridine-sensitive  $Ca^{2+}$  channel. *Nature* 1987;329:243-6.
- 13 Chen X-h, Bezprozvanny I, Tsien RW. Molecular basis of proton block of L-type  $Ca^{2+}$  channels. *J Gen Physiol* 1996;108:363-74.
- 14 Haan J, Terwindt GM, Ophoff RA, et al. Is familial hemiplegic migraine a form of basilar migraine? *Cephalgia* 1995;15:477-81.

---

## NEUROLOGICAL PICTURE

---

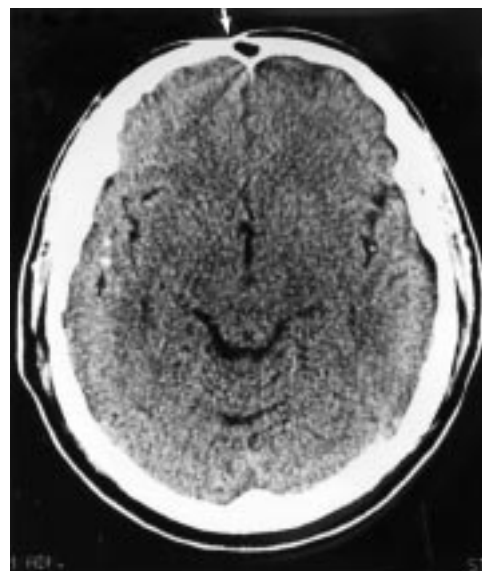
### A "scar" and epilepsy: coup de sabre



A

A 28 year old man of Turkish descent had a five year history of monthly nocturnal epileptic attacks. Physical examination disclosed a linear, atrophic, brownish skin area on the left forehead just lateral to the midline. The lesion extended from the left superior orbital ridge into the scalp and was associated with hair loss. There was no facial hemiatrophy (figure A). Neurological examination disclosed no abnormalities. EEG was normal. Brain CT showed small intracranial calcifications in the left temporal lobe and loss of subcutaneous tissue at the site of the lesion (arrows) without involvement of skull bone (figure B). Brain MRI was normal.

If, as in our patient, the history is unclear, this lesion can be mistaken for a scar. However, it is typical of linear scleroderma en coup de



B

sabre, a rare form of localised scleroderma. This is often associated with neurological symptoms, especially epilepsy. Intracranial calcifications or white matter abnormalities can occur. Because the pathogenesis is still unknown, it remains a matter of debate whether cerebral involvement in linear scleroderma en coup de sabre is a consequence of an inflammatory process or constitutes a neurocutaneous syndrome.<sup>1,2</sup>

R F DUYFF  
J VOS

Department of Neurology, St Lucas Andreas Ziekenhuis,  
Jan Tooropstraat 164, 1061 AE Amsterdam,  
The Netherlands

Correspondence to: Dr R F Duyff, Department of Neurology, St Lucas Andreas Ziekenhuis, Jan Tooropstraat 164, 1061 AE Amsterdam, The Netherlands. Telephone 0031 20 5108320; fax 0031 20 6837024.

- 1 Chung MH, Sum J, Morrell MJ, et al. Intracerebral involvement in scleroderma en coup de sabre: report of a case with neuropathologic findings. *Ann Neurol* 1995;37:679-81.
- 2 Pupillo G, Andermann F, Dubeau F. Linear scleroderma and intractable epilepsy: neuropathologic evidence for a chronic inflammatory process. *Ann Neurol* 1996;39:277-8.