

## SHORT REPORT

## Transient amnesia after perimesencephalic haemorrhage: the role of enlarged temporal horns

Jeannette W Hop, Eva H Brilstra, Gabriel J E Rinkel

### Abstract

**Objectives**—Although long term outcome of patients with perimesencephalic haemorrhage, a benign subset of subarachnoid haemorrhage, is excellent, some patients report an episode of amnesia for the first hours to days after the ictus. The relation between the occurrence of amnesia and the size of the ventricles on CT, including the temporal horns, were studied in patients with perimesencephalic haemorrhage.

**Methods**—Twenty seven consecutive patients with perimesencephalic haemorrhage were asked about the occurrence of amnesia. Age adjusted bicaudate indices and third ventricle sizes were calculated. Linear measurements of the temporal horn were taken in three directions: anterior-posterior, medial-lateral, and oblique. Additionally, enlargement of the temporal horns was assessed with the “naked eye”.

**Results**—Ten of the 27 patients reported an episode of transient amnesia; in these patients the mean sizes of the temporal horns were larger than in patients without amnesia, ranging from a factor of 1.7 for the medial-lateral measurement to a factor of 2.3 for the anterior-posterior measurement. Most of the patients with amnesia had relative bicaudate indices and relative third ventricle sizes  $> 1$ , and all had enlarged temporal horns at “naked eye” assessment.

**Conclusion**—About one third of patients with perimesencephalic haemorrhage have an episode of amnesia shortly after the bleed. The occurrence of amnesia is associated with enlargement of the temporal horns, and might be explained by temporary hippocampal dysfunction.

(J Neurol Neurosurg Psychiatry 1998;65:590-593)

Keywords: perimesencephalic haemorrhage; amnesia; hydrocephalus; temporal horn

Perimesencephalic haemorrhage, a subset of spontaneous subarachnoid haemorrhage, is characterised by relatively mild symptoms at onset, accumulation of the extravasated blood in the cisterns around the midbrain, and absence of an aneurysm on a four vessel angiography.<sup>1-3</sup> Rebleeding or cerebral ischaemia never occur, but initial CT shows enlarged ventricles in 25% of patients.<sup>4</sup> Clinically, even

the very few patients who deteriorate from acute hydrocephalus completely recover,<sup>5</sup> and the long term outcome after perimesencephalic haemorrhage is excellent.<sup>6,7</sup> Nevertheless, on outpatient follow up many patients reported an episode of amnesia which started a few hours after the onset of the bleed and lasted for several hours or days.

In a consecutive series of patients with perimesencephalic haemorrhage we studied the frequency and duration of amnesia and the relation between the occurrence of amnesia and the size of the ventricles, including the temporal horns, on initial CT.

### Patients and methods

#### PATIENTS

We studied all patients with perimesencephalic haemorrhage who were admitted to the University Hospital in Utrecht between January 1989 and June 1995. Criteria for the diagnosis were: (1) symptoms and signs of spontaneous subarachnoid haemorrhage; (2) initial CT made within 72 hours of the first symptoms, with a perimesencephalic pattern of haemorrhage<sup>2</sup>; and (3) no aneurysm detectable on a four vessel angiography.

During the initial days of stay in hospital, all patients were under continuous observation in a medium care unit; the level of consciousness was assessed each hour by means of the Glasgow coma scale.

At the time of follow up, all patients were personally interviewed by one of us (EHB), and specifically asked about the presence and time course of amnesia. During follow up, EHB was unaware of the findings on CT.

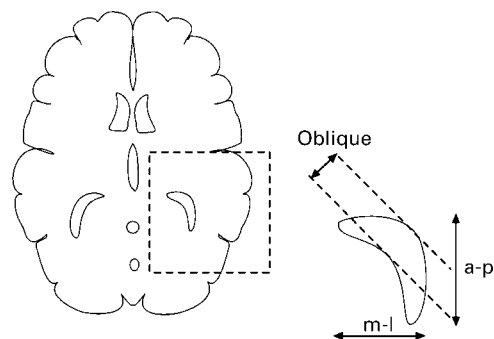


Figure 1 Measurement of the temporal horn in three directions: anterior-posterior (a-p), medial-lateral (m-l), and oblique.

University  
Department of  
Neurology, Utrecht,  
The Netherlands

J W Hop  
E H Brilstra  
G J E Rinkel

Correspondence to:  
Dr J W Hop, University  
Department of Neurology,  
PO Box 85500, 3508 GA  
Utrecht, The Netherlands.  
Telephone 0031 30 2507975;  
fax 0031 30 2522783; email  
j.w.hop@neuro.azu.nl

Received 16 January 1998  
and in revised form  
31 March 1998  
Accepted 6 April 1998

Baseline characteristics and CT measurements of patients with perimesencephalic haemorrhage with and without amnesia

Characteristic	Amnesia (n=10)	No amnesia (n=17)	MF*	p Value
<b>Baseline:</b>				
Age (mean (SD))	61 (8)*	55 (14)		NS
Female:male	1:1	1:1.4		NS
Follow up (months, mean (SD))	26 (15)	25 (17)		NS
CT <24 hours (n)	6	9		NS
<b>Frontal horns:</b>				
BCI (mean (SD))	0.21 (0.04)	0.16 (0.04)	1.3	<0.01
Rel BCI >1 (n)	7	5		=0.05
<b>Third ventricle:</b>				
Mean (SD) mm	8.7 (2.1)	5.9 (1.7)	1.5	<0.01
Rel size >1 (n)	6	3		<0.05
<b>Temporal horns (mm mean (SD)):</b>				
Anterior-posterior	10.1 (6.7)	4.4 (4.0)	2.3	=0.01
Medial-lateral	12.1 (7.0)	7.0 (5.6)	1.7	<0.05
Oblique	5.5 (3.2)	2.6 (1.7)	2.1	<0.01
Naked eye (n)	10	4		<0.01

\*MF=magnification factor; BCI= bicaudate index.

VENTRICULAR SIZES ON CT

We quantified the size of the frontal horns by means of the bicaudate index. The width of the third ventricle was measured with a transparent ruler from the CT image, and multiplied by the appropriate magnification factor. To calculate

age-adjusted relative sizes, the bicaudate indices and third ventricle sizes were divided by the corresponding upper limits for each age group.<sup>8,9</sup> The frontal horns and third ventricles were considered enlarged if the relative size exceeded 1.0.

The temporal horns were measured in three different directions: medial-lateral, anterior-posterior, and oblique (fig 1). Measurements were taken from the CT slice on which the temporal horns were best visible. For all directions we calculated the mean size of the left and right horn. All measurements were performed by one of us (JWH), unaware of the presence or absence of amnesia.

Finally, one of us (GJER) assessed the presence or absence of enlargement of the temporal horns on CT with the “naked eye”, without knowledge of the linear measurements or the occurrence of amnesia.

DATA ANALYSIS

Student’s *t* test was performed to compare the sizes of the frontal horns, third ventricles, and

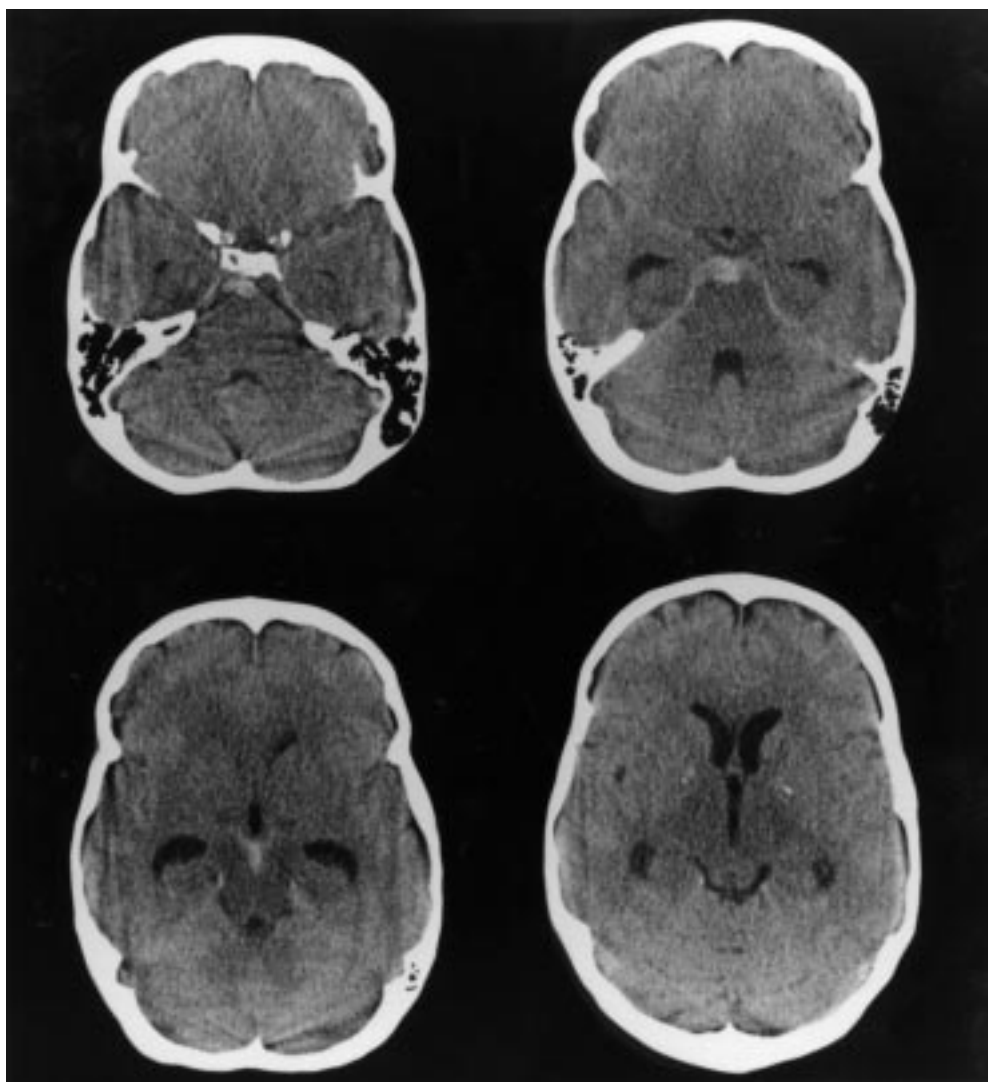


Figure 2 CT of a 54 year old patient with a perimesencephalic haemorrhage, performed within 24 hours after the ictus. This patient reported amnesia for the first 48 hours after the haemorrhage. The extravasated blood is accumulated in the cisterns around the midbrain (upper row right). The temporal horns are large (bottom row left), without enlargement of the frontal horns (bottom row right).

temporal horns between patients with or without amnesia. A  $p$  value  $< 0.05$  was considered significant. We used Fisher's exact test to compare the differences in relative bicaudate indices, relative third ventricle sizes, and "naked eye" assessments of enlargement of the temporal horns between patients with and without amnesia.

### Results

Between January 1989 and June 1995, 414 patients with a subarachnoid haemorrhage were admitted to the University Hospital, Utrecht; 29 (7%) of these had a perimesencephalic haemorrhage. Two patients were excluded from our study: one patient spoke only Arabic and in the other patient the initial CT, performed in a referring hospital, could not be retrieved. All 27 patients presented with acute severe headache, vomiting had occurred in 20. None of the patients had lost consciousness during the event. On admission, all were alert, 20 had signs of meningism, and none had focal deficits. The clinical course was uneventful for 26 patients; one patient deteriorated from hydrocephalus. His symptoms of desorientation spontaneously resolved after 1 day. The baseline characteristics of the 27 patients enrolled in our study are listed in the table.

Ten patients reported an episode of amnesia. This started within a few minutes to a few hours after the ictus and lasted between 2 hours and nearly 5 days (median 2 days). There were no major differences in sex, age and time of follow up between the patients with and without transient amnesia.

In the patients with amnesia the ventricles were larger than in the patients without amnesia. This difference was greatest for the temporal horns, ranging from a factor of 1.7 for the medial-lateral measurement to a factor of 2.3 for the anterior-posterior measurement. The difference for the frontal horns and third ventricle was less (1.3-fold and 1.5-fold), but was still significant.

In seven patients with amnesia the frontal horns were enlarged (relative bicaudate index  $> 1$ ), in six the third ventricle was enlarged (relative third ventricle size  $> 1$ ), and in all 10 the temporal horns were enlarged at "naked eye" assessment, whereas only four of the 17 patients without amnesia had enlarged temporal horns at "naked eye" assessment.

The CT of one of the patients with enlarged temporal horns at "naked eye" assessment but normal sizes of the frontal horns and third ventricles is shown in figure 2.

### Discussion

We found that one third of patients with perimesencephalic haemorrhage experienced an episode of amnesia after the bleed, despite an undisturbed level of consciousness at that time. Our results strongly suggest that this episode of amnesia after perimesencephalic haemorrhage is related to the presence of acutely enlarged ventricles, especially the temporal horns. A possible explanation for the amnesia is a temporary hypoperfusion of the hippocampus, caused by pressure from the enlarged

temporal horn. The hippocampal formation is of critical importance for the encoding of new episodic memories.<sup>10</sup> In a high resolution SPECT study of patients with transient global amnesia, hippocampal hypoperfusion was actually demonstrated.<sup>11, 12</sup> Apart from the remaining amnesic episode and the suspected hippocampal dysfunction, perimesencephalic haemorrhage and transient global amnesia have little in common. Perimesencephalic haemorrhage can be distinguished from transient global amnesia by the presence of acute headache and signs of meningism and blood in the cisterns around the midbrain on CT in perimesencephalic haemorrhage. Patients with transient global amnesia do not vomit and are desoriented in the acute stage, whereas most patients with perimesencephalic haemorrhage, including the patients who develop amnesia, are oriented and adequate.

For our study of the size of the temporal horns on CT we could not rely on standard data from a reference population. To overcome this, we merely compared the measurements between the patients with and without amnesia. The value of the assessment with the "naked eye" for the presence of enlarged temporal horns is questionable because the assessment is subjective and data on interobserver agreements are lacking. We have, nevertheless, included this assessment because in many patients the enlargement of the temporal horns on CT is obvious. By blinding the assessments we have minimised the chance of bias.

We have restricted this study to patients with perimesencephalic haemorrhage. Acute hydrocephalus is also a well known complication in patients with aneurysmal subarachnoid haemorrhage. Especially, dilatation of the temporal horns is found in 66% of patients with subarachnoid haemorrhage.<sup>13</sup> However, patients with aneurysmal subarachnoid haemorrhage are less suitable for study of the relation between hydrocephalus and amnesia for two reasons. Firstly, in patients with aneurysmal subarachnoid haemorrhage, hydrocephalus is often related to intraventricular haemorrhage, and is also a predictor of poor outcome,<sup>8</sup> whereas in perimesencephalic haemorrhage the only cause for the hydrocephalus is a block at the tentorial hiatus,<sup>4</sup> and all patients recover completely. Secondly, half of the patients with aneurysmal subarachnoid haemorrhage lose consciousness at the time of the ictus, caused by a global lack of perfusion pressure during the aneurysmal rupture.<sup>14</sup> This lack of perfusion pressure probably results in ischaemia, for which the hippocampus is especially vulnerable. With aneurysmal rupture the possible effect of hydrocephalus on the hippocampus can therefore not be distinguished from the effects of the initial haemorrhage.

In summary, about one third of patients with perimesencephalic haemorrhage report an episode of amnesia after the bleed. The occurrence of amnesia is associated with enlargement of the ventricles, especially the temporal horns. A clinically useful aspect of this study is that patients with perimesencephalic haemorrhage and enlarged temporal horns can later be

informed about the nature of antegrade amnesia, and reassured about its benign character.

We thank Professor Dr J van Gijn for his helpful comments.

- 1 van Gijn J, van Dongen KJ, Vermeulen M, *et al.* Perimesencephalic hemorrhage: a non-aneurysmal and benign form of subarachnoid hemorrhage. *Neurology* 1985;35:493-7.
- 2 Rinkel GJE, Wijdicks EFM, Vermeulen M, *et al.* Non-aneurysmal perimesencephalic subarachnoid hemorrhage: CT and MR patterns that differ from aneurysmal rupture. *Am J Neuroradiol* 1991;12:829-34.
- 3 Schwartz TH, Solomon RA. Perimesencephalic hemorrhage: review of the literature. *Neurosurgery* 1996;39:433-40.
- 4 Rinkel GJE, Wijdicks EFM, Vermeulen M, *et al.* Acute hydrocephalus in non-aneurysmal perimesencephalic hemorrhage: evidence of CSF block at the tentorial hiatus. *Neurology* 1992;42:1805-7.
- 5 Rinkel GJE, Wijdicks EFM, Vermeulen M, *et al.* The clinical course of perimesencephalic non-aneurysmal subarachnoid hemorrhage. *Ann Neurol* 1991;29:463-8.
- 6 Rinkel GJE, Wijdicks EFM, Hasan D, *et al.* Outcome in patients with subarachnoid haemorrhage and negative angiography according to pattern of haemorrhage on computed tomography. *Lancet* 1991;338:964-8.
- 7 Brilstra EH, Hop JW, Rinkel GJE. Quality of life after perimesencephalic haemorrhage. *J Neurol Neurosurg Psychiatry* 1997;63:382-4.
- 8 van Gijn J, Hijdra A, Wijdicks EF, *et al.* Acute hydrocephalus after aneurysmal subarachnoid hemorrhage. *J Neurosurg* 1985;63:355-62.
- 9 Wijdicks EFM, van Dongen KJ, van Gijn J, *et al.* Enlargement of the third ventricle and hyponatraemia in aneurysmal subarachnoid haemorrhage. *J Neurol Neurosurg Psychiatry* 1988;51:516-20.
- 10 Garrard P, Perry R, Hodges JR. Disorders of semantic memory. *J Neurol Neurosurg Psychiatry* 1997;62:431-5.
- 11 Ohnishi T, Hoshi H, Nagamachi S, *et al.* High-resolution SPECT to assess hippocampal perfusion in neuropsychiatric diseases. *J Nucl Med* 1995;36:1163-9.
- 12 Stillhard G, Landis T, Schiess R, *et al.* Bitemporal hypoperfusion in transient global amnesia: 99m-Tc-HM-PAO SPECT and neuropsychological findings during and after an attack. *J Neurol Neurosurg Psychiatry* 1989;48:339-42.
- 13 Hosoya T, Yamaguchi K, Adachi M, *et al.* Dilatation of the temporal horn in subarachnoid hemorrhage. *Neuroradiology* 1992;34:207-9.
- 14 Grote E, Hassler W. The critical first minutes after subarachnoid hemorrhage. *Neurosurgery* 1988;22:654-61.