

SHORT REPORT

Vasomotor reactivity is exhausted in transient ischaemic attacks with limb shaking

Ralf W Baumgartner, Iris Baumgartner

Abstract

Objectives—To investigate cerebral vasomotor reactivity in five patients with limb shaking transient ischaemic attacks by using transcranial Doppler sonography.

Method—Attacks with transient limb shaking were unilateral in four patients and bilateral in one. Internal carotid arteries on the side opposite the abnormal limb movements showed three 90–95% stenoses and three occlusions as assessed by cerebral angiography in three and magnetic resonance angiography and ultrasound in one case each. Reactivity of cerebral resistance vessels was studied by measuring peak mean velocities in the middle cerebral artery (MCA) before and after the application of CO₂ enriched air. Reference values were obtained from 25 normal subjects.

Results—During hypercapnia peak mean velocities slightly decreased in five MCAs (steal phenomenon) and remained unchanged in one MCA opposite the abnormal movements, whereas the other MCAs showed normal reactivities.

Conclusion—The delineation of an exhausted cerebral vasoreactivity in all hemispheres opposite the involuntary limb movements suggests that haemodynamic failure is the cause of transient ischaemic attacks with limb shaking.

(*J Neurol Neurosurg Psychiatry* 1998;**65**:561–564)

Keywords: transient ischaemic attack transcranial Doppler ultrasound

Attacks of brief, repetitive shaking movements of the limbs are an unusual manifestation of transient cerebral ischaemia, resembling simple focal motor seizures.^{1–3} As opposed to jacksonian seizures, transient ischaemic attacks with limb shaking never extend to the face or trunk, show no tonic contraction, tonic-clonic jerking, or march.^{1–4} Further, limb shaking is often precipitated by standing up or walking, and is promptly alleviated by assuming a supine position.^{2–4} Since the first description by Fisher,⁵ subsequent findings have firmly established the association of limb shaking transient ischaemic attacks with severe occlusive carotid artery disease.^{1–4,6} The movements have been

reported to cease after carotid endarterectomy and superficial temporal artery-middle cerebral artery (STA-MCA) anastomoses.^{1,3,4} These findings^{1–6} suggest that transient haemodynamic failure in the presence of maximally dilated resistance vessels of the brain might be involved in the pathogenesis of the abnormal limb movements. With the exception of one case report⁴ no haemodynamic studies have been performed to investigate cerebral vasomotor reactivity in patients with limb shaking. Recognition of the mechanism, however, is important for the administration of the appropriate treatment. Transcranial Doppler sonography (TCD) is a well established technique for the assessment of vasomotor reactivity of the brain.^{7–9} The aim of this investigation was to evaluate cerebral vasomotor reactivity in five patients with limb shaking transient ischaemic attacks by using TCD.

Patients and methods

PATIENTS

The clinical and laboratory findings are based on five patients (two women, three men; mean age 64 (range 53–73) years with limb shaking transient ischaemic attacks. Vasomotor reactivity was investigated by measuring peak mean flow velocity (V) in both MCAs before and after the administration of carbon dioxide (CO₂ reactivity). A TC 2000S ultrasound device (EME, Uberlingen, Germany) equipped with a 2 MHz monitoring probe was used as reported previously. Ten CO₂ reactivities were calculated for each patient according to the formula ((VMCA hypoventilation: VMCA normoventilation x 100) - 100)/(PCO₂ hypoventilation - PCO₂ hyperventilation).⁷ Reference values (mean 3.60 (2 SD 1.78)) were obtained from previously reported 25 normal subjects.¹⁰

The extracranial cerebral arteries were investigated using colour duplex imaging; carotid stenoses and occlusions were evaluated according to previously published criteria.¹¹ Cerebral arteries were also imaged by intra-arterial digital subtraction angiography in patients 1, 2, and 4, and by magnetic resonance angiography in patient 5. North American Symptomatic Carotid Endarterectomy Trial (NASCET) criteria were used for definite grading of carotid stenoses.¹² Patients 1–4 had CT and patient 5 had MRI of the brain.

Department of Neurology
R W Baumgartner

Department of Internal Medicine,
Division of Angiology,
University Hospital,
Bern, Switzerland
I Baumgartner

Correspondence to:
Dr Ralf W Baumgartner,
Department of Neurology,
University Hospital,
Frauenklinikstrasse 26,
CH-8091 Zurich,
Switzerland. Telephone 0041
1 255 56 86; fax 0041 1 255
43 80; email
Strusbmg@neuro.unizh.ch

Received 30 December 1997
and in revised form
13 March 1998 Accepted 19
March 1998

Table 1 Laboratory findings in patients with limb shaking transient ischaemic attacks

| Patient No | Limb shaking | CO ₂ reactivity (%) [*] | | Collateral | | | Extracranial ICA | | CT/MRI of the brain | Electroencephalogram |
|------------|--------------|---|-------|------------|------|------|------------------|--------------|---|---------------------------------------|
| | | R | L | OphA | ACoA | PCoA | R | L | | |
| 1 | R | 2.53 | -0.33 | 1 | 0 | 0 | Normal | Occlusion | Normal | Intermittent theta, L fronto-temporal |
| 2 | R | 0.00 | -0.87 | 1 | 1 | 1 | Occlusion | 90% Stenosis | Infarct borderzone LACA-MCA | Persistent delta, L hemisphere |
| 3 | R, L | -0.79 | -0.48 | 0 | 0 | 2 | Occlusion† | Occlusion† | Normal | Persistent delta, bitemporal |
| 4 | L | 0.18 | 2.41 | 1 | 0 | 1 | 95% Stenosis | 50% Stenosis | Infarct R frontal | Intermittent delta, R temporal |
| 5 | L | -0.47 | 1.81 | 1 | 0 | 1 | Occlusion | Normal | Infarcts R frontal, L thalamus, borderzone RACA-MCA | Persistent theta-delta, R hemisphere |

ACA=anterior cerebral artery; ACoA=anterior communicating artery; CO₂=carbon dioxide; ICA=internal carotid artery; L=left; MCA=middle cerebral artery; OphA=ophthalmic artery; PCoA=posterior communicating artery; R=right; TIA=transient ischaemic attack.

^{*} $((V_{MCA} \text{ hypercapnia} - V_{MCA} \text{ normocapnia} \times 100) - 100) / (pCO_2 \text{ hypercapnia} - pCO_2 \text{ normocapnia})$; abnormal < 1.9.

†Both external and common carotid arteries were also occluded.

All patients had EEGs in the supine position. In patients 1–4 attempts were made to induce limb shaking transient ischaemic attacks by having the patients stand up for several minutes. Measurements of blood pressure during a five minute recumbent position and the first three minutes on assuming an upright position were done in all patients. A ≥ 20 mm Hg decrease of systolic and mean blood pressure was assumed to be normal.¹³

Results

No patient had a history of convulsive disease or orthostatic hypotension. The cerebrovascular risk factors included arterial hypertension in all, a history of smoking and hypercholesterolaemia in four, and diabetes mellitus, coronary artery disease, and peripheral artery disease in one patient each.

The patients had multiple episodes of involuntary limb movements lasting seconds to minutes.

The movements occurred on or shortly after arising from supine to standing in all patients, and also from supine to sitting in patients 3 and 4. Limb position was not a provocative factor.

Limb movements were present on one side in four patients and on both sides in patient 3. They affected the elbow, wrist, and sometimes the shoulder in all patients, and in patients 2–5 also the knee and hip. No involvement of truncal, neck, and facial muscles was seen. The movements were described as “shaking” and “trembling”, and were estimated to be rhythmic with a frequency of 5–9 Hz. Patient 1 sometimes showed dystonic posturing of his right hand during the spells. No tonic contraction, tonic-clonic jerking, jacksonian march, or choreoathetotic movements were noticed.

Patients 2, 4, and 5 had mild weakness during seconds up to minutes after the spells. Two patients also had other transient ischaemic attacks on the side of limb shaking. These transient ischaemic attacks consisted of dysarthria and brachiofaciocrucal weakness in patient 2, and of brachiofacial weakness in patient 5. Neurological examination in patients 2 and 5 disclosed mild motor hemipareses on the side of the involuntary movements.

Ultrasonic, radiological, and EEG characteristics are given in table 1. The VMCA remained unchanged in one and slightly decreased in five hemispheres opposite to the limb shaking transient ischaemic attacks providing CO₂ reactivities of -0.47 (SD 0.38) (for comparison¹⁰ CO₂ reactivity of healthy volunteers was 3.60 (SD 0.90), and for patients with unilateral and bilateral high grade stenoses or occlusions of the carotid arteries it was 1.47 (SD 0.68) and 0.57 (SD 0.26), respectively). During standing only patient 1 developed shaking movements of his right arm, while the EEG remained unchanged. After one minute he lay down and the symptoms subsided within a few seconds. On changing from the recumbent to the upright position no patient had abnormal falls in blood pressure or complained of lightheadedness or vertigo.

Patient 1 had been treated with carbamazepine and patient 5 with phenytoin before our evaluation, each without any benefit. Treatment and clinical outcome are reported in table 2.

Discussion

In patients with normal carotid arteries increases in VMCA occur during hypercapnic challenge as the cerebral resistance vessels

Table 2 Treatment and clinical outcome of patients with limb shaking transient ischaemic attacks

| Patient No | Treatment | Outcome |
|------------|----------------------|--|
| 1 | Conservative* | Patient declined STA-MCA bypass surgery. Limb shaking TIAs disappeared spontaneously after three months, and did not recur during the next two years |
| 2 | Endarterectomy L ICA | Patient developed postoperatively hypertensive blood pressures (up to 240/130 mm Hg) and died six days after surgery of massive L hemispheric haemorrhage |
| 3 | Conservative* | No cardiovascular surgery was planned as diagnostic investigation disclosed inoperable epidermoid carcinoma of the lung with mediastinal metastases. Limb shaking TIAs continued until the patient died eight months later |
| 4 | Endarterectomy R ICA | No further episodes of limb shaking TIAs occurred over 6 years |
| 5 | Conservative* | Patient declined STA-MCA bypass surgery, although limb shaking TIAs kept her bedridden; died six months later from a major stroke of the R hemisphere |

ICA=internal carotid artery; L=left; R=right; STA-MCA=superficial temporal artery—middle cerebral artery; TIA=transient ischaemic attack.

* Blood pressure was maintained in the upper normal range and aspirin was administered.

dilate.⁷ In our five patients VMCA of the six hemispheres opposite to the involuntary limb movements showed no increase during CO₂ inhalation suggesting that the corresponding resistance vessels were already maximally dilated.⁸ In five of the six hemispheres VMCA even decreased during hypercapnia, which may indicate a steal effect. Absent and especially negative CO₂ reactivities are rare in patients with high grade stenoses or occlusions of the carotid arteries, because CO₂ reactivity is either normal or impaired in most cases.⁸⁻¹⁰ Interestingly, Tatemichi *et al*¹ also reported a negative CO₂ reactivity measured by intracranial Doppler in a patient with limb shaking transient ischaemic attacks. Smith *et al*¹⁴ used xenon-enhanced CT to correlate changes of cerebral blood flow induced by acetazolamide with the pattern of collateral flow in patients with carotid artery disease. They found that a negative flow reactivity was significantly associated with a dependence on leptomeningeal collaterals indicating a state of maximal haemodynamic compromise.

In summary, our data support clear evidence that our patients had an exhausted vasomotor reactivity in the hemispheres opposite to the abnormal limb movements.

It has been shown that the compromise of cerebral vasomotor reactivity in cases of severe carotid artery obstruction results from the presence of an unfavourable network of intracranial and extracranial collaterals.¹⁵⁻¹⁶ Hypertension may have further impaired vasomotor reactivity in our patients, because animal¹⁷ and human¹⁸ studies suggest that arterial hypertension decreases cerebral vasoreactivity.

A seizure mechanism related to transient cerebral ischaemia has been discussed as a possible explanation for the shaking movements as Heiss *et al*¹⁹ recorded epileptic activity from cortical neurons of monkeys subjected to acute ischaemia. In our and previous series the involuntary movements affected the limbs only and showed no tonic contraction, tonic-clonic jerking, or jacksonian march, and no epileptic activity during or between the attacks.^{1-3,4,6} These findings strongly argue against a seizure mechanism as the cause of limb shaking transient ischaemic attacks.

We found no evidence of orthostatic hypotension in our patients. Thus orthostatic hypotension seems not to be a prerequisite for the development of attacks with limb shaking, which is in accordance with the findings of other reports.^{1-3,4,6} Tatemichi *et al*¹ have shown in a patient with limb shaking transient ischaemic attacks and exhausted vasoreactivity of the brain that cerebral blood flow passively declines with decreasing blood pressure. Scheinberg and Stead²⁰ found a 21% decrease in cerebral blood flow that accompanied a change in posture from supine to 65° in normal subjects. The results of our study and the studies of Tatemichi *et al*¹ and Scheinberg and Stead²⁰ suggest that transient decreases of cerebral perfusion pressure and blood flow, as occurring for example, during an alteration from the supine to the upright position, might be the cause of limb shaking transient ischaemic attacks.

In two of our three conservatively treated patients the involuntary movements persisted until the patients died six to eight months later. Conversely, limb shaking abolished spontaneously within three months in the third conservatively treated patient. This probably resulted from an enhancement of collateral blood supply as Widder *et al*⁹ have recently demonstrated that vasomotor reactivity of the brain may spontaneously improve. After carotid endarterectomy the shaking movements disappeared in patient 4, whereas patient 2 died seven days after the operation from an intracerebral haematoma that was most likely caused by a hyperperfusion syndrome.²¹ The outcome for our patients is very similar to previously reported findings.^{1-3,4} Limb shaking transient ischaemic attacks disappeared in only one of four conservatively treated patients during a follow up ranging from several weeks to 18 months.^{1-3,6} Conversely the abnormal movements ceased in all patients after carotid endarterectomy.¹⁻³ Limb movements were abolished in six and reduced in three of nine patients treated with STA-MCA anastomoses.¹⁻³ Taken together these data suggest that surgical revascularisation may be more beneficial in reducing or abolishing the limb movements than conservative treatment. Because an exhausted cerebral vasoreactivity is a risk factor for the development of a hyperperfusion syndrome after carotid surgery,²¹ patients with limb shaking transient ischaemic attacks should be kept under careful postoperative surveillance.

In conclusion, we have shown that vasomotor reactivity was exhausted in all cerebral hemispheres opposite to the involuntary movements, suggesting that transient haemodynamic insufficiency may be the cause of limb shaking transient ischaemic attacks. Clinicians should be aware of this unusual condition and search for the presence of severe occlusive carotid artery disease and abnormal vasomotor reactivity of the brain as such patients may benefit from an appropriate therapy.

- 1 Baquis GD, Pessin MS, Scott RM. Limb shaking—a carotid TIA. *Stroke* 1985;16:444-8.
- 2 Fisch BJ, Tatemichi TK, Prohovnik I, *et al*. Transient ischemic attacks resembling simple partial motor seizures. *Neurology* 1988;38(suppl 1):264.
- 3 Yanagihara T, Piepgras DG, Klass DW. Repetitive involuntary movement associated with episodic cerebral ischemia. *Ann Neurol* 1985;18:244-50.
- 4 Tatemichi TK, Young WL, Prohovnik I, *et al*. Perfusion insufficiency in limb-shaking transient ischemic attacks. *Stroke* 1990;21:341-7.
- 5 Fisher CM. Concerning recurrent transient cerebral ischemic attacks. *Can Med* 1962;86:1091-9.
- 6 Michel B, Larquis P, Nicoli F, *et al*. Mouvements involontaires positionnels: acces ischémique transitoire carotidien? *Rev Neurol* 1989;145:853-5.
- 7 Markwalder TM, Grolimund P, Seiler R, *et al*. Dependency of blood flow velocity in the middle cerebral artery on end-tidal carbon dioxide partial pressure—a transcranial Doppler study. *J Cereb Blood Flow Metab* 1984;4:368-72.
- 8 Ringelstein EB, Sievers C, Ecker S, *et al*. Non-invasive assessment of CO₂-induced cerebral vasomotor response in normal individuals and patients with internal carotid artery occlusions. *Stroke* 1988;19:963-9.
- 9 Widder B, Kleiser B, Krapf H. Course of cerebrovascular reactivity in patients with carotid artery occlusions. *Stroke* 1994;25:1963-7.
- 10 Baumgartner RW, Regard M. Role of impaired CO₂-reactivity in the diagnosis of cerebral low flow infarcts. *J Neurol Neurosurg Psychiatry* 1994;57:814-7.
- 11 Sitzler M, Furst G, Fischer H, *et al*. Between method correlation in quantifying internal carotid stenosis. *Stroke* 1993;24:1513-8.

- 12 North American Symptomatic Carotid Endarterectomy Trial Collaborators. Beneficial effect of carotid endarterectomy in symptomatic patients with high-grade stenosis. *N Engl J Med* 1991;325:445-53.
- 13 Schatz IJ. Orthostatic hypotension. II. Clinical diagnosis, testing, and treatment. *Arch Intern Med* 1984;144:1037-41.
- 14 Smith HA, Thompson-Dobkin J, Yonas H, et al. Correlation of xenon-enhanced computed tomography-defined cerebral blood flow reactivity and collateral flow patterns. *Stroke* 1994;25:1784-7.
- 15 Powers WJ, Press GA, Grubb RL, et al. The effect of hemodynamically significant carotid artery disease on the hemodynamic status of the cerebral circulation. *Ann Intern Med* 1987;106:27-35.
- 16 Ringelstein EB, Zeumer H, Angelou D. The pathogenesis of strokes from internal carotid artery occlusion. Diagnostic and therapeutical implications. *Stroke* 1983;14:867-75.
- 17 Yoshida F, Fujishima M, Sadoshima S, et al. Carbon dioxide reactivity of cerebral cortical and pial arteries in spontaneously hypertensive and normotensive rats—a morphometric study. *Brain Res* 1987;412:1-5.
- 18 Maeda H, Matsumoto M, Handa N, et al. Reactivity of cerebral blood flow to carbon dioxide in hypertensive patients: evaluation by the transcranial Doppler method. *J Hypertens* 1994;12:191-7.
- 19 Heiss WD, Hayakawa T, Waltz AG. Cortical neuronal function during ischemia. *Arch Neurol* 1976;33:813-20.
- 20 Scheinberg P, Stead E. The cerebral blood flow in male subjects as measured by the nitrous oxide technique. *J Clin Invest* 1949;28:1163-71.
- 21 Solomon RA, Loftus CM, Quest DO, et al. Incidence and etiology of intracerebral hemorrhage following carotid endarterectomy. *J Neurosurg* 1986;64:29-34.

NEUROLOGICAL PICTURE

Post-arteriography cholesterol embolism

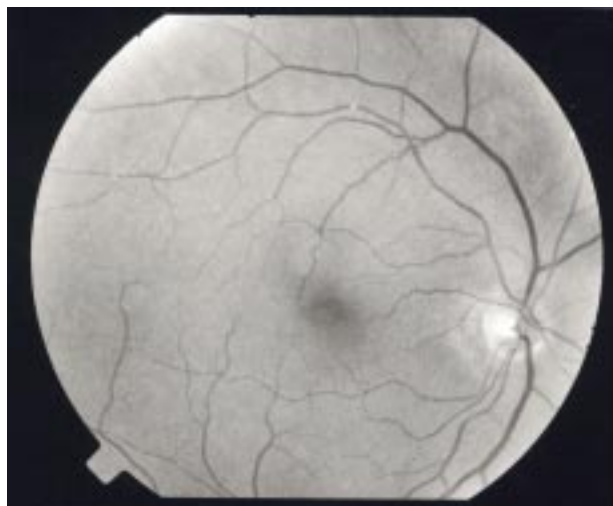


Figure 1 Cholesterol embolism of the retina.

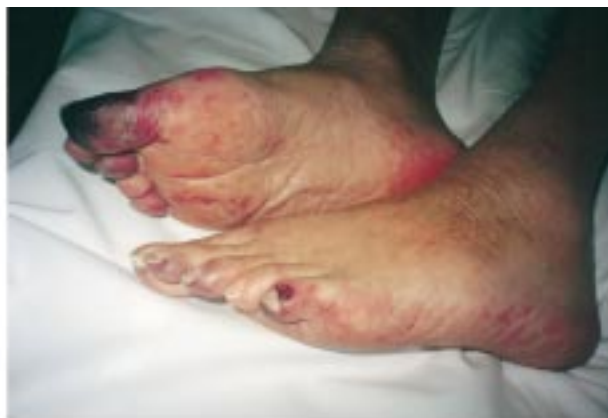

Figure 2 Necrotic lesions of the toes.

A seventy seven year old man underwent arteriography of the supra-aortic vessels for investigation of possible carotid stenosis. Immediately after arteriography the patient developed impaired consciousness and diffuse livedo predominantly in the lower limbs. Simultaneously his blood pressure increased to 230/110 mm Hg.

Twenty four hours later, impaired renal function was evident (creatinine 380 mmol/l; urea 41 mmol/l). Later on, we found variable circulation in the toes associated with cyanosis.

The syndrome of cholesterol embolism was suspected and confirmed by the presence of cholesterol emboli in the retina (fig 1). Despite stopping anticoagulation, consciousness worsened, probably due to repetitive ischaemia; the toes became necrotic (fig 2); the patient developed anal bleeding and colonoscopy showed necrotic bleeding from the colonic mucosa. The erythrocyte sedimentation rate was increased to 100 mm/hour.

Cholesterol embolism may complicate aortic atheroma. It is most often triggered by aortic angiography and sometimes by anticoagulant therapy. In several aspects the disease may present as a necrotising angitis analogous to polyarteritis nodosa.

C PRAT
Service de Neurologie
M LOKO
Service d'Ophthalmologie
J L DEVOIZE
Service de Neurologie,
Centre hospitalier d'Angoulême,
16470 St Michel, France