

STUDIES OF ACUTE PHASE PROTEIN*· †

I. AN IMMUNOHISTOCHEMICAL METHOD FOR THE LOCALIZATION OF Cx-REACTIVE PROTEIN IN RABBITS. ASSOCIATION WITH NECROSIS IN LOCAL INFLAMMATORY LESIONS

BY IRVING KUSHNER,§ M.D., AND MELVIN H. KAPLAN,|| M.D.

(From the Departments of Medicine, Metropolitan General Hospital, and Western Reserve University School of Medicine, Cleveland)

PLATES 90 TO 92

(Received for publication, July 13, 1961)

Cx-reactive protein (CxRP) is an acute phase serum protein in the rabbit which is precipitated by pneumococcal somatic Cx polysaccharide in the presence of calcium ion, and is analogous to C-reactive protein (CRP) of man (1).

Both CRP and CxRP are bound in the serum to lipid, from which separation may be accomplished by delipidation with either alcohol-ether mixture (2) or chloroform (3) at low temperature. Crystallization of delipidated CRP was achieved by McCarty in 1947 (4), and the electrophoretic mobility of this material or of lipid-bound CRP was found to be that of a beta globulin by free electrophoresis, and of a fast gamma globulin by starch electrophoresis (3). Immunoelectrophoresis of acute phase human serum in agar gel indicated a beta (5) or fast gamma (6) mobility. CxRP was isolated from acute phase rabbit serum and crystallized by Anderson and McCarty in 1951 (1). Immunologic cross-reactivity between CRP and CxRP has been demonstrated (7). Antiserum to crystalline lipid-free CRP contained no antibodies reactive with normal human serum (4), while antiserum prepared against lipid-bound CRP was usually found to cross-react extensively with normal serum (3). Analogous studies with CxRP have not been reported.

Little is known of the site of origin, distribution in tissue, and fate of these acute phase proteins, nor has any physiologic function been adduced. Various separate reports pertaining to their biologic behavior may be outlined as follows: CRP showed a destructive effect on leukocytes at high concentration, and induced increased leukocyte motility at low concentrations (8). The CRP response to inflammatory stimuli was retained following induction of granulocytopenia by nitrogen mustard (9). Administration of thorotrast, a reticuloendothelial

* This work was performed under grants-in-aid from the National Heart Institute, United States Public Health Service (H-3726), and the Cleveland Foundation.

† Portions of this study were presented before the American Association of Immunologists (*Fed. Proc.*, 1961, **20**, 263).

§ Public Health Service Research Fellow of the National Institute of Allergy and Infectious Diseases, 1958-1959, and Research Fellow of the Helen Hay Whitney Foundation, 1959-1962.

|| This work was done during the tenure of an Established Investigatorship of the American Heart Association.

blocking agent, was reported to reduce the CxRP response to inflammatory stimuli (10). Intracutaneous injection of CxRP itself in incomplete adjuvant into rabbits was observed to induce a local inflammatory reaction (11). It has been reported that the appearance of CxRP in the blood of rabbits following injection of antigen was correlated with a heightened immune response (12). On the other hand, administration of an anti-inflammatory steroid, fluorometholone, was found to suppress the CxRP response to injection of tobacco mosaic virus antigen without suppressing the antibody response to this antigen (13). The biologic significance of these observations is as yet unclear.

The present work describes an immunohistochemical method permitting detection of CxRP in tissue sections. By means of this method, the histologic distribution of CxRP in the tissues following local injection of an inflammatory stimulus was investigated. The data to be reported describe the selective localization of CxRP to the inflammatory site, its absence from cells of non-inflamed tissues and organs, the time-course of appearance of CxRP in the inflammatory site in relationship to the serum level, and its independence of leukocyte infiltration into the inflammatory area.

Materials and Methods

Preparation of Purified Cx-Reactive Protein.—Cx-reactive protein was prepared by slight modification of the method of Anderson and McCarty (1). New Zealand white rabbits weighing 2.5 to 3.0 kg were injected subcutaneously with 15 cc of 1 per cent croton oil in corn oil in multiple sites, and acute phase rabbit blood was obtained by cardiac puncture 48 to 72 hours after injection, when the CxRP level was found maximum.¹ Lipid bound to CxRP was extracted at low temperature with alcohol-ether as recommended by the above authors. The chloroform extraction technique which has been found successful for delipidation of CRP (3) was found unsatisfactory for CxRP in our hands.

In the usual procedure, 60 to 80 ml of pooled acute phase rabbit serum, chilled in an ice bath to 0°C, was added with gentle stirring to 10 volumes of a 3:1 mixture of absolute alcohol and ether kept at -12°C in a salt-ice bath. After very gentle continuous stirring for 1½ hours, the mixture was centrifuged at -5°C. The precipitate was washed three times in ether at -12°C, suspended in ether, and filtered in the cold. The filter cake was dried *in vacuo* overnight, and the product dissolved in a quantity of buffered saline (0.01 M phosphate, pH 7.2) equal to the original volume of serum. Saturated ammonium sulfate was added in the cold to 0.4 saturation, and after standing overnight in the cold, the precipitate was removed by centrifugation at 8000 RPM and discarded. The supernate was brought to 0.75 saturation by slow addition of saturated ammonium sulfate, and allowed to stand overnight at 4°C. The resulting precipitate was recovered by centrifugation, dissolved in distilled water to one-third the original volume of serum, dialyzed first against running tap water and then with constant agitation against 0.01 per cent CaCl₂ over a period of 48 hours. Lipid-associated material, including non-delipidated CxRP, was precipitated, and this material, separated by centrifugation at 8000 RPM for 30 minutes, was discarded. To ensure removal of all insoluble material, the supernate was passed through an ultrafine sintered glass filter.

This solution containing delipidated CxRP was adjusted to 0.85 per cent NaCl, and specific precipitation of CxRP carried out by addition of an optimum quantity of Cx carbohydrate. The latter was prepared by the method of Anderson and McCarty (1) from a III R strain of

¹ We are indebted to Drs. Maclyn McCarty and Harrison Wood for a sample of CxRPA prepared in sheep used in early phases of this work.

pneumococcus. The optimum concentration ranged from 0.003 to 0.0125 mg/ml in the various preparations, dependent on the amount of CxRP present. After incubation for 2 hours at 37°C, and overnight at 4°C, the CxRP-Cx carbohydrate precipitate was recovered by centrifugation in the cold, and was washed three times with cold 0.85 per cent NaCl containing 0.01 per cent CaCl₂. The precipitate was dissolved in 10 ml of a solution containing 0.1 M NaCl and 0.1 M Na citrate, and the solution centrifuged to remove traces of insoluble matter. The CxRP-Cx carbohydrate complex was reprecipitated from this clear solution by dialysis for 48 hours against large volumes of 0.01 per cent CaCl₂ in 0.85 per cent NaCl. The precipitate was again collected by centrifugation, washed, redissolved, and reprecipitated as above. This cycle of reprecipitation was carried out four times in all. The resulting delipidated CxRP-Cx carbohydrate precipitate was solubilized either in 0.0001 M disodium dihydrogen ethylenediaminetetraacetate (EDTA) in 1 per cent NaCl or in 0.1 M Na citrate in 0.1 M NaCl and used as antigen for preparation of antiserum and for specific absorption tests of antiserum. This solubilized precipitate will henceforth be referred to as CxRP.

Preparation of CxRP Antiserum in the Goat.—In preliminary work, it had been noted that immunization of a goat or sheep with CxRP preparation in Freund's adjuvant yielded antiserum with serologic activity against non-CxRP constituents in acute phase serum and tissue sections, that is to say, activity which could not be abolished following specific absorption with purified CxRP. A major goal in this work was thus the preparation of a potent antiserum which contained minimal antibody to non-CxRP material as controlled by both precipitin and immunohistochemical tests. The generally accepted principles of immunization for obtaining antiserum with minimal antibody to trace contaminants were followed, *i.e.*, injection of small doses of antigen without Freund's adjuvant, and bleeding during the early antibody response.

In the first trial of immunization, a suspension of CxRP-Cx carbohydrate precipitate was employed as antigen. A young goat received a total dose of 3 mg of protein N in two 3 week courses of five intravenous injections per week without significant antibody response after either course. Since this procedure did not seem propitious, alum-precipitated antigen was employed for subsequent courses of immunization. CxRP-Cx carbohydrate precipitate was solubilized in 1 per cent NaCl containing 0.0001 M EDTA at pH 8.0, and saturated KAl(SO₄)₂ was added dropwise until a copious precipitate appeared, while the pH was maintained at 7.0-7.4. This alum-precipitated antigen was administered intravenously and subcutaneously for three further courses in a total dose of 2.5 mg protein N. A potent antiserum (CxRPA) was obtained, which reacted strongly with acute phase rabbit serum and with CxRP solution in precipitin tests in capillary tubes (14). Only a minimal reaction with normal rabbit serum was observed. This latter reactivity was abolished by absorption of CxRPA with lyophilized normal rabbit serum. When such absorbed CxRPA was reacted with acute phase rabbit serum in agar gel diffusion studies, a single sharp band appeared after 2 days at room temperature (Fig. 1). This band showed a pattern of identity with purified CxRP solution, as shown in Fig. 2. A second broader, fainter band, closer to the antigen well, appeared in some of the plates after 6 to 8 days with both CxRP solution and acute phase serum. This band became more apparent after the plates were washed and stained, but was usually too faint to be seen in photographs. Unabsorbed antiserum reacted with CxRP solution to give a single major band and the inconstant minor band described above. This pattern was not altered by absorption of CxRPA with normal rabbit serum (Fig. 3). The reaction of absorbed CxRPA with acute phase rabbit serum and acute phase human serum revealed a cross-reactive pattern with the major CxRP band (Fig. 4). There was no precipitin reaction detectable between antiserum and Cx carbohydrate.

Fluorescent Conjugates.—Goat CxRPA was fractionated at 1/2 saturation with (NH₄)₂SO₄ to obtain the globulin fraction and the latter was conjugated with fluorescein-isothiocyanate

by the usual methods, in the absence of organic solvents (15, 16). For control studies an identical fluorescent conjugate was made from the pre-immune serum globulin from this same goat.

Absorption Procedures to Remove Non-Specific Staining.—CxRPA conjugate was routinely treated with 8 mg/ml of lyophilized normal rabbit serum previously found free of CxRP. This amount was found optimum for the conjugate employed. The conjugate was next absorbed with acetone-precipitated mouse organ powder, 100 mg/1.5 ml, to abolish the non-specific staining reaction observed with normal tissue sections (17). However, such acetone powders were found not fully effective for study of inflammatory lesions, in which considerable non-specific staining of inflammatory cells and connective tissue elements persisted even after repeated absorption with the above material (*cf.* Fig. 8). In this particular test system, non-specific staining is defined as persisting reaction of elements of inflamed tissue when stained with CxRPA conjugate absorbed with excess CxRP. Attempts to eliminate this persisting non-specific tissue staining with other organ powder preparations, including rabbit bone marrow, were only partially successful. This problem was finally resolved by using as absorbent a preparation of rabbit polymorphonuclear leukocytes separated from glycogen-induced peritoneal exudates (18). This absorbent was prepared as follows. Rabbits were injected intraperitoneally with 200 ml of 0.1 per cent glycogen in 0.85 per cent saline and the peritoneal fluid removed 4 hours later by irrigation of the peritoneal cavity with Hanks' solution without heparin. The cell suspension was filtered through several layers of cotton gauze, the cells sedimented by centrifugation, and the supernate discarded. The cells were washed once in 20 to 30 ml of buffered physiologic saline, and, after centrifugation, were suspended in 20 to 30 ml hypotonic NaCl (0.21 per cent) to lyse the small number of erythrocytes present in the exudate. After centrifugation the hemoglobin-containing supernate was discarded, and the cellular sediment was suspended in distilled water, dried by lyophilization, and ground to a fine powder in a mortar. The smallest quantity of this preparation which eliminated staining of inflammatory tissue by CxRP-absorbed CxRPA conjugate was approximately 60 mg/ml.

Fluorescence Microscope.—The ultraviolet source was a scopicon micro projection unit, equipped with a 1000 watt General Electric (Schenectady, New York) water-cooled high pressure mercury lamp (AH-6) and fitted with a quartz condenser, UG 2 exciter filter, and a red-excluding filter, BG-23. The Zeiss binocular microscope was fitted in the ocular housing with 3 thicknesses of Wratten 2B as barrier filter, and with a darkfield Zeiss ultracondenser.

Production of Inflammatory Lesions.—The local inflammatory lesion selected for study was the site of intramuscular injection of typhoid vaccine. This agent induced extensive acute inflammatory changes and was consistently effective in eliciting a CxRP response in the blood in 8 to 12 hours (1). From the technical point of view of applying the fluorescent antibody method, less difficulty from non-specific staining reactions was encountered with inflamed muscle tissue than with inflammatory sites in dermal or subcutaneous tissue or in lesions produced by more potent inflammatory stimuli such as croton oil.

New Zealand white rabbits weighing 2 to 3 kg were first tested to ensure absence of CxRP from the blood. The normal rabbits selected for study received a single injection of 1 ml of typhoid-paratyphoid vaccine² in the gastrocnemius muscle. 0.05 ml of India ink was included in the injection mixture to aid in localizing the site to be excised. A few apparently normal animals who demonstrated CxRP in their blood at the time of injection of typhoid vaccine were also studied. The animals were sacrificed at varying intervals and tissue was obtained from the injected and non-injected contralateral muscle sites, ipsilateral and contralateral popliteal lymph nodes, liver, spleen, kidney, thymus, and heart. The tissue blocks were placed in test tubes, quick frozen in a mixture of dry ice and alcohol, and stored at -25°C . Tissues were sectioned at a thickness of 4 micra in the cryostat, and the slides air-dried before fixation and staining.

² Typhoid and paratyphoid vaccine, Wyeth Laboratories, Marietta, Pennsylvania.

Fixation and Staining Techniques.—Early studies indicated that the usual methods of fixation employing alcohol, ether, acetone, or mixtures of these solvents at various temperatures were inadequate for demonstration of CxRP in the tissues. With these methods, staining of CxRP, when observed, was faint and poorly reproducible, attributable, in part, to the marked solubility of CxRP and its consequent extraction from the tissue section during the staining procedure, and in part, to denaturation of CxRP by the conditions of fixation. After trial and error with a variety of protein precipitation procedures,³ satisfactory fixation of CxRP was accomplished by use of a mixture of 1.0 per cent picric acid in acetone, neutralized by saturation with sodium acetate crystals. Freshly cut air-dried sections were immersed in this solution and the coplin jars slowly shaken for 1 hour at room temperature on a mechanical shaker. The slides were washed with continuous shaking in three changes of reagent-grade anhydrous acetone for a period of 1½ hours to remove excess tissue-bound picrate and then air-dried at 37°C for 30 minutes. The tissue sections were overlaid with 1 to 2 drops of fluorescent conjugate for 1 hour in a moist chamber, washed 10 minutes in two changes of buffered saline (0.01 M phosphate, pH 7.2), and mounted in glycerol buffer.

Definition of Immunohistochemical Specificity.—Specificity of staining for CxRP was established by the following controls. (a) Abolition of staining following absorption of antiserum with slight excess of CxRP solution; (b) Negative reaction with normal pre-immune goat serum conjugate; (c) Negative reaction with normal tissue sections. Specific staining could not be abolished by prior absorption of antiserum with Cx carbohydrate.

Serum Specimens and CxRP Tests.—Ear blood samples were obtained just prior to injection of typhoid vaccine and at the time of sacrifice. Serum was separated after standing overnight at 4°C, and was immediately tested for the presence of CxRP by the capillary precipitin technique. Equal volumes of serum and CxRPA absorbed with lyophilized normal rabbit serum were mixed in capillaries and the tubes incubated for 2 hours at 37°C and overnight at 4°C. Positive tests were graded by the height of the column of precipitate in millimeters.

Induction of Neutropenia in Rabbits.—Neutropenia was induced in rabbits by the administration of a nitrogen mustard, mechlorethamine hydrochloride,⁴ in a dose of 1.5 mg per kilo intravenously. After 3 to 4 days, when there were fewer than 60 neutrophils per mm³ of blood, typhoid vaccine with India ink marker was injected intramuscularly. The animals were sacrificed at varying intervals and muscle tissue at inflamed and non-inflamed sites was examined for presence of CxRP.

RESULTS

Muscle tissue at the site of injection of typhoid vaccine, as demarcated by India ink, exhibited intense interstitial polymorphonuclear and mononuclear cell infiltration within 3 hours, and muscle fibers, singly and in groups, revealed varying degrees of necrosis. These necrotic changes as observed in formalin-fixed paraffin sections stained with hematoxylin and eosin, were manifested by a homogeneous, refractile appearance with loss of cross-striation and myofibrillar structure (Fig. 5). These altered myofibers showed enhanced intensity of staining with eosin, and decreased reactivity with the periodic acid-Schiff stain (Fig. 6), and exhibited marked vacuolization.

The distribution of CxRP in the inflammatory lesion at 24 hours was con-

³ We are indebted to Karl Engleman for assistance with these experiments while on a medical school summer fellowship.

⁴ Mustargen, Merck Sharp & Dohme, Philadelphia, Pennsylvania.

sidered characteristic of the localization of this material and may be described as follows: In the area of inflammation scattered muscle fibers exhibited intense staining while other fibers adjacent to these were unstained. The relative number of stained myofibers in general constituted a minority of the myofibers in the center of the inflamed area. CxRP was found principally in myofibers undergoing necrotic changes, and was localized particularly at the outer edge of these cells,⁵ in vacuoles within the sarcoplasm, and in short linear or fusiform inclusions, occasionally seen extending from sarcolemma into the interior of sarcoplasm (Figs. 7, 9, 11, 13). Staining was usually of a fine, sharply delineated character, but occasionally the sites of reaction were marked by a dispersed microprecipitate.

Only those fibers giving evidence of necrotic change, as determined in hematoxylin-eosin—stained sections by double staining techniques or from examination of adjacent sections, gave evidence of the presence of CxRP. None was detected in myofibers at the inflammatory site which were considered to exhibit a normal morphologic appearance (Figs. 9 to 14). Myofibers in the non-injected contralateral muscle sites were entirely negative.

CxRP could not be detected within polymorphonuclear leukocytes nor in endomysial or perimysial connective tissue (Figs. 13, 14) in the inflammatory area. It could not be detected at any time in cellular elements of popliteal lymph nodes proximal to, and presumably draining the inflammatory site, nor in cells of distal lymph node, liver, spleen, thymus, heart, or kidney (Table I). Traces of specifically stained material, occurring as amorphous microprecipitates, were noted occasionally in lumens of vessels or in interstitial spaces of these organs, particularly in kidney.

The time-course of appearance of CxRP in the tissue sites closely paralleled that of CxRP in the serum. After the single injection of typhoid vaccine, a latent period of approximately 8 hours ensued in which CxRP could not be detected in either tissue or serum. Thereafter, for the remainder of the 48 hour period of observation (Table I), CxRP could be demonstrated both in inflamed tissue sites and in serum. It was not possible to demonstrate CxRP in tissue when none could be detected in the blood. The relative number of myofibers containing CxRP showed progressive increase from early lesions at 8 to 12 hours to older lesions at 48 hours. Observations were not continued beyond this interval.

In those apparently normal animals with CxRP in the blood at the time of injection of typhoid vaccine, the distribution of CxRP was identical with that

⁵ This site may bear a relationship to sarcolemma, defined by Bennett (19) as "the membrane component of muscle corresponding to the cell or plasma membrane." However, since this term refers to normal myofiber constituents, it may not be justifiable to apply it to sites in necrotic myofibers.

seen in normal animals without CxRP prior to injection, namely, in necrotic muscle elements at the injection site, and not in normal muscle tissue or in other organs.

The localization of CxRP in areas of inflammatory cell infiltration raised the question as to whether polymorphonuclear leukocytes were required for

TABLE I
Tissue Localization of CxRP and the Time-Course of Appearance in Inflammatory Site and Serum

Time	Rabbit No.	Serum CxRP level		Presence of CxRP by immunofluorescence						
		Pre-injection	Final	Muscle (injection site)	Contra-lateral muscle	Regional lymph node	Spleen	Liver	Kidney	Heart
<i>hrs.</i>										
1	7-91	0	0	0	0	0	0	0	—*	—
3	7-87	0	0	0	0	0	0	0	—	—
4	10-15	0	0	0	0	0	0	0	0	0
6	10-07	0	0	0	0	0	0	0	0	0
8	10-06	0	0	0	0	0	0	0	0	0
8	10-19	0	1+	+	0	0	0	0	0	0
10	10-18	0	1/2+	+	0	0	—	—	0	0
12	10-11	0	2+	+	0	0	—	—	—	—
24	7-98	0	3+	+	0	0	0	0	—	—
24	10-01	0	2+	+	0	0	0	0	0	0
45	8-77	0	2+	+	0	—	0	0	—	—
48	10-03	0	2+	+	0	0	0	0	0	0
12	10-05	3+	3+	+	0	0	0	0	0	0
24	8-81	4+	7+	++	0	0	0	—	—	—
3	7-41‡	0	0	0	0	—	—	—	—	—
24	7-40‡	4+	3+	++	0	0	0	0	—	—

* Not studied.

‡ Rendered neutropenic with nitrogen mustard.

the tissue localization of this protein. Accordingly, rabbits were rendered granulocytopenic by the injection of nitrogen mustard. 3 to 4 days after injection, when the blood granulocyte count was less than 60 per mm³, an injection of typhoid vaccine was given intramuscularly, as described above. The injection site demonstrated necrotic myofibers, but showed little or no inflammatory cell infiltrate. CxRP was localized in necrotic myofibers from such neutropenic animals in the same distribution as observed in animals not treated with nitrogen mustard (Figs. 15, 16).

DISCUSSION

The immunologic properties of the CRP and CxRP systems have not been completely resolved. Libretti *et al.* (20) found crystalline CRP as well as CRP in serum to contain at least three components by gel diffusion. However, antisera to crystalline CRP from three different patients showed identical quantitative precipitation curves with homologous and heterologous CRP preparations. The immuno- and physicochemical relationships between these components have yet to be clarified. Fishel *et al.* (21) described three diffusible components of acute phase human serum against commercial CRPA in agar gel; all three could be absorbed from serum with Cx carbohydrate. Rapport and Graf (22), using absorbed commercial serum, described only a single band, and attributed observations of multiple lines obtained only on prolonged standing to an artifact of the diffusion process. Gautier and Scheidegger (5), using absorbed commercial antiserum, described only one band in Ouchterlony plates and in immunoelectrophoretic experiments. Schultze *et al.* (6), by immunoelectrophoresis of pathologic sera, demonstrated a component, "gamma-x globulin," which reacted with both CRPA and antiserum to gamma globulin. They suggested an immunologic relationship between CRP and normal human gamma-2 globulin. However their gamma-x globulin preparations were prepared by ammonium sulfate precipitation and zone electrophoresis and may have contained both antigens, thus permitting an alternative interpretation of their data.

For the purpose of this study, CxRP was defined as that material precipitated from acute phase rabbit serum by Cx carbohydrate in the presence of calcium ion, after appropriate delipidation and fractionation procedures. In agar diffusion, a single early band and a second very weak late-appearing band were seen when this material was reacted against CxRPA. As in the case of reports of multiple components of acute phase protein cited above, the relationship between these two components remains to be clarified.

In the development of this immunohistochemical method for the detection of Cx-reactive protein, three major technical problems were encountered: (a) purification of CxRP and preparation of defined antiserum, (b) histologic fixation of CxRP in tissue sections, and (c) control of non-specific staining reactions.

1. *Preparation of CxRP and Definition of Antiserum.*—Preliminary observations had indicated that isolation of delipidated, highly purified CxRP for immunization was essential in order to avoid the complex staining reactions due to "contaminating" antibodies to serum constituents closely associated with CxRP. Lipid was separated by extraction of acute phase serum with alcohol-ether, and by subsequent dialysis against CaCl₂ solution at low ionic strength to precipitate non-delipidated material (2). Further purification

involved four times precipitation with Cx carbohydrate. CxRP, unlike CRP, is apparently not easily crystallized, and crystallization was not undertaken in this work.

For preparation of antiserum, it was essential to minimize production of antibodies to possible trace contaminants. Accordingly, the antigenic dose given was kept as low as possible, 5.5 mg protein N being the total amount injected over a period of 10 months. It was found necessary, however, to use alum-precipitated antigen at this tiny dose. Use of Freund's adjuvant was excluded because of its recognized capacity to induce antibodies to trace contaminants. Under these conditions of immunization, only a trace reaction with normal rabbit serum constituents was observed. Nevertheless, this antiserum did exhibit intense immunofluorescent reaction with normal muscle tissue constituents, notably perimysium. This latter reaction was found to be abolished by absorption with normal rabbit serum.

2. *Fixation of CxRP in Tissue Sections.*—Since CxRP was found to leach out of tissue sections with usual fixation procedures, a technique of vigorous fixation was sought which at the same time would not alter its immunologic properties. After numerous trials of a variety of protein precipitants, neutral picric acid-acetone was found to yield the most favorable result. This fixative has served successfully in this laboratory for studies of other endogenous and foreign protein antigens found difficult of fixation by previously described methods.

3. *"Non-Specific" Staining of Inflammatory Tissue Sites.*—CxRPA absorbed with mouse organ powder and normal rabbit serum and treated with excess CxRP still exhibited staining of tissue elements in the inflammatory site, particularly polymorphonuclear and mononuclear cells, sarcolemma, endomysial cells, and other connective tissue elements. Non-specific staining of scattered cells in lymph nodes and spleen was also noted. This staining was not abolished by absorption with CxRP (Fig. 8). Since this reaction was much stronger with CxRPA conjugate than with normal pre-immune goat globulin conjugate, it was possible that it resulted from a contaminating antibody. Absorption procedures with organ powders or with various fractions of acute phase serum failed to abolish this staining; however, a preparation of rabbit polymorphonuclear cells, obtained from peritoneal exudates, was found remarkably effective. Absorption of antiserum with this material resulted in little or no reduction of the specific immunohistochemical reaction with CxRP.

By this immunofluorescent technique, CxRP was found only in necrotic myofibers, localized usually at the outer edge of the cell and intracellularly in round or fusiform vacuoles. Occasionally, linear deposits were observed extending from the periphery into the interior of the myofiber. It was probable that sarcolemma and basement membrane were included in these specifically stained sites.

The involved muscle fibers, usually surrounded by inflammatory cell infiltrates, were generally close to the site of injection as evidenced by proximity to the India ink marker with which the typhoid vaccine was mixed. Such stained fibers were scattered in groups within the inflammatory area interspersed among non-stained myofibers of normal morphologic appearance. Muscle fibers more distant from the center of inflammation exhibited no stainable material, like the contralateral, non-injected muscle tissue.

These collected observations, namely, restriction of CxRP localization to the site of induced inflammation, its absence from other organs, its cytologic distribution in characteristic and well delineated sites within necrotic myofibers, and its absence from normal myofibers within the inflammatory area, are consistent with the hypothesis that CxRP is produced at the inflammatory site, possibly as a product of cellular alteration associated with necrosis. The latent period observed prior to its appearance in blood and tissue is perhaps consistent with the time required for tissue degeneration to proceed to the point of formation and release of such a tissue constituent. It was possible that the failure to observe CxRP in the local site prior to appearance in blood was related to the high degree of solubility and diffusibility of this protein, as indicated by the rigid fixation techniques required for its demonstration. On the other hand, limitations in sensitivity of the immunohistochemical method may not have permitted detection of CxRP at the time of its first appearance in inflamed tissue. Attempts to increase sensitivity by the use of indirect immunofluorescent procedures in the course of this work, (in which rabbit anti-goat globulin labeled with fluorescein was used to detect the reaction of unconjugated goat CxRPA with tissue sites), have failed. These latter procedures brought additional problems of non-specific staining.

An alternative interpretation of the data presented must be considered, namely, that the localization observed represents sites of secondary deposition of CxRP from the blood in necrotic, hence permeable, cells. This latter proposition would assume that the site of tissue origin was not determined by the techniques employed. In the absence of cellular localization of CxRP in other organs, this interpretation must be considered less probable.

The finding of a serologic reaction with inflammatory cell and tissue constituents at the inflammatory site which may be absorbed with rabbit peritoneal polymorphonuclear suspensions raises the question of whether such staining represents a reaction with acute phase reactant other than CxRP. The relationship between such a substance and material from polymorphonuclear cells is of considerable interest, and is being investigated.

Evidence that CxRP localization was not related to polymorphonuclear cell infiltration was provided first by failure to detect CxRP in these cells, and secondly by the unaltered distribution of CxRP in lesions of rabbits rendered neutropenic with nitrogen mustard as compared with normal animals. Par-

ticipation by other reticuloendothelial elements, including macrophages and lymphoid cells, was considered unlikely since such cells were free of staining, nor was localization of CxRP related to presence of these cells in the inflamed area. Hedlund's inability to find acute phase protein in rabbit lymphocytes or human leukocytes obtained during the acute phase reaction is consistent with these conclusions (23). The absence of CxRP from draining lymph nodes or spleen was against the participation of lymphoid elements in production of this material. These observations argue against proposals that CxRP is related immunologically to gamma globulin or that it may be a precursor to classical antibody.

SUMMARY

A method is presented for the immunohistochemical localization of Cx-reactive protein in rabbits, based on the use of a defined antiserum and rigorous fixation techniques requisite for this antigen. In animals in which inflammatory lesions and CxRP response were induced by intramuscular injection of typhoid vaccine, Cx-reactive protein was localized only in the area of local inflammation within muscle fibers showing morphologic evidence of necrotic change. Within such altered fibers, CxRP was observed in peripheral segments of myofiber or in subsarcolemmal sarcoplasm, in scattered deposits in sarcoplasm, and in vacuolar inclusions. No CxRP was found at any time in polymorphonuclear or mononuclear cells in the inflammatory lesion, nor in contralateral muscle, regional or distal lymph nodes, liver, spleen, thymus, heart, or kidney, except as traces in lumens of vessels or interstitium. CxRP was first detected in necrotic myofibers at the inflammatory site after a latent period of 8 to 10 hours following injection of the inflammatory stimulus and could be demonstrated in these sites for the 48 hours of the experiment. It could not be observed at the inflammatory site before appearance in the blood. Identical histologic localization in necrotic myofibers at the site of the local lesions was found following induction of granulocytopenia with nitrogen mustard. These findings are consistent with the hypothesis that CxRP is formed locally at the site of inflammation from tissue elements undergoing necrotic change. Alternatively, secondary deposition from the blood at the inflammatory site cannot be excluded, but is considered less likely in view of the failure to obtain evidence of a cellular localization of CxRP in other organs.

The technical assistance of Mary Louise Suchy and Momoye Kansaki is acknowledged.

BIBLIOGRAPHY

1. Anderson, H. C., and McCarty, M., The occurrence in the rabbit of an acute phase protein analogous to human C-reactive protein, *J. Exp. Med.*, 1951, **93**, 25.
2. MacLeod, C. M., and Avery, O. T., The occurrence during acute infections of a

- protein not normally present in the blood. II. Isolation and properties of the reactive protein, *J. Exp. Med.*, 1941, **73**, 183.
3. Wood, H. F., McCarty, M., and Slater, R. J., The occurrence during acute infections of a protein not normally present in the blood. V. Physical-chemical characteristics of the C-reactive protein crystallized by a modified technique, *J. Exp. Med.*, 1954, **100**, 71.
 4. McCarty, M., The occurrence during acute infections of a protein not normally present in the blood. IV. Crystallization of the C-reactive protein, *J. Exp. Med.*, 1947, **85**, 491.
 5. Gautier, A., and Scheidegger, J. J., Qu'est ce que la proteine-C? *Schweiz. med. Woch.*, 1957, **87**, 950.
 6. Schultze, H. E., Schwick, G., Sonnet, J., Heremans, J., and Michaux, J. L., Gamma-x-globulin, eine immunoelektrophoretisch nachweisbare γ -globulin-komponente mit beziehungen zum C-reactiven protein, *Klin. Woch.*, 1960, **38**, 62.
 7. Gotschlich, E., and Stetson, C. A., Jr., Immunologic cross-reactions among mammalian acute phase proteins, *J. Exp. Med.*, 1960, **111**, 441.
 8. Wood, H. F., Effect of C-reactive protein on normal human leukocytes, *Proc. Soc. Exp. Biol. and Med.*, 1951, **76**, 843.
 9. Good, R. A., Acute-phase reactions in rheumatic fever, in *Rheumatic Fever*, (L. Thomas, editor), Minneapolis, University of Minnesota Press, 1952, 135.
 10. Montella, S., and Wood, H. F., Studies on the Cx-reactive protein. II. Inhibition of the Cx-reactive protein response in rabbits by blockade of the reticuloendothelial system, *J. Exp. Med.*, 1957, **106**, 321.
 11. Wood, H. F., and Montella, S., Studies on the Cx-reactive protein. I. The effect of administration of Cx-reactive protein to normal rabbits, *J. Exp. Med.*, 1957, **106**, 315.
 12. Wood, H. F., The relationship between the acute phase response and antibody production in the rabbit. I. Correlation between the early appearance of Cx-reactive protein and subsequent antibody production, *J. Exp. Med.*, 1953, **98**, 311.
 13. Hokama, Y., Coleman, M. K., and Riley, R. F., Effect of drugs on Cx protein responses in the rabbit, *Proc. Soc. Exp. Biol. and Med.*, 1960, **105**, 510.
 14. Anderson, H. C., and McCarty, M., Determination of C-reactive protein in the blood as a measure of the activity of the disease process in acute rheumatic fever, *Am. J. Med.*, 1950, **8**, 445.
 15. Coons, A. H., and Kaplan, M. H., Localization of antigen in tissue cells. II. Improvements in a method for the detection of antigen by means of fluorescent antibody, *J. Exp. Med.*, 1950, **91**, 1.
 16. Riggs, J. L., Seiwald, R. J., Burckhalter, J. H., Downs, C. M., and Metcalf, T. C., Isothiocyanate compounds as fluorescent labelling agents for immune serum, *Am. J. Path.*, 1958, **34**, 1081.
 17. Kaplan, M. H., Localization of streptococcal antigen in tissues. I. Histologic distribution and persistence of M protein, types 1, 5, 12, and 19 in the tissues of the mouse, *J. Exp. Med.*, 1958, **107**, 341.
 18. Cohn, Z. A., and Morse, S. I., Interactions between rabbit polymorphonuclear leukocytes and staphylococci, *J. Exp. Med.*, 1959, **110**, 419.

19. Bennett, H. S., The structure of striated muscle as seen by the electron microscope, *in* The Structure and Function of Muscle, (G. H. Bourne, editor), New York, Academic Press, 1960, 137.
20. Libretti, A., Goldin, M., and Kaplan, M. A., Immunologic relationships of C-reactive protein from various human pathologic conditions, *J. Immunol.*, 1957, **79**, 306.
21. Fishel, C. W., Vedros, N. A., and Rothlauf, M. V., Serologic and fractionation studies of C-reactive protein, *J. Infect. Dis.*, 1960, **106**, 174.
22. Rapport, M. M., and Graf, L., Quantitative determination of C-reactive protein by complement fixation, *Proc. Soc. Exp. Biol. and Med.*, 1956, **93**, 69.
23. Hedlund, P., Clinical and experimental studies on C-reactive protein (acute phase protein), *Acta Med. Scand.*, 1961, suppl. 361.

EXPLANATION OF PLATES

PLATE 90

FIG. 1. Agar gel diffusion. 1, Acute phase rabbit serum; 2, Goat CxRPA, unabsorbed; 3, Goat CxRPA absorbed with lyophilized normal rabbit serum.

A major CxRP band is seen between wells 1 and 2, as well as several faint minor bands. Absorption of antiserum with normal rabbit serum (3) eliminated the minor bands. The line between 2 and 3 is due to reaction of unabsorbed antiserum in 2 with excess normal rabbit serum used for absorption in 3. Diffusion pattern after 12 days.

FIG. 2. 1, CxRPA absorbed with normal rabbit serum; 2, Acute phase rabbit serum; 3, Purified CxRP.

The reaction of antiserum with CxRP shows a pattern of identity with acute phase rabbit serum. Agar plate after 4 days.

FIG. 3. 1, Purified CxRP; 2, CxRPA, unabsorbed; 3, CxRPA absorbed with normal rabbit serum.

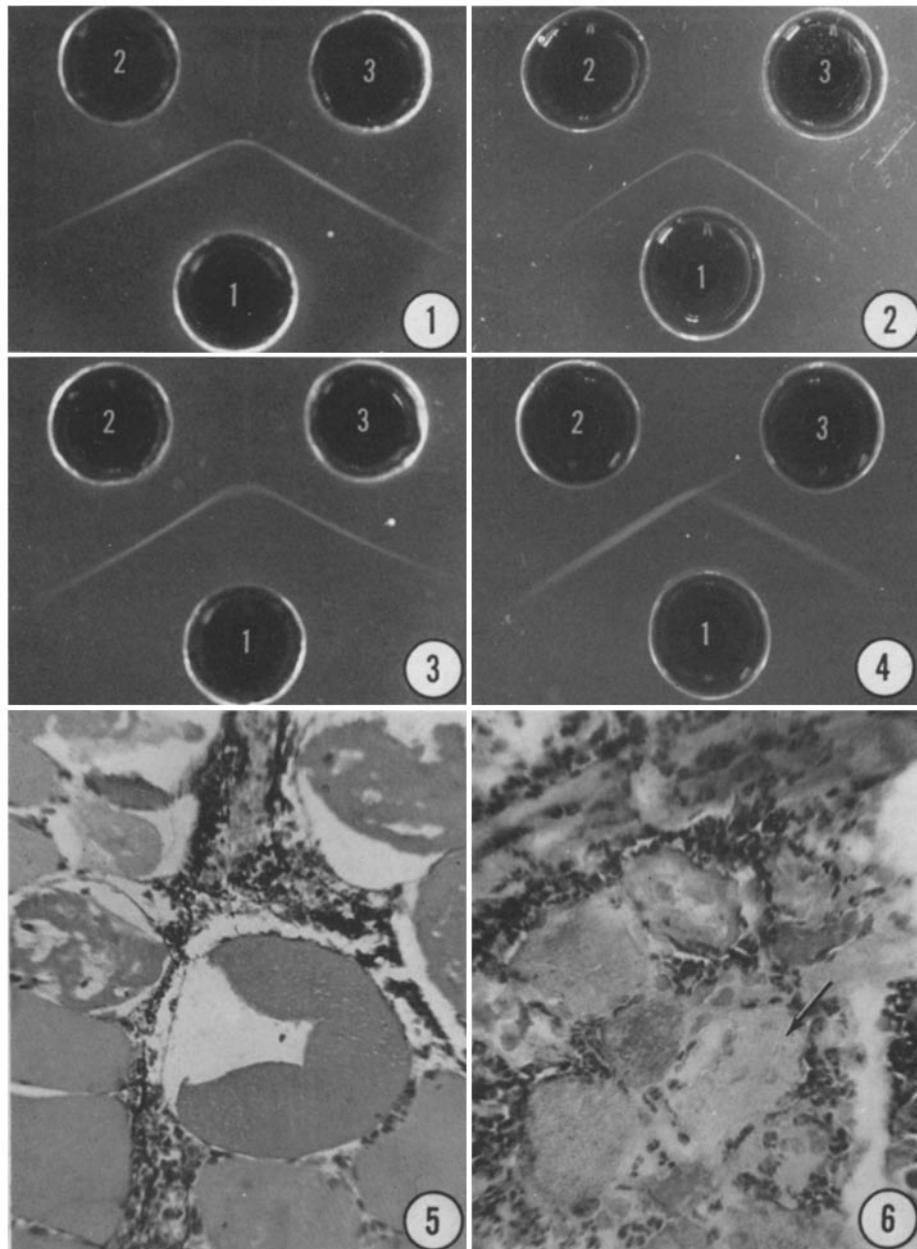
A single band results from the reaction between CxRP and CxRPA. Absorption of antiserum with normal rabbit serum does not affect this reaction. 12 days.

FIG. 4. 1, CxRPA absorbed with normal rabbit serum; 2, Acute phase rabbit serum; 3, Acute phase human serum.

CxRPA reacts with acute phase human serum in 3 showing a cross-reactive pattern with the CxRP band of acute phase rabbit serum. 8 days.

FIG. 5. Muscle site from rabbit 10-06, sacrificed 8 hours after local injection of typhoid vaccine. Necrotic myofibers show vacuolization, a refractile homogeneous appearance, and eosinophilic staining. Intense infiltration with inflammatory cells. Carbon black seen in interstitium was injected as marker with vaccine. Fixed in neutral formalin; paraffin section. Hematoxylin and eosin stain. $\times 250$.

FIG. 6. Rabbit 8-77, sacrificed 45 hours after intramuscular injection of typhoid vaccine. Periodic acid-Schiff stain of muscle at injection site. Necrotic myofibers, as indicated by arrow, show decreased staining reaction as compared with surrounding intact fibers. $\times 250$.



(Kushner and Kaplan: Localization of Cx-reactive protein)

PLATE 91

FIG. 7. Rabbit 8-81 sacrificed 24 hours after intramuscular injection of typhoid vaccine. Section of muscle at injection site stained with CxRPA conjugate. The latter was absorbed with normal rabbit serum, but not with peritoneal exudate preparation. CxRP is localized at the peripheral edge of muscle fibers, in vacuoles, and in inclusions within sarcoplasm of necrotic myofibers. Staining of inflammatory cells is non-specific (arrow). $\times 312$.


FIG. 8. Section adjacent to that shown in Fig. 7 stained with CxRPA conjugate absorbed also with CxRP. The reaction with CxRP in necrotic myofibers has been abolished, while non-specific stain of inflammatory cells persists (arrow). $\times 312$.

FIG. 9. Rabbit 8-81, sacrificed 24 hours after injection. CxRPA conjugate used in this and subsequent figures was absorbed with normal rabbit serum and peritoneal exudate preparation. CxRP is localized to the single necrotic myofiber in this section, and is revealed in vacuoles, multiple inclusions, and along the myofiber edge. $\times 312$.

FIG. 10. Same section as Fig. 9. Coverslip was floated off and section stained with hematoxylin and eosin. The single myofiber found to contain CxRP shows marked necrotic changes and vacuolization. $\times 312$.

FIG. 11. Inflamed muscle, rabbit 8-81. Section stained with CxRPA conjugate. CxRP demonstrated in two muscle fibers, at periphery of these cells, and in vacuoles and linear and droplet inclusions. Adjacent muscle fibers non-reactive. $\times 312$.

FIG. 12. Same section as Fig. 11, restained with hematoxylin and eosin. The necrotic and vacuolated character of the myofibers shown to contain CxRP is demonstrated. Correspondence of CxRP localization with droplet vacuoles is evident. Inflammatory cell exudate, present in left lower corner, shows no staining reaction. $\times 312$.



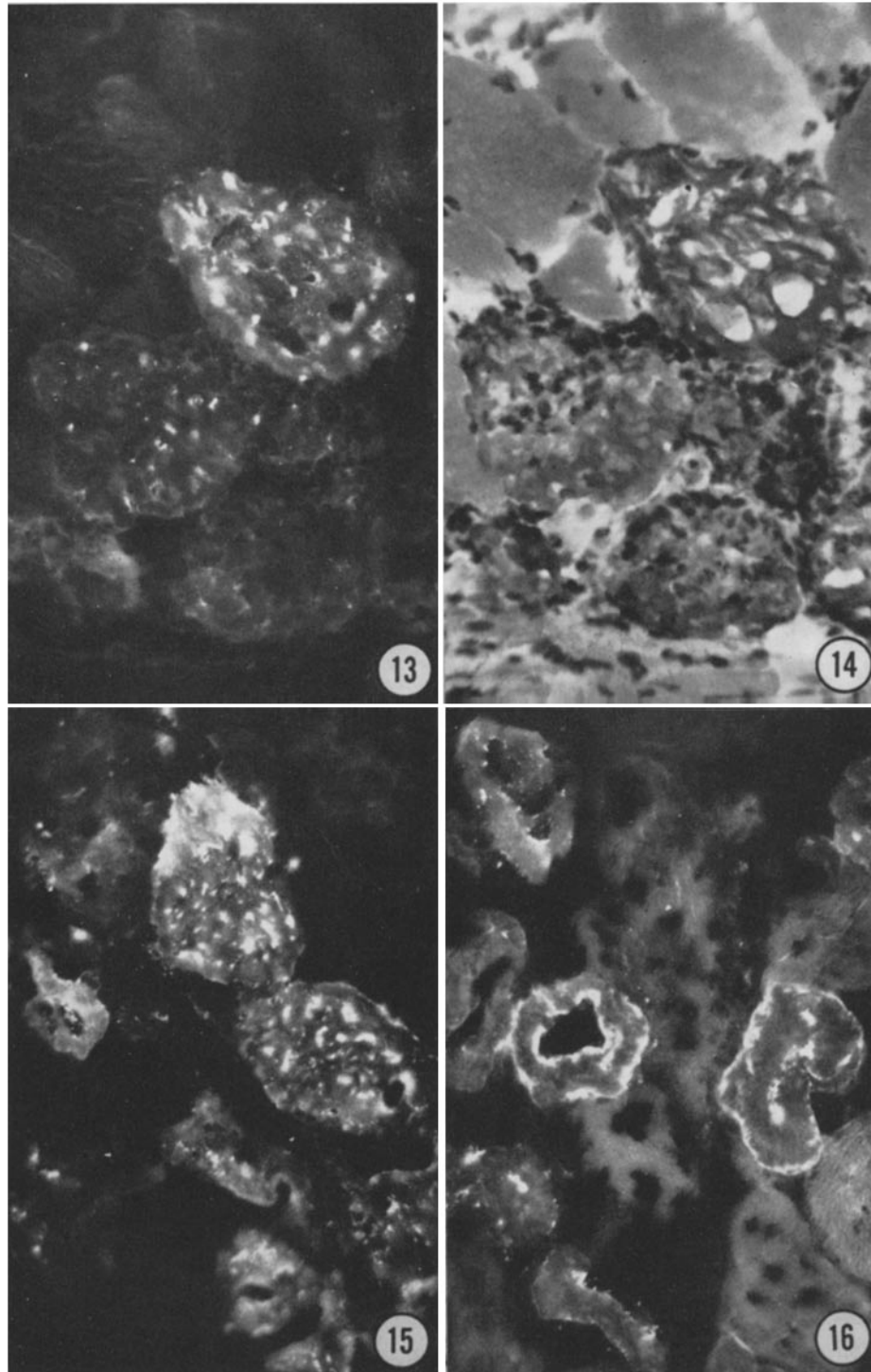
(Kushner and Kaplan: Localization of Cx-reactive protein)

PLATE 92

FIG. 13. Rabbit 8-77, 45 hours after injection of typhoid vaccine. CxRP is localized to inclusions and vacuoles of necrotic myofibers. $\times 312$.

FIG. 14. Same section as Fig. 13, restained with hematoxylin and eosin. Necrotic appearance of CxRP-containing myofibers is evident. Normal-appearing myofibers as at upper left contain no CxRP. Note large number of polymorphonuclear and mononuclear cells within and around necrotic muscle, in which CxRP could not be demonstrated. $\times 312$.

FIGS. 15 and 16. Muscle sections from rabbit 7-40, rendered granulocytopenic by injection of nitrogen mustard, and sacrificed 24 hours after typhoid vaccine injection. CxRP localized within necrotic muscle fibers in cell periphery and in vacuoles. Hematoxylin and eosin sections revealed only an occasional inflammatory cell in this area. $\times 250$.



(Kushner and Kaplan: Localization of Cx-reactive protein)