

THE VACUOLATING VIRUS OF MONKEYS

II. VIRUS MORPHOLOGY AND INTRANUCLEAR DISTRIBUTION WITH SOME HISTOCHEMICAL OBSERVATIONS*

BY W. H. GAYLORD, JR., PH.D., AND G.-D. HSIUNG, PH.D.

(From the Department of Epidemiology and Public Health,
Yale University School of Medicine, New Haven)

PLATES 94 TO 97

(Received for publication, July 10, 1961)

The vacuolating virus SV₄₀ has been recognized as an entity for a relatively short time. Sweet and Hilleman (17, 18) summarized some of the characteristics of the virus but there has been available no information regarding its morphology or intracellular distribution. More recent observations (9) have shown that cells infected with the vacuolating virus often display well marked, intranuclear, inclusion bodies. The inclusions usually appear in advance of cytoplasmic vacuoles and, as a consequence, it seemed probable that the origin of the virus was in the nuclei of infected cells. For that reason, the following observations were directed toward a study of the nuclear events following infection and, more specifically, toward a description of the virus particle and its intracellular distribution.

Materials and Methods

Virus.—Two strains of vacuolating virus (SV₄₀) were studied. One, PA-57, was isolated by one of us from a patas monkey (*Erythrocebus patas*) kidney culture in 1957 and carried since that time in patas cultures. Two lines of this strain (including two passage levels of one line) were examined.

Strain VA 45-54 (Sweet and Hilleman), obtained through the courtesy of Dr. Hilleman, was received as the first subculture in grivet monkey (*Cercopithecus aethiops*) kidney cultures. It was carried in patas cultures in this laboratory.

Cells.—Cultures of patas monkey kidney and human kidney were prepared as described previously (10). All cells were seeded on coverslips in Leighton tubes.

Fixation and Staining.—Cells prepared for light microscope studies were stained as routine with hematoxylin and eosin after fixation in Zenker's solution, as described in the preceding paper. For special purposes, however, preparations were stained with hematoxylin and eosin after fixation in 10 per cent buffered formalin, Carnoy's solution, or after Carnoy's fixation followed by hydrolysis in hydrochloric acid, as for the Feulgen reaction.

The Feulgen reaction was performed on cells after fixation in Carnoy's solution for varying periods of time, from several minutes to several days, without noticeable differences. In our

* Aided by Grant No. E-127B from the American Cancer Society, Inc., and by a grant from the National Foundation.

hands, optimal staining was achieved for cultured monolayers by hydrolyzing for 10 minutes in one-normal HCl at 58°C (nom. 60°) followed by the application of Schiff's reagent for 30 minutes. A water rinse was used but no metabisulfite. Counterstaining, when it was done, consisted of a 30 second dip in a 0.5 per cent light green SF yellowish solution made up in 90 per cent ethonol to which two drops of aniline was added (15). For comparison, light green, alone, was used after hydrolysis omitting Schiff's reagent.

The histone reaction of Alfert and Geschwind (1) was carried out as published except for the fact that light green was substituted for fast green at a pH of 8.0 after extraction with trichloroacetic acid.

Palade's method of fixation (12) was employed for electron microscopy (2 hours' fixation and 30 minute intervals of dehydration). No special electron stains were used before or after methacrylate embedding.

Procedure.—The virus under study was isolated from a spontaneous infection of patas kidney cells and there always existed a possibility that it, or another indigenous simian virus, might have been present in the patas cells used for these experiments. Such an eventuality could have lead to misleading, if not erroneous, interpretations. Accordingly, the following precautions were taken in order to minimize chances for misinterpretation. Electron microscopic observations were made from repeat experiments done several months apart to insure that cells were obtained from different monkeys. Both times, however, strain VA 45-54, and strain PA-57 were examined. Hence, direct comparisons were carried out on both viruses propagated in cells derived from the same monkey and, again, from a monkey sacrificed at a different time. The latter experiment included Feulgen reactions and hematoxylin and eosin-stained preparations in parallel. Uninoculated controls from the same series were held for 3 weeks without the appearance of cytopathology.

Most observations of hematoxylin and eosin-stained preparations were carried out on a time sequence experiment in cells derived from a third monkey. Coverslips were taken for fixation every 2 hours after inoculation until 10 hours, and daily thereafter for 9 days as described in the accompanying paper.

Findings by Light Microscopy

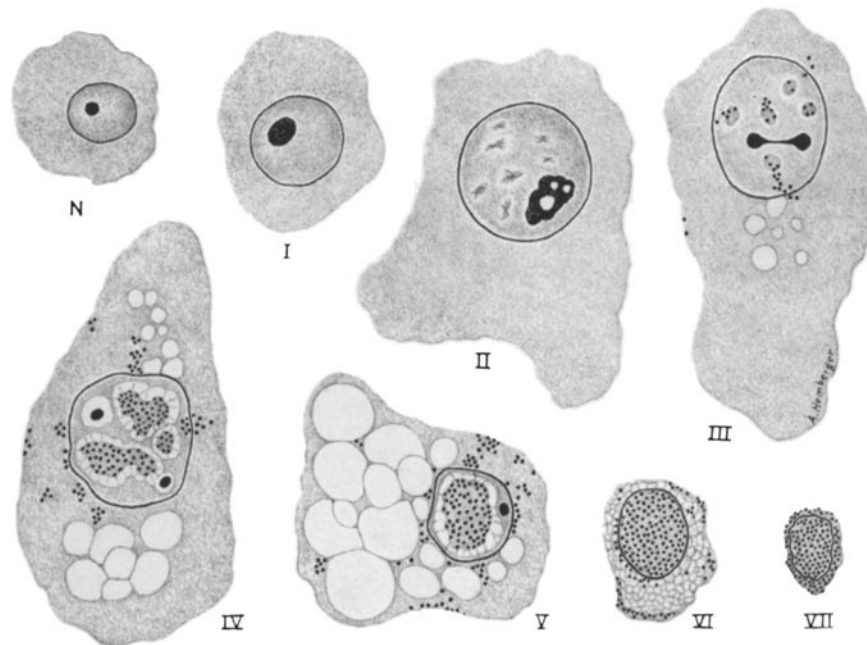
Controls.—The dominant cell type seen in patas monkey kidney cultures was a large, flattened, epithelioid cell. These cells, usually arranged in sheets, contained large oval nuclei and often displayed at least two nucleoli. Smaller, more densely staining cells, aligned in rows, occurred at the conjunctions of the sheets of large cells. They were assumed to be imperfectly formed or degenerating variants of the dominant type because the rows appeared as more populated, dense, cellular ropes in older cultures. Infrequently, cells of a second, fibroblast-like, type did appear in small clusters. Little significance was assigned to them because of their rarity.

A considerable variation in cell, and nuclear, size was always present, with the result that there was an overlap in the sizes of "normal" and infected nuclei. Some cytoplasmic vacuoles were seen in control cultures. They were interpreted as normal for older cultures and were not as striking or extensive as the specific vacuoles for which the virus under study was named. At no time were intranuclear inclusions detected in control cultures.

Inoculated Cultures.—As noted in a previous communication (10), infection with PA-57 results in nuclear swelling, inclusion body formation, and cytoplasmic vacuolization, in that order. The present comparative studies have revealed no morphologically distinguishable differences between PA-57 and VA 45-54; consequently, no attempt has been made to differentiate one from the other in the following observa-

tions. The various morphological changes seen in infected cells are arranged schematically in Text-fig. 1 and tabulated in Table I. A summary of staining reactions is presented in Table II.

Swelling.—Foci containing numerous greatly distended nuclei, with and without inclusion bodies, were present in inoculated cultures after the 1st day (Fig. 1). The enlarged nuclei were generally, but not always, found in cells with a correspondingly enlarged flat, spreading cytoplasm. Whereas normal nuclei were ellipsoidal with axial ratios in the neighborhood of 2:3, the “meganuclei” appeared ballooned to an almost



TEXT-FIG. 1. Diagrammatic presentation of the pathological stages described in Table I (N represents an uninfected or “normal” tissue culture cell). The proposed sequence is a composite based on time studies of cell populations.

round shape with diameters two to three times the length of a normal nuclear major axis (Fig. 1). Meganuclei appeared to have no distinctive tinctorial properties when stained with hematoxylin and eosin except for a tendency toward increased basophilia. Feulgen reactions yielded mixed results. Some large nuclei showed a normal-appearing Schiff-positive network or stippling in contrast to others which were deeply stained.

Giant nuclei displaying generalized, basophilic stippling (Fig. 1) or early, prophase-like, basophilic clumps were seen, occasionally, in recently infected cultures. Although mitotic figures were common in cultures representing early infection (Fig. 8), there was an almost total absence¹ of any further mitotic evolution in meganuclei and the observed chromatin rearrangement may not have been prophase mitosis.

¹ Chromosomes were encountered in large nuclei only once. For the present, this observation must be regarded as an anomaly.

Inclusion Bodies.—Inclusions were detectable by the 2nd day after infection. Hematoxylin and eosin-stained nuclei displayed multiple, small, amorphous, eosinophilic patches seen as randomly distributed discontinuities in the chromatin network (Fig. 2). Occasionally, a diffuse, eosinophilic blush underlying the normal basophilic chromatin could be seen. It was interpreted as a more widespread, and perhaps earlier, manifestation of the same change. Less often, the sum of both stains was observed as a purple resultant.

Nucleoli, at this stage, were greatly enlarged structures displaying bizarre shapes. They were frequently pervaded with large and small cavities giving them a moth-eaten or spongiform appearance (Fig. 11). Nucleoli in contact with the nuclear mem-

TABLE I
Summary of Cellular Changes Resulting from SV₄₀ Infection

Stage	Nucleus	Nucleolus	Chromatin	Cytoplasm	Virus
I	Swells	Enlarges	No change	Extends	None seen
II	Greatly distended	Assumes bizarre shapes; often appears moth-eaten or spongiform	Basophilic clumping	Spreads extensively in all directions; vacuoles can occur	None seen as a rule
III	Slightly distorted	Fragments	Eosinophilic patches appear randomly scattered	Vacuoles appear at nuclear membrane	Small amounts in nucleus, leaks to cytoplasm
IV	Becomes distorted	Shrinks	Moth-eaten chromatin; eosinophilic inclusions coalesce	Vacuoles increase in number and size	Present in large numbers in inclusions; some leakage to cytoplasm
V	Shrinks	Pushed to nuclear margin	Nearly gone except for marginal rim (replaced by virus)	Vacuoles greatly distended, coalesce, replace entire cytoplasm	Fills nucleus; some in all parts of cytoplasm
VI	Consolidated mass	?	Gone	Shrunken consolidated mass	Nucleus solid mass of packed virus
VII	Whole cell shrunken mass of virus				

brane were observed repeatedly and, at times, long extensions could be seen leading from deep-seated nucleoli to the nuclear membrane.

Later preparations, taken at daily intervals, showed a progressive increase in numbers of nuclei containing fewer but larger amorphous accumulations of acidophilic substance (Figs. 2, 3). These larger accretions were easily recognizable "inclusion bodies." They were surrounded by clear halos through which ran fine connecting strands (Fig. 4). At this stage, nucleoli were reduced to small, round, very dense structures which seemed to persist throughout all subsequent stages of nuclear change. Single, large inclusions completely filling the nucleus (except for the nucleolus and halo) could be seen, but not often enough to consider them an invariable end-product (Fig. 3). (Possibly, such cells fall off of the supporting glass, leaving a biased sample. There is some reason to believe that they do.) Despite the apparently drastic alterations of swelling, inclusion formation, and shrinkage, nuclei appeared to remain intact throughout the course of infection and karyorrhexis was not a prominent feature.

Inclusions were intensely Feulgen-positive (Fig. 6). In those instances when all of the chromatin network had been replaced by acidophilic substance, the entire nucleus appeared a uniform red (Figs. 6, 9, 10). The acid dye, light green, when used alone, was also readily accepted by the inclusion material causing the inclusion bodies to be a bright green (Fig. 7). Furthermore, it was found that inclusions accepted both stains at the same time giving a bluish or greenish-grey color (Fig. 8). No other structure (including chromosomes) in infected cultures or controls was similarly stained. The reaction was, therefore, specific for inclusion bodies in these experiments.

Light green, at pH 8, failed to stain inclusion bodies after trichloroacetic acid extraction. Phase microscopy indicated that inclusions were homogeneous for that level of resolution and of a low density in comparison to nucleoli. Polarized light failed to

TABLE II
Staining Reactions of SV₄₀ Inclusion Bodies

Stain	Fixative	Other	Inclusions	Chromatin	Nucleoli
Hematoxylin and eosin	Zenker's		Acidophilic	Basophilic	Basophilic
"	Formalin		"	"	"
"	Carnoy's		"	"	Acidophilic
"	"	HCl-hydrol.	"	"	"
Feulgen with light-green counterstain	"		Grey	Red	Green
Feulgen	Carnoy's	No counter-stain	Red	Red	—
Light-green		HCl-hydrol-ysis	Green	Green	Green
Light-green pH 8		TCA-extracted	—	Green	Green

show anisotropy and no crystal-like structures were observed in infected nuclei. There was no obvious correlation between any stage of inclusion formation and cytoplasmic vacuoles except the previously mentioned timing. That is, inclusions appeared about 48 hours before vacuoles. Vacuoles, after they did appear, continued to be present in increasing size and number with each subsequent time interval until the entire cytoplasm was filled. Although such cells were greatly distorted they did not lose their integrity. Syncytia were observed rarely and, in most preparations, not at all.

Findings by Electron Microscopy

The morphological findings presented above were gleaned from observations of whole cells, whereas the following descriptions refer exclusively to sectioned material. In general, structures seen with the light microscope were readily identifiable in the electron microscope and transition from one system to the other entailed little difficulty. The most obvious deviation was not unexpected. Reissig, with Melnick (14) and

with Black and Melnick (5), had shown that the circumscriptive halos of herpes and measles inclusions are artifacts. They do not exist after osmium fixation, whether viewed by light or electron microscopy. Predictably, no halos were seen in the present electron microscopic study of SV₄₀.

Those nuclear zones corresponding to inclusion bodies were sharply outlined, however, by an abrupt cessation of the normal chromatin pattern (Fig. 5). Within the zones so outlined there were distinctive virus-like particles. Exceptionally large numbers were observed in some, but not all, cells from all inoculated cultures examined. Morphologically identical particles were found in preparations of both PA-57 and VA 45-54 inoculated material but not in control cells from uninoculated cultures. The particles comprised a uniform population of regular, small, round, corpuscles with diameters of 300 Å ± 10 per cent (Fig. 10). They were of low electron density without dense centers and, occasionally, they appeared hollow (Fig. 12). At times, particles could be seen attached one to another, in a linear fashion to form short chains or strings of beads.

Although they were seen most often, and in the greatest numbers, in nuclei, particles were often observed in the cytoplasm of affected cells, especially in the vicinity of the nuclear membrane. Virus was not in the cytoplasmic vacuoles, as a rule, but not many vacuoles were seen. (Cultured cells tend to lie flat on the glass and the vacuoles may be in such thin portions of the cytoplasm that they appear in section as protoplasmic strands or detritus unless viewed *en face*. The more turgid nuclei stand out much better.)

Within nuclei, virus was present in areas devoid of chromatin, giving the impression that one was replaced by the other. In those nuclei containing little virus, the particles were in close association with chromatin and, in more advanced stages, islands of residual chromatin were seen surrounded by virus chains. Transitional zones between chromatin and virus presented a complex picture. As seen in very thin section, chromatin consisted of beaded, highly irregular, branching strands with ill-defined nodules, kinks, and annular interconnections (Fig. 12). Virus particles in very thin sections appeared as ringlets, often with adherent strands of chromatin and usually distorted from the round. In those places where virus and chromatin met, it was often not possible to differentiate between virus enmeshed in the chromatin net and the small rings of interconnected chromatin threads.

Careful search of nucleoli did not produce any convincing evidence that this structure was the site of virus origin (although nucleoli were seen which were infiltrated with particles when virus was present in great numbers throughout the entire nucleus). From time to time, structures reminiscent of nucleoli were observed which lacked the granular RNP component of Palade (13). These agranular "nucleoli" were composed of closely aggregated threads indistinguishable from threads comprising the chromatin network and continuous with it. However, their heavy concentration, size, shape, and distribution in the nucleus all tended to identify them with nucleoli rather than clumps of chromatin.

DISCUSSION

The cytopathology of SV₄₀ virus infections in patas cultures is independent of the virus origin, rhesus, or patas monkeys. Intranuclear inclusions are distinct and directly attributable to virus activity. Cellular hypertrophy and

vacuole formation are regular features and the entire process suggests a slow-growing, intranuclear virus infection with continuous leakage to the cytoplasm.

The first observable response of affected cells is usually a pronounced hypertrophy. Although it is undoubtedly the result of infection, the direct cause of swelling remains a matter for conjecture. Manuelidis (11) has pointed out that the pathological swelling and vacuolization of cells *in vitro* and *in vivo* is a common manifestation of cellular distress. In the cells under study, avacuolar swelling was the earliest reaction seen and vacuolization was a late development. Marked swelling of the nucleus was characteristic and, at times, it was not accompanied by a cytoplasmic increase. Nuclear swelling is not a reflection of the presence of large numbers of virus particles because it was virtually impossible to find virus, electron microscopically, in swollen nuclei of the "early" variety. The pronounced enlargement of nucleoli seen at this time would indicate an increase in cellular activity and the term "growth" might apply more aptly than "swelling." Staining reactions, even of early swelling, give little indication of dilution and the imbibition of excess water seems unlikely. In any event, it would appear that the initial effect of an invading virus is on the host cell nucleus.

Aside from evidence of continued nucleolar activity in large nuclei the only remarkable finding prior to chromatolysis is a scattered clumping of the chromatin. The phenomenon was difficult to demonstrate consistently and, when found, it resembled early prophase. However, no further mitotic stages were demonstrable in meganuclei and it is assumed that the clumping represents early pathology. Possibly, mitotic arrest at prophase occurs after infection but there seems to be no accumulation of prophase cells. Alternatively, it may be that resting cells and those in prophase are susceptible to infection but not cells in more advanced stages. This would account for the fact that clumping was difficult to demonstrate but it would require that the chromosomes maintain their integrity during nuclear swelling. We think that chromatin clumping is a real but fleeting expression of infection.

The ensuing events are much clearer. Scattered, focal lysis of the chromatin network occurs. In place of the chromatin there appear acidophilic patches which enlarge and coalesce to form readily discernible inclusion bodies. They contain virus and they are Feulgen-positive. That they are, in fact, acidophilic is borne out by their acceptance of the acid stain, light-green, concurrently with Schiff's reagent. There can be little doubt that the inclusion is biphasic but electron micrographs show only a single morphological entity, the virus particles. Admittedly, the virus must be suspended in a ground-substance or nuclear sap of some sort. Nevertheless, nuclei can be seen which are so densely packed with particles that there is room for little else and the intervening spaces are of very low electron density indicating a paucity of potentially reactive molecules.

It is plain from the Feulgen reaction that one component is DNA, but the

nature of the other component is more equivocal. Presumably, it is protein and, apparently, not a histone. It is acidophilic when stained with eosin or with light-green alone (after hydrochloric acid hydrolysis) at a pH of 4.5. Light-green at pH 8 did not stain inclusions which had been subjected to trichloroacetic acid extraction. The substitution of light-green for fast-green in this modification of the technique of Alfert and Geschwind (1) ought not to change its specificity and histone may be ruled out accordingly.

That the inclusions should be both acidophilic and Feulgen-positive is unusual.² Chromosomes were distinctly basophilic in the same preparations, even after acid hydrolysis. Neither they, nor any other cellular elements assumed the greenish or bluish-grey hue displayed by inclusion bodies. In these experiments, the grey color reaction was peculiar to inclusion bodies and inclusion bodies, in turn, were found to be almost pure virus. As a result, the reaction is considered to be a virus-specific stain for light microscopy.

The picture of a small, 300 A, virus packed in the nuclei of infected cells is not unique, having been first described in 1953 by Bunting (6). It should be emphasized, however, that inclusion bodies of the vacuolating virus are of Cowdry's type A and not type B. Other morphological parallels exist (2, 4, 7, 8, 16) but there are some differences, at least in interpretation.

We have been unable to convince ourselves that nucleoli are the site of virus formation as has been suggested for two other similar viruses (16, 7). Instead, it appears as if chromatin threads throughout the nucleus can be converted into virus. Granting that nucleoli might be favored sites of production under some conditions, in the vacuolating virus infected nuclei, it was more common to find virus nested in regions of lysed chromatin than in nucleoli. Furthermore, as seen in light microscopic preparations of whole cells, the inclusions began as small randomly scattered foci not necessarily oriented around nucleoli. It is possible that the distribution of RNA is a limiting factor. In the case of the vacuolating virus there is a definite eruption of nucleolar activity. Nucleoli enlarge early in the infectious process, cavitate, fragment, and then shrink down to small persistent remnants. RNA is widely distributed as a result of such marked hyperactivity and possibly the necessary "sites" for virus formation are more randomized because of it. It is reasonably certain that the virus is a DNA virus and there is fragmentary electron microscopic evidence that chromatin does actually convert to virus.

SUMMARY

Cells infected with the vacuolating virus, SV₄₀, respond by swelling to several times their normal volume. Within enlarged nuclei, virus-containing inclusions appear which are acidophilic and Feulgen-positive. The formation of nuclear

² A parallel observation seems to have been made by Bereczki (3) but appears to differ in certain respects. A full report has not been seen.

inclusions is followed by the appearance of cytoplasmic vacuoles and then shrinkage of the cell. Inclusions were found to exhibit unique double staining when a light-green counterstain was used in the Feulgen reaction. The virus is of low electron density, round, and 300 Å in diameter. It occurs in large numbers, singly and in short chains, and it appears to multiply at the expense of chromatin.

We are indebted to Mrs. Mary Garrison and Mrs. Grace Tucker for their care and skill in the biological arts, especially experimental staining.

BIBLIOGRAPHY

1. Alfert, M., and Geschwind, I., A selective staining method for the basic proteins of cell nuclei, *Proc. Nat. Acad. Sc.*, 1953, **39**, 991.
2. Banfield, W. G., Dawe, C. J., and Brindley, D. C., Intracellular and extracellular particles in tissue cultures inoculated with parotid-tumor agent (polyoma virus), *J. Nat. Cancer Inst.*, 1959, **23**, 1123.
3. Berezcki, E. Comment by L. Dmochowski, *Nat. Cancer Inst. Monograph No. 4*, 1960, 209.
4. Bernhard, W., Febvre, H. L., and Cramer, R., Mise en évidence au microscope électronique d'un virus dans des cellules infectées *in vitro* par l'agent du polyome, *Comptes Rend. Acad. Sc.*, 1959, **249**, 483.
5. Black, F. L., Reissig, M., and Melnick, J. L., Measles virus, *Adv. Virus Research*, 1959, **6**, 205.
6. Bunting, H., Close-packed array of virus-like particles within cells of a human skin papilloma, *Proc. Soc. Exp. Biol. and Med.*, 1953, **84**, 327.
7. Edwards, G. A., Comparative micromorphology of normal, transforming, and malignant cells, *Nat. Cancer Inst. Monograph No. 4*, 1960, 313.
8. Howatson, A. F., and Almeida, J. D., An electron microscope study of polyoma virus in hamster kidney, *J. Biophysic. and Biochem. Cytol.*, 1960, **7**, 753.
9. Hsiung, G.-D., Abstract, *Bact. Proc.*, 1961, 151.
10. Hsiung, G.-D., and Gaylord, W. H., Jr., The vacuolating virus of monkeys. I. Isolation, growth characteristics and inclusion body formation, *J. Exp. Med.*, 1961, **114**, 975.
11. Manuelidis, E. E., Pathological swelling and vacuolization of cells, *in* *Frontiers in Cytology*, (S. L. Palay, editor), New Haven, Yale University Press, 1958, 417.
12. Palade, G. E., A study of fixation for electron microscopy, *J. Exp. Med.*, 1952, **95**, 285.
13. Palade, G. E., A small particulate component of the cytoplasm, *J. Biophysic. and Biochem. Cytol.*, 1955, **1**, 59.
14. Reissig, M., and Melnick, J. L., The cellular change produced in tissue cultures by Herpes B virus correlated with the concurrent multiplication of the virus, *J. Exp. Med.*, 1955, **101**, 341.
15. Semmens, C. S., and Bhaduri, P. H., A technique for differential staining of nucleoli and chromosomes, *Stain. Technol.*, 1939, **14**, 1.
16. Stone, R. S., Shope, R. E., and Moore, D. H., Electron microscope study of the

- development of the papilloma virus in the skin of the rabbit, *J. Exp. Med.*, 1959, **110**, 543.
17. Sweet, B. H., and Hilleman, M. R., The vacuolating virus, SV₄₀, *Proc. Soc. Exp. Biol. and Med.*, 1960, **105**, 420.
18. Sweet, B. H., and Hilleman, M. R., Detection of a "non-detectable" simian virus (vacuolating agent) present in rhesus and cynomolgus monkey-kidney cell culture material. A preliminary report. Second International Conference on Live Poliovirus Vaccines, *Pan. Am. Health Org. and World Health Org.*, 1960, 79.

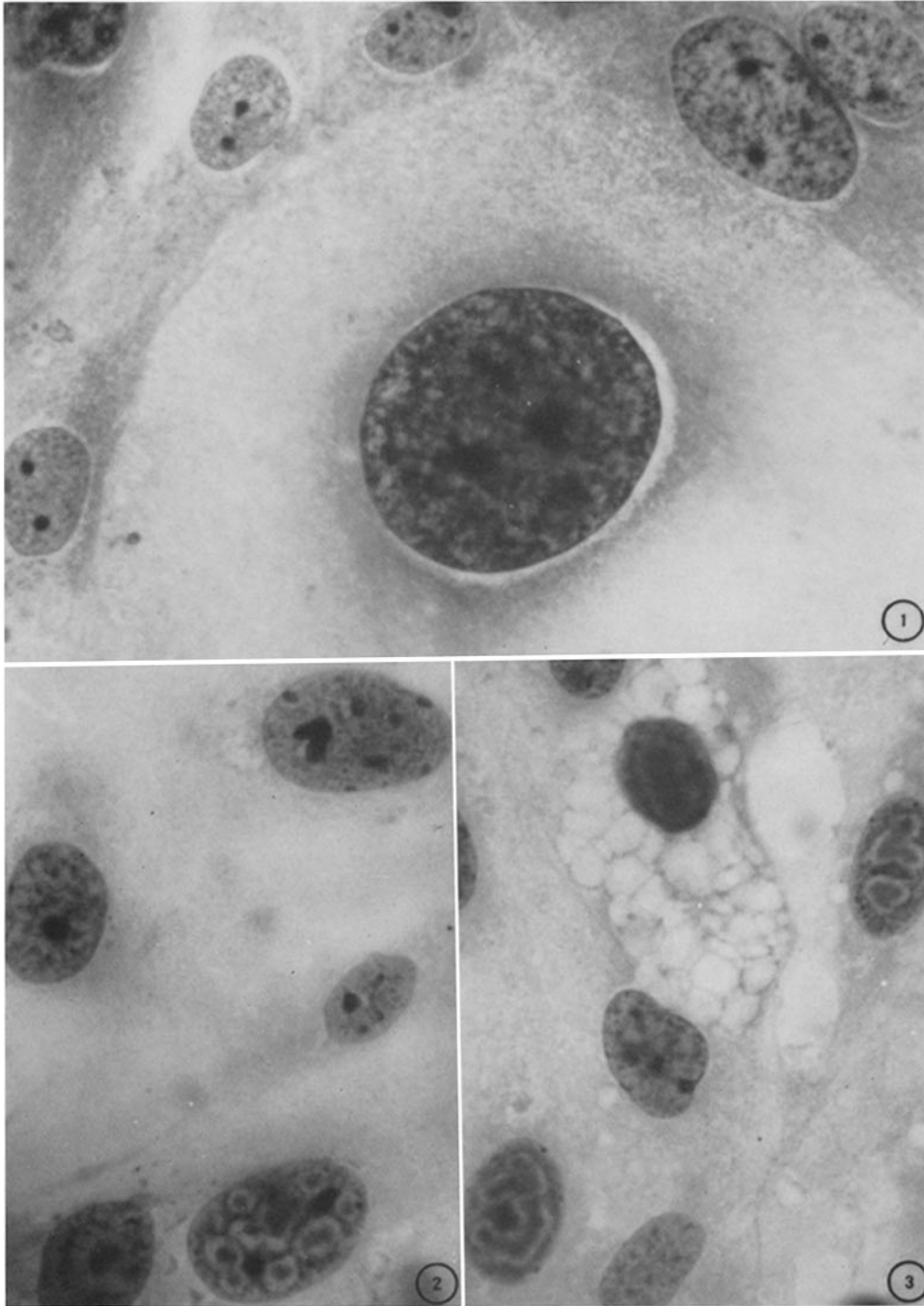
EXPLANATION OF PLATES

PLATE 94

FIG. 1. Early stages of SV₄₀ virus infection in patas monkey kidney cells. Nuclei in upper right corner show early swelling (stage 1) and chromatin clumping. Remarkably large central cell is in stage 2 with basophilic nuclear granules, hyperactive nucleoli (two central densities), and extensive cytoplasmic spreading. Nucleus is 40 μ in diameter and entire cell is about 125 μ in length. Lower two micrographs are presented at the same magnification for comparison. Zenker's fixation, hematoxylin and eosin stain. \times 1200.

FIG. 2. Nucleus at upper right is in third stage of infection. Dense, inverted "V" is the nucleolus, other dense spots are eosinophilic "patches." Note random distribution relative to nucleolus. Nucleus at bottom center shows the beginning of stage four. Small, multiple, eosinophilic inclusions are larger than patches described above and surrounded by clear halos. Carnoy's fixation, hematoxylin and eosin stain. \times 1200.

FIG. 3. Nucleus at right shows the beginning of inclusion enlargement and fusion. Nucleolus is in center. Inclusion body in nucleus at lower left margin shows more advanced fusion in the form of a horse-shoe around the nucleolus. Cell at top center has single consolidated inclusion and extensive cytoplasmic vacuolization. This preparation was subjected to HCl hydrolysis before staining for comparison with Figs. 6 to 8. Carnoy's fixation, hematoxylin and eosin stain. \times 1200.



(Gaylord and Hsiung: Vacuolating virus of monkeys. II)

PLATE 95

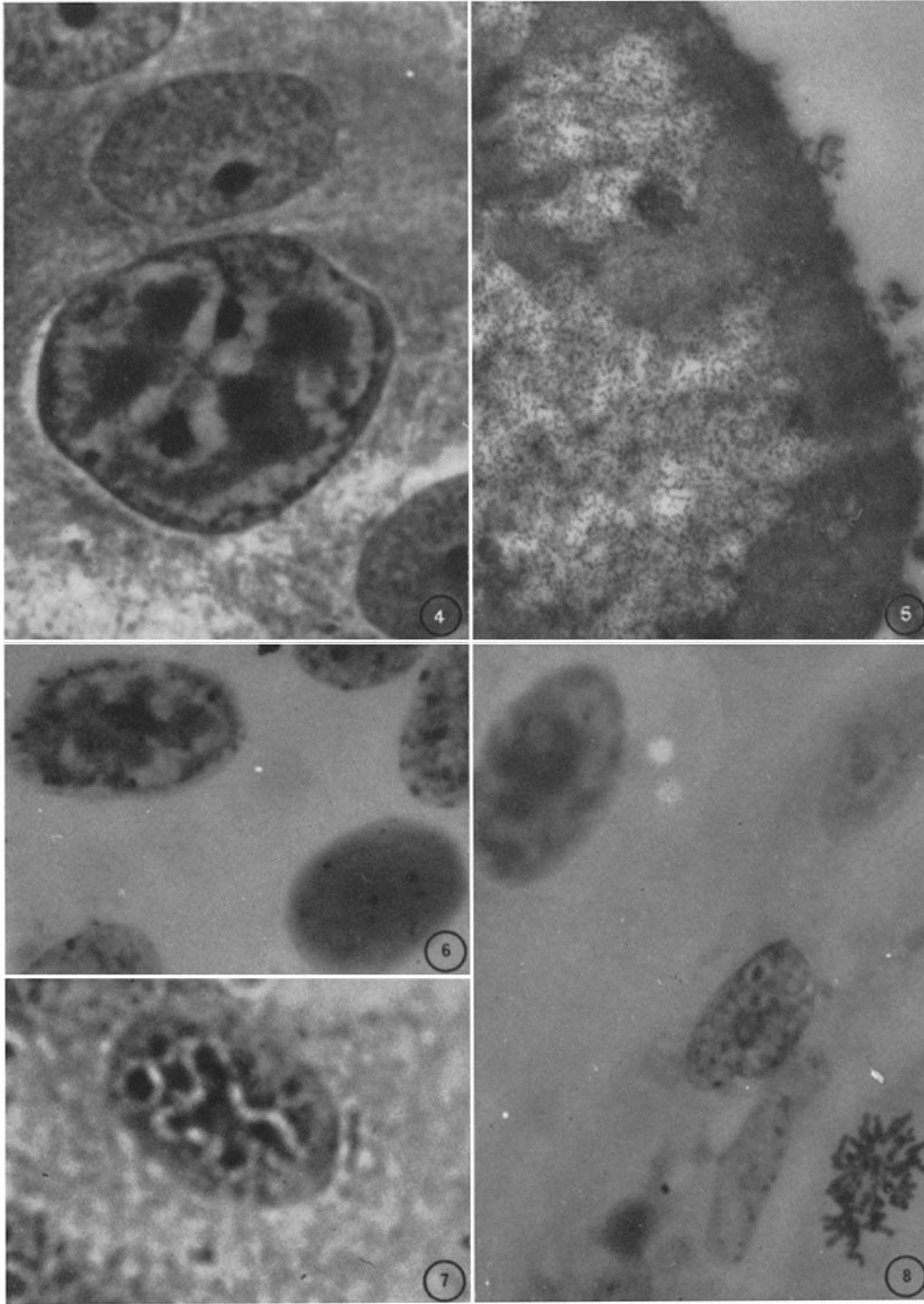
FIG. 4. Detail of SV₄₀ virus-induced intranuclear inclusion body as seen in light microscopy. Two very dense central spots are nucleoli. Four diffuse dense areas are abnormal eosinophilic material. Connecting bridges of the same substance indicate tendency of separate foci to coalesce as they enlarge. Surrounding "clear" halo is laced with karyoplasmic strands resulting from fixation shrinkage. Sharp, basophilic line separates halo from basophilic marginal chromatin and external halo indicates slight shrinkage of entire structure. Whole mount, Zenker's fixation, hematoxylin and eosin stain. $\times 1850$.

FIG. 5. Portion of a stage-four nuclear inclusion. No halo is present in osmium-fixed cells. Marginal chromatin is a grey mass of threads and appears to be partially "eaten" away. Areas devoid of chromatin correspond to eosinophilic inclusion body and contain numerous virus particles. Electron micrograph. $\times 16,500$.

FIG. 6. Feulgen reaction, no counter-stain. Inclusion body at upper left is red, indicating a DNA virus. Nucleus at lower right is entirely and uniformly stained by Schiff's reagent. It is probably packed with virus, as in Fig. 10. Carnoy's fixation. $\times 1650$.

FIG. 7. Inclusion body stained with light green after having been subjected to HCl hydrolysis (at the same time as the cells in Fig. 6). Affinity for this acid dye and for eosin tends to indicate protein in the same general area as the DNA. Sole structures with appreciable electron density seen in similar areas are virus particles. Carnoy's fixation. $\times 1850$.

FIG. 8. Feulgen reaction with light green counterstain. Chromosomes and chromatin of central nucleus are red (and basophilic, see Fig. 3); nucleolus is bright green (and usually eosinophilic after fixation in Carnoy's solution). Nucleus at upper left has taken both stains and is a bluish to greenish-grey color. Only inclusion bodies show the property of double staining. $\times 1350$.

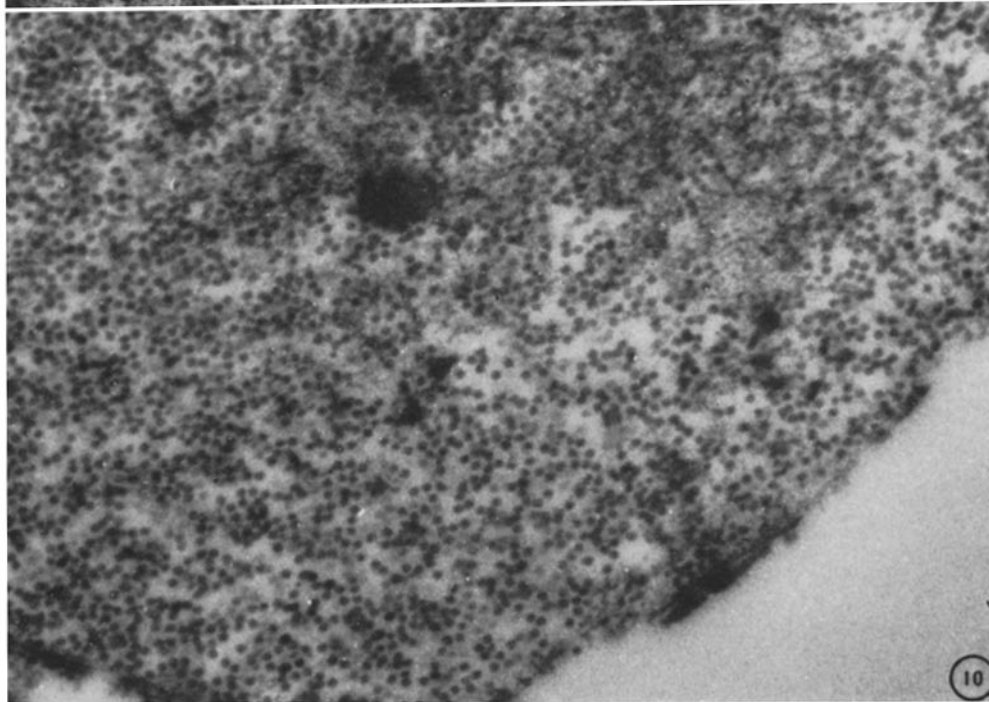
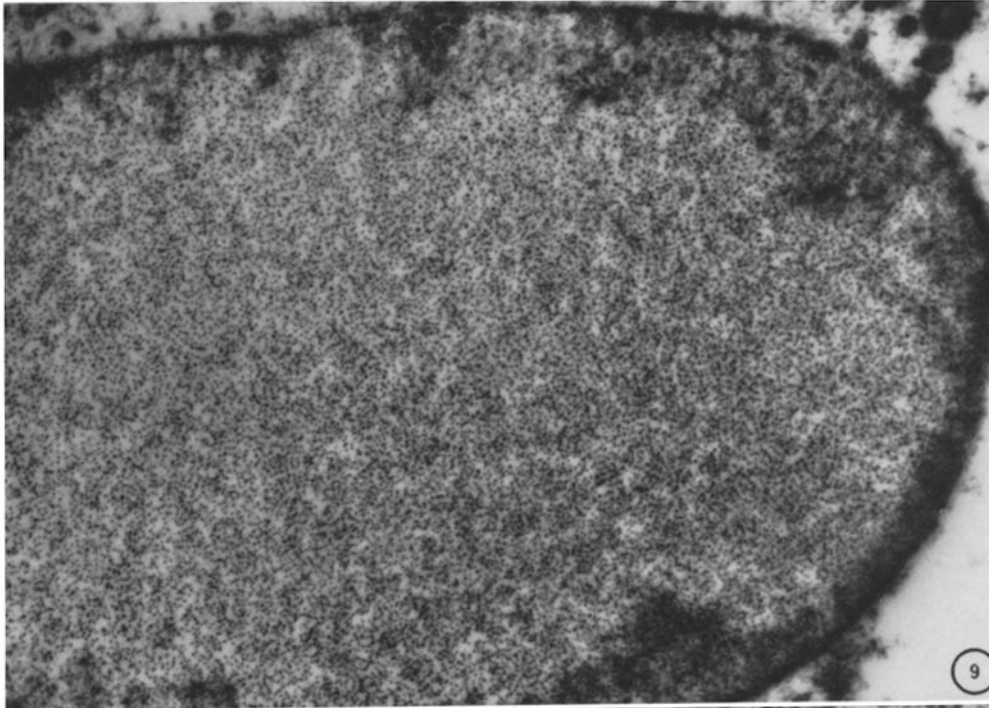


(Gaylord and Hsiung: Vacuolating virus of monkeys. II)

PLATE 96

FIG. 9. Well advanced infection comparable to that seen in cell at top-center of Fig. 3. Nucleus is almost entirely filled with virus. (An estimated 1.3×10^4 particles are visible in this picture.) Scattered residua of chromatin, at periphery, illustrate the inverse correlation between virus and chromatin. $\times 16,500$.

FIG. 10. Appearance of virus in sections having a thickness greater than the length of one particle diameter, *i.e.*, >300 A. Particles are generally round, homogeneous, and of moderate to low electron density. There is a marked tendency toward the formation of short chains, at times branching. $\times 33,000$.

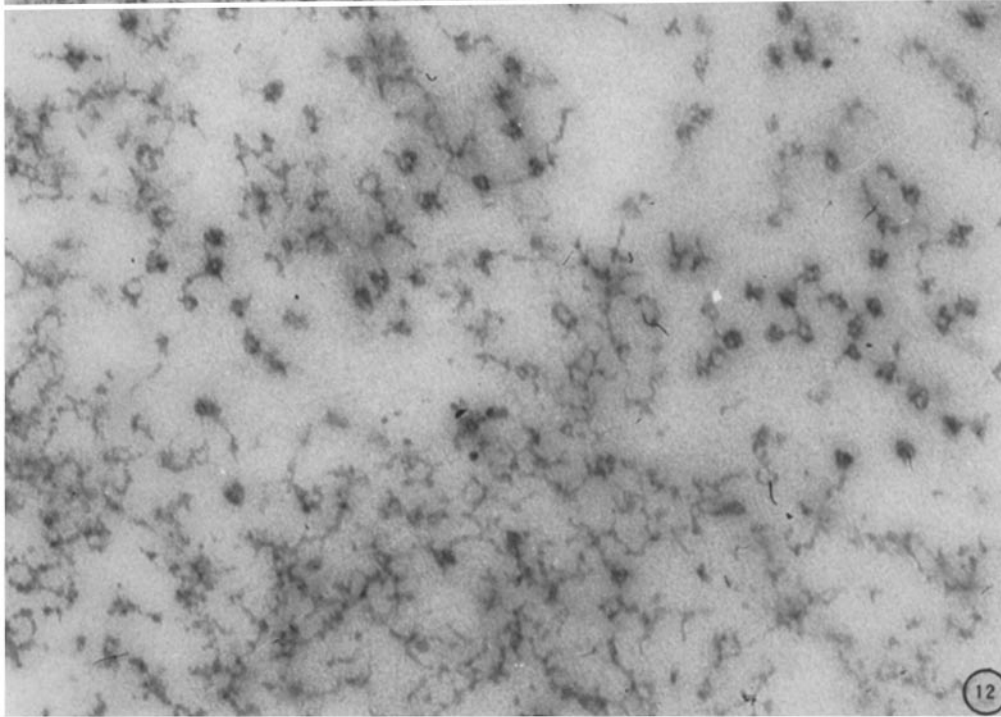
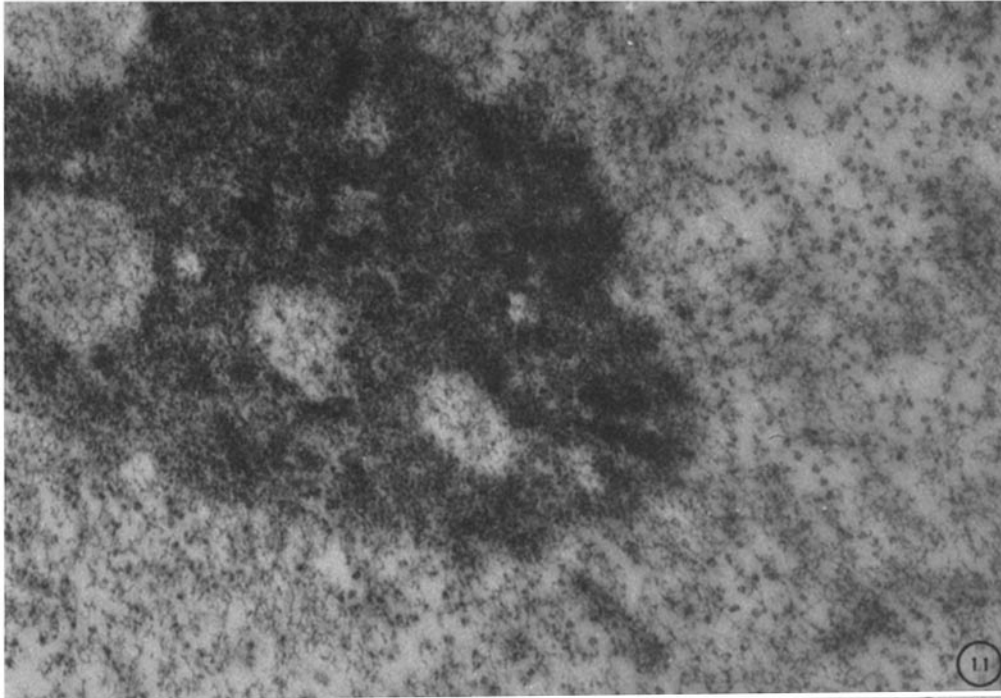


(Gaylord and Hsiung: Vacuolating virus of monkeys. II)

PLATE 97

FIG. 11. Nucleolar region of an infected cell. The enlarged nucleolus is pitted. The discrete foci of low density have typical karyoplasmic threads representing the chromatin network. Similar threads radiating from periphery of the nucleolus are contiguous with the background network. Nuclear areas adjacent to the nucleolus contain quantities of virus but the presence of virus within the nucleolus is debatable. $\times 30,000$.

FIG. 12. Transitional zone between virus containing area and chromatin. Because this is a very thin section, virus particles appear hollow. Loops of the chromatin threads have similar proportions and strands of chromatin adhere to virus particles. At times, it is difficult to distinguish virus from chromatin. $\times 65,000$.



(Gaylord and Hsiung: Vacuolating virus of monkeys. II)