

# The Gow-Gates Technique for Mandibular Block Anesthesia

## A Discussion and a Mathematical Analysis

Michael C. Kafalias, BDS, MDS, MSD, FRACDS\*,  
George A.E. Gow-Gates, MDS, Gary J. Saliba, BSc PhD†

Departments of \*Operative Dentistry and †Applied Mathematics, University of Sydney, Australia

Reliable profound mandibular block anesthesia is questionable when depositing the anesthetic solution at the lingula. Complications can occur and the needle may impact a number of important anatomical structures by deep penetration. The Gow-Gates technique for mandibular anesthesia obviates these problems.

In this paper the Gow-Gates technique is reinterpreted using a geometrical approach based on lines and planes and is proved mathematically. In so doing a simple yet concise method of reaching the injection site is presented with a definite relationship between the anatomical pathway of the needle and a formal geometrical and mathematical pattern.

**T**he key to successful mandibular restorative and surgical procedures with or without sedation is profound regional block anesthesia. It has been acknowledged that mandibular anesthesia attempted by depositing the anesthetic solution at the lingula and other sites using intraoral landmarks leaves much to be desired.<sup>1-4</sup> The mandibular teeth are supplied by a plexus of nerves<sup>5</sup> and the effectiveness of inferior alveolar mandibular anesthesia, when compared to the Gow-Gates mandibular block technique, is shown in Table 1.<sup>4,6-9</sup>

In the conventional inferior alveolar nerve block, one or more puncture points and injection sites involving

three nerves are needed to anesthetize the mandibular nerve. The anesthetic solution is deposited in close proximity to the neurovascular bundle.<sup>10</sup>

Complications and structures potentially at risk from the conventional technique have been reported by Murphy and Grundy.<sup>1</sup> Since the lengths of needles used for mandibular block anesthesia are 35 mm and 41 mm, these authors described a smaller and a larger sector within the pterygomandibular space equivalent to the two needle lengths which include anatomical structures which can be impacted by over deep penetration and/or faulty angulation of the needle. These are, within the smaller sector described, the lingual nerve and the inferior alveolar neurovascular bundle in the pterygomandibular space. The area lateral to the space is protected by the mandibular ramus. The medial area is unprotected and in it there are the following structures:

1. medial pterygoid muscle and several large veins within its substance;
2. the deep part of the parotid gland which limits the pterygomandibular space posteriorly;
3. the front of the internal carotid artery in the carotid sheath;
4. the pharyngeal venous plexus in the lateral part of the retropharyngeal space.

The larger sector described includes the above-mentioned and several additional structures. These are, from lateral to medial side:

1. a tributary of the retromandibular vein;
2. more of the parotid gland;
3. the styloid process and its muscles;
4. the internal jugular vein and vagus nerve within the carotid sheath;
5. the internal carotid sympathetic plexus behind the carotid sheath;
6. the longus capitis muscle. The most posteromedial part of this sector almost reaches the lateral mass of the atlas.

Received November 19, 1986; accepted for publication April 17, 1987.

Dr. Gow-Gates is a private practitioner in Sydney, Australia.

Address correspondence to Prof. M.C. Kafalias, Dental Hospital of Sydney, 2 Chalmers Street, Sydney N.S.W. 2010, Australia.

© 1987 by the American Dental Society of Anesthesiology

ISSN 0003-3006/87/\$3.50

**Table 1.** Success Rate for Mandibular Anesthesia

References	Conventional (%)	Gow-Gates (%)
Robertson <sup>4</sup>	71	92
Malamed <sup>6</sup>	N/A	97.25
Yamada <sup>7</sup>	82	100
Sisk <sup>8</sup>	79	95
Gow-Gates <sup>9</sup>	90.3 91.7	100 100

Frequent complications associated with the injection of the anesthetic solution at the lingula are:

1. trismus by penetration into the medial pterygoid muscle<sup>11</sup>;
2. an increase in extravascular tissue pressure within the pterygomandibular space<sup>12</sup> resulting in loss of the anesthetic solution;
3. in this highly vascular region it is preferable to use anesthetic solutions incorporating vasoconstrictors to avoid the premature loss of anesthesia. Vasoconstrictors, in turn, provide the very real possibility of producing undesirable systemic effects once introduced into the blood stream.

In fact, De Shazer<sup>13</sup> posed the question "Is the inferior alveolar block obsolete?"

## THE GOW-GATES MANDIBULAR NERVE BLOCK

The Gow-Gates technique for mandibular nerve anesthesia<sup>9,14,15</sup> uses extraoral landmarks, a single intra-oral puncture point, and a single injection site without the alteration of the position of the needle. The anesthetic solution is deposited at the lateral side of the condyle just below the insertion of the lateral pterygoid muscle in a relatively avascular area of loose fatty areolar tissue above and away from the neurovascular bundle. This injection site is bounded by the bony surface of the condyle posteriorly, by the lateral pterygoid muscle superiorly, the medial pterygoid muscle and interpterygoid fascia medially, and laterally by the ramus of the mandible. The diffusion of the anesthetic solution is thus controlled, and, with the aid of gravity and biophysical forces (i.e., pulsation of the maxillary artery, muscular function of jaw movement), the anesthetic solution floods the entire pterygomandibular space to reach all three oral sensory portions of the mandibular branch of the trigeminal nerve and other sensory nerves in the region, thus overcoming the need to anesthetize supplementary in-

nervation. Moreover, vasoconstrictors are not required to achieve successful anesthesia.

This flooding action of the anesthetic solution around the nerve trunk complies with the concept of de Jong<sup>16</sup> in that at least 6 mm and preferably 10 mm of nerve length must be exposed to the anesthetic solution to deter impulses from skipping over the blocked segment.

The effectiveness of the Gow-Gates technique has been found to be very high (Table 1). With this technique (if it is carried out correctly) there are fewer complications, and the technique offers a much lower potential of risk when compared with other regional block methods of anesthetizing the lower jaw. Panuska<sup>17</sup> reported that in Honduras a dental hygienist injected 1,200 patients and obtained complete anesthesia in all but two patients.

The incidence of positive blood was zero. The comparative ease of instruction to paramedic personnel with limited anatomy and physiology background attests to the simplicity and safety of the procedure.<sup>17</sup>

The extraoral landmarks used in the Gow-Gates technique are:

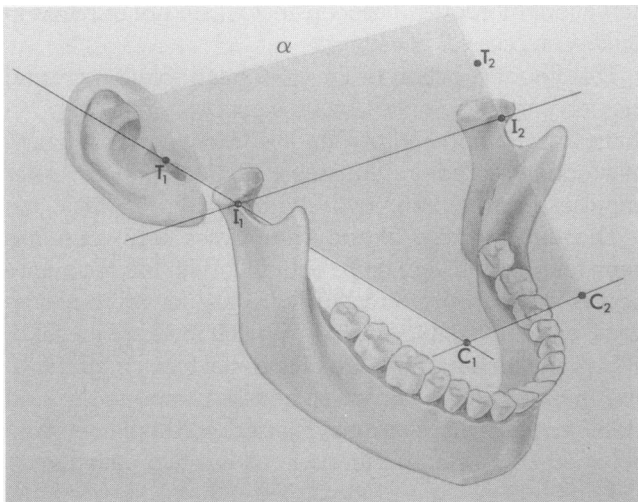
1. the lower border of the tragus of the ear,
2. the corners of the mouth,
3. the angulation of the tragus to the side of the face. (This angulation is variable and has a distinct bearing on the lateral direction of the needle pathway and hence the injection site.)

These landmarks provide the necessary set of points to define two reference planes which have been adopted because they are visible and which are used to guide the needle to the correct puncture point.

This paper presents the relationship of the anatomical pathway of the needle to a formal geometrical and mathematical description of the reference planes used in the Gow-Gates technique. The abstract formulation presented correlates the extraoral landmarks to the puncture and injection sites without the need to rely on an elaborate anatomical and physiological explanation.

## GEOMETRICAL FORMULATION

The first of the reference planes, labeled alpha ( $\alpha$ ) (Fig. 1) is defined by two lines. The first line  $C_1T_1$  passes through the lower border of the tragus ( $T_1$ ) of the ear, and the corner of the mouth ( $C_1$ ). Both of these landmarks are on the same side of the face. Because of the orientation chosen in drawing Fig. 1, the point  $I_1$  (the impact site of the needle at the neck of the condyle) appears to lie on the line  $C_1T_1$  which represents an edge of the  $\alpha$  plane. In fact,  $I_1$  does not lie on  $C_1T_1$  but is located at a position



**Figure 1.** The  $\alpha$  plane is defined by the points  $C_1T_1T_2C_2$ . Although  $I_1$  is shown to be at the edge of the  $\alpha$  plane, it usually found in a more medial position, and not on the line  $C_1T_1$ .

towards the center of the mouth. This is shown more clearly in Figs. 5 and 9 and will be discussed further, below. The second line,  $C_1C_2$ , passes through both corners of the mouth.

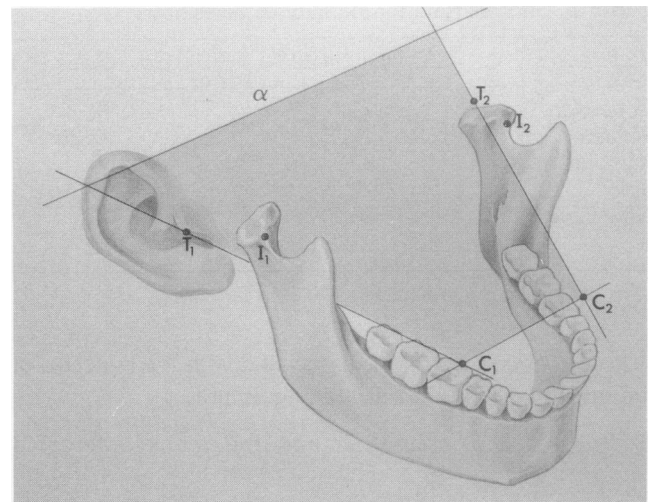
This description of the  $\alpha$  plane is valid only if the mouth is *fully opened*. A full extension of the mouth forces the condyle to lie along the line  $C_1T_1$ . If the mouth is not fully opened, the line  $C_1T_1$  (and hence the  $\alpha$  plane itself) will not pass through the neck of the condyle but through a point lower down (Fig. 2).

The alignment of the needle in the  $\alpha$  plane results in the correct height of the puncture point  $P_1$  in the tissue (Fig. 1). Thus if the mouth is not fully extended, the  $\alpha$  plane will guide the needle to a site which is too low in relation to the intended site,  $I_1$ . This would result in an ineffective block.

In a latero-medial direction on the  $\alpha$  plane the puncture point is within a 2.2-mm space<sup>1</sup> when the mouth is fully open, between the medial side of the deep tendon of the temporalis muscle (laterally) and the pterygo-mandibular raphe (medially).

Once the correct injection site is located, the remaining task for the clinician is to determine the angle of insertion of the needle. This is performed by referring to the angulation of the tragus to the side of the face.

The second reference plane, labeled beta ( $\beta$ ), is defined as the plane which contains the tragus (Fig. 3). It can be seen that  $\beta$  does not pass through the condyle. Consequently the needle does not lie in this plane but is found in a plane which is parallel to  $\beta$  and passes through the puncture and impact sites. This plane is labeled beta prime ( $\beta'$ ).



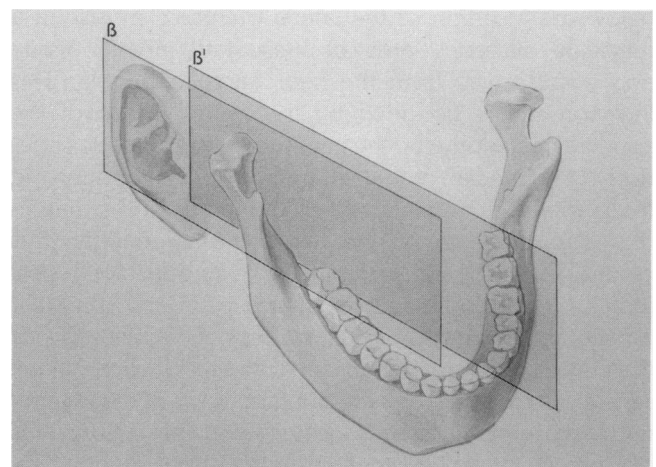
**Figure 2.** If the mouth is not fully opened the impact point  $I_1$  does not lie in the  $\alpha$  plane.

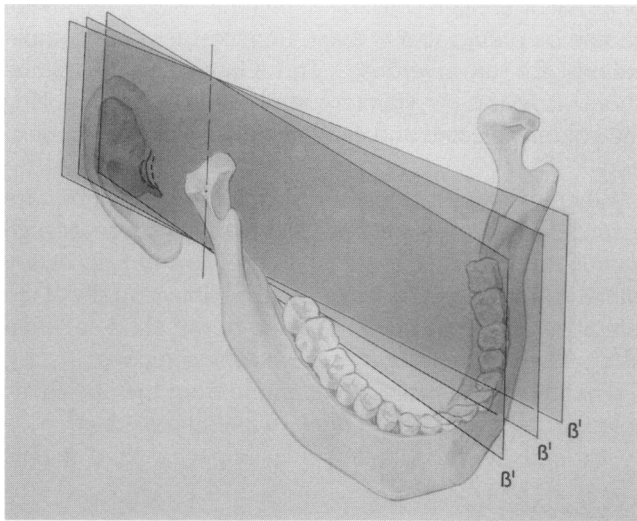
Figure 4 shows how the angular position of  $\beta'$  (and hence the needle) varies in relation to three possible different alignments of the tragus to the side of the face. Clearly, if the angle of insertion is misjudged, the impact site would be completely bypassed.

The basic aspects of the technique are summarized in Fig. 5 which shows the relationship between the  $\alpha$ ,  $\beta$ , and  $\beta'$  planes. The intersection of the  $\alpha$  and  $\beta'$  planes lies along the line  $LP_1I_1$  which is contained in the  $\alpha$  plane.

As can be seen, this line represents the true path of the

**Figure 3.** The  $\beta$  plane is defined to be the plane on the side of the face which contains the tragus. The plane  $\beta'$  is parallel to  $\beta$  and passes through the injection site. The needle is directed in the  $\beta'$  plane.





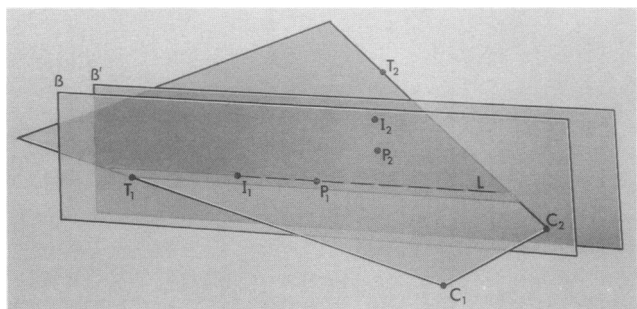
**Figure 4.** Because the angulation of the tragus to the side of the face is variable, the angle of orientation of  $\beta$  and  $\beta'$  must also be variable. This figure shows three different orientations of  $\beta'$  in response to three possible angles of orientation of the tragus to the side of the face.

needle. This diagram also shows the relationship between the landmarks  $C_1$ ,  $T_1$ , and  $I_1$ . As was stated earlier, the point  $I_1$  is not in line with  $C_1$  and  $T_1$  but is located further towards the center of the mouth.

## DISCUSSION

When the mouth is closed the condyle rests in the glenoid fossa and the ramus presents an oblique inclination superiorly. Opening the mouth as wide as possible is associated with a translation of the mandible, transforming the ramus into a more vertical position. The condyle

**Figure 5.** This figure shows the relationship between the  $\alpha$ ,  $\beta$ , and  $\beta'$  planes without reference to the mandible. The intersection between the  $\alpha$  (blue plane) and  $\beta'$  (green plane) planes lies in the line  $LP_1I_1$  which represents the path of the needle.



rests near the articular eminence, the anterior surface of the neck of the condyle presents a broader and vertical position to the  $\alpha$  and  $\beta$  planes, and the injection site is in the same frontal plane as foramen ovale.

Nonalignment of the needle pathway to the  $\alpha$  and  $\beta$  planes medially to the medial pole of the condylar neck will result in less than favorable results as well as involving the pterygoid plexus of veins and the sympathetic plexus of the internal carotid artery and its branch. The signs and symptoms of Horner's syndrome (i.e., constriction of the pupil, ptosis, enophthalmos) is distressing to the patient.

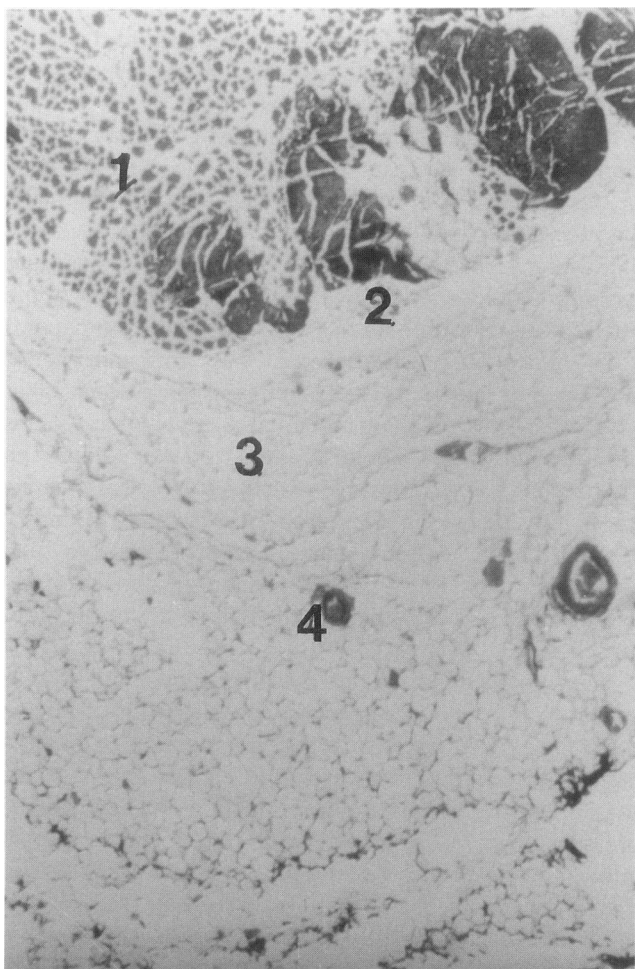
The placement of the needle away from the inferior alveolar and lingual nerves minimizes paresthesia. Likewise, the needle pathway in the lateral and higher regions of the space, when aligned correctly, avoids penetrating the medial pterygoid muscle which is mainly responsible for trismus. Trismus may also be due to rupture of vascular tissue releasing neurovascular substances such as serotonin, which are pain producing substances on the vascular bed, resulting in hypomobility of the masticatory muscles.

There is a significant relationship between the rate of injection and pressure rise when depositing the anesthetic solution, consequently affecting its retention within the region. It is claimed that depositing 2 ml of an anesthetic solution at the lingula in 18.3 sec increases hydrostatic pressure from 14.5 to 469 mm Hg.<sup>18</sup> Such a great imbalance between intra- and extravascular pressure and the resulting loss of the anesthetic through the pores of the capillary walls affects its concentration at the nerve membrane and may result in a partial or complete failure of the block.

The injection site at the lateral side of the anterior surface of the condyle is a relatively avascular zone of loose fatty areolar tissue (Fig. 6). This is in contrast to the highly vascular injection site at the lingula (Fig. 7). The provision of a greater tissue fluid component in this region enables the clinician to maximize the therapeutic and minimize the toxic effects of the anesthetic by reducing the rate of drug uptake through absorption when injecting 1 ml at the rate of no less than 30 sec.

Although no studies are available to indicate increased rise in pressure when injecting at the condyle, clinical observations of the comparative ease with the expulsion of the solution from the syringe in contrast to the resistance experienced in injecting at the lingula indicates that the pressure is significantly reduced.

Fasciae develop in planes where the connective tissue of the region is subject to regular tension. Tension is exerted either by direct action of the muscles or during movement of parts of the body, or mandible, which, of course, means indirect influence of muscle function. Fasciae finally develop under the influence of muscle



**Figure 6.** Photomicrograph 1 mm anterior to the condyle (coronal section,  $\times 30$ ).

1. Lateral pterygoid muscle
2. Tendon of the lateral pterygoid muscle
3. Loose areolar fatty tissue
4. Small blood vessels.

contraction where the covering connective tissue is expanded from within.<sup>19</sup>

Such condensations vary from individual to individual and if they are present may play the clinically important role of diverting infection towards different walls of the space in which it is contained. The same can be said of the diffusion of the anesthetic solution making its pathway difficult to predetermine.<sup>19</sup>

By depositing the anesthetic solution at the lingula it is likely to be influenced in its pathway and hence in its activity because of these fasciae condensations, whereas this does not occur at the lateral side of the anterior surface of the condyle.<sup>20</sup>

Local anesthetic drugs are central nervous system depressants and toxic complications are related to increased blood levels of the drug. It is important that the

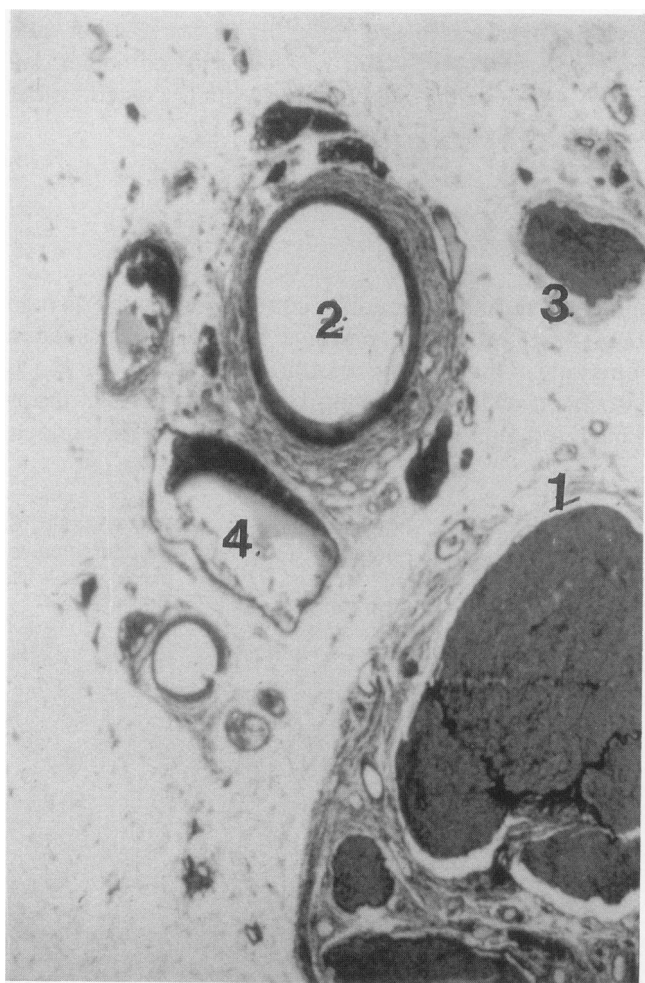
pharmacological results of a regional block technique should be predictable to avoid unnecessary toxic complications for an overdose. The Gow-Gates technique should minimize systemic complications by controlling the volume injected and eliminating supplementary injections.

Whereas vasoconstrictors such as epinephrine are essential in the conventional technique because of high vascularity in the area involved, they are not necessary with the Gow-Gates technique with an injection site at the lateral side of the anterior surface of the condyle when using 4% prilocaine or 3% carbocaine solutions.

The affect of deleting epinephrine from the anesthetic solution injected at the lingula was demonstrated by a split mouth study.<sup>8</sup> Bimandibular impacted third molars

**Figure 7.** Photomicrograph 1 mm above the lingula (horizontal section,  $\times 30$ ).

1. The inferior alveolar nerve
2. The inferior alveolar artery
3. The mylo-hyoid nerve
4. Veins.



**Table 2.** Aspiration Tests: Positive Aspirations Injecting at the Lingula

References	%	Cases
Harris <sup>22</sup>	3.6	3,085
Forrest <sup>23</sup>	4.2	577
Schiano, Strambi <sup>24</sup>	11.0	702
Bartlett <sup>25</sup>	11.7	702
Corkery, Barrett <sup>26</sup>	16.8	214
Adams, Mount <sup>27</sup>	18.0	94

were removed surgically; alternatively, the Gow-Gates and conventional techniques were employed using 3 ml of 4% prilocaine without vasoconstrictors. The Gow-Gates technique achieved 95% grade A anesthesia, whereas the conventional technique showed 65% grade A anesthesia.

Local toxicity may be due to traumatizing the nerve, muscular penetration, or by lacerating vascular tissue. It has been demonstrated that the injection at the lingula is associated with a higher incidence of hematoma formation than is generally realized, as observed by signs of ecchymosis in the pharyngeal region.<sup>21</sup> The advantages of the relatively avascular site at the condyle in contrast to that of the lingula is suggested by positive aspiration tests and their comparison in both injection sites (Table 2).<sup>22-27</sup>

The dispersion of an anesthetic solution through tissue is associated with a reduction in its concentration, and is related to the vascularity at the injection site. This is explained mathematically by Schilli,<sup>28</sup> who reported that 1 ml of a 2% solution yields a liquid sphere having a radius of 0.62 cm. When the drop spreads out and becomes diluted gradually in all directions, the solution 0.5 cm from the confines of the original drop is only 0.34% in strength. At a distance of 2 cm, solution must expand in volume over 76 cm<sup>3</sup>. The strength is then only 0.026%.

As the buccal nerve is approximately 23 mm from the injection site at the condyle, there is a significant reduction in the concentration of the anesthetic solution consequently affecting the block. The relationship of volume of the anesthetic solution injected and the effectiveness of blocking the buccal nerve was demonstrated: 100% anesthesia using 3 ml of 4% plain prilocaine,<sup>4</sup> 78%<sup>6</sup> and 62%<sup>8</sup> anesthesia using 1.8 ml of 2% lignocaine 1:100,000 epinephrine.

## MATHEMATICAL FORMULATION

The Gow-Gates technique has been examined purely mathematically. Such a treatment has been included to show (a) that the geometrical formulation of the tech-

nique is correct, (b) that the technique is accurate, predictable, and (c) to provide a mathematical interest to those wishing to peruse these ramifications. The details are found in the appendix.

This section is designed neither to confuse a very simple technique nor to create a mysterious aura of an overly scientific presentation.

This mathematical description of the Gow-Gates technique is made by representing the three reference planes  $\alpha$ ,  $\beta$ , and  $\beta'$  as well as the needle pathway by mathematical equations. In order to do this, a right-handed, ortho-normal coordinate system is defined.

Each of the oral landmarks can then be represented by a set of three numbers or coordinates, viz,  $x$ ,  $y$ ,  $z$ .

It is convenient to set up the coordinate system such that the  $x$  and  $y$  axes lie in the  $\alpha$  plane and the  $z$  axes perpendicular to it. This is shown in Fig. 8, which also shows all of the landmarks in a totally abstract fashion by representing them as points in space using coordinates. For example,

$$\begin{array}{ll} I_1(-x_3, 0, 0), & I_2(x_3, 0, 0), \\ C_1(-x_2, -y_2, 0), & C_2(x_2, -y_2, 0), \\ P_1(-x_1, -y_1, 0), & P_2(x_1, -y_1, 0), \\ T_1(-x_4, y_3, 0), & T_2(x_4, y_3, 0) \end{array}$$

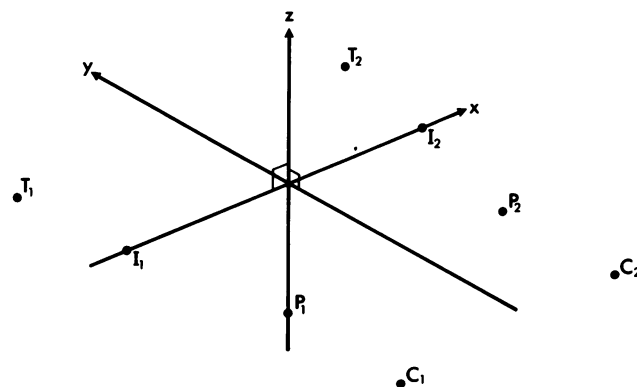
where  $x_1 < x_2 < x_3 < x_4$  and  $y_1 < y_3 < y_2$ .

A comparison with Fig. 1 shows the correlation between the "point" representation of each of the landmarks to their relationship with the rest of the mandible.

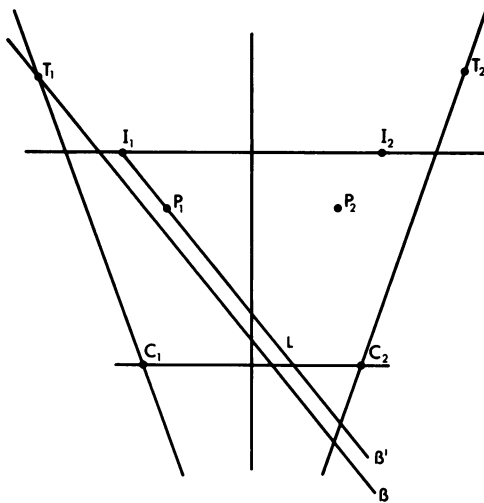
The mathematical representation of the  $\alpha$  plane is simply given by:

$$z = 0, x \in \mathbb{R}, y \in \mathbb{R}$$

**Figure 8.** Each point associated with the technique is represented in space by a unique coordinate. The coordinates are determined by scanning along the  $x$ ,  $y$ , and  $z$  axes. Note that all of these points lie in the  $x - y$  (or  $\alpha$ ) plane, i.e., the value of the  $z$  coordinated is zero.







**Figure 9.** A view of the various landmarks as if looking vertically onto the  $\alpha$  plane. The lines  $\beta$   $T_1$  and  $LP_1I_1$  represent the intersection between the  $\beta$  and  $\beta'$  planes, respectively, with the  $\alpha$  plane. The point  $I_1$  does not lie on the line  $C_1T_1$ .  $C_1$ ,  $C_2$ , corners of the mouth;  $I_1$ ,  $I_2$ , injection sites;  $P_1$ ,  $P_2$ , puncture points;  $T_1$ ,  $T_2$ , tragus points.

If  $R (-x_r, -y_r, z_r)$  is a point lying on  $\beta$  and OR the perpendicular distance from the origin, 0 to R, then the equation of the  $\beta$  is given by:

$$x_r x + y_r y - z_r z = -[x_r^2 + y_r^2 + z_r^2]$$

Since  $I_1$  lies in the  $\beta'$  plane, the equation for this  $\beta'$  plane is given by:

$$x_r x + y_r y - z_r z = -x_3 x_r$$

Since the path of the needle is contained in the  $\alpha$  (or  $x - y$ ) plane, all of the lines and points of interest lie in this plane. Thus the three-dimensional model can be reduced to that of two dimensions. Such a model is shown in Fig. 9 where  $T_1 T_2 C_1 C_2$  represents the  $\alpha$  plane, and  $L P_1 I_1$  is the actual needle pathway and also represents the intersection between the  $\alpha$  and  $\beta'$  planes. In this simplified model, the needle pathway can be represented by the equation of a straight line and is given by:

$$y = \frac{y_1 x}{x_1 - x_3} + \frac{y_1 x_3}{x_1 - x_3}$$

**Table 3.** Aspiration Tests: Positive Aspirations Injecting at the Condylar Neck

References	%	Cases
Gow-Gates	1.6	3,000
Panuska <sup>17</sup>	Nil	1,201
Malamed <sup>6</sup>	1.9	4,275

where

$$\theta = \tan^{-1} \left[ \frac{y_1}{x_1 - x_3} \right]$$

represents the angle between the tragal plane ( $\beta$  or  $\beta'$ ) and the x axis. The equations for the planes and the path of the needle for the left side of the mouth are identical in structure.

**CONCLUSION**

The Gow-Gates technique for mandibular anesthesia has been in use since 1947 and was first published in 1973. Comparative studies by a variety of authors have given credibility to the technique by showing that it is predictable, accurate, simple, and safe to use. The technique has a very high success rate, has minimal toxic effects, shows very low positive blood aspiration, and is used without vasoconstrictors.

Unlike the conventional inferior alveolar technique, and provided the mouth is fully opened, the Gow-Gates technique allows for the deposition of the anesthetic solution in the relatively avascular region at the neck of the condyle.

The needle pathway is substantiated by geometrical and mathematical analysis which removes any doubt as to the validity of the technique. The clinician is now provided with a different conception of mandibular block anesthesia.

**REFERENCES**

1. Murphy TR, Grundy EM. The inferior alveolar neurovascular bundle at the mandibular foramen. *Dent Pract* 1969;20:41-48.
2. Bremer G. Measurements of special significance in connection with anaesthesia of the inferior alveolar nerve. *Oral Surg Oral Med Oral Pathol* 1952;5:966-988.
3. Levy TP. An assessment of the Gow-Gates mandibular block for third molar surgery. *JADA* 1981;103:37-39.
4. Robertson WD. Clinical evaluation of mandibular conduction anaesthesia. *Gen Dent* 1979;27:49-51.
5. Carter RB, Keen EN. The intramandibular course of the inferior alveolar nerve. *J Anat* 1971;108:433-440.
6. Malamed SF. The Gow-Gates mandibular block, evaluation after 4,275 cases. *Oral Surg Oral Med Oral Pathol* 1981;51:463-467.
7. Yamada A, Jastak JT. Clinical evaluation of the Gow-Gates block in children. *Anesth Prog* 1981;28:106-109.
8. Sisk AL. Evaluation of the Gow-Gates mandibular block for oral surgery. *Anesth Prog* 1985;32:143-146.
9. Gow-Gates GAE, Watson JE. The Gow-Gates mandibular block; further understanding. *Anesth Prog* 1977;24:183-189.

10. Sicher H. Oral Surgery, 4th ed. St. Louis: C.V. Mosby, 1965:480-481.
11. Stone J. Trismus after injection of local anaesthetic. Oral Surg 1979;48:29-32.
12. Rood JR. The pressures created by inferior alveolar injections. Br Dent J 1978;144:280.
13. De Shazer DO, Coffey SL. Is the mandibular block obsolete? Chronicle 1981;44:90-91.
14. Gow-Gates GAE. Mandibular conduction anaesthesia; a new technique using extra oral landmarks. Oral Surg Oral Med Oral Pathol 1973;36:321-330.
15. Watson JE, Gow-Gates GAE. A clinical evaluation of the Gow-Gates mandibular block technique. NZ Dent J 1976;72:220-221.
16. De Jong RH. Physiology and Pharmacology of Local Anaesthesia, 2nd ed. Springfield, IL: Charles C. Thomas, 1974:96-97.
17. Panuska, H. The presidents corner. Anesth Prog 1979;26:3.
18. Rood JR. The pressures created by inferior alveolar injections. Br Dent J 1978;144:280.
19. Sicher H. Oral Anatomy, 4th ed. St. Louis: C.V. Mosby, 1965:476-483.
20. Galbreath JC, Eklund MK. Tracing the courses of the mandibular block injection. Oral Surg Oral Med Oral Pathol 1970;30:571-582.
21. Traeger K. Haematoma following inferior alveolar injection. A possible cause for anaesthesia failure. Anesth Prog 1979;26:122-123.
22. Harris SC. Aspiration before injection of dental local anesthetics. J Oral Surg 1957;15:229-303.
23. Forrest JO. Notes on aspiration before injection of local anaesthetics using dental cartridges. Br Dent J 1959;107:259-262.
24. Schiano AM, Strambi RC. Frequency of accidental intravascular injection of local anaesthetics in dental practice. Oral Surg 1964;17:178-184.
25. Bartlett SZ. Clinical observations on the effects of injections of local anaesthetic preceded by aspiration. Oral Surg 1972;33:520-526.
26. Corkery PF, Barrett BE. Aspiration using local anaesthetic cartridges with an elastic recoil diaphragm. J Dentistry 1973;2:72-74.
27. Adams AR, Mount GT. The effectiveness of a disposable aspirating syringe. Aust Dent J 1976;21:258-261.
28. Schilli W. Vasoconstrictors in local anaesthesia. Quintessence Int. (Dental Digest), 1977;8:15-18.