

THE THYROID "MICROSOMAL" ANTIBODY REVISITED
Its Paradoxical Binding In Vivo to the Apical Surface of the Follicular
Epithelium

BY E. L. KHOURY, G. F. BOTTAZZO* AND I. M. ROITT

From the Department of Immunology, The Middlesex Hospital Medical School, London

Several autoantibodies have been described in autoimmune thyroid diseases with specificities for antigens localized to the ("microsomal") acinar cell cytoplasm, colloid space (thyroglobulin, second colloid antigen), and surface membrane (TSH-receptor and other as yet unidentified moieties) (1).

If circulating antibodies play any direct role in the pathogenesis of human thyroid disease, for example by mediating cytolysis, or by blocking or stimulating function and growth (2), they must be able to interact in vivo with their specific antigens. This interaction will depend upon the accessibility of autoantigenic determinants on the cell surface, on basal membranes, and in the circulation, and the availability of adequate amounts of antibody in intravascular and interstitial fluids.

Immunohistological examination of the affected target tissue, by direct immunofluorescence (IFL)¹ with labeled anti-immunoglobulin (Ig) or anti-complement sera, is an accepted way of looking for evidence of in vivo autoreactivity. Glands from patients with autoimmune thyroid disease have been repeatedly screened by this procedure and granular deposits of Ig often associated with complement, were described in the colloid, in the connective-tissue stroma and along the follicular basement membrane (FBM; references 3-6). Thyroglobulin is the most likely target for colloid-bound Ig and is also believed to be involved in some instances in immune complexes deposited around the FBM (7). On the other hand, no direct evidence was found under these conditions concerning binding in vivo of autoreactive Ig on the follicular epithelium, though the presence of Ig deposits on isolated cells from thyrotoxic glands has been mentioned (8).

Recently, it has been established that the cytoplasmic microsomal autoantigen is also present on the cell surface of human thyroid cells maintained in monolayer cultures (9). The same cell surface autoantigen is involved in the complement-

Supported by funds from the British Medical Research Council. E. L. K. was a Wellcome Trust Research Fellow.

* Correspondence should be addressed to Dr. G. F. bottazzo at the Dept. of Immunology, The Middlesex Hospital Medical School, Arthur Stanley House, 40-50 Tottenham Street, London W1P 9PG. E. L. Khoury's present address is: Div. of Oral Biology, HSW-604, University of California at San Francisco, San Francisco, CA 94143.

¹ Abbreviations used in this paper: C3, third component of complement; CM, culture medium; FBM, follicular basement membrane, FCS, fetal calf serum; IFL, immunofluorescence; PBS, phosphate-buffered saline; TMAb, thyroid microsomal antibodies.

mediated antibody-dependent cytotoxic effect exerted *in vitro* by sera from autoimmune thyroid disease patients, positive for thyroid microsomal antibodies (TMAb). On the other hand, no direct evidence has been found concerning *in vivo* autoreactivity of TMAb, even though their presence in the circulation is almost invariably associated with autoimmune thyroid disease.

In the course of IFL studies on the cell-surface reactivity of TMAb on human thyroid cultures (9) it became apparent that, while follicular cells from normal glands were always negative when tested by direct IFL with anti-Ig conjugates, those obtained from the thyroids of patients with circulating TMAb frequently displayed spontaneous surface-bound Ig. These observations prompted us to look systematically for the binding *in vivo* of these antibodies to thyroid cells. Evidence is also presented which indicates that the surface expression of the microsomal autoantigens on the thyroid cell epithelium is restricted *in vivo* to the apical border of the follicular cells and therefore may not be readily accessible to circulating antibodies.

Materials and Methods

Direct Immunofluorescent Staining on Frozen Thyroid Sections

17 glands were used for these experiments. Operative specimens were obtained from 13 patients with thyrotoxicosis, 3 with diffuse or nodular nontoxic goiter, and 1 with dyshormonogenetic goiter. In each case and in all subsequent experiments, the diagnosis was confirmed on clinical, laboratory, and histological grounds. Staining for *in vivo* immunoglobulin deposits was carried out according to established techniques (3, 5, 7). In brief, 4- μ m freshly cut cryostat thyroid sections were washed in phosphate-buffered saline (PBS) for 15 min and subsequently incubated with fluorescein-conjugated anti-human Fab, IgG, IgM, and third component of complement (C3) for 30 min at room temperature. All antisera were diluted 1:20 before use. Sections were washed again in PBS for 15 min and mounted. These and all subsequent preparations described in this paper were examined under a Zeiss fluorescence microscope equipped with epiillumination and phase contrast.

Immunofluorescent Staining of Thyroid Monolayers

Substrates. 41 human thyroids were used. Tissues were obtained from the following patients: 10 with Graves' thyrotoxicosis, 2 with Hashimoto's thyroiditis, 6 with diffuse or nodular nontoxic goiter, 1 with dyshormonogenetic goiter, and 8 with adenomatous, carcinomatous, or cystic lesions where normal peri-lesional tissue was used. 12 normal adult thyroids, obtained from patients undergoing radical neck surgery for cancer of the larynx, and 2 from 14- and 17-wk-old fetuses were used as controls. Serum samples from 1 patient with thyrotoxicosis, 2 with thyroid cysts, and 1 with adenoma, and from the 12 donors of normal thyroid tissue were not available for the conventional hemagglutination tests for thyroglobulin and thyroid microsomal autoantibodies (Wellcome Reagents).

Preparation of Thyroid Monolayer Cultures. The procedure followed for obtaining viable cells and establishing the cultures was recently described (9). In brief, the glands were obtained immediately after removal and processed under sterile conditions. The thyroid tissue was chopped into small pieces, washed several times in culture medium (CM) (Flow 199 plus NaHCO 0.35 mg/ml, penicillin 300 U/ml, and streptomycin 300 μ g/ml) and incubated for 60 to 90 min at 37°C with either collagenase (Worthington type IV, 2 mg/ml), trypsin, (Difco, 2.5 mg/ml) or collagenase followed by trypsin (60 min each). After discarding undigested tissue fragments and lysing erythrocytes in 0.83% ammonium chloride buffer, the thyroid cells were washed and resuspended in CM supplemented with 15% heat-inactivated fetal calf serum (FCS). Cell viability after dispersion was assessed by differential staining with an acridine orange/ethidium bromide mixture under fluores-

cence microscopy (10) and was >90% in all preparations. An accurate cell count at this stage was not feasible, as most thyroid cells were in clusters (11). 100 μ l of the cell suspension were plated on to round coverslips, 13 mm in diameter, placed in multiwell (Linbro) plates and 400 μ l of 15% FCS in CM added to each well. The cultures were kept at 37°C in a 5% CO₂ humidified cell incubator until tested by IFL.

Staining Procedure. 18–36-h-old viable monolayers were employed in these experiments. For the direct method the monolayers were washed in CM and then incubated for 30 min at room temperature with a fluorescein-conjugated sheep anti-human Fab serum diluted 1:20 in CM. In addition, monolayers from 12 of the abnormal glands were also stained with monospecific fluorescein-conjugated sheep antisera against human IgG, IgM, IgA, and C3 (Wellcome Reagents), diluted 1:20 under the same conditions. In some of the cases in which negative IFL was obtained, staining was repeated with lower dilutions of these conjugates. In 9 cases, both monolayer cultures and frozen sections from the same gland were stained.

For the indirect method, the viable cell-monolayers were first incubated with known TMAb-positive sera giving organ-specific thyroid cell-surface IFL staining (9) and the reaction subsequently revealed with the anti-Fab conjugate. Cultures from 20 of the abnormal glands were additionally tested with the autologous serum. Control sera were from healthy laboratory staff, negative for thyroid or other autoantibodies and with no family history of organ-specific autoimmune disease.

Complement Fixation and Cytotoxicity In Vitro

To detect complement fixation in vitro, the monolayers were incubated with blood group AB (12), fresh normal human serum (FNHS) diluted 1:5 in CM as a source of complement, and counterstained with anti-C3 conjugate. In addition, cell suspensions from all 41 thyroid glands were incubated with 20% blood group AB, FNHS in CM for 48 h at 37°C in the cell incubator, in order to detect any direct cytotoxic effect of the added complement by screening the preparations under phase contrast in an inverted microscope (9).

Immunofluorescent Staining of Partially Disrupted Thyroid Follicles in Suspension

Substrates. Six human thyroids were used for this study. Three were thyrotoxic glands, two were nontoxic goiters and one was a normal thyroid. To obtain partially digested follicles, the thyroid tissue was chopped into small pieces, washed in the same culture medium, and incubated at 37°C with collagenase (2 mg/ml) for 20–30 min, with gentle shaking. After discarding large undigested fragments and lysing the erythrocytes, broken follicles, smaller fragments of epithelium, and dispersed thyroid cells were resuspended in CM. Cell viability was always >90%.

Sera. Several sera positive for TMAb and thyroid cell-surface IFL staining on cultured monolayers were used. In addition, the autologous serum was tested on all but the normal thyroid.

Staining Procedure. Immediately after the enzymatic digestion 180 μ l aliquots of the cell suspension and 20 μ l of undiluted test serum were placed in 4-ml centrifuge tubes, making a final serum dilution of 1:10. The mixture was incubated in an ice bath for 30 min with frequent gentle shaking. The tubes were then filled with culture medium and centrifuged at 150 g for 5 min. The cell pellet was resuspended in 100 μ l of a fluorescein sheep anti-human Fab conjugate diluted 1:50, and incubated for a further 30 min. After a second wash and centrifugation, the cell pellet was resuspended in 50 μ l of culture medium and a drop of the suspension placed on a microscope slide, mounted, and examined under fluorescence microscopy. In the direct IFL staining the test serum was omitted and the same anti-human Fab conjugate was used to reveal spontaneous binding of Ig in vivo. An anti-C3 conjugate was also used.

Results

Immunoglobulin Deposition on Frozen Thyroid Sections. When unfixed cryostat sections of randomly selected tissue blocks from 13 thyrotoxic glands were

stained by direct IFL, clea? cut linear deposits of IgG delineating the apical border of the follicular epithelium were seen in 6 cases (Fig. 1; Table I). This pattern, though essentially focal and restricted to some follicles on each section, was quite uniform at the inner edge of a given follicle. Even when in some cases there were strong deposits on the apical surface, intracytoplasmic staining was seen in some thyroid cells in only one of the glands examined. Neither IgM nor C3 could be found in these deposits. Likewise, no complement-fixation in vitro could be detected in these glands when sections positive for bound IgG were

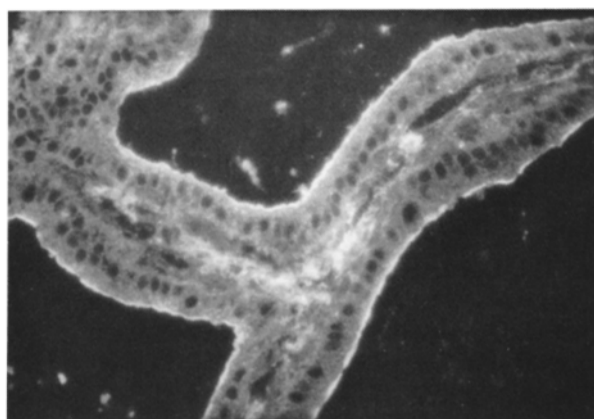

FIGURE 1. Frozen tissue section from a thyrotoxic gland stained by direct immunofluorescence with conjugated anti-human IgG showing a continuous linear staining on the apical border of acinar cells. $\times 250$.

TABLE I
In Vivo Deposition of Immunoglobulins and Complement in Operative Specimens of Thyroid Glands

Thyroid donors	Thyroid preparations	Direct immunofluorescence		
		Anti-IgG	Anti-IgM	Anti-C3
		<i>no. positive/no. tested</i>		
Graves' thyrotoxicosis	Unfixed cryostat sections:			
	Apical border	*6/13	0/10	0/10
	Follicular basement membrane	*5/13	4/10	5/10
	Monolayer cultures	‡8/10	0/6	/6
Hashimoto's goiter	Monolayer cultures	2/2	0/2	0/2
Other thyroid lesions	Unfixed cryostat sections:			
	Apical border	§1/4	0/4	0/4
	Follicular basement membrane	0/4	0/4	0/4
	Monolayer cultures	§2/15	0/4	0/4
Normals	Monolayer cultures	0/14	NT	NT

NT, not tested.

* Only one gland showed simultaneous apical border and basement membrane staining. Altogether 10/13 thyrotoxic glands showed some in vivo fixation of antibodies on sections.

‡ 5/8 positive monolayers were derived from glands showing deposits of microvillar antibodies on sections.

§ The three glands showing microvillar deposits on sections or monolayer culture were from patients with nontoxic diffuse or nodular goiters and circulating thyroid microsomal antibodies.

incubated with FNHS and counterstained with fluoresceinated anti-C3. IgA deposition was not looked for.

The staining on the apical border was always correlated with positive thyroid microsomal antibodies in the patient's serum, but glands from three thyrotoxic TMAb-positive patients did not show this *in vivo* Ig deposition. Thyroid sections of three TMAb-negative thyrotoxicosis cases were negative for Ig deposits on the apical border and only one of the nontoxic goiters was weakly positive although in this case the serum had low titer TMAb. The dyshormonogenetic goiter was negative.

In addition, five of the thyrotoxic glands displayed granular deposits of Ig and C3 along the follicular basement membrane (Fig. 2). These deposits varied in intensity on different areas, though their presence could always be confirmed on sections from several blocks of the same gland. IgG and to a lesser extent IgM were found around the FBM. Complement was invariably attached *in vivo*. No correlation or topographical association was found between apical and basal immune deposits. Moreover, sections with the strongest deposits along the FBM were devoid of staining on the apical pole, and vice versa (Table I). Ig along the FBM was not found in the three nontoxic or the dyshormonogenetic goiters.

Immunoglobulin Deposition on Thyroid Cell Monolayers. In no instance was cell-surface IFL present on cultured thyroid follicular cells from 12 normal adult and 2 fetal glands, when directly stained with fluorescein-conjugated anti-human Ig (Table I). Negative results were also obtained on monolayers derived from peri-adenomatous or peri-cystic tissue of eight patients, four nontoxic goiters, one dyshormonogenetic goiter, and two thyrotoxic glands, even though some of the patients' sera were positive for microsomal antibodies. In 12 other cases (8 with thyrotoxicosis, 2 with Hashimoto's thyroiditis, and 2 with nontoxic goiter), spontaneous cell-surface-bound Ig was detected by direct IFL staining on monolayers (Fig. 3*a*). The IFL pattern consisted of coarse and sparse granular staining covering the whole surface of the cell (Fig. 3*b*), similar to that obtained by indirect IFL with TMAb-positive sera on blood group O normal thyroid

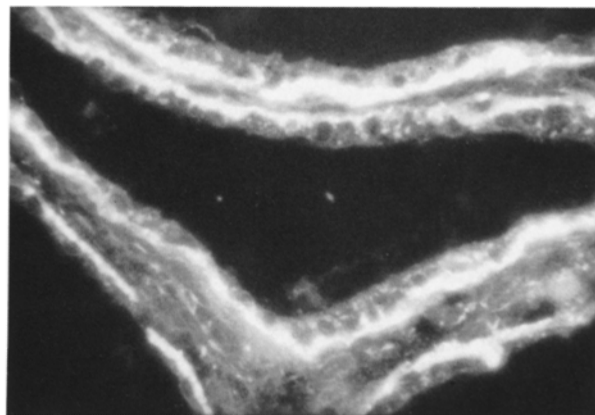


FIGURE 2. Direct immunofluorescence staining of frozen tissue section from a thyrotoxic gland (different from that in Fig. 1) by anti-IgG conjugate, showing discrete deposits along the follicular basement membrane. $\times 250$.

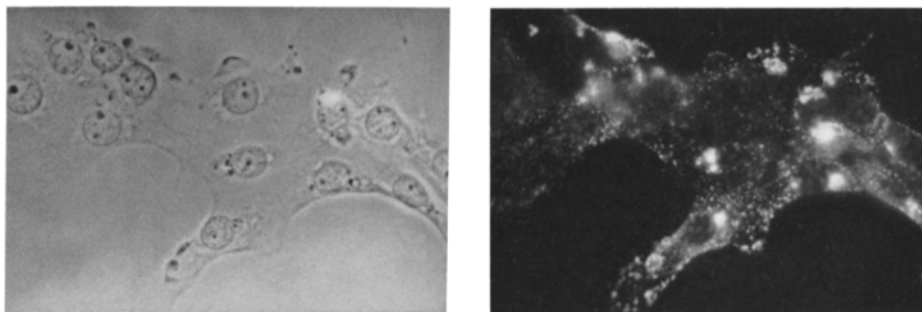


FIGURE 3. Demonstration of *in vivo* binding of Igs on thyroid follicular cells. After 24 h in culture, cells are spread on the coverslip as seen by phase-contrast microscopy (*left*); and when stained with anti-Fab conjugate, a significant proportion (all in this particular field) showed granular surface immunofluorescence (*right*). The large bright areas represent autofluorescent intracytoplasmic vacuoles (orange in the original). $\times 650$.

monolayers (9). However, positive reactions for spontaneously bound Ig were usually focal, involving fairly numerous groups of follicular cells, except in the cultures prepared from the Hashimoto glands, where nearly all cells displayed significant staining. This focal distribution allowed most cultures with spontaneous deposits to be tested also by indirect IFL with TMAb-positive sera, including the patient's own, which produced a uniformly distributed granular staining on all cells. Spontaneous membrane-bound Ig was usually no longer detected after 2 d in culture, although cells were still able to react with TMAb-positive sera.

In an attempt to rule out the possibility that this spontaneous staining reaction might be an artifact caused by the binding of intravascular or locally produced Ig to cell-surface autoantigens while the cells were processed with proteolytic enzymes, two tissue samples from the same portion of a gland were obtained and finely minced. One of the samples was extensively washed (four to six times) in CM before enzymatic treatment, while the other was subjected to digestion without previous washing. No qualitative or quantitative differences in the direct staining with fluorescein-labeled anti-Fab were recorded on cultures derived from the samples processed in these two ways. This experiment was repeated with several glands.

The correlation between circulating TMAb and the presence of spontaneously cell-surface-bound Igs on cultured monolayers is shown in Fig. 4. Positive IFL on viable cultures was never observed when cells came from a TMAb-negative donor. However, not all TMAb-positive cases showed spontaneous Ig deposits on the surface of the monolayers, even though their sera invariably reacted well with autologous cultures in the indirect IFL test. Cells dispersed from the perilesional tissue of a follicular adenoma with focal thyroiditis were negative for direct IFL, even though the TMAb in the patient serum produced strong cell surface staining on autologous 24-h old monolayers.

Fibroblastoid cells present in the cultures, specially those of thyrotoxic and Hashimoto glands, were invariably negative for direct IFL staining. Occasional spread macrophages were nonspecifically stained by labeled antisera due to their cell surface Fc receptors.

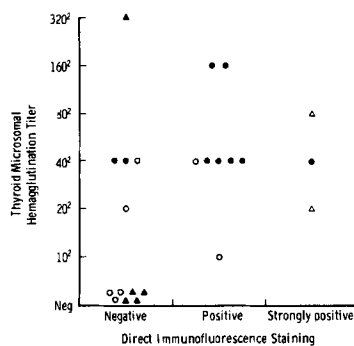


FIGURE 4. Microvillous Ig deposits on thyroid cells in vivo, demonstrated by direct anti-Fab staining of viable monolayer cultures, and their correlation with circulating thyroid "microsomal" antibodies. ●, Thyrotoxicosis. Δ, Hashimoto's thyroiditis. ○, Diffuse or nodular non-toxic goiter. ▲, Single nodule, follicular adenoma, cyst, carcinoma, and one dyshormonogenetic goiter (normal peri-lesional tissue was used in all cases).

Spontaneous membrane-bound Igs stained for IgG in all cases, but only trace amounts of IgA were detected and then in just a small proportion of the cultures. IgM and C3 were never found by direct IFL, even when monospecific antisera were used at higher concentration. Furthermore, none of the cultures displaying cell-surface-bound IgG in vivo fixed complement spontaneously in vitro, as assessed by complement-fixing IFL with FNHS and anti-C3 conjugate on 24-h old monolayers or by phase contrast monitoring of cytotoxicity by FNHS alone on freshly dispersed cell suspensions. On the other hand, these cultures did show significant complement fixation and cytotoxic changes in vitro when incubated with autologous serum before the addition of FNHS.

There was a noticeable difference in the staining intensity between anti-Fab and monospecific anti-IgG labeled antisera, the latter being weaker on cultured cells obtained by trypsin digestion. That this was due to an effect of the trypsin on the Fc portion of cell-surface-bound IgG during enzymatic treatment was shown by the following experiments. 24-h old monolayers from a normal gland were incubated with a TMAb-positive serum as for indirect IFL. The monolayers were then detached with 0.25% trypsin solution for 10 min at 37°C, and the cell suspension replated on new coverslips after trypsin inactivation with FCS. 24 h later the follicular cells had again spread and were directly stained with anti-Fab and -IgG conjugates. There was a significantly brighter staining with anti-Fab serum (++) vs. weak + with anti-IgG). Furthermore, these pretreated cultures failed to display any complement fixation when incubated successively with FNHS and fluorescent anti-C3 conjugate. Nontrypsinized control monolayers showed similar staining with anti-Fab and -IgG sera and were positive for complement-fixing IFL, when incubated with the same TMAb-positive serum.

Immunoglobulin Deposition and Localization on Partially Disrupted Follicles. Under phase contrast microscopy, partially broken thyroid follicles from the six glands used in these experiments often appeared as three-dimensional structures resembling "half-melons" in which a central concavity—the empty colloid space—and a normally polarized row of follicular cells at the rupture surface, were recognized on focusing (Figs. 5a, and 6,a and c). There were also compact

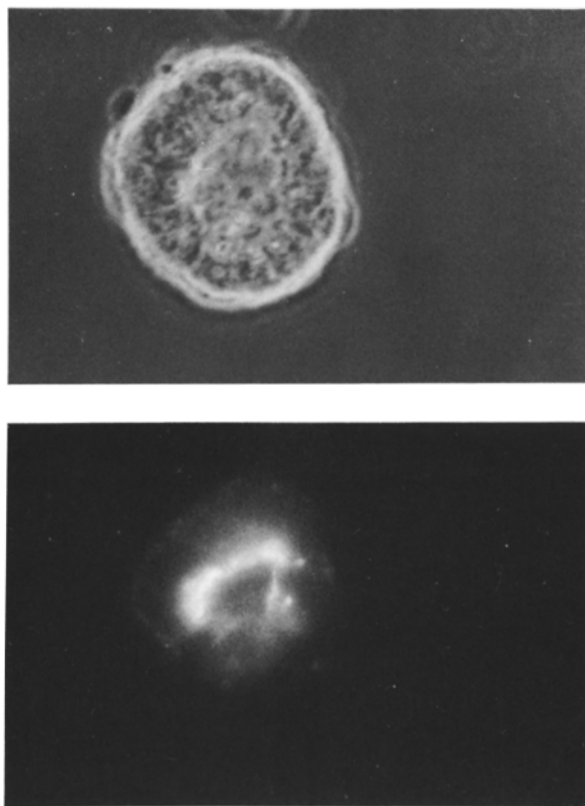


FIGURE 5. Partially disrupted follicle from a thyrotoxic gland. (*Top*) Phase-contrast showing the three-dimensional structure ("half-melon"); focus is on the row of follicular cells in the plane of rupture. (*Bottom*) Direct immunofluorescence staining with anti-Fab reveals Ig deposits restricted to the inner apical surface. $\times 650$.

structures without these features, presumably unbroken follicles or perhaps fragments lying on the split surface and displaying the basal surface of the epithelium. The preparations contained the whole spectrum of fragmented epithelium, and occasional single follicular cells in which the polarity of the microvilli on the apical pole was still noticeable (Fig. 7*a*).

When the direct IFL test with anti-Fab was applied, only the three thyrotoxic glands showed spontaneously bound Ig, the patients all having significant titers of circulating TMAb. This Ig deposition on partially disrupted follicles was restricted to the apical border of the epithelium, appearing as a continuous linear staining on the inner edge of the row of cells at the ruptured level (Fig. 5*b*). At the magnification used ($\times 650$) the fluorescence was apparently localized at the level of cellular microvilli. Complement was not trapped in the Ig deposits. When the same follicular preparations were first incubated with autologous or homologous sera containing TMAb before staining with anti-Fab, a similar though brighter IFL pattern was seen at the apical border (Fig. 6*b*). By focusing through the three-dimensional structure of the follicles, a reticulated and dotted pattern could be observed on the entire concave surface lining the empty colloid space

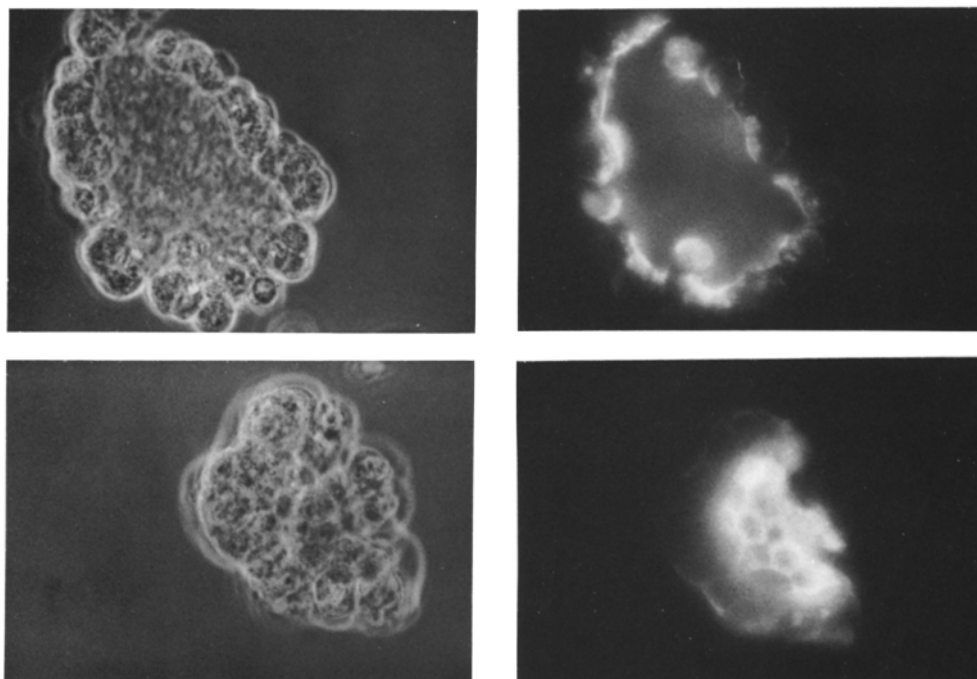


FIGURE 6. Partially disrupted follicle from a normal thyroid stained by indirect immunofluorescence with serum containing thyroid "microsomal" antibodies. At the level of the rupture plane photographed under phase-contrast in (a), the surface antigen is seen to be localized to the apical pole of the acinar cells (b). This is confirmed by focusing the microscope on the cells at the base of the follicular cavity (c), where confluent fluorescence is clearly apparent (d). $\times 650$.

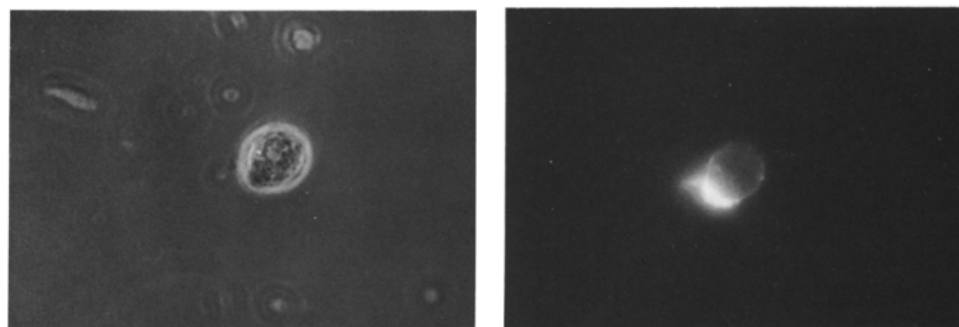


FIGURE 7. Isolated follicular cell in suspension immediately after collagenase digestion, seen under phase-contrast (a). Stained by indirect immunofluorescence with a TMAb positive serum, shows surface fluorescence localized on the apical pole (b). $\times 650$.

(Fig. 6 d). Single follicular cells present in the preparations also displayed positive cell-surface IFL restricted to the apical pole, simulating a "capping" phenomenon (Fig. 7 b). Partially disrupted follicles from all six glands studied by this procedure showed the same pattern of reactivity with TMAb positive sera. Fluorescence was never seen on the basal wall of the follicular cells corresponding to the vascular pole.

There was no correlation between binding *in vivo* of Ig on the surface of follicular cells, either in frozen tissue sections, monolayer cultures or partially disrupted follicles, and the presence of thyroglobulin antibodies in the patient's serum.

Discussion

Although circulating antibodies were demonstrated in autoimmune thyroid disease many years ago (13), the exact immunopathologic mechanisms responsible for attack on the corresponding target cells *in vivo* remain unknown. Thyroid microsomal and thyroglobulin antibodies are considered useful and convenient serum "markers" for the diagnosis and monitoring of thyroid autoimmune patients. However, we may legitimately ask whether these antibodies represent primary or secondary phenomena in the complex events leading to thyroid cell damage. The finding that surface-reacting immunoglobulins were present in the sera of autoimmune thyroid patients (14) and that they were cytotoxic for dispersed thyroid cells in the presence of complement (9, 15) was undoubtedly an important step towards identifying immune phenomena more conspicuously related to the initiation of cell injury. Recently, proof was obtained that thyroid "microsomal" autoantigens not only have a cytoplasmic localization within the follicular cells, but these molecules are also fully expressed on the cell surface (9, 16). A similar phenomenon has been observed in other organ-specific systems (17-19).

Although it is generally accepted that circulating TMAB tend to be associated with clinically overt autoimmune thyroid diseases, their presence in the serum does not necessarily imply an active disease and in some cases correlates with a silent autoaggressive damaging process that can only be proved on histological (20) or biochemical (21) grounds, when deliberately searched for. What is still difficult to explain is the paradox that 20% of "healthy" middle-aged women possess TMAB yet only a small proportion of them show thyroid abnormalities after many years of follow-up (22, 23). Furthermore, transplacental passage of high titer TMAB from mothers with Hashimoto's thyroiditis or primary myxoedema does not generally cause neonatal hypothyroidism, unless the rare adenyl cyclase-blocking antibody is concurrently transferred to the baby (24). The present demonstration that the autoreactive antigens are exclusively localized on the apical microvillous border of thyroid follicular cells facing the colloid space, where they would be relatively inaccessible to circulating antibody, may now explain some of these apparent clinical discrepancies. This topographical restriction of the target antigen is not altogether unexpected, since the "microsomal" antigen in the cytoplasm is believed to be a protein component of the membrane of exocytotic vesicles carrying newly synthesized thyroglobulin to be stored in the colloid (25, 26). Fusion of these vesicles with the apical plasma membrane, which is known to occur (27, 28), will lead to a consequent expression of the antigen on the cell surface at this site. The evenly distributed IFL staining of the cell surface "microsomal" antigen on human thyroid monolayers may be a consequence of the preservation of cell polarity on spread-out cultured cells with microvilli in contact with the culture medium (29). It is worth noting, that a preferential concentration of the cytoplasmic "microsomal" antigens at the apical

border of follicular cells was a common observation on thyroid sections during routine determination of thyroid antibodies (Fig. 8) before the introduction of the more sensitive hemagglutination test. This sequestration of antigen on the apical cell surface in intact follicles might be the reason for the lack of binding of human TMAb to monkey glands in passive transfer experiments, even though the monkey thyroid microsomal antigen was fully cross-reactive with human TMAb in the indirect IFL test (13). Likewise, this may also explain why thyroiditis sera, cytotoxic to follicular cells dispersed in trypsin and to a lesser extent collagenase (9, 25), failed to affect the outgrowth of undigested fragments presumably because they still maintained their follicular structure in the *in vitro* system (15, 30, 31).

In the light of these considerations, structural changes of the follicular basement membrane reported in autoimmune thyroid diseases (32, 33), and related to deposition of immune complexes (7), may certainly be of pathogenetic significance. While FBM fragmentation seen in thyrotoxic glands is focal and somehow restricted to those patients with high thyroid antibody titers, the changes in Hashimoto's thyroiditis—though qualitatively similar—are diffuse, more severe, and always present (32). It is therefore conceivable that tissue damage mediated by the *in vivo* reaction of cytotoxic "microsomal" antibodies with cell surface determinants on the microvilli might only occur in association with breaks in the continuity of the FBM (and perhaps loosening of the tight intercellular junctions), with the subsequent leakage of Ig, complement components and/or killer lymphoid cells into the acinar space. Alternative mechanisms of exposing the relevant apical autoantigens to the lymphoid system have recently emerged. Reconstituted thyroid follicles reverse their polarity in the presence of high concentrations of fetal calf serum (34), so allowing the microvillous portion of the cell to be externalized (35). HLA-DR antigens are not usually expressed on resting thyroid culture cells, but incubation of the same preparations with mitogens stimulates these cells to synthesize DR molecules (36). Interestingly, the same phenomenon has been observed spontaneously *in vivo* in autoimmune thyroid glands (37) and

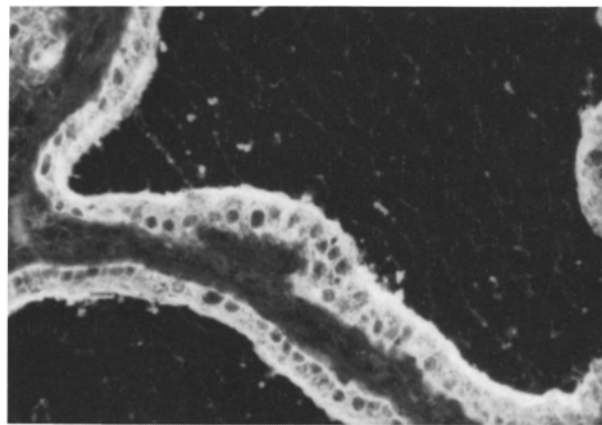


FIGURE 8. Indirect immunofluorescence on thyroid frozen section with TMAb-positive serum giving cytoplasmic staining concentrated towards the apical microvillous pole of the follicular cells. $\times 250$.

these preliminary results clearly indicate that thyroid epithelial cells have the full potential for recognition by autoreactive T cells, known to have receptors for DR antigens (38).

Our finding of spontaneously bound Ig on the cell-surface of monolayer cultures and partially broken follicles derived from the glands of patients with autoimmune thyroid disease suggests that reaction of TMAb with the apical surface antigen can indeed occur in vivo. Two facts would indicate that these Ig deposits contain TMAb. First, surface-reactive Ig was found only in glands from patients with circulating TMAb, irrespective of their clinical diagnosis or functional status. Secondly, in all the preparations examined, whether monolayers or partially broken follicles, the cells invariably displayed an IFL pattern similar to that observed when normal viable thyroid cells are stained with TMAb-positive sera by the indirect IFL technique. That this autoreactivity is a true in vivo phenomenon and not an artifact due to processing in vitro, is suggested by the fact that cells cultured from either unwashed or extensively washed neighboring portions of the same gland did not differ in their expression of spontaneously bound surface Ig and that spontaneous binding did not necessarily parallel the presence of TMAb in the circulation, even when present at high titers. Particularly convincing evidence for the binding of antibody to the apical cell surface in vivo is the demonstration of Ig deposition on frozen tissue sections of the glands with the same topographical distribution as that found after staining partially broken follicles in suspension.

The Ig deposits in vivo were almost exclusively IgG (deposition of IgD and IgE was not specifically looked for). Failure of the bound IgG to fix complement might be a consequence of low Ig binding density, since we know from the brighter IFL staining obtained on subsequent reaction with autologous serum that not all antigenic sites were saturated in vivo; other factors could be Ig subclass restriction (39) or enzymatic damage to the Fc region along the lines discussed above. In any case, one would expect selective loss of cells on which the bound Ig had activated the complement cascade. In contrast, the Ig deposits on the follicular basal membrane displayed wider immunological features, including complement fixation.

In conclusion, several characteristics of the TMAb system would be consistent with a pathogenetic role in thyroid autoimmune diseases: the specific autoantigen is expressed on the thyroid cell surface; TMAb are almost always present, often in high titers, and there is local synthesis by infiltrating lymphoid cells (40); the antibodies bind in vivo to the apical surface of follicular cells; and they produce—at least in vitro—an impressive complement-mediated cytotoxic effect on these cells. Nevertheless, the presence of TMAb in the circulation and local interstitial fluids would be a necessary but not sufficient condition for their reactivity in vivo, since access to the corresponding cell surface autoantigen may require additional factors due to its relatively secluded location on the apical pole.

Summary

We have shown that thyroid monolayers derived from the glands of patients with autoimmune thyroid disease have immunoglobulin (Ig) bound to their surface. This appears to have been deposited in vivo rather than during prepa-

ration of the monolayers, a view supported by our finding of such deposits on the apical margin of follicular cells in sections cut from these glands and stained with conjugated anti-immunoglobulin. It is likely that these deposits represent specific binding of so-called "microsomal" autoantibodies to the surface of the thyroid cells in vivo since staining of partially disrupted follicles ("half-melons") with Hashimoto serum containing microsomal autoantibodies in the indirect immunofluorescence (IFL) test, localized the antigen on the apical surface of the cells lining the follicular cavity. Thus, paradoxically, although the antigen is relatively inaccessible, autoantibodies do reach and combine with the thyroid surface in vivo and may therefore play a role in pathogenesis.

We are grateful to the surgeons of the Middlesex Hospital, in particular Mr. C. Russell, and those of Grays Inn National ENT Hospital for providing the human tissues, and to the many physicians who allowed us to test the serum of their patients. We thank Mrs. Linda Hammond for skilled technical assistance and Prof. Deborah Doniach for valuable discussion.

Received for publication 1 September 1983.

References

1. Doniach, D., G. F. Bottazzo, and H. A. Drexhage. 1982. The autoimmune endocrinopathies. *In Clinical Aspects of Immunology*. Vol. 2. P. J. Lachmann and K. Peters, editors. Oxford. 903-37.
2. Bottazzo, G. F., H. A. Drexhage, and E. L. Khoury. 1982. Thyroid antibodies in thyroid diseases. *In Receptors, Antibodies and Disease*. London, Pitman (Ciba Foundation Symposium). 153-67.
3. Koffler, D., and A. H. Friedman. 1964. Localization of immunoglobulins in chronic thyroiditis. *Lab Invest*. 13:239.
4. Doniach, D. 1967. Thyroid autoimmune disease. *J. Clin. Pathol.* 20:385.
5. Werner, S. C., O. Wegelius, J. A. Fierer, and K. C. Hsu. 1972. Immunoglobulins (E,M,G) and complement in the connective tissues of the thyroid in Graves' disease. *N. Engl. J. Med.* 287:421.
6. Kalderon, A. E., H. A. Bogaars, and I. Diamon. 1973. Ultrastructural alterations of the follicular basement membrane in Hashimoto's thyroiditis. Report of eight cases with basement membrane deposits. *Am. J. Med.* 55:485.
7. Kalderon, A. E., and H. A. Bogaars. 1977. Immune complex deposits in Graves' disease and Hashimoto's thyroiditis. *Am. J. Med.* 63:729.
8. Indiveri, F., E. Rolandi, A. Barabino, G. Di Benedetto, and A. Polleri. 1973. Thyroid cells in Graves' disease. *Lancet*. ii:743.
9. Khoury, E. L., L. Hammond, G. F. Bottazzo, and D. Doniach. 1981. Presence of the organ-specific 'microsomal' autoantigen on the surface of human thyroid cells in culture: its involvement in complement-mediated cytotoxicity. *Clin. Exp. Immunol.* 45:316.
10. Lee, S. K., J. Singh, and R. B. Taylor. 1975. Subclasses of T cells with different sensitivities to cytotoxic antibody in the presence of anesthetics. *Eur. J. Immunol.* 5:259.
11. Pekonen, F., and B. D. Weintraub. 1978. Thyrotropin binding to cultured lymphocytes and thyroid cells. *Endocrinology*. 103:1668.
12. Khoury, E. L. 1982. Re-expression of blood group ABH antigens on the surface of human thyroid cells in culture. *J. Cell Biol.* 94:193.

13. Roitt, I. M., and D. Doniach. 1958. Human auto-immune thyroiditis: serological studies. *Lancet*. ii:1027.
14. Fagraeus, A., and J. Jonsson. 1970. Distribution of organ antigens over the surface of thyroid cells as examined by the immunofluorescence test. *Immunology*. 18:413.
15. Pulvertaft, R. J. V., D. Doniach, and I. M. Roitt. 1961. The cytotoxic factor in Hashimoto's disease and its incidence in other thyroid diseases. *Br. J. Exp. Pathol.* 42:496.
16. Toccafondi, R., C. M. Rotella, C. Marcocci, L. Bartalena, L. Chiovato, G. F. Fenzi, R. Zonefrati, and A. Pinchera. 1981. Measurement of thyroid cell surface antibodies by radioassay using human cultured thyroid cells. *J. Endocrinol. Invest.* 4:439.
17. Khoury, E. L., L. Hammond, G. F. Bottazzo, and D. Doniach. 1981. Surface reactive antibodies to human adrenal cells in Addison's disease. *Clin. Exp. Immunol.* 45:48.
18. Masala, C., G. Smurra, M. A. Diprima, M. A. Amendoleas, D. Celestino, and E. Salsano. 1980. Gastric parietal cell antibodies: demonstration by immunofluorescence of their reactivity with the surface of the gastric parietal cells. *Clin. Exp. Immunol.* 22:271.
19. Pujol-Borrell, R., E. L. Khoury, and G. F. Bottazzo. 1982. Islet cell surface antibodies in Type I (insulin dependent) diabetes mellitus: use of human fetal pancreas cultures as substrate. *Diabetologia*. 22:89.
20. Yoshida, H., N. Amino, K. Yagawa, D. Uemura, M. Satoh, K. Miyai, and Y. Kumahara. 1978. Association of serum antithyroid antibodies with lymphocytic infiltration of the thyroid gland: studies of seventy autopsied cases. *J. Clin. Endocrinol. Metab.* 46:859.
21. Hawkins, B. R., P. S. Cheah, R. L. Dawkins, S. Whittingham, H. G. Burger, Y. Patel, I. R. Mackay, and T. A. Welborn. 1980. Diagnostic significance of thyroid microsomal antibodies in randomly selected population. *Lancet*. ii:1057.
22. Hooper, B., S. Whittingham, J. D. Mathews, I. R. MacKay, and D. H. Curnow. 1972. Autoimmunity in a rural community. *Clin. Exp. Immunol.* 12:79.
23. Tunbridge, W. M. G., M. Brewis, J. M. French, D. Appleton, T. Bird, F. Clark, D. C. Evered, J. G. Evans, R. Hall, P. Smith, J. Stephenson, and E. Young. 1981. Natural history of autoimmune thyroiditis. *Br. Med. J.* 282:258.
24. Matsuura, N., Y. Yamada, Y. Nohara, J. Konishi, K. Kasagi, K. Endo, H. Kojima, and K. Wataya. 1980. Familial neonatal transient hypothyroidism due to maternal TSH-binding inhibitor immunoglobulins. *N. Engl. J. Med.* 303:738.
25. Roitt, I. M., N. R. Ling, D. Doniach, and K. G. Couchman. 1964. The cytoplasmic auto-antigen of the human thyroid. I. Immunological and biochemical characteristics. *Immunology*. 7:375.
26. Pinchera, A., G. F. Fenzi, L. Bartalena, L. Chiovato, C. Marcocci, and L. Baschieri. 1980. Antigen-antibody systems involved in thyroid autoimmunity. In *Autoimmune Aspects of Endocrine Disorders*. A. Pinchera, D. Doniach, G. F. Fenzi, and L. Baschieri, editors. Academic Press, London. 57-72.
27. Ekholm, R., G. Engstrom, L. E. Ericson, and A. Melander. 1975. Exocytosis of protein into the thyroid follicle lumen: an early effect of TSH. *Endocrinology*. 97:337.
28. Tice, L. W., and S. H. Wollman. 1974. Ultrastructural localization of peroxidase on pseudopods and other structures of the typical thyroid epithelial cell. *Endocrinology*. 94:1555.
29. Mauchamp, J., A. Margotat, M. Chambard, B. Charrier, L. Remy, and M. Michel-Bechet. 1979. Polarity of three-dimensional structures derived from isolated hog thyroid cells in primary culture. *Cell Tissue Res.* 204:417.
30. Forbes, I. J., I. M. Roitt, D. Doniach, and I. L. Solomon. 1962. The thyroid cytotoxic autoantibody. *J. Clin. Invest.* 41:996.

31. Irvine, W. J. 1962. Studies on the cytotoxic factor in thyroid disease. *Br. Med. J.* 1:1444.
32. Stuart, A. E., and W. S. A. Allan. 1958. The significance of basement-membrane changes in thyroid diseases. *Lancet.* ii:1204.
33. Sommers, S. C., and W. A. Meissner. 1954. Basement membrane changes in chronic thyroiditis and other thyroid diseases. *Am. J. Clin. Pathol.* 24:434.
34. Nitsch, L. S., and S. H. Wollman. 1980. Ultrastructure of intermediate stages in polarity reversal of thyroid epithelium in follicles in suspension culture. *J. Cell Biol.* 86:875.
35. Hanafusa, T., R. Pujol-Borrell, L. Chiovato, L. J. Hammond, and G. F. Bottazzo. 1982. Culture of human thyroid follicles with normal and reversed polarity. *Ann. Endocrinol. (Paris).* 43:25a.
36. Pujol-Borrell, P., T. Hanafusa, L. Chiovato, and G. F. Bottazzo. 1983. Lectin-induced expression of DR antigen on human cultured follicular thyroid cells. *Nature (Lond.).* 304:71.
37. Hanafusa, T., R. Pujol-Borrell, L. Chiovato, R. C. G. Russell, D. Doniach, and G. F. Bottazzo. 1983. Aberrant expression of HLA-DR antigen on thyrocytes in Grave's disease: relevance for autoimmunity. *Lancet.* ii:1111.
38. Bottazzo, G. F., R. Pujol-Borrell, T. Hanafusa, and M. Feldmann. 1983. Hypothesis: Role of Aberrant HLA-DR Expression and antigen presentation in the induction of endocrine autoimmunity. *Lancet.* ii:1115.
39. Dean, B. M., G. F. Bottazzo, and A. G. Cudworth. 1983. IgG subclass distribution in organ specific autoantibodies. Its relationship to complement-fixing ability. *Clin. Exp. Immunol.* 52:61.
40. MacLachlan, S. M., A. M. Dickinson, A. Malcolm, J. R. Farndon, E. Young, S. J. Proctor, and B. Rees Smith. 1983. Thyroid autoantibody synthesis by cultures of thyroid and peripheral blood lymphocytes. I. Lymphocyte markers and response to pokeweed mitogen. *Clin. Exp. Immunol.* 52:45.