

AMYLOID FIBRIL IN HEREDITARY CEREBRAL  
HEMORRHAGE WITH AMYLOIDOSIS (HCHWA) IS RELATED  
TO THE GASTROENTERO-PANCREATIC NEUROENDOCRINE  
PROTEIN, GAMMA TRACE\*

BY DANIEL H. COHEN,<sup>‡</sup> HELEN FEINER,<sup>§</sup> OLAFUR JENSSON,<sup>¶</sup> AND  
BLAS FRANGIONE<sup>§</sup>

*From the Departments of Medicine<sup>‡</sup> and Pathology,<sup>§</sup> Irvington House Institute, New York  
University Medical Center, New York 10016; and The Blood Bank,<sup>¶</sup> Genetical Division,  
University Hospital of Iceland, Reykjavik, Iceland*

Systemic amyloid diseases are known to result from the polymerization and deposition of variable region fragments of immunoglobulin light chains (AL), the amyloid A protein (AA) (1), and prealbumin fragments (PA) (2). The nature of the fibrillar proteins deposited in localized forms of amyloidosis remains unknown with the exception of those in medullary thyroid carcinoma (1), and the senile heart (3), which have been shown to be calcitonin and prealbumin-related, respectively. Precursor or related molecules are detectable in the serum for the AL, AA, and prealbumin (PA) types of amyloidosis. The localized deposits of amyloid in the brain, pancreas, or aorta, which are associated with the aging process (4), have not been characterized biochemically. Inheritance of genetic defects leading to systemic amyloidosis has been shown to occur in Familial Mediterranean Fever (1) and the autosomal dominant Familial Amyloid Polyneuropathy syndromes (2). The purpose of this paper is to report on the purification, antigenic localization, and biochemical analysis of amyloid proteins deposited in the small cerebral arteries and arterioles of three young Icelandic patients dying of cerebral hemorrhage secondary to a form of autosomal dominant amyloidosis shown to be localized to the cerebral vasculature by extensive postmortem examination (5). These nonhypertensive, previously healthy individuals, suffered sudden catastrophic, often multifocal cerebral hemorrhages from intraparenchymal and/or meningeal vessels extensively infiltrated with amyloid. 75 such cases of HCHWA from a large kindred in Iceland have been previously reported and characterized clinicopathologically elsewhere (5).

A condition similar to HCHWA has also been described in a member of a kindred originated from The Netherlands (6).

#### Materials and Methods

*Purification of Amyloid Fibrils.* Frozen brain and leptomenigeal tissue from three male Icelandic patients (PE, BA, SS) who died at ages 34, 36, and 24 of HCHWA was processed as follows: amyloid fibrils were purified from a preparation of pooled leptomeninges and

---

\* Supported by U. S. Public Health Service Research Grants No. AM 01431 and AM 02594.

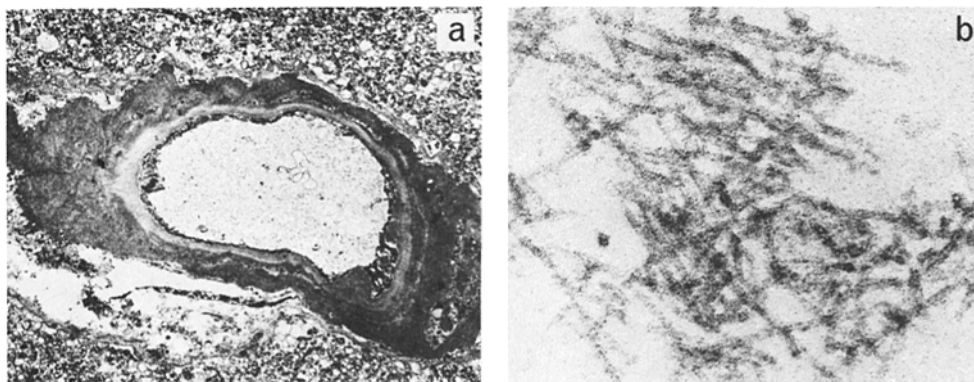


FIGURE 1. (a) Electron photomicrograph of a small intracerebral artery showing thickening of the vessel wall and obliteration of normal landmarks by fibrillar material characteristic of amyloid.  $\times 1,400$ . (b) Electron photomicrograph of extract from pooled meninges showing fibrils characteristic of amyloid.  $\times 187,500$ .

meningeal blood vessels dissected from the brains of the three patients. The fibrils were extracted in distilled water according to the method of Pras et al. (2) and then fractionated on Sephadex G-100 columns as previously described (2).

*Electron and Immunofluorescence Microscopy.* Tissue blocks 1 mm in greatest dimension and a water-soluble extract from the pooled leptomeninges were fixed in 2.5% glutaraldehyde and processed for electron microscopy according to routine procedure. 4- $\mu\text{m}$  thick frozen sections were incubated with antisera against IgG, M, A,  $\kappa$ , and  $\lambda$  light chains (Behring Diagnostics, Summerville, NJ) (direct technique) and against AA protein, prealbumin (Behring Diagnostics), amyloid P component, and gamma trace (made against soluble intact gamma trace isolated from urine) (7) (indirect technique). Negative controls included sections incubated with normal rabbit serum, sections incubated only with fluorescein-conjugated goat anti-rabbit IgG, and specimens of brain from five patients without cerebrovascular amyloid.

*Amino Acid Sequence and Amino Acid Analysis.* Automated amino acid sequencing was performed on a Beckman 890C sequencer (Beckman Instruments, Inc., Fullerton, CA). Phenylthiohydantoin amino acids were identified by high pressure liquid chromatography (HPLC) and by amino acid analysis. Amino acid analysis was performed on a Durrum Model D-500 amino acid analyzer (Durrum Instrument Corp., Sunnyvale, CA) (8).

## Results

Electron micrographs showed replacement of the normal landmarks of small cerebral and meningeal arteries by fibrillar material characteristic of amyloid (Fig. 1a). The distilled water extracts of the pooled leptomeninges showed similar fibrils (Fig. 1b) that exhibited green birefringence after Congo red staining.

Fig. 2a shows the elution profile obtained when amyloid fibrils from the three brains were fractionated on Sephadex G-100. Fraction I contained no amyloid fibrils and was not studied further. Peak II was composed predominantly of one subunit of molecular weight 11,500 daltons with another component of 15,800 daltons (Fig. 2c, lane 2). Fig. 2c, lane 1 shows the SDS-PAGE of the unfractionated amyloid fibril preparation which indicates that the latter is a minor species. Peak II was rechromatographed on Ultrogel AcA54 (LKB Instruments, Inc., Rockville, MD) in 3 M Guanidine 0.2 M  $\text{NH}_4\text{HCO}_3$  and a major and minor peak

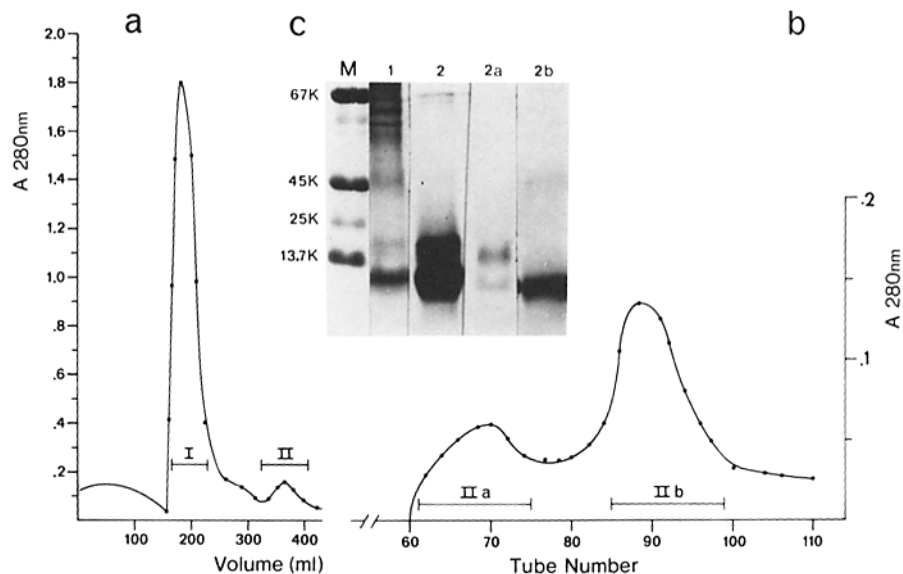


FIGURE 2. (a) Fractionation of HCHWA amyloid fibrils on  $2.5 \times 180$  cm Sephadex G100 column equilibrated in 5 M guanidine 1 M acetic acid. (b) Rechromatography of peak II on  $2.5 \times 180$  cm Ultrogel AcA54 column equilibrated in 3 M guanidine 2 M  $\text{NH}_4\text{HCO}_3$ . (c) SDS-PAGE 17% slab gel of unfractionated amyloid fibrils extracted from leptomeninges (lane 1). Lanes 2, 2a, and 2b are purified components from Fig. 2a and b. M, markers; 67K, bovine serum albumin 67,000 mol wt; 45K, ovalbumin 45,000 mol wt; 25K, chymotrypsinogen A 25,000 mol wt; 13.7K ribonuclease A 13,700 mol wt. All samples were reduced in 0.1 M dithiothreitol before application.

IIa, and IIb as seen in Fig. 2b were obtained. Fig. 2c, lanes 2a and 2b shows that peak IIa was mostly composed of the 15.8-k dalton minor band and peak IIb contained the pure 11.5-k dalton band.

The automated amino acid sequence of peak II Fig. 2a (36 residues) and peaks IIa and IIb Fig. 2b (26 and 18 residues respectively) showed them to be identical amongst themselves (Fig. 3). A computerized search for homologies to known proteins revealed that the HCHWA amyloid proteins are homologous to a recently described protein, gamma trace (9) starting at position 11. Moreover, the amino acid composition of purified peak IIb (not shown) was similar to that reported for human gamma trace (9).

**Immunofluorescence Microscopy.** There was bright localization of gamma trace in the walls of leptomeningeal and intracerebral arteries of all three patients with HCHWA (Fig. 4) as well as vascular localization of amyloid P component in two cases (PE and BA). A negative result was obtained with antisera to prealbumin, AA protein,  $\kappa$  or  $\lambda$  light chain, IgG, IgA, and IgM. Control brains from patients without neurologic disease and from five patients with Alzheimer's disease were also negative for gamma trace.

### Discussion

Localized cerebrovascular amyloidosis is sometimes present along with the characteristic plaques and neurofibrillary tangles in sporadic or familial Alzheimer's type disease (10), which usually presents clinically as a dementia, but

Human $\gamma$ trace	Ser-Ser-Pro-Gly-Lys-Pro-Pro-Arg-Leu-Val-Gly-Gly-Pro-Met-Asp- <sup>10</sup> Ala-Ser-Val-Glu-Glu-Glu-Gly-Val-Arg-Arg <sup>20</sup>
HCHWA amyloid peak II	_____
HCHWA amyloid peak IIa	_____
HCHWA amyloid peak IIb	_____
Human $\gamma$ trace	Ala-Leu-Asp-Phe- <sup>30</sup> Val-Gly-Glu-Tyr-Asn-Lys-Ala-Ser-Asn-Asp-Met-Tyr-His-Ser-Arg-Ala <sup>40</sup>
HCHWA amyloid peak II	_____
HCHWA amyloid peak IIa	_____
HCHWA amyloid peak IIb	_____

FIGURE 3. The amino terminal sequence of peaks II, IIa, and IIb from Fig. 2 compared with that of gamma trace (9). The solid lines indicate identical residues.

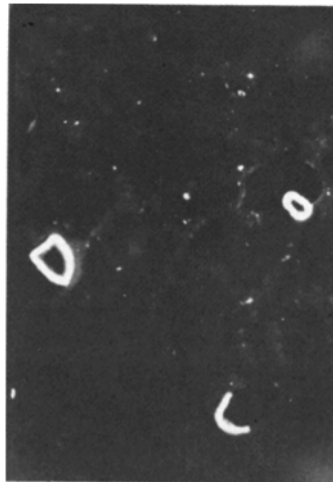


FIGURE 4. Immunofluorescence photomicrograph showing bright localization of gamma trace in three intracerebral arteries. Similar localization was present in meningeal vessels. Rabbit anti-human gamma trace and fluorescein-labeled goat anti-rabbit IgG were used.  $\times 225$ .

occasionally with cerebral hemorrhage in addition (11). Cerebrovascular amyloid disease, unassociated with neuritic plaques or tangles, can present as catastrophic cerebral hemorrhage in otherwise healthy nondemented individuals (11, 12), may also be sporadic (12) or hereditary (5, 6), and is increasingly recognized as a cause of cerebral hemorrhage (12, 13). Such congophilic angiopathy (without clinical manifestations) has also been shown to accumulate in the normal aging brain (13). Clinicopathological reports on large kindreds manifesting autosomal dominant HCHWA have originated from Iceland (5) and the Netherlands (6). The biochemical nature of the amyloid proteins in these diseases has remained unknown. It is important to determine whether the cerebrovascular amyloid in these hereditary syndromes is biochemically related to that associated with the normal aging process, Alzheimer's type dementias, or sporadic congophilic angiopathy with hemorrhage.

The amino acid sequences of the amyloid fibril subunits from these Icelandic patients (Fig. 3) and the reaction of their cerebral amyloid deposits with anti-

gamma trace antiserum (Fig. 4), indicates that the amyloid protein subunits share the same amino terminus and are related to gamma trace beginning at its eleventh amino terminal residue. Whether the HCHWA amyloid protein and the gamma trace are identical remains to be determined. The gamma trace-like material in HCHWA amyloid may have polymerized after the cleavage of the amino terminal decapeptide from gamma trace-related proteins.

Human gamma trace is a basic serum and cerebrospinal fluid (CSF) protein of molecular weight 13,260 daltons, with gamma electrophoretic mobility that has been localized immunocytochemically to the anterior pituitary, pancreatic A cells, and certain cortical neurons (9). Its concentration in CSF is fivefold that in serum and CSF concentrations are increased in the very young and the very old (14). Gamma trace is a hormone-like molecule in that it has sequence homologies to glucagon and corticotropin (9) but its physiological function remains unknown. Several other peptides have been shown previously to have a dual distribution in peptidergic central nervous system neurons and in endocrine cells located diffusely throughout the gastrointestinal tract and concentrated in the pituitary and pancreas: (vasoactive intestinal peptide, gastrin, corticotropin, somatostatin, met-enkephalin (15). It has been suggested that peptidergic cells in the gastrointestinal tract may attune the organism to the contents of the gut lumen and the corresponding central nervous system peptides can coordinate patterns of behavior with visceral and alimentary stimulation. Families of neuroendocrine peptides have been shown to be derived from common precursors in man and invertebrates (16). The gamma trace-related amyloid proteins described herein may represent precursors of new, as yet undescribed and/or known, active neuroenteropancreatic peptides. HCHWA appears to be the first genetic disease related to the diffuse peptidergic gastroenteropancreatic neuroendocrine system and detailed understanding of the biochemical defects in HCHWA may elucidate endocrine peptide processing common to the gut, brain, and endocrine glands in man.

### Summary

Amyloid fibrils were isolated from the leptomeningeal blood vessels obtained at autopsy from three Icelandic patients dying of Hereditary Cerebral Hemorrhage with Amyloidosis (HCHWA) and verified by Congo red staining and electron microscopy. Gel filtration on Sephadex and Ultrogel columns yielded predominantly one component (molecular weight 11,500 daltons) and also another minor component (molecular weight 15,800 daltons). Automated amino terminal sequencing showed these proteins to be similar (36 residues) to a recently described human protein, gamma trace, beginning at its eleventh amino terminal residue. The amyloid deposits in all three patients stained with rabbit anti-gamma trace antiserum. Although the function of gamma trace is not known, it appears to have structural homology with several hormones and has been localized to the brain, pancreas and pituitary. The amyloid fibril subunits seem to have polymerized after cleavage of the amino terminal decapeptide from gamma trace-related proteins. Therefore, HCHWA appears to be the first genetically determined disease related to the gastroenteropancreatic neuroendocrine system.

We would like to thank Dr. Anders Grubb, University of Lund, Malmo, Sweden for providing the anti-gamma trace antiserum and Mr. Arthur Kunz for his technical assistance.

Received for publication 14 March 1983 and in revised form 26 April 1983.

### References

1. Glenner, G. 1980. Amyloid deposits and amyloidosis: the beta fibrilloses. *N. Engl. J. Med.* 302:1283.
2. Pras, M., E. C. Franklin, F. Prelli, and B. Frangione. 1981. A variant of prealbumin from amyloid fibrils in familial polyneuropathy of Jewish origin. *J. Exp. Med.* 154:989.
3. Sletten, K., P. Westermark, and J. B. Natvig. 1980. Senile cardiac amyloidosis is related to prealbumin. *Scand. J. Immunol.* 12:503.
4. Schwartz, P. 1965. Senile pancreatic insular and cardiac amyloidosis. *Trans. N. Y. Acad. Sci.* 27:393.
5. Gudmundsson, G., J. Hallgrímsson, T. A. Jonasson, and O. Bjornason. 1972. Hereditary cerebral hemorrhage with amyloidosis. *Brain.* 95:387.
6. Wattendorf, A. F., G. Th. A. M. Bots, L. N. Went, and L. J. Edntz. 1982. Familial cerebral amyloid angiopathy presenting as recurrent cerebral hemorrhage. *J. Neurol. Sci.* 55:121.
7. Lofberg, H., A. O. Grubb, and A. Brun. 1981. Human brain control neurons contain gamma trace. Rapid isolation, immunohistochemical and physicochemical characterization of human gamma trace. *Biomed. Res.* 2:298.
8. Frangione, B., E. Rosenwasser, H. S. Penefsky, and M. E. Pullman. 1981. Amino acid sequence of the protein inhibitor of mitochondrial adenosine triphosphatase. *Proc. Natl. Acad. Sci. USA.* 78:7403.
9. Grubb, A., and H. Lofberg. 1982. Human gamma trace, a basic microprotein: amino acid sequence and presence in the adenohipophysis. *Proc. Natl. Acad. Sci. USA.* 79:3024.
10. Mandybur, T. I. 1975. The incidence of cerebral amyloid angiopathy in Alzheimer's Disease. *Neurology.* 25:120.
11. Okazaki, H., T. J. Reagan, and R. J. Campbell. 1979. Clinicopathological studies of primary cerebral angiopathy. *Mayo Clin. Proc.* 54:22.
12. Case records the Massachusetts General Hospital, Case No. 49-1982. R. E. Scully, E. J. Mark, and B. U. McNeely, editors. *N. Engl. J. Med.* 307:1507.
13. Vinters, H. V., and J. J. Gilbert. 1981. Amyloid angiopathy: its incidence and complications in the aging brain. *Stroke.* 12:118 (abstr.).
14. Lofberg, H., A. O. Grubb, T. Sveger, and J. E. Olsson. 1980. The cerebrospinal fluid and plasma concentrations of gamma trace and  $\beta 2$  microglobulin at various ages and in neurological disorders. *J. Neurol.* 223:159.
15. Powell, D., and P. Skrabanek. 1979. Brain and Gut. *Clin. Endocrinol. Metab.* 8:299.
16. Scheller, R. H., J. F. Jackson, L. B. McAllister, B. S. Rothman, E. Mayeri, and R. A. Axel. 1983. A single gene encodes multiple neuropeptides mediating a stereotyped behavior. *Cell.* 32:7.