

## Sequestra of Labyrinth.

By F. W. WATKYN-THOMAS, F.R.C.S.

PATIENT, a girl, aged 18. Old-standing chronic suppurative right otitis media, following scarlet fever. Swelling over right mastoid and temporal. Complete right facial palsy. Complete right deafness. Radical mastoid operation. Cholesteatoma. Sinus deep to the lateral sinus leading to sequestra, which were removed by the Neumann route. Uneventful recovery. Cavity filled by scar. Some facial recovery.

History vague. No recollection of vertigo.

Facial weakness noticed for "some months."

Dr. J. KERR LOVE (President) said he had no doubt the sequestra were from the cochlea and semicircular canal.

Dr. J. KERR LOVE (President) showed his double instrument for tonsillar operations, as a supplement to the instrument shown at the Section's last meeting by Mr. Tweedie.

[May 2, 1925]

## The Mastoid Emissary Vein and its Surgical Importance.

By ARTHUR CHEATLE, F.R.C.S.

## ANATOMY.

THE mastoid vein is treated with scant courtesy by anatomists and with still less by aural surgeons. Even Politzer does not mention it, except in connexion with "Griesinger's sign" in septic thrombosis of the lateral sinus and extension along the vein. Yet it is of interest as having a distinguished ancestry in being the remains of the primitive jugular vein, and sometimes it is of great surgical importance. In the greater number of specimens the vein is present; is single, and small; originates on the outer edge of the lateral sinus groove just below the bend; has a short course in the substance of the bone in an upward and backward direction; opens on the surface just behind the upper posterior edge of the base of the mastoid process on a level with the roof of the bony auditory meatus, to enter into the occipital or posterior auricular vein, then to form part of the external jugular vein. Being a vestige, it is subject to variation in every particular, and I show you instances which I have met with in my collection, and in the skulls at the Royal College of Surgeons' Museum. I must say at once that the investigation has been made in the canal of the dry bone only, a procedure to which there are some drawbacks, one being that a branch of the occipital artery passes through the same canal, and it may be that when the canal is duplicated, one of these is for that vessel.

*Presence.*—It is not uncommon for all traces of the vein to be absent bilaterally or unilaterally; I suppose that in the course of time the vein will disappear altogether.

*Size.*—The canal may be the size of a mere thread, or of a wax match, or from  $\frac{1}{8}$  to  $\frac{3}{8}$  of an inch in diameter. In two skulls it was nearly  $\frac{1}{2}$  inch, and as these cases are of special importance, I shall describe them separately. The veins with a canal of  $\frac{1}{8}$  of an inch or more in diameter must certainly make a great difference in the size of the external jugular vein, and it is possible that the canal would show in an X-ray photograph in the living subject. Those of  $\frac{1}{8}$  of an inch or more are certainly seen in the empty cleaned dry skull, as can be noted among the photographs shown. The groove for the lateral sinus below the origin of a large mastoid vein appears smaller.

### 30 Cheatele: *Mastoid Emissary Vein and its Surgical Importance*

*Number.*—It may be single at the origin and double at the exit, or double at origin and exit, or double at origin with three points of exit. In connexion with this the canal for the branch of the occipital artery must be remembered.

*Origin.*—This may be above the bend of the lateral sinus groove or much lower down, or in the groove itself. The vein may run in a groove before entering the bone. It may be double. There may be a distinct sulcus.

*Course.*—This is always in the substance of the bone, and although cells may border it above, outside and below, they are never internal to it. In other words, the canal is never surrounded by cells. It may be very short,  $\frac{1}{8}$  of an inch, especially if it originates low down, or long, up to  $\frac{3}{4}$  of an inch. The direction is often upwards and backwards, but it may be upwards, backwards, downwards and backwards, or downwards. Not infrequently it is curved. It may be translucent to the surface, especially when originating low down.

*Exit.*—This may be far back, reaching the masto-occipital suture, or even beyond it. It may be low down in the digastric fossa, or above and behind it, or behind it. If double, one may be behind, or below, the other. Sometimes there is a regular sulcus, into which diploic veins, or a superficial vessel, can be seen to enter.

*Asymmetry.*—This is not at all uncommon. The following instances have been noted:—

- 1 { Double at origin and exit on right side.  
   { Single at origin and exit on left side.
- 2 { Single at origin and exit, and in a groove at origin on right side.  
   { Single at origin and double at exit, and no groove on left side.
- 3 { Small, and running in a groove at origin on right side.  
   { Large and no groove at origin on left side.
- 4 { Small and single on right side.  
   { Large, single at origin, double at exit on left side.
- 5 { Large, with large digastric cell lying against it below on right side.  
   { Mere thread on left side.
- 6 Very large, replacing the lower part of the lateral sinus on the left side only.

*Association with the Petro-squamosal Sinus.*—There is no constant association, but it is seen here in two specimens. The petro-squamosal sinus groove occurs most frequently without abnormality of the lateral sinus, or of the mastoid vein.

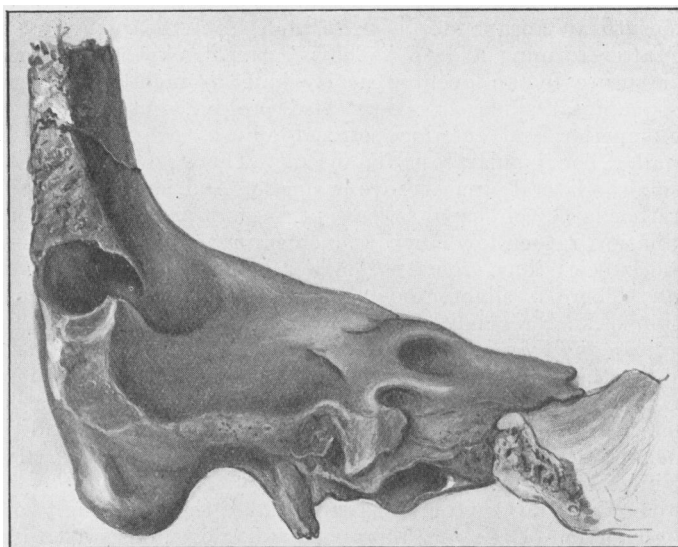
**TWO SKULLS IN WHICH THE VEIN TAKES THE PLACE OF THE LOWER PART OF THE LATERAL SINUS:—***On both sides in one, and on the left side only in the other.*

I will now describe the two specimens alluded to before, in which the vein canal measured nearly half an inch in diameter.

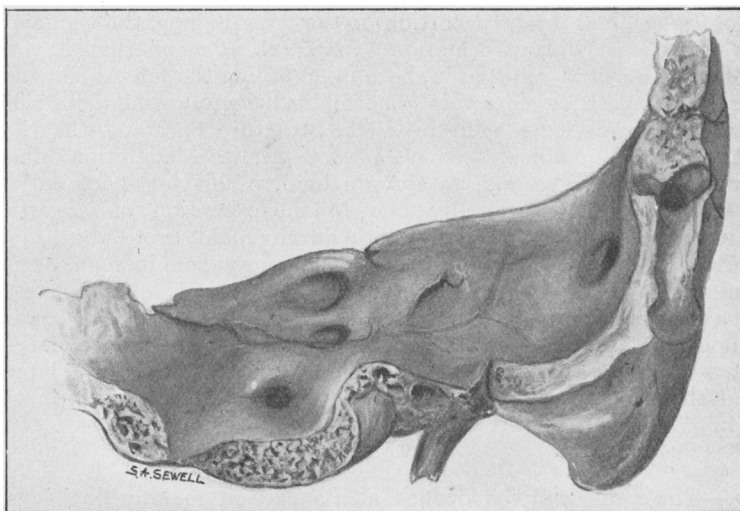
This condition was found in two instances among 1,500 skulls examined in the collection of the Royal College of Surgeons' Museum.

(1) No. 612.1, Royal College of Surgeons' Museum, No. 13 among the specimens shown. It is a French skull in which the back part is broken away. On both sides the lower part of the lateral sinus groove is absent. On the left side the lateral sinus groove, which is larger than that on the right, comes to an end just below the outer end of the posterior border of the temporal bone, and turns backwards to a large mastoid vein canal nearly half an inch in diameter. The same condition is present on the right side, but the lateral sinus groove and vein canal are much smaller, the latter measuring a quarter of an inch in diameter. A deep groove runs downwards superficially for an inch from the exit. This external groove is seen in ungulates. The jugular foramina are small and the fossæ are absent on both sides. There are no other abnormalities.

(2) No. 154.1, Royal College of Surgeons' Museum, No. 13A among the specimens shown. This is an English skull sectioned vertically in half. On the



Left bone.



Right bone.

No. 612.1.—COLLECTION OF SKULLS. ROYAL COLLEGE OF SURGEONS' MUSEUM.

Drawings of the posterior aspect of the temporal bones from a French skull in which the back part is broken away.

On both sides the lower part of the lateral sinus groove is absent.

On the left side the groove is large and measures nearly  $\frac{1}{2}$  in. in diameter; the right side  $\frac{1}{4}$  in.

On the right side there is a deep groove running superficially downwards from the exit for an inch, a condition seen also in the skulls of some ungulates.

The jugular foramina are small on both sides, and the jugular fossæ absent.

left side a large lateral sinus groove runs down the posterior surface of the temporal bone, then comes to an abrupt stop half an inch from the jugular foramen, turns outwards, and after forming a deep "elbow" runs backwards to emerge at the masto-occipital suture by an opening nearly half an inch in diameter. A well-marked petro-squamosal sinus groove is also present, but without an external opening. The superior and inferior petrosal sinuses are present. The jugular foramen is small. The jugular fossa is absent. There are no other abnormalities. On the right side the lateral sinus groove is smaller, and is continued to the jugular foramen. A rather large vein canal is present, measuring an eighth of an inch in diameter, originating rather low down and emerging by two openings—one behind the other. The lateral sinus groove is smaller below the vein origin. The jugular bulb is present. There is slight grooving for a petro-squamosal sinus. The only other description of such a condition I have found is one by P. P. Laidlaw, in the *Journal of Anatomy and Physiology*, 1902-3, xxxvii, p. 364. He describes an Egyptian temporal bone in the Cambridge University Museum, in which there is partial absence of the lateral sinus groove associated with the presence of a large mastoid foramen. There is also absence of the internal acoustic meatus and of the stylo-mastoid foramen. The jugular fossa is absent. The superior petrosal sinus groove is present, the inferior absent.

Piersol, in his "Human Anatomy" (1918), makes the following two statements: "The horizontal portion of the left lateral sinus has been observed to be lacking or reduced to an exceedingly fine channel, and one or both of the sinuses have been observed to pass through a greatly enlarged mastoid foramen, to open into the posterior auricular vein, the sigmoid sinus being represented only by a very small channel" (p. 869). In writing of the petro-squamosal sinus, he says that it "represents the original terminal portion of the lateral sinus, the sigmoid portion of that sinus being a secondary formation" (p. 869). It seems that, in some animals at all events, the mastoid vein has a share in emptying the lateral sinus.

In searching for a reason for this abnormality, the following dicta were borne in mind. The first by Wiedersheim in "The Structure of Man," that "the venous system shows unmistakable traces of a very primitive condition inherited from lower vertebrates"; the second, by Cunningham, in his text-book on "Anatomy," that "abnormalities are generally due to the retention of conditions which normally are only transitory in ontogenetic development, or to the acquirement of conditions which, though not as a rule present at any time in man, occur normally in some animals." From my investigations, which are not yet complete, there is no doubt that this abnormality is an atavistic one. One finds a similar condition in the lemur, in dogs, and in ungulates, as you will see in the skulls shown. In all these a large petro-squamosal sinus is also present, the lower part of the lateral sinus is absent, and there is a well-marked mastoid vein canal, especially in the dog and horse. I hope to report further on this matter.

#### SURGICAL IMPORTANCE.

*Injury.*—The vein may be opened at its exit in making incisions, or when stripping up the periosteum in various operative procedures, or in its course, in removing bone for extensive cellular infection, or for exploration and treatment of lateral sinus thrombosis, cerebellar abscess or tumour, or in the operation of decompression and in fracture of the skull. As a rule the bleeding is trivial and easily controlled by plugging with gauze or Horsley's wax, but in the larger ones in which we are practically opening the lateral sinus, and actually doing so in a case like the two specimens separately described, it may be troublesome, and I would suggest using a muscle plug. The temporal muscle is always at hand in aural operations.

*Sepsis.*—The vein may be infected from the lateral sinus and this would appear to be inevitable in the larger ones. In such cases an oedematous swelling or abscess

may form at the exit, constituting "Griesinger's sign" of lateral sinus thrombosis; and as Politzer states, in his only reference to the vein, this sign may be behind the mastoid process, or in the posterior triangle. The specimens shown demonstrate why this varying position of the sign should occur. The vein may become septicly thrombosed after an accidental, or incidental, opening, with secondary implication of the lateral sinus. I have heard of such a case occurring after an operation for extensive mastoiditis, necessitating the opening of and shutting off of the lateral sinus. It may be separately and directly septicly thrombosed from infected mastoid cells; such a case was described by Dr. Joseph Friedman and Dr. Samuel D. Greenfield, in *The Laryngoscope*, 1923, xxxiii, p. 347. During an operation for acute mastoid infection, the vein was exposed and found to be of great size,  $\frac{3}{8}$  in. in diameter, and to be thrombosed without implication of the lateral sinus. It was left unopened, but subsequently the sepsis spread to the lateral sinus, which had to be dealt with. One can imagine sepsis spreading from the vein to the diploic veins, which open into it, causing osteo-myelitis and local inflammatory signs in unexpected parts of the skull. One can also realize that if the sepsis has extended down the occipital and external jugular veins, or if the lateral sinus empties entirely through the mastoid vein, it would be necessary to ligature and excise the external jugular in the same way as the internal jugular is dealt with in lateral sinus thrombosis.

*Abnormality of the Groove for the Superior Petrosal Sinus.*

An Indian skull sectioned vertically in half, No. 653.2, Royal College of Surgeons' Museum, No. 12A in the specimens shown. Although not germane to the original subject, the abnormality was discovered during the investigation. On the right side a large mastoid vein canal is present, measuring  $\frac{1}{2}$  in. in diameter; on the left side the canal is small. On the right side only, a vein canal leaves the upper and anterior aspect of the inner tympanic wall, penetrates the superior surface of the temporal bone at the level of the ampullary end of the superior semicircular canal, then divides into two branches, one running backwards and inwards on the superior surface to reach the posterior edge, when it turns outwards to run on its usual course to the lateral sinus groove, the other branch running inwards to the cavernous sinus.

I wish to offer my sincere thanks to the Council of the Royal College of Surgeons for the use of its material, to Sir Arthur Keith for good help and advice, and to the staff of the Museum.

*Discussion.*—Dr. DAN MCKENZIE said that unless one practised the dissection of temporal bones for oneself he did not think it was possible to obtain the essential intimate knowledge of the anatomy of this region. The temporal bone was one of the most variable of all human structures.

On one occasion, he (the speaker), when a junior, had had to operate in the country for mastoid suppuration. He made the usual incision and found a cellular mastoid process; he made a horizontal incision further back, and in doing so, he cut into an enormous vessel which yielded a great spurt of blood. He placed his finger on it to stop it. He could not tie it, he had no antiseptic wax with him, and he thought it might be possible to put in an ordinary strip of gauze. So large was the foramen that the gauze went in comfortably, and the bleeding stopped. He wondered whether in such a case the orifice could be stopped safely with soap. He had found that the inside of a cake of ordinary toilet soap was sterile. Subsequently, as he had on a former occasion reported to the Section, this case developed a septic clot in contact with the packing, but the lateral sinus and emissary vein were opened up and the patient recovered.

Dr. LOGAN TURNER said it was a great pleasure to see Mr. Cheate again exhibiting some of his anatomical work. Specialists in rhinology and otology seemed to have struck a region which was full of abnormalities. Dr. McKenzie's remarks about the variations in the mastoid might be equally applied to the sinuses.

Another point of interest was the possibility of cavernous sinus thrombosis arising through the mastoid emissary vein. He (the speaker) recalled the interesting case of a man with

a carbuncle of the neck, who developed cavernous sinus thrombosis and meningitis. At the post-mortem examination the process of infection was found to have extended from the occipital vein, through the mastoid emissary vein to the lateral sinus, and thence through the superior petrosal to the cavernous sinus. Hence there arose a connexion between the superficial occipital venous system and the cavernous sinus in certain cases which might make primary infection in the neck a possible source of cavernous sinus thrombosis.

Mr. CHEATLE (in reply) said he had forgotten to mention one point, which had reference to what Dr. Logan Turner said about secondary infection of the vein. It was recorded that veins behind the auricle empty into the emissary vein, hence there was always the risk of infection spreading from the surface.

### Case of Bilateral Mumps Deafness.

By NICOL RANKIN, M.B.

(Introduced by Dr. DAN MCKENZIE).

K. H., AGED 10, female. About the middle of January, 1925 she had a pyrexial attack during which it is said she had some transient vertigo. This was followed by "ringing" and "thumping" in both ears, and on January 29 she suddenly became deaf in the left ear. Next day she was found to be deaf in the right ear also, and at the same time she was found to be suffering from mumps. No vertigo was experienced at this stage.

*Hearing.*—Tuning fork (middle C) is not heard at all by air-conduction on either side, and the bone-conduction is minus 30 (approx.).

Vestibular tests (rotation and caloric) produced a normal ocular response but without any vertigo, although after prolonged rotation the child vomited. No vertigo was noticed during the mumps attack.

Suggestions for treatment are invited. Is pilocarpine of value?

*Discussion.*—Sir JAMES DUNDAS-GRANT said he wondered whether Members had better success than he with pilocarpine in this class of case.

Dr. KERR LOVE (President) said that this whole group of cases, and the cases of congenital deafness, had one feature in common, namely, that the cochlear part of the eighth nerve was involved, and, as a rule, the vestibular nerve was not. That raised the question of the pathology, as to whether these cases were toxic; whether there was a neuritis, or a meningitis, or, lastly, whether they must be classed as "hysterical."

Sir WILLIAM MILLIGAN said that the prognosis of these cases was bad. The deafness was not always bilateral. He agreed that pilocarpine was practically useless; the only time he had seen it do good was when injected within a few days of the onset of the deafness. It was an interesting speculation as to what caused the extreme deafness in these cases. In some there was probably a localized basal meningitis, the deafness occurring much on the same principle as the profound deafness in cerebro-spinal meningitis. He (the speaker) had not found any treatment of use in these cases.

Mr. RANKIN (in reply) said that the best course to take in this case would be to instruct the child in lip-reading. He had not known of any case in which benefit was derived from pilocarpine.

### Case of Sudden Bilateral Nerve Deafness of Unknown Origin in a Child.

By DAN MCKENZIE, M.D.

THE girl is 10 years of age. Two years ago she awoke one morning almost completely deaf in both ears. There was no vertigo and the incident was not associated with any other illness. She had measles when 4 years old, and mumps a year after the deafness appeared. There has never been any ear discharge. Tonsils and