

Diagnosis and management of microscopic colitis

Ayman A. Abdo, MD, FRCPC Paul Beck, MD, PHD, FRCPC

ABSTRACT

OBJECTIVE To describe microscopic colitis (MC) and a stepwise approach to its diagnosis and management.

QUALITY OF EVIDENCE MEDLINE was searched from January 1996 to August 2002. Controlled trials were sought, but due to their relative rarity, most articles cited are well designed retrospective studies and reviews.

MAIN MESSAGE Microscopic colitis in both its collagenous and lymphocytic forms is a relatively common and important cause of diarrhea in middle-aged and elderly patients. It usually presents as chronic watery diarrhea. Results of endoscopic and radiologic examinations are normal; specific histologic findings are seen on colonic biopsy. Once the diagnosis is confirmed, we suggest a stepwise approach to therapy. First-line therapies include antidiarrheal agents; second-line include bismuth subsalicylates and budesonide; third-line include cholestyramine and 5-aminosalicylic acid agents. When patients fail to respond to these therapies, oral corticosteroids or immune modulatory therapy should be considered. For severe unresponsive cases, colectomy is the last resort.

CONCLUSION Microscopic colitis is an important cause of chronic diarrhea. Once the diagnosis is confirmed, a stepwise approach to treatment is suggested.

RÉSUMÉ

OBJECTIF Définir la colite microscopique et proposer une démarche par étapes pour le diagnostic et le traitement.

QUALITÉ DES PREUVES Une recherche a été effectuée dans MEDLINE entre janvier 1996 et août 2002. Les essais contrôlés recherchés étant toutefois peu nombreux, la plupart des articles cités sont des revues et des études rétrospectives de qualité.

PRINCIPAL MESSAGE La colite microscopique, qu'elle soit collagénique ou lymphocytaire, est une cause importante et relativement fréquente de diarrhée chez les adultes d'âge moyen et avancé. Une diarrhée aqueuse chronique en est la manifestation habituelle. Les examens endoscopiques et radiologiques sont normaux, mais la biopsie colique révèle des changements histologiques spécifiques. Une fois le diagnostic confirmé, on suggère une démarche thérapeutique par étapes. Le traitement de premier recours inclut les antidiarrhéiques; la deuxième étape fait appel au subsalicylate de bismuth et au budésônide; la troisième étape inclut la cholestyramine et l'acide 5-aminosalicylique. En cas d'échec de ces traitements, une corticothérapie orale ou un traitement d'immunomodulation devrait être envisagé. Dans les cas réfractaires sévères, la colectomie constitue un dernier recours.

CONCLUSION La colite microscopique est une importante cause de diarrhée chronique. Une fois le diagnostic établi, on suggère d'adopter une démarche thérapeutique par étapes.

This article has been peer reviewed.

Cet article a fait l'objet d'une évaluation externe.

Can Fam Physician 2003;49:1473-1478.

Microscopic colitis (MC) is an inflammatory condition of the colon in which the colonic mucosa appears normal under endoscopic and radiologic examination, but histologic examination reveals specific features. Microscopic colitis is two separate but related diseases, collagenous colitis (CC) and lymphocytic colitis (LC). The two are similar in presentation and natural history, but differ in histologic appearance.

In both conditions, the colonic mucosa's lamina propria is inflamed and has increased intraepithelial lymphocytes. In CC, but not in LC, marked thickening of the subepithelial collagen layer is the hallmark of the disease. Microscopic colitis has attracted attention recently as an important and relatively common cause of chronic diarrhea.^{1,2} In this article, we review MC in both its forms (CC and LC) emphasizing practical issues in diagnosis and management from a family physician's perspective with a critical review of the available literature.

Quality of evidence

MEDLINE was searched from January 1966 to August 2002 using the headings "collagenous colitis," "lymphocytic colitis," and "microscopic colitis." We found 950 publications, of which 747 remained after exclusion of non-English-language papers. When further restricted to clinical trials, only 17 publications were found; six were directly related to MC, and only one was a randomized trial. Restricting the search to review articles, we found 76 articles, only eight of which directly addressed MC. Because controlled trials are rare, we have included all clinical trials, well designed retrospective studies, and reviews. We have critically examined all the available evidence on every treatment option and have graded the evidence from level I to level III according to the Canadian Task Force on Preventive Health Care.

Epidemiology

A description of MC was first published in 1976. Since that time, it has been increasingly recognized as a common cause of chronic diarrhea.³ Although initially thought to be rare, more recent estimates suggest that yearly incidence of CC is around 0.6 to 2.3 per 100 000 population and prevalence around 10.0 to 15.7 per 100 000 in Europe.⁴ It could be as high as 15 per 100 000 in elderly women (similar to the incidence of

Drs Abdo and Beck teach in the Division of Gastroenterology at the University of Calgary in Alberta.

ulcerative colitis⁵). Incidence and prevalence of LC have been estimated at about 3.1 and 14.4 per 100 000, respectively.

Some believe the prevalence of both LC and CC has been markedly underestimated. One recent abstract suggested that MC now represents up to 20% of cases of irritable bowel disease (IBD).⁶ At present, there are no published epidemiologic data from North America. One retrospective study from three tertiary care centres in Canada found 94 cases of CC from 1990 to 1997.⁷ Another study done in Turkey assessed all patients undergoing colonoscopy for chronic diarrhea and found that, of those whose colonic mucosa appeared normal under endoscopy, 10% had MC.⁸

Initially, the disease seemed to affect more women than men, but more recent reviews have shown no significant difference in prevalence between the sexes.⁹ Increased recognition of MC in recent years is likely due to increased awareness of its existence so that gastroenterologists routinely biopsy patients with endoscopically normal-appearing colons. Microscopic colitis typically presents in the sixth or seventh decade of life, but it has been reported in all age groups, including children.¹⁰

Clinical features

The main symptom of MC is chronic intermittent diarrhea.² Some patients lose weight, or have abdominal pain or nonspecific upper gastrointestinal symptoms. Arthralgias and various other autoimmunelike conditions also appear to be associated with MC and can be seen in as many as 40% of patients.⁹

The disease most commonly associated to date is celiac disease. About a third of patients with celiac disease have histologic changes that could be compatible with MC.¹¹ Collagenous colitis should be sought particularly in patients with celiac disease who do not respond to a gluten-free diet. Collagenous sprue has also been described with changes similar to CC in the stomach or small bowel.¹²

To date, no clear evidence indicates that MC is an inherited disease. Patients in several families, however, have first-degree relatives diagnosed with MC.^{13,14}

Histopathology

The following features suggest a histologic diagnosis of CC^{15,16}: diffuse discontinuous thickening of a subepithelial collagen layer under the basement membrane of more than 10 mm (range 7 to 80 mm); inflammation in the lamina propria consisting mainly

of lymphocytes and plasma cells; and epithelial lesions (flattening, detachment, and intraepithelial lymphocytosis). The second and third criteria are enough to diagnose LC (collagen layer remains unthickened).

The site in the colon where diagnostic yield for MC is highest is controversial. Earlier reports suggested that sigmoid biopsies are reliable and miss only few CC patients.¹⁷ Other reports suggested that rectosigmoid biopsies can miss up to 40% of cases.¹⁸ More recent reports suggest that the transverse colon provides the most diagnostic biopsies.¹⁹ If true, colonoscopic examinations would be required for those with negative biopsies from sigmoidoscopic examinations.

Diagnosis

A detailed history should be the first step in evaluating patients suspected of having MC. This should include duration of diarrhea and a description of stools. In MC, diarrhea is often chronic and intermittent, and usually watery, although steatorrhea has been described occasionally. Severe bloody diarrhea is not compatible with MC. Other gastrointestinal symptoms that could indicate celiac disease or IBD should be investigated. Possibly associated autoimmune diseases should also be considered.

Other causes of chronic diarrhea should be ruled out: infections, and inflammatory and drug-related causes. Stool cultures should be taken and stool should be examined for ova and parasites. In general, complete blood count, erythrocyte sedimentation rate, and fecal leukocyte count are normal in patients with MC, so these tests are not helpful in making the diagnosis unless IBD is suspected. Similarly, radiologic investigations, including barium studies, are not useful for these patients, but might be required originally to rule out other causes, especially in older patients. Sigmoidoscopy is generally accepted as the first-line endoscopic procedure. If biopsies from the sigmoid colon are normal and clinical suspicion remains high, a full colonoscopy is warranted given that the studies discussed above show a possible miss rate as high as 40% with sigmoidoscopy alone.

Natural history

The natural history of MC is not clear. Complete symptomatic remission can be seen in as many as 60% of LC patients and 34% of patients with CC after 6 months of follow up.²⁰ Other studies suggest a 15%

spontaneous recovery rate and a 48% recovery rate with treatment after 3.5 years of follow up.²¹

Treatment

The poorly understood pathophysiology of MC means there have been many therapeutic interventions that have had variable degrees of success. A stepwise approach has been suggested by many authors,^{1,22} and we agree (**Figure 1**). Our approach is based on the literature and the strength of existing evidence.

General measures. General measures should be carried out first. Patients' volume status and general condition should be assessed. Volume repletion and corrections of possible aggravating factors, such as caffeine, dairy products, dietary supplements, and artificial sweeteners, should be the initial step in management.

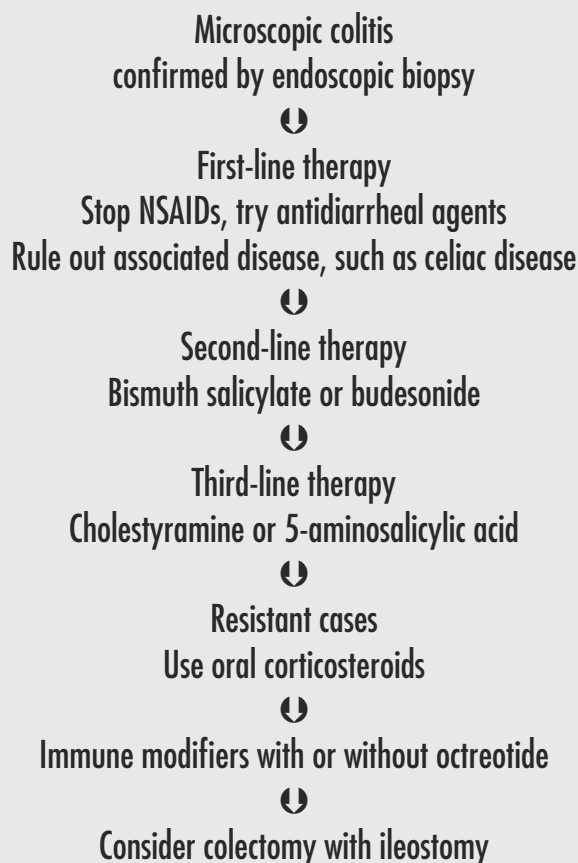
Medications. Medications that could aggravate symptoms or even contribute to pathogenesis, such as nonsteroidal anti-inflammatory drugs (NSAIDs) should be stopped if possible because some authors have suggested a strong association between MC and NSAIDs.^{23,24} Other studies do not support the association.^{7,25} Given the possible exacerbating effect of NSAIDs on other forms of IBD and studies suggesting a beneficial effect of stopping NSAIDs, it seems reasonable to suggest stopping NSAIDs if possible and assessing patients' response¹ (level III evidence).

Nonspecific antidiarrheal therapy. No prospective or randomized studies focused on this therapy. Results of the two largest retrospective studies are included in **Table 1**.^{9,22} Given the relative safety of these agents and the possibility of spontaneous remission, many groups have suggested antidiarrheal agents should be first-line therapy for MC^{9,22} (level II evidence). Octreotide has been reported to relieve symptoms of patients with CC.²⁸

Bile acid binders. A recent study by Ung et al²⁹ found that 44% of patients with CC had abnormal Se-mochoolic acid taurine levels (SeHCAT test) suggesting bile acid malabsorption.²⁹ All patients (normal and abnormal SeHCAT tests) were treated with open-label cholestyramine (4 g/d) or colestipol (5 g/d) as bile acid binders; 78% of them had rapid, marked, or complete improvement. Most (92%) patients with abnormal SeHCAT test results improved rapidly, as did 67% of patients with normal results. In their large series, Bohr et al⁹ reported a 59% response rate to cholestyramine (level II evidence).

Table 1. Summary of therapeutic options for treating microscopic colitis: *Suggested doses and clinical response.*

THERAPY	STRENGTH OF EVIDENCE	DOSE PER DAY	CLINICAL RESPONSE (BOHR ET AL ⁹) %	CLINICAL RESPONSE (ZINS ET AL ²³) %	CLINICAL RESPONSE (OTHER STUDIES) %
Loperamide	II	2-16 mg	71 (n = 69)		
Bismuth	I	2-3 tablets daily			91 (n = 12) ²⁶
Budesonide	I	9 mg	100 (n = 2)		57 (n = 28) ³⁰ 76 (n = 51) ³¹
Cholestyramine	II	4-20 g	59 (n = 44)	33 (n = 6)	
Sulfasalazine	III	2-4 g	59 (n = 108)		
Mesalamine	III	2-4 g	45 (n = 31)	92 (n = 13)	
Steroids	II	10-50 mg	82 (n = 39)	84 (n = 31)	
Azathioprine	II	2.0-2.5 mg/kg			87 (n = 8) ²⁷
Metronidazole	III	500 mg three times daily	55 (n = 44)	36 (n = 11)	
Erythromycin	III	500 mg twice daily	67 (n = 15)		

Figure 1. Suggested treatment for patients with microscopic colitis

NSAIDs—nonsteroidal anti-inflammatory drugs.

Bismuth subsalicylate. A prospective open-label study examined use of eight chewable 262-mg bismuth subsalicylate tablets daily for 8 weeks by patients with MC (seven of whom also had CC).²⁶ Of the 12 patients completing the trial, 11 had resolution of diarrhea and a reduction in fecal weight after an average of 2 weeks, and nine had resolution of histologic changes.

After a follow-up period of 7 to 28 months, nine patients remained well, two required more treatment, and one still had diarrhea. The same authors later reported (in abstract form only) results of a randomized study of 14 patients with MC (nine with CC). Seven patients were randomized to bismuth (same dose as above) and seven to placebo. Patients were then crossed over and had posttreatment sigmoidoscopy and biopsy. Treatment was effective in 12 of the 13 patients completing the trial; nine patients had long-term remission. No notable side effects or toxicities were reported. Based on these results, bismuth is suggested as second-line therapy after antidiarrheal agents for patients with CC (level I evidence).

Budesonide. Two randomized, placebo-controlled trials have investigated the effect of budesonide in treatment of MC. In the first study,³⁰ budesonide (9 mg/d for 8 weeks) was compared with placebo in 28 Belgian patients with CC. Eight of the 14 patients completing the trial (on an intention-to-treat basis) responded to treatment ($P = .05$). No reduction in the thickness of the collagen layer was seen, but inflammation of the lamina propria was greatly reduced.

More recently, a larger randomized, double-blind, placebo-controlled, multicentre trial³¹ involving 51 patients with CC randomized subjects to budesonide (9 mg/d for 6 weeks) or placebo. Clinical response was seen in 76% of treated patients, but only 12% of placebo patients in intention-to-treat analyses. Histologic improvement was seen in 60% in the budesonide group, but only 4% in the placebo group. Budesonide should also be considered as second-line therapy for patients unresponsive to simple antidiarrheal therapy (level I evidence).

Mesalamine or sulfasalazine. No prospective or randomized studies were identified. Results of the two large retrospective studies are included in **Table 1**. Most experts are not impressed by these agents, especially when what seem to be more potent agents are available. For this reason

Editor's key points

- Microscopic colitis, an inflammatory condition of the colon, appears normal on endoscopic examination, but has characteristic histologic features. It is a relatively common cause of chronic watery diarrhea in middle-aged and elderly people.
- Clinically, little distinguishes it from other forms of chronic, intermittent diarrhea that cause weight loss and abdominal pain. Arthralgias or autoimmune symptoms are commonly associated; celiac disease is especially linked.
- Diagnostically, blood tests and x-ray examinations are of little use: biopsy with a sigmoidoscope or colonoscope is necessary when symptoms warrant.
- A stepwise approach to management is suggested: avoid nonsteroidal anti-inflammatory drugs and aggravating foods; use antidiarrheal agents (bismuth subsalicylate or budesonide, cholestyramine or 5-aminosalicylic acid); if necessary, then use steroids or immune modifiers with or without octreotide; and finally, perform colectomy in extreme cases.

Points de repère du rédacteur

- Dans la diarrhée microscopique, l'examen endoscopique est négatif, mais la biopsie révèle des changements histologiques typiques. Cette affection inflammatoire du côlon est une cause relativement fréquente de diarrhée aqueuse chronique chez les adultes d'âge moyen et avancé.
- Cliniquement, elle se distingue mal des autres formes de diarrhée chronique intermittente qui causent amaigrissement et douleurs abdominales. Elle s'accompagne souvent d'arthralgies et de symptômes auto-immuns. On note une association particulière avec la maladie cœliaque.
- Les examens sanguins et radiologiques sont peu utiles au diagnostic: quand les symptômes sont importants, une biopsie par sigmoïdoscopie ou colonoscopie s'impose.
- On préconise une démarche thérapeutique par étapes: élimination des anti-inflammatoires non stéroïdiens et des aliments provocateurs; prescription d'antidiarrhéiques (subsalsalicylate de bismuth ou budésônide, cholestyramine ou acide 5-aminosalicylique); passage éventuel aux stéroïdes ou aux immunomodulateurs, avec ou sans octréotide; et, enfin, recours à la colectomie dans les cas extrêmes.

5-acetylsalicylic acid agents should probably be used only after patients have failed a trial of bismuth or budesonide (level III evidence).

Corticosteroids. No prospective or randomized studies were identified. Results of the two largest retrospective reports are included in **Table 1** (level II evidence). Patients refractory to the above therapies should be treated with a short course of steroids. Most patients respond positively to therapy, but the relapse rate is high.

Immune modulatory therapy. Pardi et al²⁷ reported retrospective analyses of all patients treated at the Mayo clinic for MC with azathioprine and 6-mercaptopurine. Nine patients with MC were identified; six of them had CC. Patients were either refractory to steroids or dependent on steroids. Four of the eight patients taking steroids had resolution of diarrhea, and steroids were withdrawn. The other patients were able to taper or discontinue steroids successfully, but had mild residual diarrhea. Severe diarrhea persisted in one patient who required an ileostomy.

In another study, methotrexate treatment for concomitant rheumatoid arthritis was associated with a positive clinical response in two patients.⁹ Patients refractory to steroids, with relapse after discontinuation of steroids, or requiring prolonged courses of steroids should be referred to tertiary care centres for consideration of immune modulatory therapy (level II evidence).

Conclusion

Microscopic colitis in both its forms, collagenous and lymphocytic colitis, is a relatively common and important cause of diarrhea in middle-aged and elderly patients. Other causes of chronic diarrhea must be ruled out and sigmoidoscopy performed for colonic biopsies. Once a diagnosis of MC is confirmed, a step-wise approach with medical therapy is suggested. ❁

Competing interests

None declared

Correspondence to: Dr Paul L. Beck, University of Calgary, Health Sciences Centre, Division of Gastroenterology, 3330 Hospital Dr NW, Calgary, AB T2N 4N1; telephone (403) 220-4500; fax (403) 270-0995; e-mail plbeck@ucalgary.ca

References

1. Pardi DS, Smyrk TC, Tremaine WJ, Sandborn WJ. Microscopic colitis: a review. *Am J Gastroenterol* 2002;97(4):794-802.
2. Bohr J, Olesen M, Tysk C, Jarnerot G. Collagenous and lymphocytic colitis: a clinical and histopathological review. *Can J Gastroenterol* 2000;14(11):943-7.
3. Lindstrom CG. 'Collagenous colitis' with watery diarrhoea—a new entity? *Pathol Eur* 1976;11(1):87-9.

4. Fernandez-Banares F, Salas A, Forne M, Esteve M, Espinos J, Viver JM. Incidence of collagenous and lymphocytic colitis: a 5-year population-based study. *Am J Gastroenterol* 1999;94(2):418-23.
5. Bohr J, Tysk C, Eriksson S, Jarnerot G. Collagenous colitis in Orebro, Sweden: an epidemiological study 1984-1993. *Gut* 1995;37(3):394-7.
6. Cross A, Treanor D, Keegan D, Sheahan K, Mulcahy H, O'Donoghue D. Microscopic colitis: increased incidence or increased recognition? *Gastroenterology* 2002;122(4):A602-3.
7. Abdo A, Raboud J, Freeman HJ, Zetler P, Tilley J, Chau H et al. Clinical and histological predictors of response to medical therapy in collagenous colitis. *Am J Gastroenterol* 2002;97(5):1164-8.
8. Erdem L, Yildirim S, Yilmaz B, Gultekin O, Koksal H, Peker O. The rate of microscopic colitis in patients with chronic diarrhea with unknown etiology. *Gastroenterology* 2002;122(4):W1608.
9. Bohr J, Tysk C, Eriksson S, Abrahamsson H, Jarnerot G. Collagenous colitis: a retrospective study of clinical presentation and treatment in 163 patients. *Gut* 1996;39(96):846-51.
10. Gremse DA, Boudreaux CW, Mancini EA. Collagenous colitis in children. *Gastroenterology* 1993;104(3):906-9.
11. Breen EG, Farren C, Connolly CE, McCarthy CF. Collagenous colitis and coeliac disease. *Gut* 1987;28(3):364.
12. McCashland TM, Donovan JP, Strobach RS, Linder J, Quigley EM. Collagenous enterocolitis: a manifestation of gluten-sensitive enteropathy. *J Clin Gastroenterol* 1992;15(1):45-51.
13. Abdo AA, Zetler PJ, Halparin LS. Familial microscopic colitis. *Can J Gastroenterol* 2001;15(5):341-3.
14. Van Tilburg AJ, Lam HG, Seldenrijk CA, Stel HV, Blok P, Dekker W, et al. Familial occurrence of collagenous colitis. A report of two families. *J Clin Gastroenterol* 1990;12(3):279-85.
15. Lazenby AJ, Yardley JH, Giardiello FM, Jessurun J, Bayless TM. Lymphocytic ("microscopic") colitis: a comparative histopathologic study with particular reference to collagenous colitis. *Hum Pathol* 1989;20(1):18-28.
16. Jessurun J, Yardley JH, Giardiello FM, Hamilton SR, Bayless TM. Chronic colitis with thickening of the subepithelial collagen layer (collagenous colitis): histopathologic findings in 15 patients. *Hum Pathol* 1987;18(8):839-48.
17. Zins BJ, Tremaine WJ, Carpenter HA. Collagenous colitis: mucosal biopsies and association with fecal leukocytes. *Mayo Clin Proc* 1995;70(5):430-3.
18. Carpenter HA, Tremaine WJ, Batts KP, Czaja AJ. Sequential histologic evaluations in collagenous colitis. Correlations with disease behaviour and sampling strategy. *Dig Dis Sci* 1992;37(12):1903-9.
19. Offner FA, Jao RV, Lewin KJ, Havelec L, Weinstein WM. Collagenous colitis: a study of the distribution of morphological abnormalities and their histological detection. *Hum Pathol* 1999;30(4):451-7.
20. Baert F, Wouters K, D'Haens G, Hoang P, Naegels S, D'Heygere F, et al. Lymphocytic colitis: a distinct clinical entity? A clinicopathological confrontation of lymphocytic and collagenous colitis. *Gut* 1999;45(3):375-81.
21. Goff JS, Barnett JL, Pelke T, Appelman HD. Collagenous colitis: histopathology and clinical course. *Am J Gastroenterol* 1997;92(1):57-60.
22. Zins BJ, Sandborn WJ, Tremaine WJ. Collagenous and lymphocytic colitis: subject review and therapeutic alternatives. *Am J Gastroenterol* 1995;90(9):1394-400.
23. Riddell RH, Tanaka M, Mazzoleni G. Non-steroidal anti-inflammatory drugs as a possible cause of collagenous colitis: a case-control study. *Gut* 1992;33(5):683-6.
24. Giardiello FM, Hansen FC III, Lazenby AJ, Hellman DB, Milligan FD, Bayless TM, et al. Collagenous colitis in setting of nonsteroidal antiinflammatory drugs and antibiotics. *Dig Dis Sci* 1990;35(2):257-60.
25. Veress B, Lofberg R, Bergman L. Microscopic colitis syndrome. *Gut* 1995;36(6):880-6.
26. Fine KD, Lee EL. Efficacy of open-label bismuth subsalicylate for the treatment of microscopic colitis. *Gastroenterology* 1998;114(1):29-36.
27. Pardi DS, Loftus EV Jr, Tremaine WJ, Sandborn WJ. Treatment of refractory microscopic colitis with azathioprine and 6-mercaptopurine. *Gastroenterology* 2001;120(6):1483-4.
28. Fisher NC, Tutt A, Sim E, Scarpello JH, Green JR. Collagenous colitis responsive to octreotide therapy. *J Clin Gastroenterol* 1996;23(4):300-1.
29. Ung KA, Kilander A, Nilsson O, Abrahamsson H. Long-term course in collagenous colitis and the impact of bile acid malabsorption and bile acid sequestrants on histopathology and clinical features. *Scand J Gastroenterol* 2001;36(6):601-9.
30. Baert F, Schmit A, D'Haens G, Dedeurwaerdere F, Louis E, Cabooter M, et al. Budesonide in collagenous colitis: a double-blind placebo-controlled trial with histologic follow-up. *Gastroenterology* 2002;122(1):20-5.
31. Miehle S, Heymer P, Bethke B, Bastlein E, Meier E, Bartram H, et al. Budesonide treatment for collagenous colitis: a randomized, double-blind, placebo-controlled, multicenter trial. *Gastroenterology* 2002;123(4):978-84.