

Arnis Freiberg, MD, FRCSC Stephen Dougherty, MD

A Review of Management of Ingrown Toenails and Onychogryphosis

SUMMARY

The purpose of this paper is to propose a rational treatment protocol according to basic surgical principles, anatomy of the nail bed, and etiological factors. Ingrown toenails have been discussed in medical literature for more than 1300 years. The condition commonly affects young adults and may result in significant morbidity in terms of loss of days from work, education, and recreation. The anatomy and physiology of the nail bed are presented to promote better selection of the proper management procedure. Ingrown toenails can be classified in terms of congenital or acquired causes. A surgical protocol, along with a description of each surgical technique, is supplied. The pathology of onychogryphosis is classified in terms of involvement of the germinal matrix, the sterile matrix, or both. Treatment is determined by the severity and underlying medical condition of the patient. (*Can Fam Physician* 1988; 34:2675-2681.)

Key words: toe nails, ingrown, onychogryphosis, treatment protocol

RÉSUMÉ

Cet article propose un protocole thérapeutique rationnel de l'ongle incarné fondé sur les principes chirurgicaux de base, l'anatomie du lit unguéal et les facteurs étiologiques. Les premières discussions que l'on retrouve à ce sujet dans la littérature médicale remontent à plus de 1300 ans. C'est une condition fréquente, autant chez les jeunes que chez les adultes, et sa morbidité devient significative en termes de jours perdus au travail, à l'école et dans les activités sportives. On y rappelle l'anatomie et la physiologie du lit de l'ongle, ce qui permettra de mieux choisir la ligne de conduite appropriée. On classifie les ongles incarnés selon leurs causes congénitales ou acquises. L'article présente un protocole chirurgical comportant la description de chacune des techniques. La classification pathologique de l'onychogryphose est fonction de l'implication de la matrice germinative, de la matrice stérile ou des deux. La gravité de la condition médicale sous-jacente du patient déterminera le traitement approprié.

Dr. Freiberg is Head of the Division of Plastic Surgery of Toronto Western Hospital and an Associate Professor of Plastic Surgery in the University of Toronto. Dr. Dougherty was an interne elective at Toronto Western Hospital at time of the preparation of this manuscript. Requests for reprints to: Dr. A. Freiberg, Toronto Western Hospital, Edith Cavell Wing, 4-020, 399 Bathurst Street, Toronto, Ont. M5T 2S8

THE ANATOMY of the toenail (Figure 1) consists of the nail plate, the nail bed, and surrounding soft tissue, including the proximal nail fold, which extends approximately 6 mm over the base of the nail plate, called the "lunula". The nail bed consists of germinal and sterile

matrices. The germinal matrix originates close to bone, just beyond the proximal one-sixth of the distal phalanx, and ends at the sterile matrix, located close to the distal lunula. Upper germinal matrix cells are also located on the under surface of the proximal nail fold. The sterile matrix provides both adherence and a sliding surface for the nail plate. The nail plate measures 0.5 mm in thickness, and grows distally and parallel to the nail bed. It is composed of three layers: dorsal, intermediate and ventral. The first two are formed by the upper and lower germinal matrices, and the third from the sterile matrix.¹ Nail keratin is a scleroprotein with a high sulphur content. Toenails grow at a rate of approximately 1.5 mm per month, and there is a 50% decrease

of linear growth rate over one's lifetime.²

Classification and Pathophysiology of Ingrown Toe Nails

Ingrown toe nails can be classified as either congenital (too narrow or too wide) or acquired (either acute [infected] or chronic) (Chart 1) (Figure 2). Etiological factors, therefore, are: deformity of the nail (congenital or acquired); pressure on the nail walls (tight footwear); or softening and laxity of the surrounding soft tissue (Chart 2). Molding action of pressure causes the nail plate to turn downwards and "dig in". As the cuticle folds converge, the nail plate is squeezed and raised in its centre. The penetrated cuticle fold causes

inflammation, erosion, granulation, swelling, pain, infection, and disability.³

Prophylactic Management

The aims of management are: to make a correct diagnosis; and to choose an appropriate treatment protocol. Non-operative therapy includes proper transverse cutting of nails, avoiding cutting of corners (Figure 3), central filing, soaking feet twice a day in warm water, followed by careful drying and placement of cotton wool under the corners of the nail plate and along the nail sulcus (Figure 4). This is continued until the nail plate once again extends past the end of the toe. The patient should

wear proper-fitting shoes with a low heel and adequate toe box. Follow-up should be arranged for at least six months. The disadvantage of this treatment plan is the high default rate. Lloyd-Davies found that after two years of attending a toe clinic, 40% of patients had defaulted, 33% were cured, and 27% were still being treated.⁴

Operative Management

Operative indications include: persistence of pain or disability after 1-2 weeks of adequate non-operative treatment; late presentation with chronic changes and unsuitability for non-operative management; local abscess; or troublesome nail regrowth

Chart 1 Classification of Ingrown Toenails

1. Congenital
 - too narrow
 - too wide
2. Acquired
 - acute
 - chronic

Chart 2 Pathophysiology of Ingrown Toenails

1. Deformity of nail plate
 - congenital
 - acquired through faulty cutting
2. Pressure on nail walls
 - adjacent toes
 - footwear
3. Surrounding soft tissues
 - softening and laxity

Figure 1
Nail-Bed Anatomy and Terminology

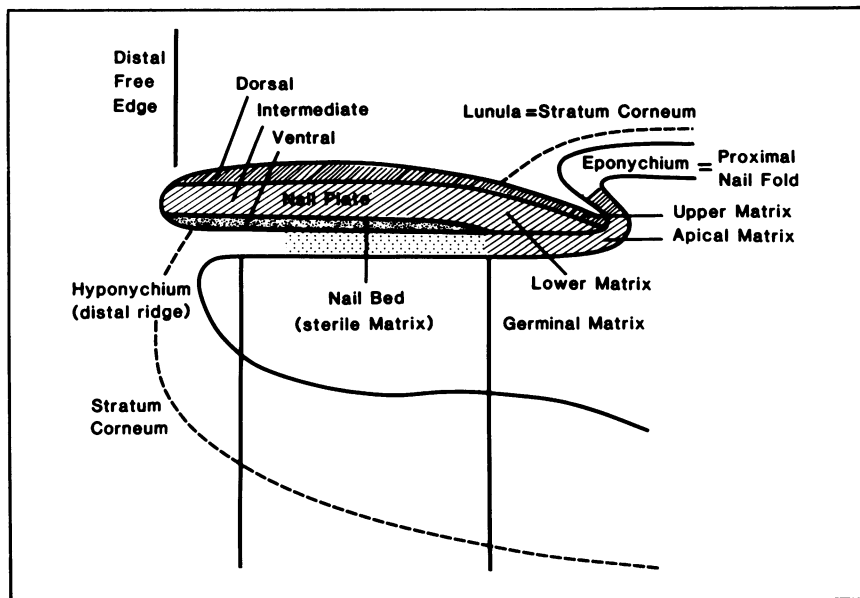


Figure 3
Proper Nail Care: Prophylaxis

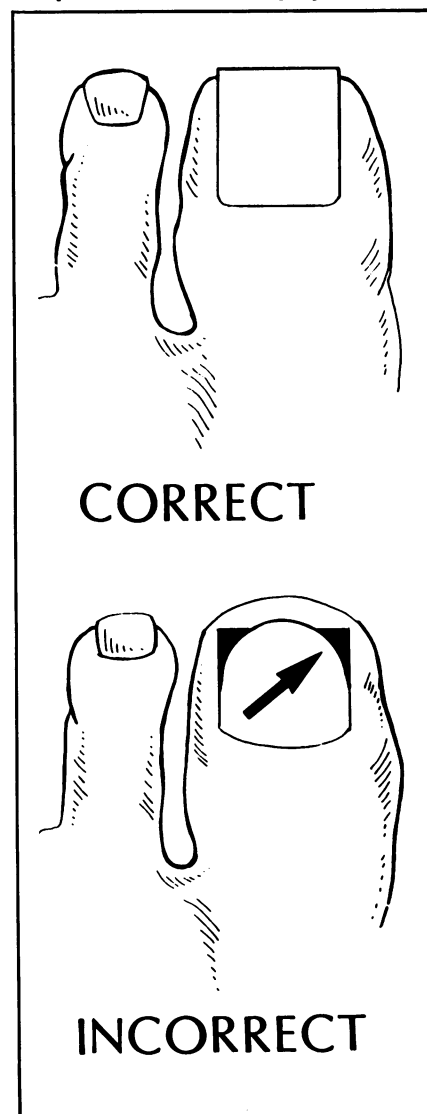
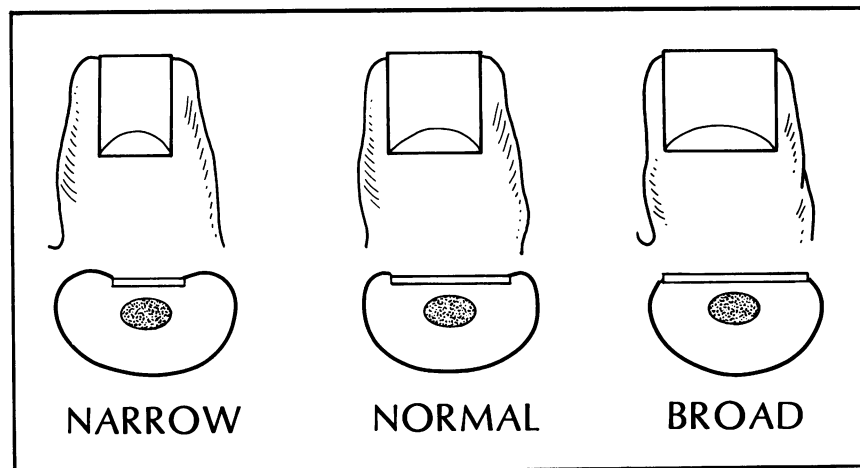


Figure 2
Classification of Ingrown Toenails



after earlier surgery.⁵ The procedure should be simple with a minimal recurrence rate. Normal footwear should be worn with comfort within a week of operation.⁶

Toe-nail surgery is minor surgery. It requires local digital and dorsal cutaneous nerve blocks. For big toes, general anesthesia is needed only if cellulitis is present proximal to the IP joint. A penrose drain tourniquet, #11 scalpel blade, scissors, jelonet, wet gauze, and bulky dressing are needed. The dressing should be removed in 3-4 days.

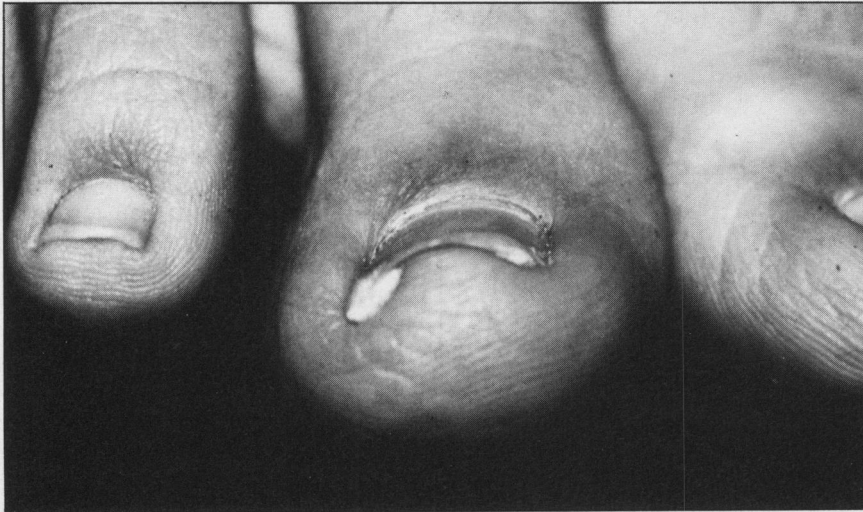Operative procedures include nail-

plate avulsion. This procedure may be partial (medial wedge, lateral wedge), as indicated for acute relief of pain and removal of dead nail plate, or total, as indicated for acute infection or abscess formation. One blade of a straight hemostat is inserted under one side of the nail plate until it reaches the base of the nail. The hemostat is then closed and appropriate rotary movement is applied to remove the nail. It is of utmost importance to remove *all* the nail plate remnants, especially those that are loose and often imbedded laterally in the granulation tissues. Excessive

granulation tissue and macerated lateral fold tissue is excised. The abscess or infective process is thus relieved, and proper wound care and cleansing should follow until healing is complete.

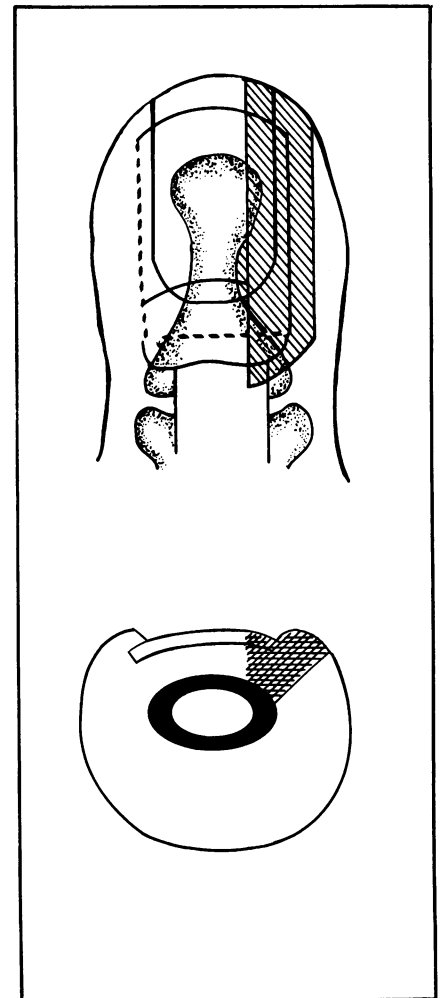
Soaking and topical antibiotics, which are often suggested, are ineffective and unnecessary. Systemic antibiotics are seldom used and are only indicated in diabetics and in patients with more proximal cellulitis. The advantage of this procedure is the rapid relief of symptoms and eradication of infection. The disadvantage is the low cure rate, reported as only 36%

Figure 4
Dressing Nail-Bed



Packing of small amounts of cotton under nail plate to encourage nail-plate growth away from the soft tissue.

Figure 5
Partial Excision of an Ingrown Toenail

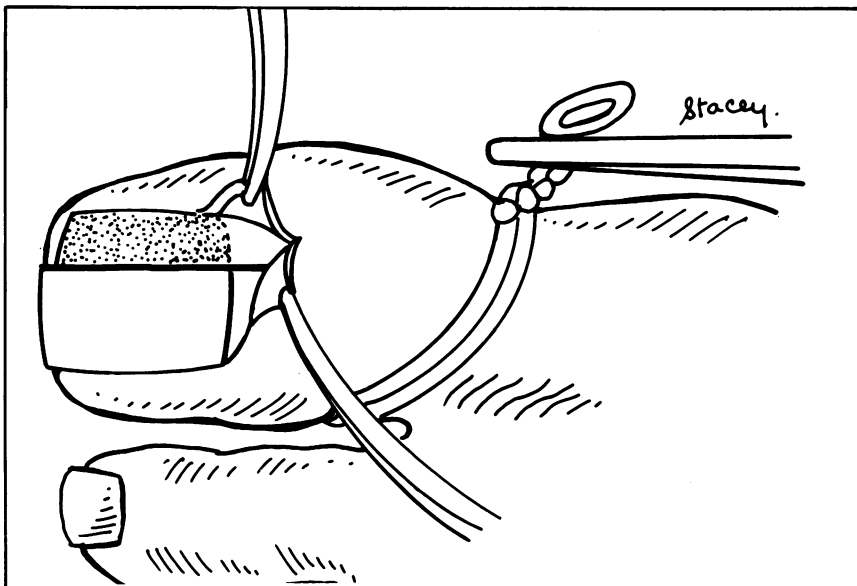


A "classical" partial or wedge excision of an ingrown toenail (shaded part excised). Note that portions of both sterile and germinal matrices are excised, including the proximal nail fold.

Chart 3
Surgical Protocol

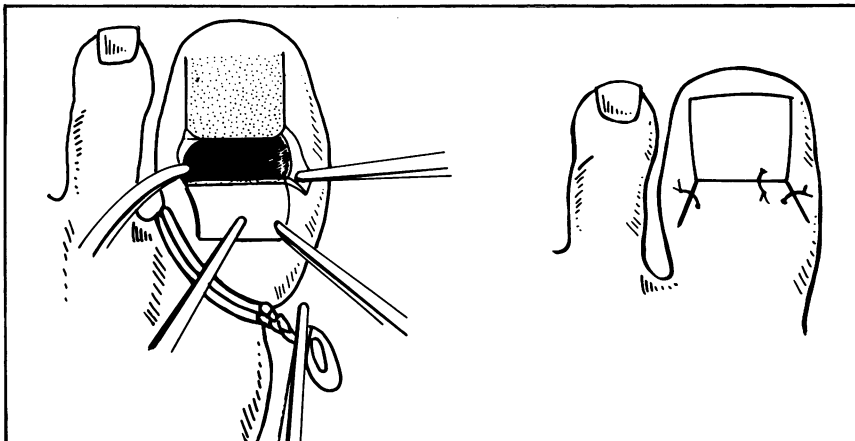
Technique	Indication
A) Nail-plate avulsion	
a) partial	- Acute relief of pain
b) total	- Acute abscess, infection
B) Radical nail-bed excision	
i) classical germinal + sterile matrices	
ii) Selective germinal matrix	
a) partial (classical)	- 1) Congenital or acquired unilateral nail deformity
	- 2) Unilateral troublesome nail regrowth
b) total (selective)	- Bilateral congenital or acquired ingrown toenails
C) Symes procedure	

Figure 6



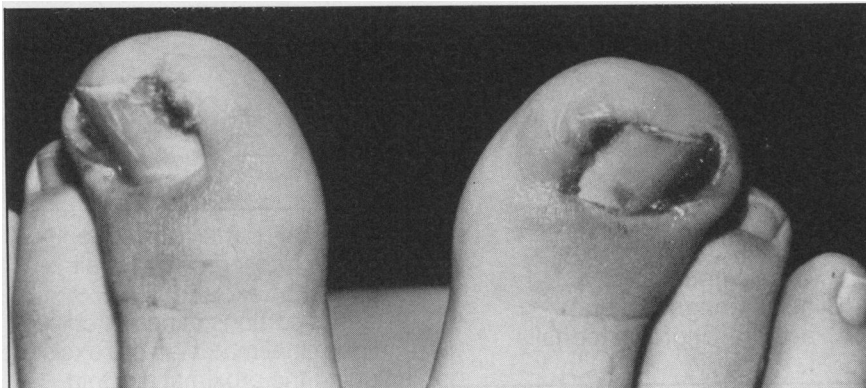
Selective (wedge) excision of germinal matrix only (non-shaded portion of nail bed), for unilateral ingrown problems.

Figure 7
Total (radical) Nail-Bed Ablation



The proximal nail-fold skin is reflected, the dark portion (germinal matrix) is selectively excised, and the skin flap sutured. Note the use of a tourniquet, which is important for proper visualization.

Figure 8
Bilateral, Acute, Acquired Ingrown Toenails



successful.⁵ The surrounding lateral nail folds are sometimes large and fibrosed, and the digital pulp tends to move dorsally when the nail is avulsed. The new nail, which is often thick and less pliant than the original nail, is frequently unable to depress this tissue as it regrows, and a recurrence of the condition results.

The definitive procedures include radical nail-bed excisions. This procedure may be partial (wedge, used for either a congenital unilateral nail-plate deformity or for correction of unilateral, troublesome, nail regrowth after previous surgery) or total, used for medial and lateral ingrowth of nails that show either congenital or acquired problems (Chart 3). Partial radical nail-bed excision classically involves removal of a wedge of nail plate and underlying sterile and germinal matrices (Figure 5). A selective radical nail-bed excision removes only the V-shaped wedge of germinal matrix (Figure 6), but poor exposure of the germinal matrix may lead to incomplete excision and troublesome nail regrowth. Thus full exposure of each proximal corner of the germinal matrix is essential for complete excision of the remnants.

The technique for partial (wedge) nail-bed excision includes making a single, diagonal, 1-cm incision at the base of the nail and reflecting the proximal nail fold.⁷ Using scissors, remove 1 cm longitudinal wedge of nail plate by placing the blades above and below the nail plate and cutting right to its base. Use a scalpel to excise the total nail bed, continuing down to the periosteum and taking care to excise all "crumbs" in the basal corner and lateral areas of the matrix. The epithelium on the undersurface of the adjacent nail wall is excised. The skin is resutured to the nail plate.

The technique for total nail-bed ablation (Figure 7) consists of removal of the nail plate after making two diagonal incisions, one at each proximal nail corner.⁸ A scalpel is then used to excise selectively all of the germinal matrix (white) down to, but preserving, the periosteum. The diagonal incisions and the skin of the proximal nail fold are resutured, and a non-adherent dressing is applied. After germinal matrix excision, the ventral nail plate re-epithelialises on

Figure 9
Eight Months Following Simple Partial Avulsions of Nail Plates

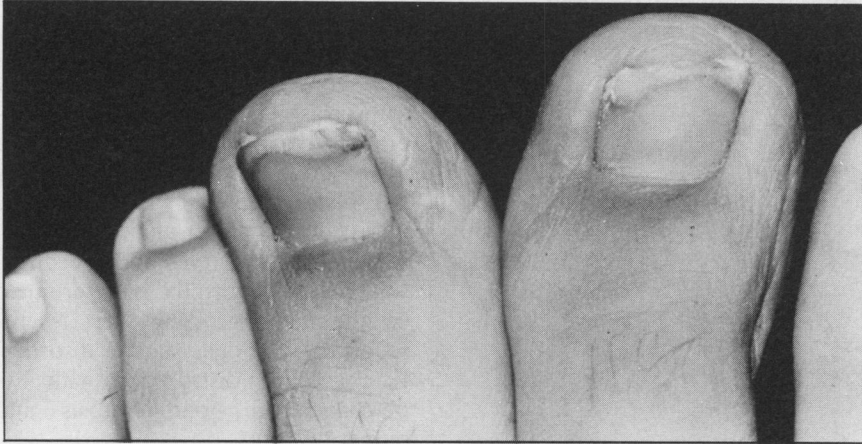


Figure 10
Congenital, Narrow, Ingrown Toenail

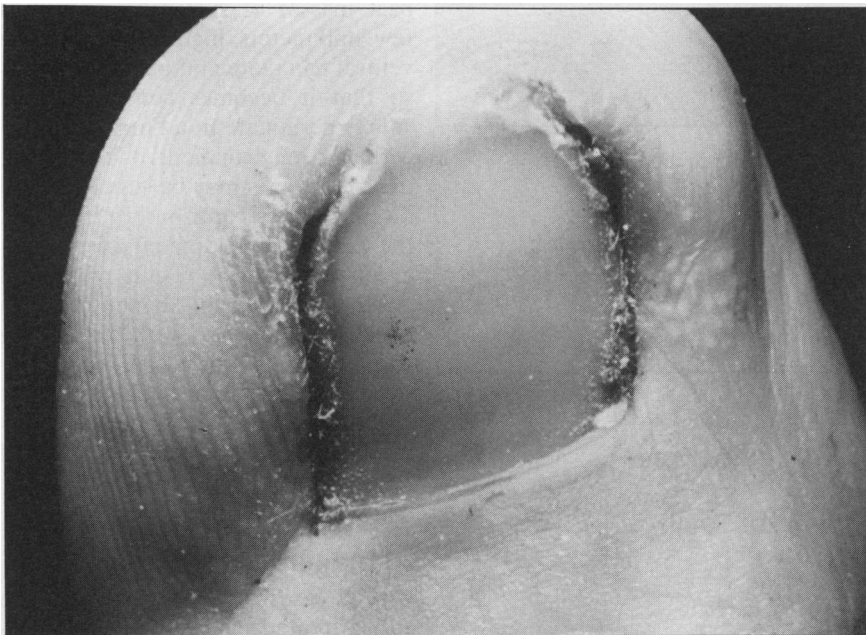
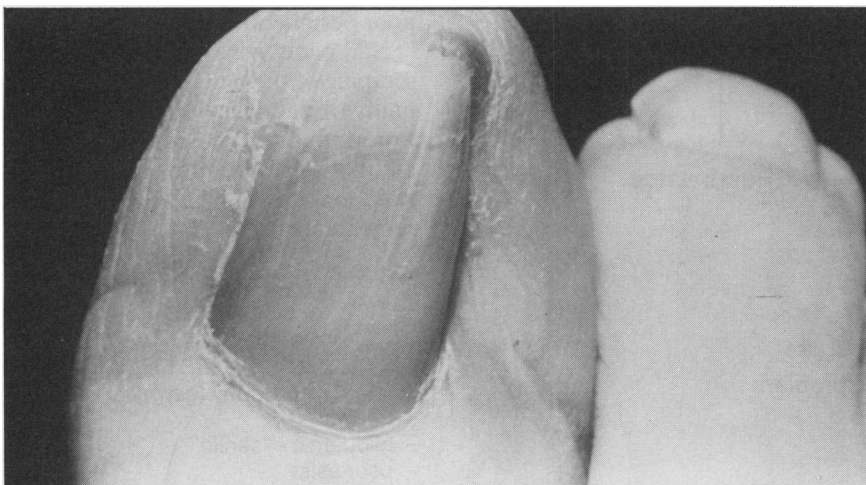


Figure 11
Post-Operative Toenail



Twenty-four Months post-operatively, treated by classical bilateral wedge (partial) excision of sterile and germinal matrices.

its own, originating from the sterile matrix. It covers and protects the nail bed with a hyponychial keratin layer. Symptomatic recurrence rates for single wedge nail-bed excision are reported as 25% by Winograd, and for total nail-bed ablation as between 0% and 16% by Zadik.⁹ Patients should be followed for at least six months.

Symes operation is described as excision of the terminal half of the phalanx, including removal of the nail plate, nail wall, and germinal matrix; and closure by a plantar flap. This operation is rarely indicated and then only for symptomatic nail regrowth, after both total nail-bed ablation and one attempt at local re-ablation have failed. This procedure, however, results in a short, bulbous toe.⁵

Results

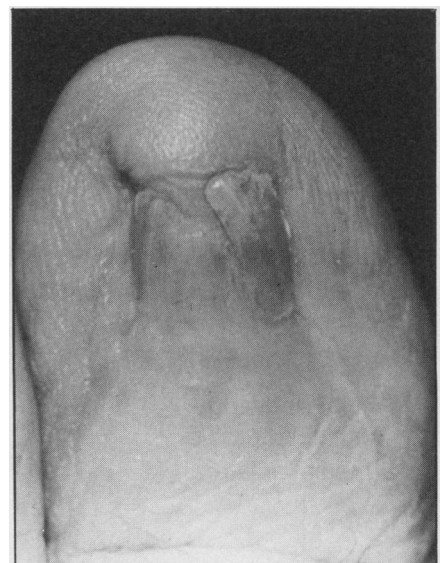
The preceding treatment protocol has been used successfully by the senior author for the past 15 years.

Representative results are illustrated in Figures 8–12.

Onychogryphosis

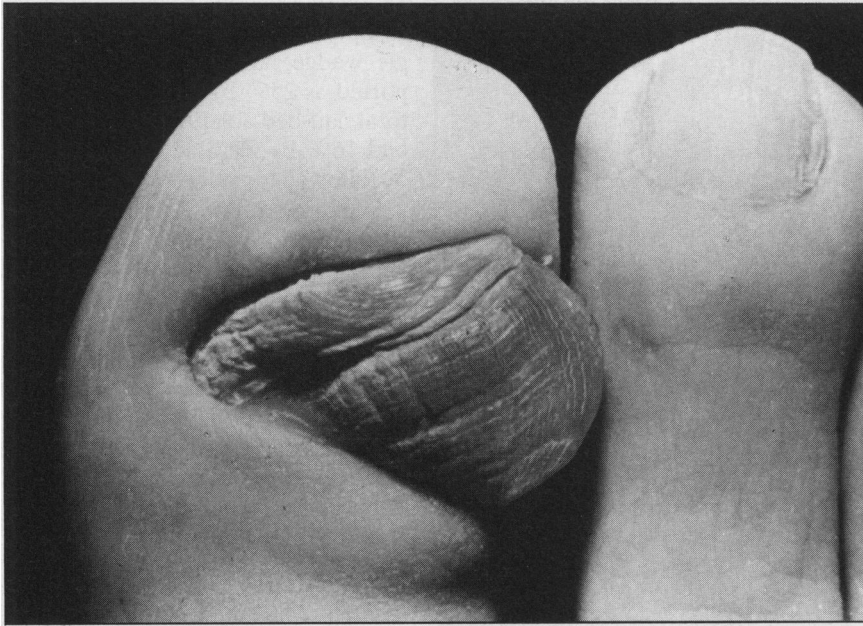
Onychogryphosis is an acquired dystrophy causing thickening, increase in length, and curvature of the affected nail plate; it occurs more commonly in the great toe (Figure 13).¹⁰ Thickening of the nail plate

Figure 12
Eighteen Months after Radical, Selective Germinal Matrix Excision



Note keratinization of the remaining sterile matrix.

Figure 13
Typical Appearance of Onychogryphosis of the Big Toenail



may result from germinal matrix (nail hypertrophy) and/or sterile matrix (pachyonychia) pathology (Chart 4).

Nail hypertrophy may be idiopathic or "senile", traumatic or secondary to psoriasis.² Recurrent trauma, generally aggravated by footwear, causes increased thickness and torsion of the nail plate. One side of the germinal matrix grows faster than the other. The nail plate curves and the direction of the deformity is determined by the faster growing side. Microscopically, the cells show a disorderly, wave-line distribution with hyperchromatism, parakeratosis and numerous splits.

Pachyonychia may be the result of fungal infections or psoriasis. Compact masses of subungual keratin a few millimeters high, adhere to the ventral nail plate and push it upwards so that it becomes convex. Fungal spores germinate in a humid and macerated environment. Therefore, onychomycosis may be superimposed on, or act as a contributory factor to, the further development of onychogryphosis. As a result of fungal growth, subungual hyper-keratosis develops, together with thickening and brown discoloration of the ventral nail. Because of their keratolytic enzymes, the dermatophytes penetrate further into the hyponychial keratin and ultimately destroy the nail plate itself.

Management

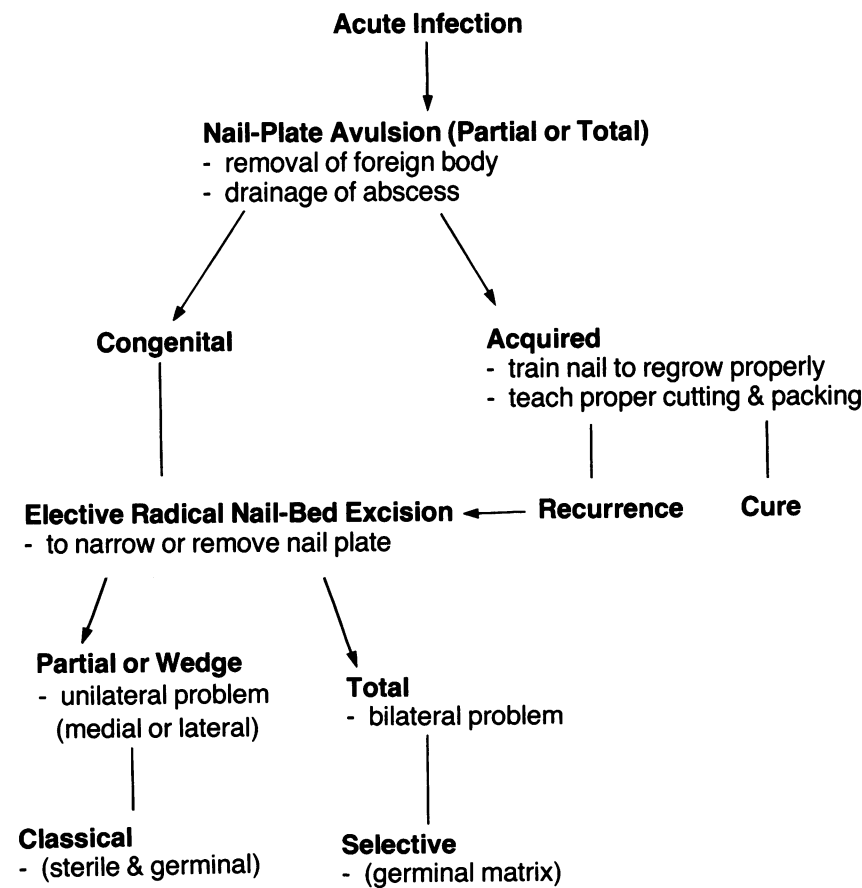
Mild cases of ingrown toenail are either treated palliatively, with trimming of nails, proper footwear and hygiene, or operatively. The former is recommended for the elderly with poor peripheral vascular supply.

Nail plate avulsion with or without scraping of the nail bed, is a more definitive treatment that is simple with low morbidity. The deformity is usually not as severe after the first avulsion, and the new nail plate does not re-generate for, at least, 6-12

Chart 4 Pathology of Onychogryphosis

1. Nail hypertrophy (germinal matrix)
 - trauma
 - idiopathic - "senile"
 - psoriasis
2. Pachyonychia (sterile matrix)
 - fungal
 - psoriasis

Figure 14
Management of Ingrown Toenails



months, usually yielding a good cosmetic result. Selective germinal matrix excision, as described above, is used only for severe cases; however, this is seldom necessary, as the simpler technique of nail-plate avulsion may be safely repeated several times, as necessary.

Conclusions

It is hoped that this paper has given a logical, physiological, simple and effective management plan of two common toenail problems (Figure 14). Therapy based on an understanding of the basic physiology of nail growth and pathology, as well as basic principles of wound care, will help physicians to perform the most appropriate procedure for each individual patient. ■

References

- Jarrett A, Spearman RIC. Histochemistry of the human nail. *Arch Dermatol* 1966; 94:652-7.
- Runne U, Orfands CE. Human nail: structure, growth and pathological changes. *Curr Probl Dermatol* 1981; 9:102-49.
- Lathrop R. Ingrowing toenails: causes and treatment. *Cutis* 1977; 20:119-22.
- Lloyd-Davies RW, Brill GC. Etiology and outpatient management of ingrowing toenails. *Br J Surg* 1963; 50:592-7.
- Murray WR. Onychocryptosis: principles of non-operative and operative care. *Clin Orthop* 1979; 142:96-102.
- Gabriel SS, Dallos V, Stevenson L et al. Ingrowing toenail: a modified segmental matrix excision operation. *Br J Surg* 1979; 66:285-6.
- Winograd AM. Modification in the technique of operation for ingrown toenail. *JAMA* 1929; 92:229-30.
- Zadik FR. Obliteration of the nail bed of the great toe without shortening the terminal phalanx. *Br J Bone Joint Surg* 1950; 32:66-7.
- Murray WR, Bedi BS. Surgical management of ingrowing toenail. *Br J Surg* 1975; 62:409-12.
- Kouskoukis CE, Sher RK. Onychogryphosis. *J Dermatol Surg Oncol* 1982; 8:138-40.

CoActifed*

Tablets/Syrup/Expectorant
Antitussive—Expectorant—Decongestant

Indications: CoActifed Expectorant: To facilitate expectoration and control cough associated with inflamed mucosa and tenacious sputum.

CoActifed Syrup and Tablets: The treatment of cough associated with inflamed mucosa.

Precautions: Before prescribing medication to suppress or modify cough, it is important to ascertain that the underlying cause of the cough is identified, that modification of the cough does not increase the risk of clinical or physiologic complications, and that appropriate therapy for the primary disease is provided.

In young children the respiratory centre is especially susceptible to the depressant action of narcotic cough suppressants. Benefit to risk ratio should be carefully considered especially in children with respiratory embarrassment, e.g., croup. Estimation of dosage relative to the child's age and weight is of great importance.

Since codeine crosses the placental barrier, its use in pregnancy is not recommended.

As codeine may inhibit peristalsis, patients with chronic constipation should be given CoActifed preparations only after weighing the potential therapeutic benefit against the hazards involved.

CoActifed contains codeine: may be habit forming.

Use with caution in patients with hypertension and in patients receiving MAO inhibitors.

Patients should be cautioned not to operate vehicles or hazardous machinery until their response to the drug has been determined. Since the depressant effects of antihistamines are additive to those of other drugs affecting the CNS, patients should be cautioned against drinking alcoholic beverages or taking hypnotics, sedatives, psychotherapeutic agents or other drugs with CNS depressant effects during antihistaminic therapy.

Adverse Effects: In some patients, drowsiness, dizziness, dry mouth, nausea and vomiting or mild stimulation may occur.

Overdose: Symptoms: Narcosis is usually present, sometimes associated with convulsions. Tachycardia, pupillary constriction, nausea, vomiting and respiratory depression can occur.

Treatment: If respiration is severely depressed, administer the narcotic antagonist, naloxone. Adults: 400 µg by i.v., i.m. or s.c. routes and repeated at 2 to 3 minute intervals if necessary. Children: 10 µg/kg by i.v., i.m. or s.c. routes. Dosage may be repeated as for the adult administration. Failure to obtain significant improvement after 2 to 3 doses suggests that causes other than narcotic overdosage may be responsible for the patient's condition.

If naloxone is unsuccessful, institute intubation and respiratory support or conduct gastric lavage in the unconscious patient.

Dosage: Children 2 to under 6 years: 2.5 mL 4 times a day. Children 6 to under 12 years: 5 mL or ½ tablet 4 times a day. Adults and children 12 years and older: 10 mL or 1 tablet 4 times a day.

Supplied: Expectorant: Each 5 mL of clear, orange, syrupy liquid with a mixed fruit odor contains: triprolidine HCl 2 mg, pseudoephedrine HCl 30 mg, guaifenesin 100 mg, codeine phosphate 10 mg. Available in 100 mL and 2 L bottles.

Syrup: Each 5 mL of clear, dark red, syrupy liquid with a pineapple odor and a sweet black currant flavor contains: triprolidine HCl 2 mg, pseudoephedrine HCl 30 mg and codeine phosphate 10 mg. Available in 100 mL and 2 L bottles.

Tablets: Each white to off-white, biconvex tablet, code number WELLCOME P4B on same side as diagonal score mark, contains: triprolidine HCl 4 mg, pseudoephedrine HCl 60 mg and codeine phosphate 20 mg. Each tablet is equivalent to 10 mL of syrup. If tablet is broken in half, it reveals a yellow core. Bottles of 10 and 50 tablets.

Additional prescribing information available on request.

* Trade Mark W-610

PAAB
CCPP



WELLCOME MEDICAL DIVISION
BURROUGHS WELLCOME INC.
KIRKLAND, QUÉ.

IDARAC*

PRESCRIBING INFORMATION floctafenine 200 mg tablets. **THERAPEUTIC CLASSIFICATION:** Analgesic **ACTION:** IDARAC (floctafenine) is an anthranilic acid derivative which has analgesic and anti-inflammatory properties. Floctafenine has been shown to inhibit in vitro biosynthesis of prostaglandins PGE₂ and PGF_{2α}. Gastrointestinal bleeding determined by daily fecal blood loss was shown in one clinical trial to be approximately 1.2 mL after 1600 mg/day of floctafenine compared to 10.4 mL after 2400 mg/day of acetylsalicylic acid. In normal volunteers, IDARAC was well absorbed after oral administration and peak plasma levels were attained 1-2 hours after administration and declined in a biphasic manner with an initial (α phase) half-life of approximately 1 hour and a later (β phase) half-life of approximately 8 hours. Floctafenine and its metabolites do not accumulate following oral administration of multiple doses. After oral and intravenous administration of 14C labelled IDARAC, urinary excretion accounted for 40% and fecal and biliary excretion accounted for 60% of the recovered radioactivity. The main urinary metabolites are floctafenic acid and its conjugate with minimal amounts of free floctafenine.

INDICATIONS: IDARAC (floctafenine) is indicated for short-term use in acute pain of mild and moderate severity. **CONTRAINDICATIONS:** IDARAC (floctafenine) is contraindicated in patients with peptic ulcer or any other active inflammatory disease of the gastrointestinal tract and in patients who have demonstrated a hypersensitivity to the drug. **WARNINGS:** USE IN PREGNANCY: The use of IDARAC (floctafenine) in women of childbearing potential requires that the likely benefit of the drug be weighed against the possible risk to the mother and fetus. Use of the drug in women who are nursing is not recommended. USE IN CHILDREN: The safety and efficacy of IDARAC in children have not been established and therefore is not recommended. The safety and efficacy of long-term use of IDARAC have not been established. **PRECAUTIONS:** IDARAC (floctafenine) should be used with caution in patients with impaired renal function. In clinical trials with IDARAC, dysuria without apparent changes in renal function was reported. The incidence of dysuria was greater in males than in females and occurred primarily in the first morning voiding. It has not been established whether dysuria is related to dose and/or duration of drug administration. Patients taking anticoagulant medication may be given IDARAC with caution. Alterations in prothrombin time have been observed only in clinical trials where the administration of IDARAC was extended beyond two weeks. IDARAC should be used with caution in patients with a history of peptic ulcer or other gastrointestinal lesions. **ADVERSE REACTIONS:** The most commonly occurring side effects reported during IDARAC (floctafenine) therapy were: **CENTRAL NERVOUS SYSTEM:** Drowsiness, dizziness, headache, insomnia, nervousness, irritability. **GASTROINTESTINAL SYSTEM:** Nausea, diarrhea, abdominal pain or discomfort, heartburn, constipation, abnormal liver function, gastrointestinal bleeding. **UROGENITAL SYSTEM:** Dysuria, burning micturition, polyuria, strong smelling urine, urethritis and cystitis. **ALLERGIC-TYPE REACTIONS:** Maculopapular skin rash, pruritis, urticaria, redness and itching of the face and neck. Other less frequently occurring side effects were: tinnitus, blurred vision, dry mouth, thirst, bitter taste, anorexia, stomach cramps, flatulence, hot flushes and sweating, tachycardia, weakness and tiredness. **SYMPTOMS AND TREATMENT OF OVERDOSE:** In a case of overdose standard procedures to evacuate gastric contents, maintain urinary output and provide general supportive care should be employed. **DOSAGE AND ADMINISTRATION:** The usual adult dose of IDARAC (floctafenine) is 1 to 2 tablets (200 to 400 mg), every 6 to 8 hours as required. The maximum recommended daily dose is 1200 mg. IDARAC is recommended for short-term management of acute pain. The tablets should be taken with a glass of water. IDARAC is not recommended for use in children. **AVAILABILITY:** Each tablet of IDARAC contains 200 mg of floctafenine. Tablets are biconvex, round, creamy-white, with W on one side and 200 on the other side. IDARAC is available in bottles of 100 tablets. Store at room temperature, protected from light. IDARAC is a Schedule F (prescription) drug. Product monograph is available upon request.

Winthrop

Winthrop Laboratories
Division of Sterling Drug Ltd.**
Aurora, Ontario L4G 3H6
*Registered Trademark
**Registered User

PAAB
CCPP