

AN ELECTRON MICROSCOPE STUDY OF THE EMBRYOLOGY OF THE INTERCALATED DISC IN THE HEART OF THE RABBIT*

By ALAN R. MUIR, M.D.‡

(From the Department of Anatomy, Washington University School of Medicine, St. Louis)

PLATES 42 TO 49

(Received for publication, October 25, 1956)

The studies of Van Breeman (23), Sjöstrand and Andersson (22) and Price, Weiss, Hata, and Smith (18) have shown that the fine structure of the intercalated disc consisted of a double membrane flanked by the termination of myofibrils in dense material. These observations caused the above authors to suggest that the discs represent the junctions between neighbouring cardiac muscle cells and thus support the concept that cardiac muscle is cellular in character.

By light microscopy, intercalated discs have not been demonstrable in embryonic or early foetal life (26), and it has been shown that they increase in numbers and complexity with age after birth (13). In tissue cultures, Hogue (8) has shown that intercalated discs appear only after 30 to 50 days of cultivation. It appeared, therefore, that, regardless of the interpretation of the structure of the adult disc, embryonic muscle was syncytial.

The object of this investigation was to trace the development of the intercalated discs, in order to determine whether their absence in embryonic life was real or only apparent because of the limitations of previous techniques.

Material and Methods

Embryos were removed under barbiturate anaesthesia from rabbits of known copulation age. After the stage of development had been checked with the table of Minot and Taylor (15), the embryonic heart was fixed in osmium tetroxide with bichromate buffered to a pH of 7.6 (4). Portions of the right ventricular wall of young and adult rabbits were fixed in the same way. Fifteen stages of development were studied, namely at $9\frac{1}{2}$, 10, 11, 13, 15, 18, 23, and 28 days after copulation, in newborn and 4, 15, 20, 30, and 50 days after birth. Adult cardiac muscle was obtained from the mother after removal of the embryos.

The author wishes to express his gratitude to Dr. E. W. Dempsey for providing the necessary facilities, and for much advice and helpful criticism.

* This investigation was aided, in part, by grants (B-425 and RG-3784) from the United States Public Health Service, National Institutes of Health.

‡ Work performed during the tenure of a Commonwealth Fund Fellowship. Present address: Department of Anatomy, University of Edinburgh, Scotland.

After 1 hour's fixation the tissues were rapidly dehydrated in alcohol and embedded in a mixture of butyl and methyl methacrylate. Sections were cut either on the Porter-Blum (17) microtome or on the Minot microtome with the knife holder described by Dempsey and Lansing (5). The sections were examined, without removal of the methacrylate, on a RCA EMU2 microscope at initial magnifications of 1,000 to 6,000 diameters. Thick sections were cut from the same blocks and were examined by phase microscopy and after staining with Heidenhain's haematoxylin.

OBSERVATIONS

The investigation was carried out and the descriptions will be given in reversed chronological order, making it possible to trace the recognised disc of the adult into the previously unrecognised structure in early embryos.

Adult.—The branching muscle fibres could be seen to be transected by intercalated discs. These discs replaced the Z membrane and exhibited, occasionally, a characteristic step-like course across the fibre. The magnitude of the step was always the same as, or a multiple of, the sarcomere length (Fig. 1). Phase microscopy on adjacent sections proved that these structures were, indeed, the intercalated discs of light microscopy.

At higher magnifications, the disc was seen to contain a plicated double membrane. Where these membranes were running transverse to the myofibrillar axis, dense material into which the myofilaments inserted was seen in the sarcoplasm adjacent to each component of the double membrane (Fig. 2). When the double membrane was running parallel to the myofibrils, as between the steps of a step-like disc, there was, usually, no aggregation of dense material and only with difficulty could the continuity of the membranes be established. The membranes became continuous with the sarcolemma bounding the cleft between two muscle fibres, as in the lower part of Fig. 2 and in Fig. 3. The sarcolemma showed an inner, narrow, discrete cell membrane and an outer diffuse layer of greater thickness but less density. The outer layer of the sarcolemma was continuous with and had a structure indistinguishable from that of the material which separated the membranes of the disc.

The interval between the double membranes was only about 300 A, but the complex folding and the related dense material made the over-all thickness of the disc approximately 7,000 A. In some preparations, the distance between the membranes was irregularly and markedly increased, up to 6,000 A as in Fig. 4. This appearance was considered an artefact, but it illustrated the tendency of cardiac muscle to segment at the site of the disc (1, 12, 20). This separation would also explain the observation of Przewoski (19) of a clear space between what he termed the "stratum granulosum terminale" of the disc.

Rarely structures, similar to intercalated discs, were observed between the sides of adjacent, parallel fibres (Fig. 5). In such a preparation the cell membrane, or inner layer of the sarcolemma could be traced to one of the layers

of the double membrane, while the outer diffuse layer of the sarcolemma could be traced into the gap between the membranes.

Phase microscopy showed that there were often more than one nucleus to each area of sarcoplasm bounded by intercalated discs, but field limitations made it impossible to confirm this on the electron micrographs. In Fig. 1, the appearance of double nuclei may be due to the plane of section, but the size, 26 microns from pole to pole, suggested that the two nuclei were closely apposed.

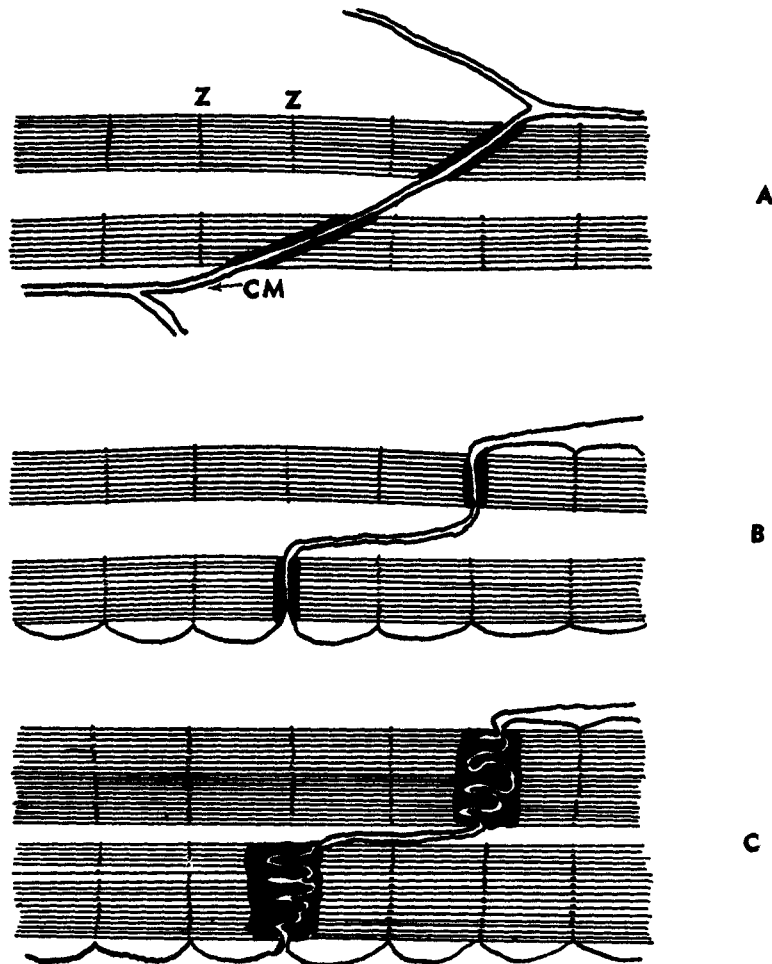
Young Postnatal.—The arrangement of muscle fibres and the discs were the same as in the adult, but the membranes were much less folded where the myofibrils were attached. Thus, although the gap between the membranes remained, as in the adult, about 300 A, the over-all thickness of the disc was reduced to about 1,600 A. The thickness of the Z membrane in this contracted muscle was about 800 A and it was not possible to differentiate the intercalated discs from them, using the phase microscope. For the same reason, the discs could not be identified by ordinary microscopy earlier than the 20th postnatal day, although cross-striations could be seen easily at birth. The continuity of the plasma membranes between the steps of the disc could be traced as in Fig. 6, but at the site of insertion of myofilaments the dense material rendered the membranes more conspicuous. These inconspicuous membranes frequently could be traced past many sarcomeres and often off the field, thus giving the appearance of incomplete discs. There was no sign of the myofilaments passing through the disc, although their passage through the Z membranes could be discerned.

Late Foetus—18th day of prenatal life to birth.

The sarcoplasmic mass was divided into areas by cell membranes. The cells thus delimited were spindle-shaped and never contained more than one nucleus. At low magnifications ($\times 1,000$) the cell membranes could not be seen clearly on the screen and the mass of sarcoplasm appeared syncytial, but repeated examinations, at higher magnifications always revealed that cell membranes passed between any two nuclei (Fig. 7). The frequency with which the cell membranes were seen and the fact that the density of the nuclear population was greater than in the adult, lead to the observation that these cells were considerably smaller than the areas in the adult bounded by intercalated discs. The degree of differentiation of myofibrils varied from cell to cell in any one specimen; characteristically the myofibrils were arranged in the peripheral cytoplasm. Occasional mitoses were observed, and in some instances differentiated myofibrils were present in the cytoplasm of the dividing cell.

The myofibril always appeared to reach the cell membrane one sarcomere length from the previous Z membrane, and at the site of meeting the cell membrane the myofibrilaments were embedded in dense material identical in appearance to that of the older intercalated discs. This arrangement was

repeated in the next cell; thus, a structure essentially similar to, but simpler than the adult disc was produced. In these foetal stages the axis of the myofibril sometimes approached the cell membrane at an acute angle, causing the double



TEXT-FIG. 1. Schematic representation of the structure of the intercalated disc in (A) embryo; (B) newborn; (C) adult.

membrane to pass obliquely across the axis; this was never observed after birth. Dark condensations adjacent to the cell membrane were always related to the termination of myofibrils, although sometimes the plane of section made them at first appear isolated.

Embryonic.—younger than the 17th day after coitus.

The heart muscle was composed of small, mononucleated, spindle-shaped cells. Bundles of myofilaments, divided into sarcomeres by Z membranes, were observed in the sarcoplasm (Figs. 8 and 9). As in the later stages, the cell membranes always crossed a myofibrillar axis at the point where a Z membrane would have been expected. The material which embraced the termination of the myofilaments at the cell membrane had a similar electron density to that of the material which surrounded the myofilaments to form the Z membranes.

The hearts from the embryos which were removed $9\frac{1}{2}$ and 10 days after coitus comprised a single tubular structure and the older specimens showed the first sign of convolution of the tube. In this early stage, the youngest that were examined, the cell boundaries of the cardiac muscle cells were readily seen. The myofibrils exhibited Z membranes and wherever a myofibrillar axis crossed the boundary between cells, a simple form of intercalated disc was seen (Fig. 9).

The changes that were seen in the disc during development have been shown schematically in Text-Fig. 1. The oblique passage of the membranes across the myofibrillar axis were only seen in the spindle-shaped cells of the embryo, shown in Text-Fig. 1 A. Mechanical traction on this simple structure could have produced the step-like form seen in the young postnatal animal (Text-Fig. 1 B). Further mechanical forces in later life could then have produced the complex foldings of the membranes shown in Text-Fig. 1 C. This suggestion is supported by Jordan's (10) observation that comb-like forms of disc were found in hypertrophied hearts. The fact that by light microscopy the discs have been more readily demonstrated in papillary muscles than in the atrial myocardium would also support the suggestion that mechanical forces produce the complexity which makes them demonstrable.

In all the specimens the myofibrils appeared contracted, and measurements showed that from the $9\frac{1}{2}$ day embryo to the adult the sarcomere length remained between 1.4 and 1.6 microns.

DISCUSSION

The electron microscope studies of Van Breeman (23), Sjöstrand and Anderson (22), Price, Weiss, Hata, and Smith (18) and the present work seemed to show that the adult intercalated disc was the site of junction of neighbouring cardiac muscle cells, and so support the work of Werner (24) and von Palczewska (16). Lewis (14), employing tissue cultures of cardiac muscle in which individual cells contracted at different rates, concluded that the cells were physiologically and probably structurally independent. The tendency for cardiac muscle to segment at the site of the discs, as reported by Saphir and Karsner (20), Jordan and Bordin (12), and Beams, Evans, Janney, and Baker

(1), seemed to support the cellular concept, although these authors, who favoured the syncytial structure, interpreted their findings as a demonstration of the fragility of myofibrils at these points. By injecting saline into the muscle fibre, de Rényi (6) noticed that greater pressure was needed to force the fluid through the disc than through the sarcoplasm elsewhere, an observation entirely in accord with the recent electron microscope findings.

The intercalated discs are similar in many respects to the terminal bars which occur between adjacent intestinal epithelial cells (25) and in the stratum spinosum of the epidermis (21). In the latter situation, the tonofibrils of the epidermal cells terminate in dense plaques similar to the ones which receive the myofilaments.

The early electron micrographs of Berrian (2) and Beams, Evans, Janney, and Baker (1) did not resolve the double membrane in the substance of the disc and these authors thus supported the generally recognized view that cardiac muscle was syncytial. The acceptance of this view has been largely due to the series of papers published by H. E. Jordan, who supported the earlier work of Heidenhain (7) and others.

The reasons for Jordan's conclusions can be summarised as follows: (1) Embryonic cardiac muscle appeared syncytial, (2) Intercalated discs only appeared in late prenatal life (13), (3) Myofibrils crossed the disc without apparent interruption (9), (4) The number of discs increased with age (13), (5) The discs can appear superimposed on the nucleus (11), (6) The discs could be incomplete or interrupted in their course across a fibre (11), (7) Areas bounded by adjacent discs might not contain a nucleus (9), (8) The area bounded by adjacent discs might contain more than one nucleus (9).

This investigation has shown that points 1, 2, and 3 are erroneous. The observation that with age the disc becomes larger and more complex readily explains point 4. The dense material on the cell membrane occurs only at points where the membranes transect a myofibril, and as the membranes occasionally run for long distances between and parallel to myofibrils, the observations 5 and 6 can be explained readily by the unresolvability of the cell membranes by light microscopy. This explanation was advanced by von Palczewska (16) in her Figs 9 and 10; in the same article she also showed how point 7 could be caused by the plane of section, a point which was admitted by Jordan (9). The final item indicates only that adult cardiac muscle cell may be multinucleated. This is entirely probable; Werner (24) stated that each *muskel-territorium* contains 2 to 32 nuclei, the usual number being 8. The present observations that early embryonic muscle is mononucleate and that mitosis can be observed after differentiation of myofibrils lend support to the suggestion that the multinucleated state in the adult is produced by nuclear division without cytoplasmic separation.

The principal conclusion from this study is that cardiac muscle is cellular throughout its development and in the adult, and that there is no valid evidence to contest the statement that the intercalated discs are specialised regions of cellular adhesion.

The multinucleated adult cardiac muscle cell is much larger than the mononucleated cell of the embryonic muscle. Since from the early stages, the differentiating myofilaments are inserted at each end into the cell membranes it follows that *within each cell* the myofilaments must grow in length. As the sarcomere length is constant throughout development, this growth must involve the addition of sarcomeres. Heidenhain (7), although supporting the concept of syncytial structure, suggested that the intercalated discs were the site of growth of the myofibril; a suggestion which is not incompatible with the present conclusions. The demonstration by Bourne (3) of high enzyme concentrations in the adult disc therefore may be a significant observation.

Our present understanding of the morphology of intercalated discs raises many questions concerning the spread of excitation and contractility across these specialised junctions. In this connection, the present demonstration of structures, analogous to the discs but disposed across cell boundaries parallel to the fibre axis, should be emphasized. If these dense structures are involved in the transmission of impulses, the spread of excitation in cardiac muscle may proceed laterally as well as along the main axis of the fibre.

SUMMARY

Prenatal and postnatal cardiac muscle from rabbits has been studied by electron microscopy, after osmium fixation and methacrylate embedding. The observations showed that

1. Cell membranes divide the muscle into cellular units from the youngest embryo which was studied (9½ days after coitus) until the adult state.
2. The embryonic muscle cells contain only one nucleus, whereas the adult cell may be multinucleated.
3. At all stages of development, wherever a myofibrillar axis crosses a cellular boundary, the myofilaments are interrupted by an intercalated disc.
4. With age, increase in size and complexity of the discs render them recognisable by the light microscope.

BIBLIOGRAPHY

1. Beams, H. W., Evans, T. C., Janney, C. D., and Baker, W. W., Electron microscope studies on the structure of cardiac muscle, *Anat. Rec.*, 1949, **105**, 59.
2. Berrian, J. H., Electron microscopic structure of the intercalated discs of mammalian cardiac muscle, Project No. NM 001057.10.01, United States Naval School of Aviation Medicine, Pensacola, Florida, 1953.

3. Bourne, G. H., Enzymes of the intercalated discs of heart muscle fibres, *Nature*, 1953, **172**, 588.
4. Dalton, A. J., A chrome-osmium fixative for electron microscopy, *Anat. Rec.*, 1955, **121**, 281.
5. Dempsey, E. W., and Lansing, A., Improved knife-holders for thin sectioning with rotary microtomes, *Proc. Soc. Exp. Biol. and Med.*, 1953, **82**, 253.
6. de Rényi, G. S., The nature of intercalated discs of cardiac muscle studied by the microdissection method, *Am. J. Med. Sc.*, 1945, **209**, 270.
7. Heidenhain, M., Ueber die Structur des menschlichen Herzmuskels, *Anat. Anz.*, 1901, **20**, 33.
8. Hogue, M. J., Intercalated discs in tissue culture, *Anat. Rec.*, 1947, **99**, 157.
9. Jordan, H. E., The structure of heart muscle of the humming bird, with special reference to the intercalated discs, *Anat. Rec.*, 1911, **5**, 517.
10. Jordan, H. E., The intercalated discs of hypertrophied heart muscle, *Anat. Rec.*, 1912, **6**, 357.
11. Jordan, H. E., and Banks, J. B., A study of the intercalated discs of the heart of the beef, *Am. J. Anat.*, 1917, **22**, 285.
12. Jordan, H. E., and Bordin, J., The relation of intercalated discs to the so-called "segmentation" and "fragmentation" of heart muscle, *Anat. Anz.*, 1913, **43**, 612.
13. Jordan, H. E., and Steele, K. B., A comparative microscopic study of the intercalated discs of vertebrate heart muscle, *Am. J. Anat.*, 1912, **13**, 151.
14. Lewis, W. H., Cultivation of embryonic heart muscle, *Carnegie Institution of Washington, Contrib. Embryol.*, 1926, **18**, 1.
15. Minot, C. S., and Taylor, E., Normal plates of the development of the rabbit. Normentafeln zur Entwicklungsgeschichte der Wirbelthiere, Jena, Gustav Fischer, 1905, **5**.
16. von Palczewska, I., Über die Struktur der menschlichen Herzmuskelfasern, *Arch. mikr. Anat.*, 1910, **75**, 41.
17. Porter, K. R., and Blum, J., A study in microtomy for electron microscopy, *Anat. Rec.*, 1953, **117**, 685.
18. Price, K. C., Weiss, J. M., Hata, D., and Smith, J. R., Experimental needle biopsy of the myocardium of dogs, with particular reference to histologic study by electron microscopy, *J. Exp. Med.*, 1955, **101**, 687.
19. Przewoski, E., Du mode de réunion des cellules myocardiques de l'homme adulte, *Arch. sc. biol., St. Petersburg*, 1893, **2**, 287.
20. Saphir, O., and Karsner, H. T., An anatomical and experimental study of segmentation of the myocardium and its relation to the intercalated discs, *J. Med. Research*, 1924, **44**, 539.
21. Selby, C. Cannan, An electron microscope study of the epidermis of mammalian skin in thin sections, *J. Biophysic. and Biochem. Cytol.*, 1955, **1**, 429.
22. Sjöstrand, F. S., and Andersson, E., Electron microscopy of the intercalated discs of cardiac muscle tissue, *Experientia*, 1954, **10**, 369.
23. van Breeman, V. L., Intercalated discs in heart muscle studied with the electron microscope, *Anat. Rec.*, 1953, **117**, 49.

24. Werner, M., Besteht die Herzmuskulatur der Säugetiere aus allseits scharf begrenzten Zellen oder nicht? *Arch. mikr. Anat.*, 1910, **75**, 101.
25. Weiss, J. M., The role of the Golgi complex in fat absorption as studied with the electron microscope with observations on the cytology of duodenal absorptive cells, *J. Exp. Med.*, 1955, **102**, 775.
26. Witte, L., Histiogenesis of the heart muscle of the pig in relation to the appearance and development of the intercalated discs, *Am. J. Anat.*, 1919, **25**, 333.

EXPLANATION OF PLATES

All the plates are electron micrographs of rabbit cardiac muscle.

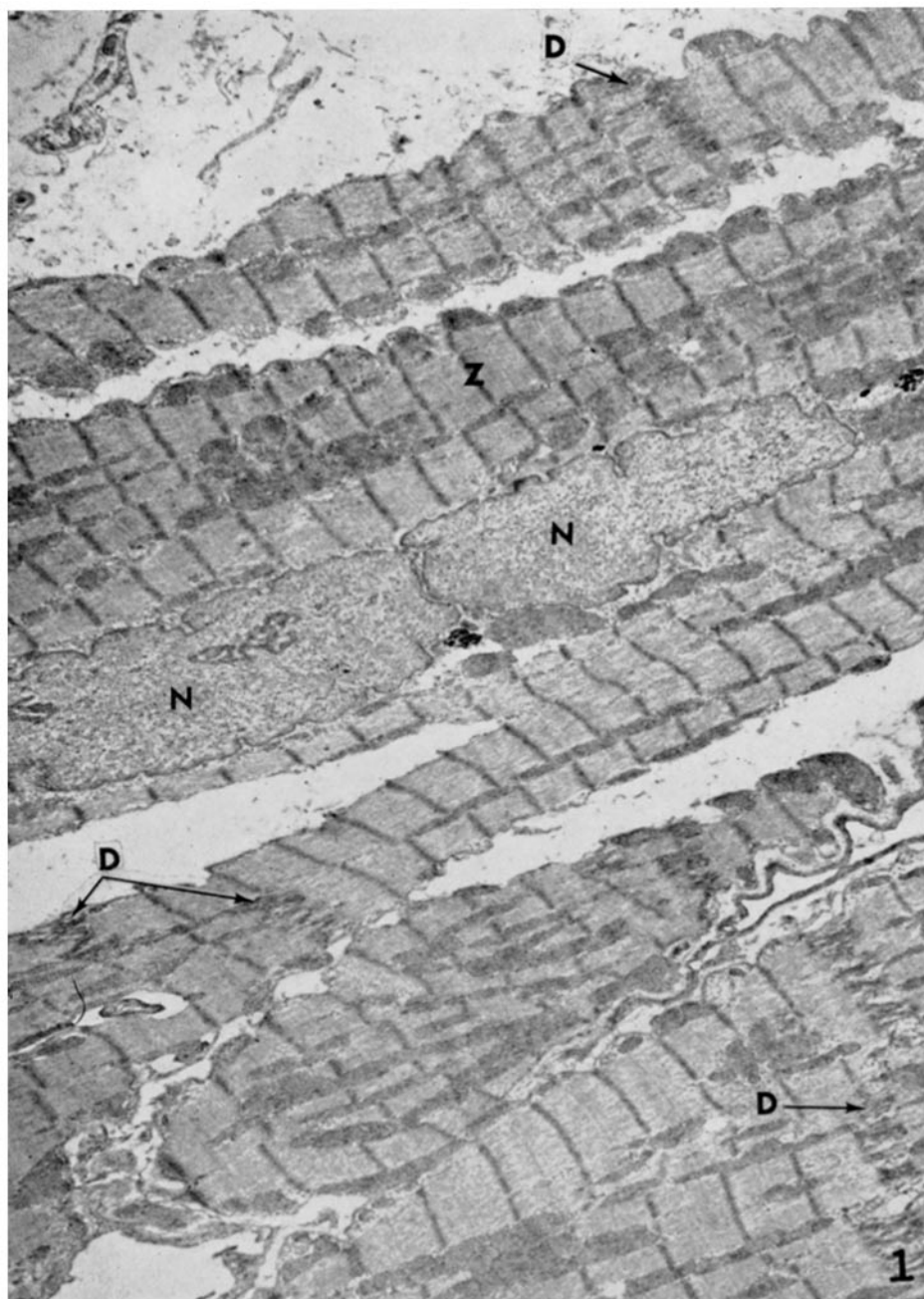
Abbreviations

<i>CM</i> , cell membrane.	<i>MY</i> , myofilaments.
<i>D</i> , intercalated disc.	<i>N</i> , nucleus.
<i>G</i> , Golgi apparatus.	<i>S</i> , sarcolemma.
<i>M</i> , mitochondrion.	<i>Z, Z</i> (Krause's) membrane.

PLATE 42

FIG. 1. Adult. The branching cardiac muscle fibres are transected by intercalated discs (*D*), which cross the fibre at points where *Z* membranes would be expected. In the lower left portion of the photograph, a disc which exhibits the step-like course across the fibre can be seen.

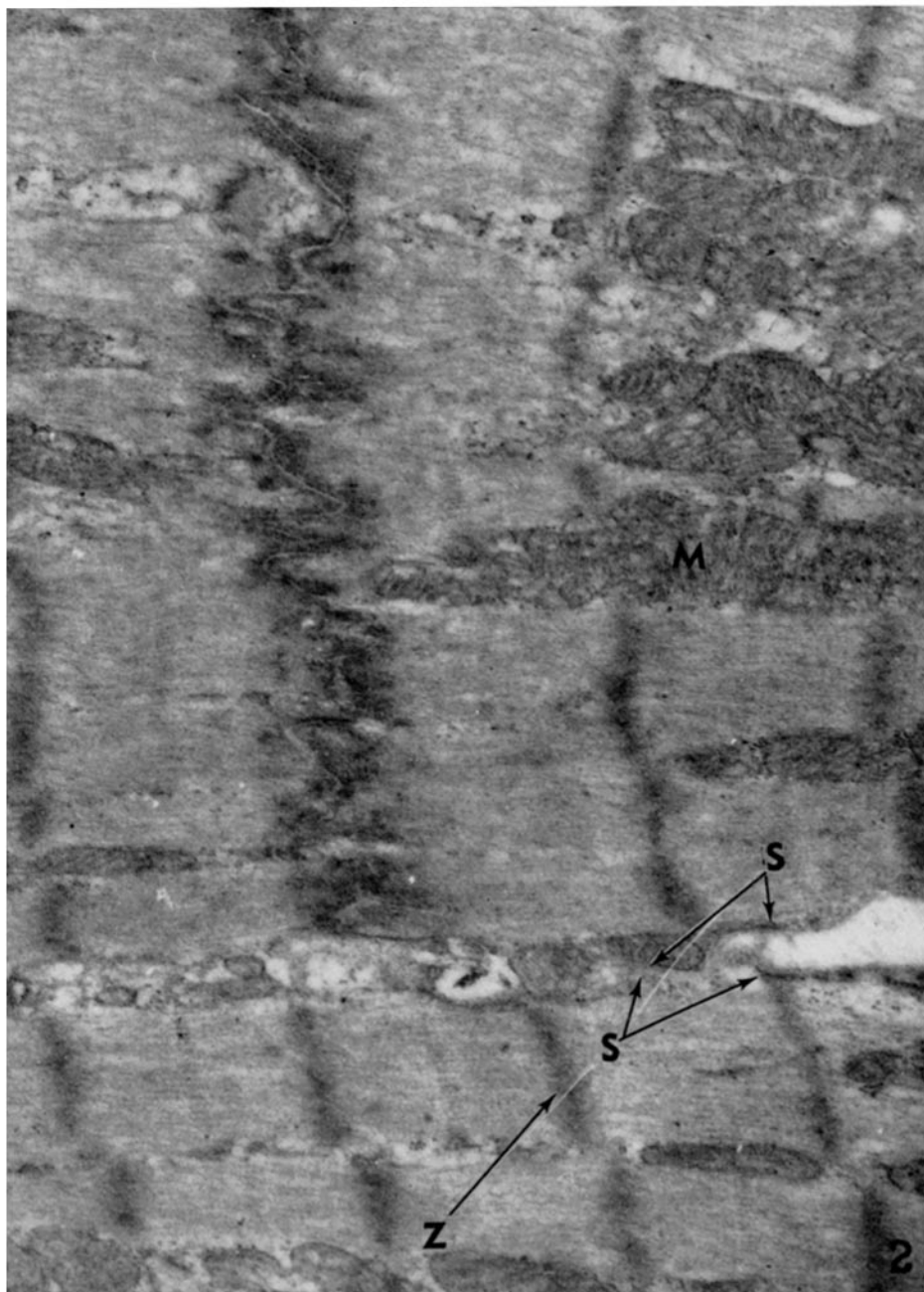
Dimensions suggest that the nuclei (*N*) are two separate nuclei, and not the same nucleus separated at a fold by the plane of section. $\times 4800$.



(Muir: Embryology of the intercalated disc)

PLATE 43

FIG. 2. Adult. Higher magnification of the same section illustrated in Fig. 1. The fine structure of the disc is depicted. The myofibrils formed of myofilaments can be seen separated from each other by sarcoplasm containing mitochondria. At the disc the myofilaments end in the dense material adjacent to the cell membrane. The plicated cell membranes can be traced across the disc, and in the lower part become continuous with the sarcolemma (*S*). $\times 25,000$.


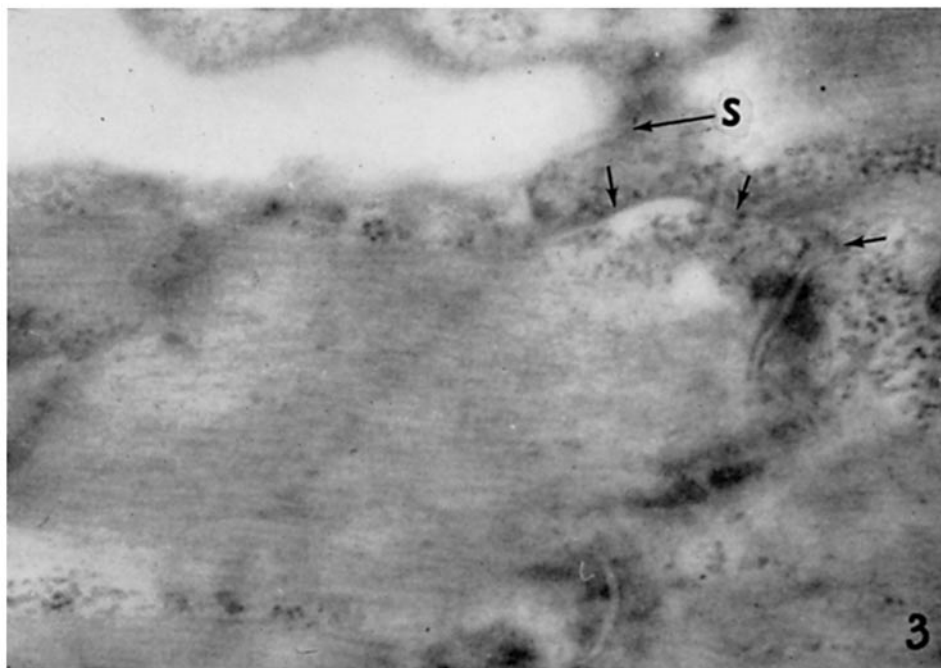


(Muir: Embryology of the intercalated disc)

PLATE 44

FIG. 3. Adult. The sarcolemma at (*S*) can be seen to be composed of a narrow, dark, inner membrane and an outer diffuse layer of less density. The inner membrane can be traced, past the arrows, to one of the two membranes in the disc. The diffuse layer has a density similar to that seen between the layers of the disc. $\times 38,000$.

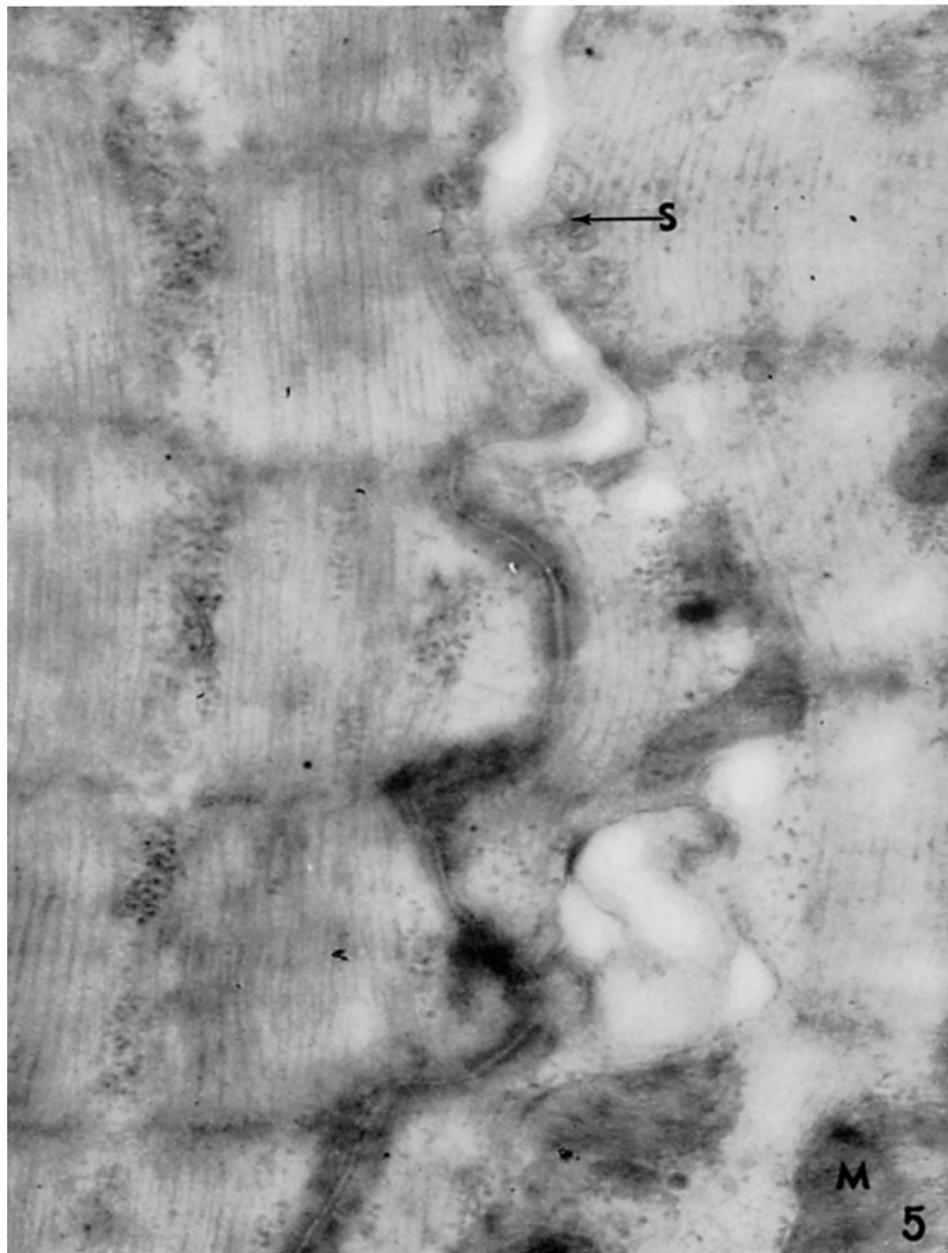
FIG. 4. Adult. The upper arrow shows a marked separation of the membranes of the disc, which was considered an artefact. The lower arrow indicates the normal relations. $\times 18,000$.



(Muir: Embryology of the intercalated disc)

PLATE 45

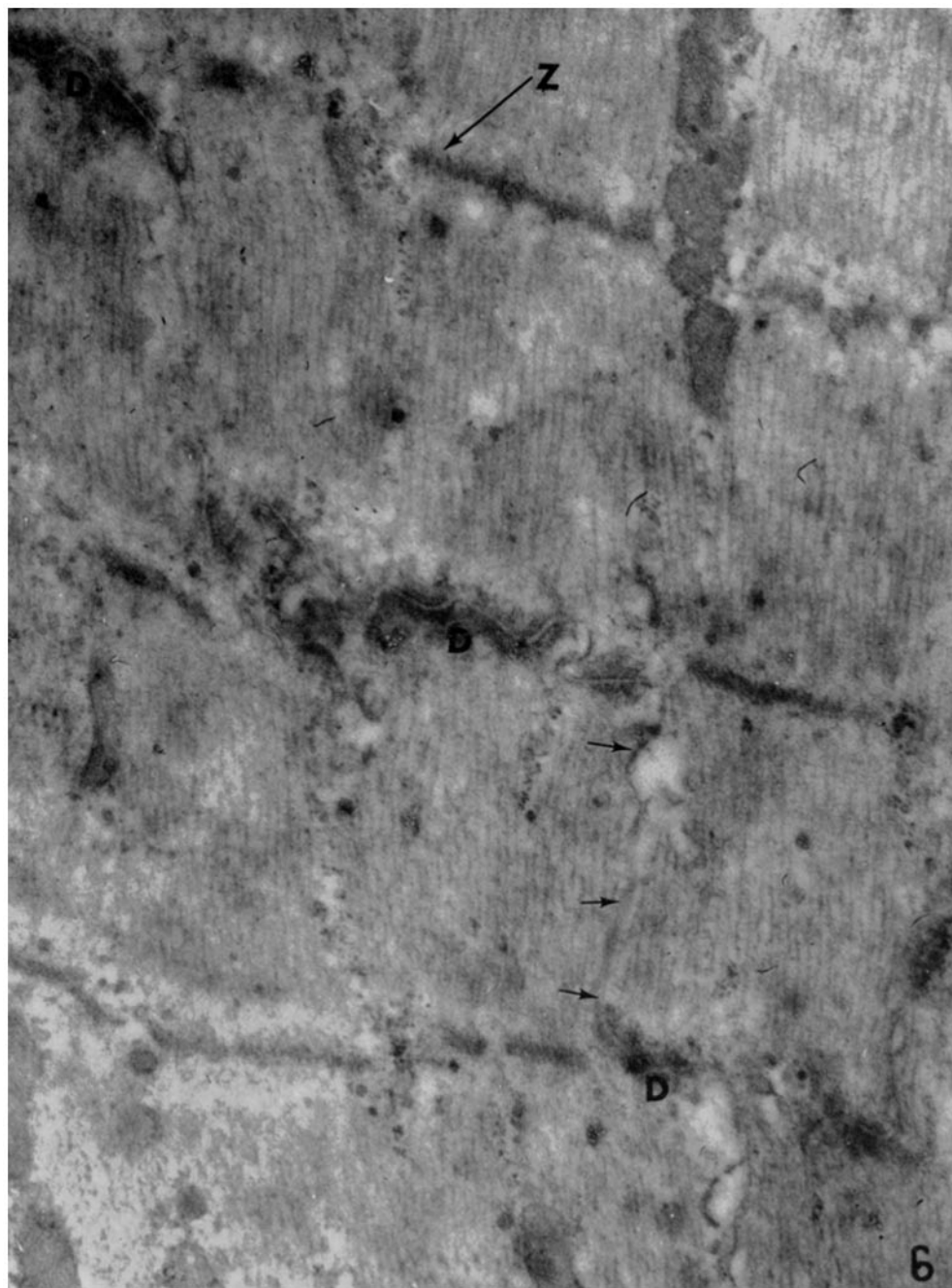
FIG. 5. Adult. Two muscle cells are parallel and in close proximity to one another. In the upper part of the field the fibres are separated by a cleft which is bounded by the sarcolemma (*S*) of each fibre. In the lower part of the field, the fibres are bound together by a structure similar to an intercalated disc, but no myofilaments can be seen terminating in the dense material in either cell. Along the cell margins in the upper part of the picture, vesicular structures can be seen which appear to bud off from the cell membrane. $\times 50,000$.



(Muir: Embryology of the intercalated disc)

PLATE 46

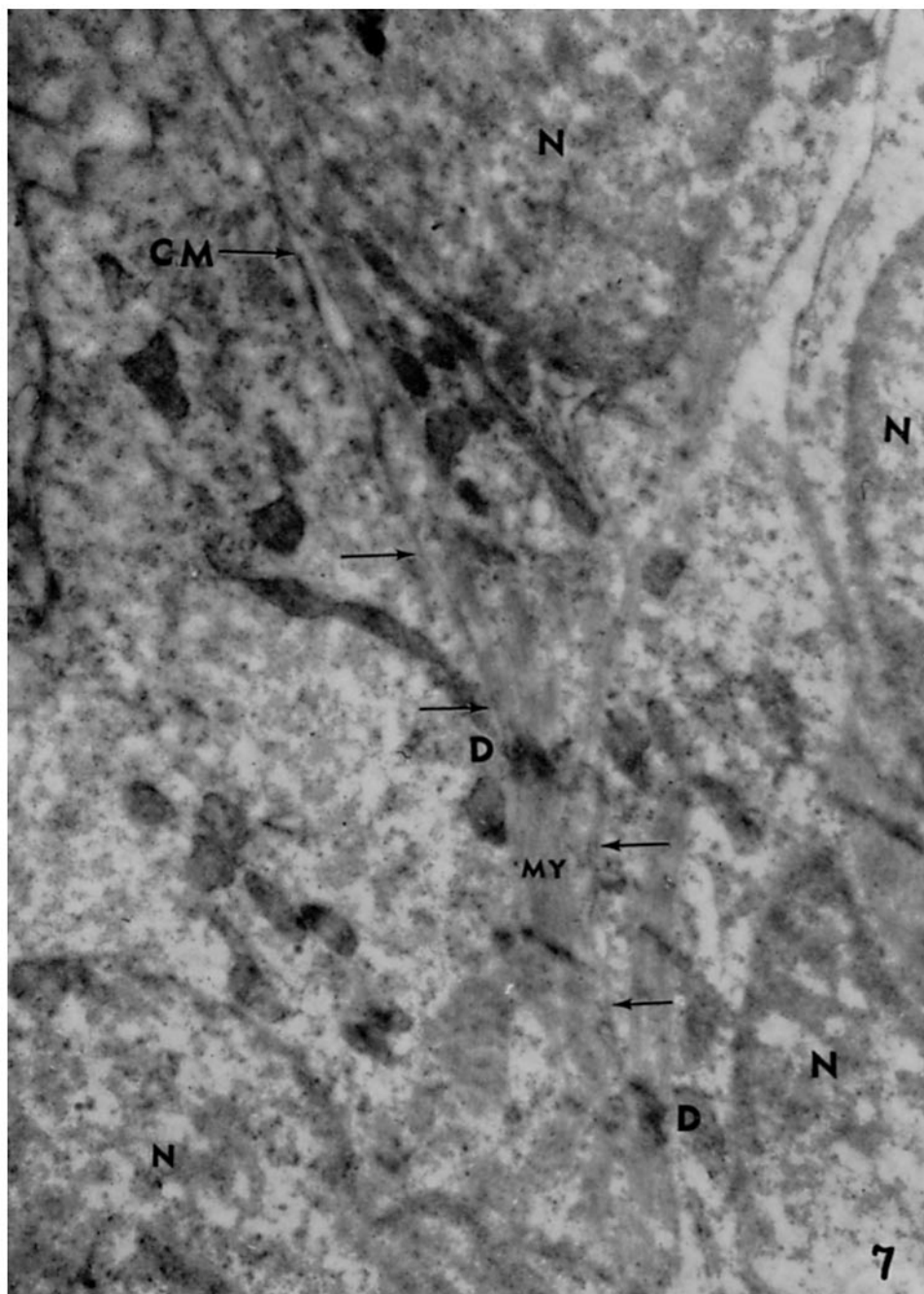
FIG. 6. 20 days after birth. The myofibrillar axis shown in this field is transected by an intercalated disc which shows three steps (*D-D-D*). Where the membranes cross the myofibrillar axis, there is a dense material into which the myofilaments terminate. The membranes can be traced from one step to the next, as indicated by the arrows, but the absence of the dense material makes their course difficult to follow. $\times 38,000$.



(Muir: Embryology of the intercalated disc)

PLATE 47

FIG. 7. Prenatal, 18 days after coitus. Portions of five cardiac muscle cells can be seen, four of which contain nuclei. One of the cell membranes (*CM*) can be traced down, past the upper two arrows, to the developing intercalated disc (*D*). After transecting the myofibrillar axis (*MY*) the membranes can be followed past the lower two arrows to the lower disc (*D*). $\times 20,000$.

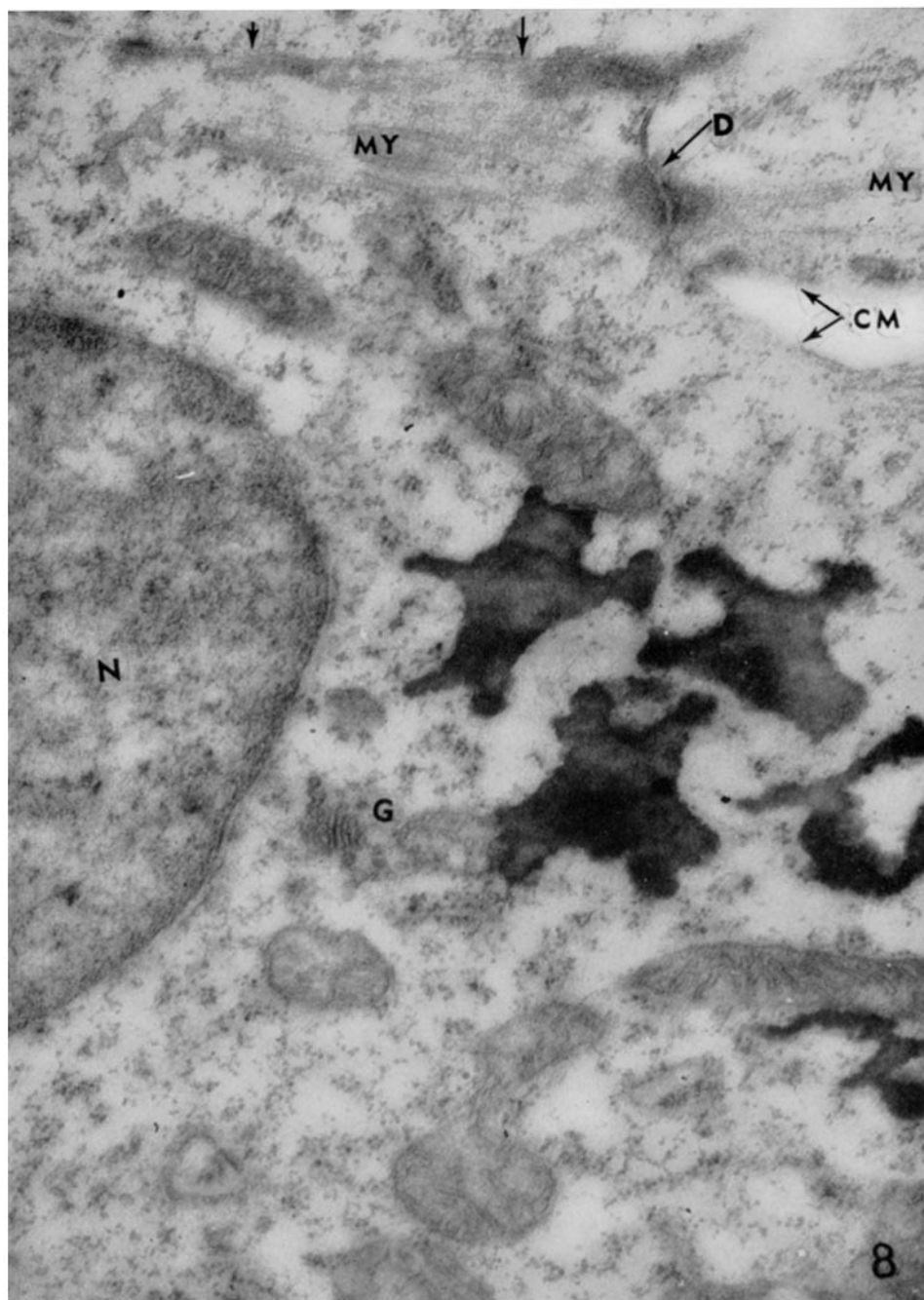


(Muir: Embryology of the intercalated disc)

PLATE 48

FIG. 8. Prenatal, 15 days alter coitus. In the upper part of the field the cell membrane (*CM*) can be traced through the disc (*D*) and then parallel to the myofilaments (*MY*) past the two inverted arrows. There is no continuity between the myofilaments to the left of the disc with those in the other cell to the right of the disc.

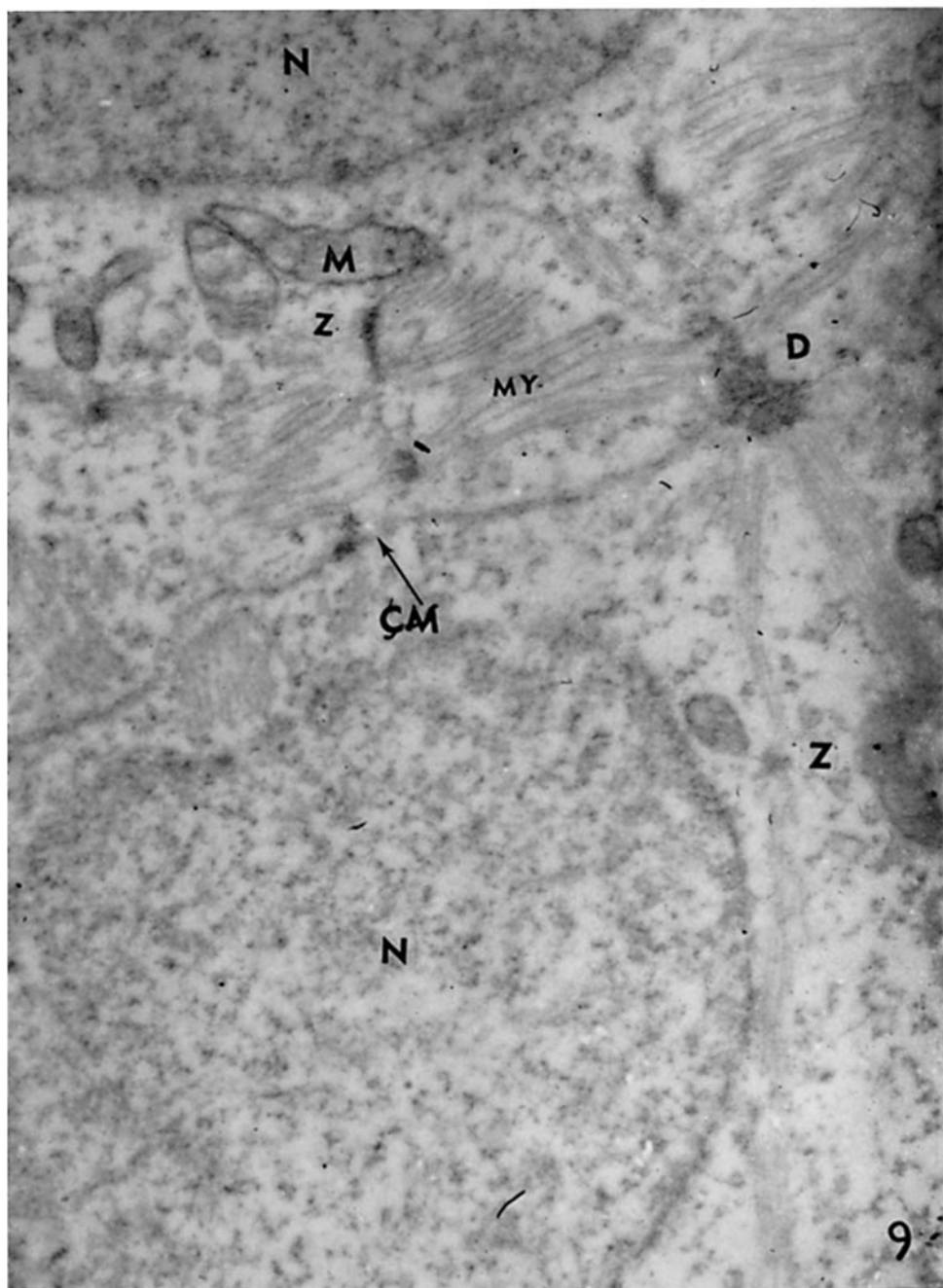
Lipide droplets can be seen close to the Golgi apparatus (*G*) at the side of the nucleus (*N*). $\times 23,500$.



(Muir: Embryology of the intercalated disc)

PLATE 49

FIG. 9. Prenatal, 10 days after coitus. This was the youngest stage of development which was studied. Two closely apposed nuclei (*N-N*) are seen, but cell membranes (*CM*) divide the intervening cytoplasm. Myofilaments (*MY*) divided into sarcomeres by *Z* membranes (*Z*) can be discerned, and where these myofilaments converge on the cell membrane an intercalated disc (*D*) is seen. $\times 24,000$.



(Muir: Embryology of the intercalated disc)